

# Profilactic usage of N-acetyl cysteine in the treatment of tuberculosis in children may be effective in protection from hepatotoxicity: A case experience

<sup>1</sup>Erkan YETMİŞ  
<sup>2</sup>Nevzat Aykut BAYRAK  
<sup>1</sup>Çağatay NUHOĞLU

<sup>1</sup>Department of Pediatrics, University of Health Sciences, Turkey. Haydarpaşa Numune Training and Research Hospital, İstanbul, Turkey

<sup>2</sup>Department of Pediatric Gastroenterology, University of Health Sciences, Turkey. Zeynep Kamil Maternity and Children's Training and Research Hospital, İstanbul, Turkey

## ABSTRACT

Tuberculosis (TB) disease: Despite developed advanced diagnostic methods and new treatments, its frequency is increasing especially in developing countries and continues to cause death worldwide. Most of the drugs used in the disease process are hepatotoxic. These drugs are generally well tolerated, but their simultaneous use enhances each other's hepatotoxic effect. The toxic hepatitis that develops during treatment, affects treatment compliance and treatment results can be fatal when it is not noticed, and adequate precautions are not taken. In our case, we wanted to report the protective effect of adding oral N-acetyl cysteine to quadruple (isoniazid, rifampicin, pyrazinamide, and ethambutol) TB treatment against recurrent hepatotoxicity that occurs during the treatment of TB.

**Keywords:** Children, hepatotoxicity, n-acetyl cysteine, treatment, tuberculosis.

## ORCID ID

EY : 0000-0003-2721-1353  
NAB : 0000-0002-5553-6123  
ÇN : 0000-0003-2187-4121



**Cite this article as:** Yetmiş E, Bayrak NA, Nuhoğlu Ç. Profilactic usage of N-acetyl cysteine in the treatment of tuberculosis in children may be effective in protection from hepatotoxicity: A case experience. Zeynep Kamil Med J 2021;52(4):202–205.

**Received:** July 11, 2021 **Accepted:** October 05, 2021 **Online:** November 01, 2021

**Correspondence:** Erkan YETMİŞ, MD. Türkiye Sağlık Bilimleri Üniversitesi, Haydarpaşa Numune Sağlık Uygulama ve Araştırma Merkezi, Çocuk Sağlığı ve Hastalıkları Kliniği, İstanbul, Turkey.

**Tel:** +90 538 294 42 68 **e-mail:** yetmis.erkam@gmail.com

© Copyright 2021 by Zeynep Kamil Medical Journal - Available online at [www.zeynepkamiledj.com](http://www.zeynepkamiledj.com)

## INTRODUCTION

Tuberculosis (TB) is one of the most important causes of morbidity and mortality worldwide. While 10.4 million new cases were seen in 2016, it is estimated that 1.7 million people died. The highest incidence was detected in Southeast Asia and Africa by The World Health Organization.<sup>[1]</sup>

Although a rare complication, drug-induced hepatotoxicity is associated with isoniazid (INH), rifampicin (RIF), and pyrazinamide (PZA), which are the first-line drugs used in TB chemotherapy.<sup>[2]</sup>

In cases; findings ranging from elevation in liver function tests, nausea, vomiting, anorexia, jaundice, abdominal pain accompanied, or a symptomatic disease characterized by fatal acute liver failure may be observed.<sup>[3,4]</sup> The diagnosis is made by excluding other causes of liver damage.<sup>[5]</sup>

## CASE REPORT

A 16-year-old male patient applied to us with cough and bloody sputum production. The patient's cough intensified in the last week and hemoptysis had begun to appear in the last few days. In the physical examination, respiratory sounds were slightly rough and there were occasional rhoncus. Our patient's mother died due to TB, and her older sister had received TB treatment for 6 months in 2019. In the primary laboratory tests we performed, there was no leukocytosis (5390/mm<sup>3</sup>), C-reactive protein 5.7 mg/dL (n:0–0.5), and erythrocyte sedimentation rate 60 mm/h (n:0–20 mm/h). The patient's serum albumin level 44.3 g/L (32–45), aspartate aminotransferase (AST) 15 IU/L (n:<35), alanine aminotransferase (ALT) 10 IU/L (n:<36), and renal function tests and electrolyte values were within normal limits. Urinalysis was normal. There was no obvious feature in the postero-anterior chest X-ray.

In the thoracic computed tomography requested in line with the family history and complaints of the patient, there was a cavitory area in the upper lobe of the left lung and increased alveolar density and peribronchovascular millimetric size reticulo nodular density increases and ground-glass appearances are observed in favor of TB disease in the posterior segment of the superior part of the left lung lower lobe (Fig. 1, 2). There was no reproduction in the blood culture, urine culture and sputum culture of our patient. Combined oropharyngeal swab COVID-19 PCR test was negative, mycobacterium PCR was positive in sputum, and ARB was negative in gastric fasting water 3 times. The patient's tuberculin skin test was negative, he had a BCG scar on his left shoulder. Quadruple anti-TB treatment (INH 1 × 300 mg, RIF 1 × 450 mg, PZA 2 × 500 mg, ethambutol 1 × 1000 mg) was started.

On the 7<sup>th</sup> day of the anti-TB treatment of our patient, his AST value was 554 IU/L, and his ALT value was 590 IU/L when he had abdominal pain, nausea, vomiting and anorexia. Prothrombin time was prolonged by 1.61 and activated partial thromboplastin time by 36 s. Gamma glutamyl transferase was normal. Anti-TB drugs were discontinued considering toxic hepatitis. The patient's enzymes decreased to normal levels 7 days later. There was no evidence of active disease in hepatitis A, B and C serology and anti-HIV, cytomegalovirus, rubella and Epstein-Barr virus scans sent from our patient. Serum alpha-fetoprotein level was normal. Oral ursodeoxycholic acid (UDKA) 20 mg/kg/day was started for the patient.

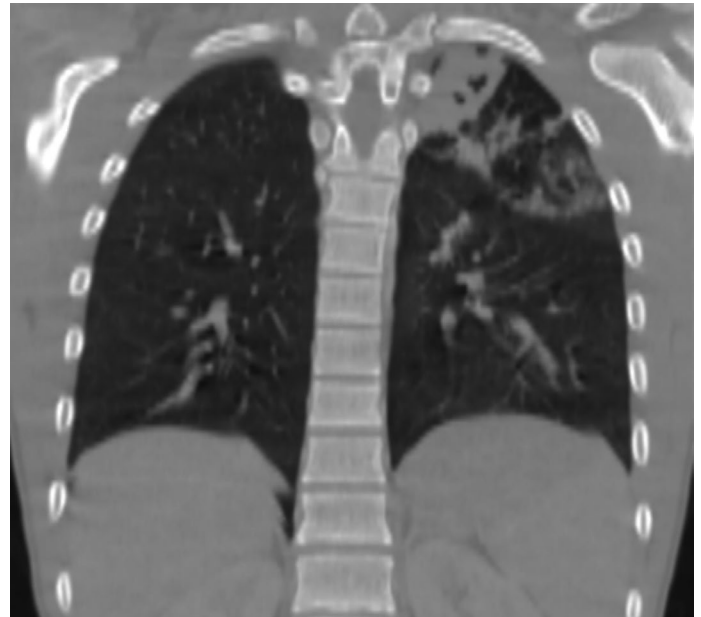


Figure 1: Cavitory area in the upper lobe of the left lung.

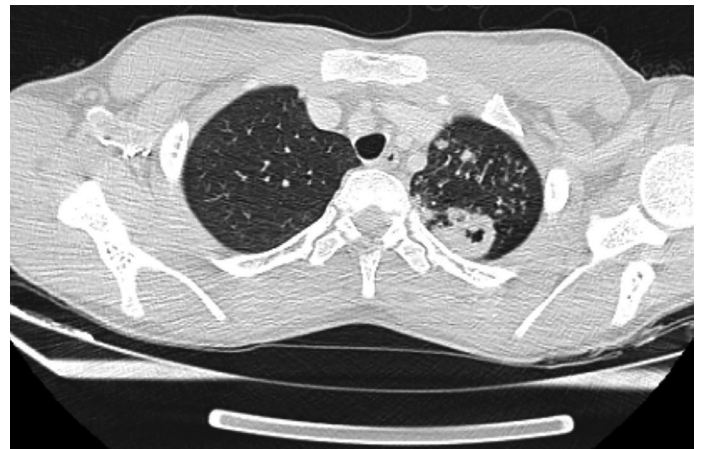

Figure 2: Increased alveolar density and peribronchovascular millimetric size reticulo nodular density increases and ground-glass appearances are observed in favor of Tuberculosis disease in the posterior segment of the superior part of the left lung lower lobe.

Anti-TB drugs were discontinued due to the increase in liver enzyme values on the 7<sup>th</sup> day of the patient's re-initiated anti-TB treatment. UDKA was also discontinued because there was no bile duct involvement. The patient's liver enzyme values decreased to normal levels on the following 8<sup>th</sup> day. Autoantibodies sent to exclude autoimmune hepatitis were negative. Serum alpha-1 antitrypsin level, ceruloplasmin, and IgG were normal. After the patient's liver enzyme values improved, oral N-acetyl cysteine (NAC) therapy was started on routine 20 mg/kg/day instead of a loading dose in addition to quadruple anti-TB drugs. The patient, who received anti-TB drug therapy for 2 months, received INH, RIF, and oral NAC therapy for another 4 months after 2 months. The patient used NAC treatment orally for 6 months. No toxic hepatitis picture developed again in the regular follow-ups during this period.

## DISCUSSION

One of the most important problems in TB treatment is drug tolerance and potential side effects. Problems caused by drugs show a broad spectrum from neurological symptoms, skin rash, and mild transaminase elevations to hepatic encephalopathy.<sup>[6]</sup> If the drug-induced toxic hepatitis picture is recognized and the drug is discontinued, hepatocellular damage is reversible and recovery without sequelae is observed.<sup>[7]</sup> INH, RIF, and PZA, which are indispensable three drugs in the first-line treatment regimen of TB, are hepatotoxic drugs and when used together, they increase each other's hepatotoxic effects.<sup>[8,9]</sup>

In the literature, it has been stated that poor nutritional conditions, low albumin, which is an indicator of chronic malnutrition, and the presence of additional diseases in the patient significantly increase the risk of hepatotoxicity during TB treatment.<sup>[10]</sup> It has been suggested that malnutrition also poses a risk for hepatotoxicity by affecting drug metabolism.<sup>[11]</sup> Hepatotoxicity often occurs during the 1<sup>st</sup> months of treatment. In an adult study, they reported that they observed elevated transaminases and the development of toxic hepatitis within the first 8 weeks of treatment.<sup>[9]</sup> While the period between the development of hepatotoxicity and the initiation of treatment ranges between 11 and 21 days in the literature, the time for transaminases to return to normal was between 11 and 18 days.<sup>[12,13]</sup> In our patient, the first transaminase increase was detected on the 7<sup>th</sup> day and the second on the 8<sup>th</sup> day. Transaminases had decreased to normal on the 7<sup>th</sup> day on both occasions after treatment was discontinued. The durations in our case are shorter than the literature information.

It has been reported that the rate of hepatotoxic reactions is much higher in developing countries such as India (8–39%) compared to Western countries (2–3%) with similar dosing schedules.<sup>[14]</sup> Since the antioxidant capacity of TB patients decreases, these patients have higher oxidative stress. The oxidative stress of TB patients in underdeveloped countries is higher than patients in developed countries. Especially low Vitamins A, C, and E, selenium and glutathione levels increase oxidative stress.<sup>[15,16]</sup> It has been reported that lack of food intake and malnutrition resulting from this in underdeveloped countries negatively affect the functioning of enzyme systems that are effective in drug metabolism in the liver.<sup>[2]</sup>

Toxic hepatitis picture has an important effect on the results of the treatment of TB patients.<sup>[17]</sup> Acute liver failure, ascites, and hepatic encephalopathy may develop in patients with some drug-induced liver damage (IBHD) or may present with only simple enzyme elevations. In a study conducted in China, it was shown that TB patients with IBHD have more than 9 times the risk of treatment failure and more than twice the risk of long-term intensive phase therapy exposure compared to those without IBHD.<sup>[17]</sup>

TB drugs cause a variety of adverse effects in TB patients, and oxidative stress plays a role in mediating these adverse effects. IBHD is one of the most important side effects of TB drugs and it is believed that oxidative stress plays a role in the development of this side effect.<sup>[18]</sup> TB patients have high oxidative stress due to the slow functioning of enzyme systems involved in the catabolism of the liver due to malnutrition and comorbidities, and they are prone to IBHD. Therefore, antioxidants can potentially reduce the negative effects caused by anti-TB drugs and facilitate recovery from TB.<sup>[19]</sup>

In animal experiments, the use of NAS together with INH and RIF was found to be protective against the hepatotoxic effects of these drugs.<sup>[20]</sup> In a randomized controlled study conducted on 60 adults in the adult age group, patients were given oral NAS therapy 2 × 600 mg/day. Although the rate of patients developing hepatotoxicity in the control group was 37%, no hepatotoxicity was observed in the group receiving oral NAS treatment.<sup>[21]</sup> In a study by Bhilare et al.<sup>[22]</sup> in rats, they showed that antioxidants such as NAS have a significant restorative effect on enzyme levels and biochemical parameters against INH-induced liver damage. Hepatoprotective effect of NAS includes suppression of oxidative stress, cell membrane stabilization, and strengthening of cellular antioxidant defenses.

Unfortunately, oral NAS therapy has not been emphasized enough in the literature to prevent possible hepatotoxic side effects that may occur during the treatment of TB in childhood. Although there are many studies on this subject in the adult age group, there is no similar study in the childhood age group. In this case report, we think that the use of 20 mg/kg/day prophylactic instead of oral NAC can prevent the hepatotoxic effects of TB treatment in childhood as well as in adults. Studies on this subject in large series with pediatric participation are needed.

## Statement

**Informed Consent:** Written, informed consent was obtained from the patient's family for the publication of this case report and the accompanying images.

**Peer-review:** Externally peer-reviewed.

**Author Contributions:** Concept – EY; Design – NAB; Supervision – ÇN; Resource – EY; Materials – EY; Data Collection and/or Processing – NAB; Analysis and/or Interpretation – ÇN; Literature Search – NAB; Writing – EY; Critical Reviews – EY.

**Conflict of Interest:** The authors have no conflict of interest to declare.

**Financial Disclosure:** The authors declared that this study has received no financial support.

## REFERENCES

- Collu C, Fois A, Crivelli P, Tidore G, Fozza C, Sotgiu G, et al. A case-report of a pulmonary tuberculosis with lymphadenopathy mimicking a lymphoma. *Int J Infect Dis* 2018;70:38–41.
- Ramappa V, Aithal GP. Hepatotoxicity related to anti-tuberculosis drugs: Mechanisms and management. *J Clin Exp Hepatol* 2013;3(1):37–49.
- Naqvi IH, Mahmood K, Talib A, Mahmood A. Antituberculosis drug-induced liver injury: An ignored fact, assessment of frequency, patterns, severity and risk factors. *Open J Gastroenterol* 2015;5(12):173–84.
- Yu YC, Mao YM, Chen CW, Chen JJ, Chen J, Cong WM, et al. CSH guidelines for the diagnosis and treatment of drug-induced liver injury. *Hepatol Int* 2017;11(3):221–41.
- Chalasanani NP, Hayashi PH, Bonkovsky HI, Navarro VJ, Lee WM, Fontana RJ. ACG clinical guideline: The diagnosis and management of idiosyncratic drug-induced liver injury. *Am J Gastroenterol* 2014;109(7):950–66.
- Tahaoğlu K. Tüberkülozda Tedaviye Yanıtın Takibi ve İlaç yan Etkileri, Tüberkülin, Koruyucu Tedavi, Temaslı Muayenesi. *Toraks Dernei Tüberküloz Çalışma Grubu. Toraks Derneği ikinci Yıllık Kongresi. Antalya 6-10 Mayıs 1998.* p. 58–68.
- Türkay C, Akbulut A. İlaça bağlı karaciğer hasarı. In: Özden A, Fiahin B, Yılmaz U, Soykan İ, editors. *Gastroenteroloji. Eylül: Türk Gastroenteroloji Vakfı; 2002.* p. 601–4.

8. Kocabaş A. Tüberküloz tedavisinde sorunlar. Kocabaş A, editor. Tüberküloz kliniği ve kontrolü. Adana: Çukurova Üniversitesi Basımevi; 1991. p. 315–33.
9. Riska N. Hepatitis cases in isoniasid treated groups and in a control group. Bull Int Union Tuber 1976;51(1):203–8.
10. Singla R, Sharma SK, Mohan A. Evaluation of risk factors for antituberculosis treatment induced hepatotoxicity. Indian J Med Res 2010;132:81–6.
11. Walter-Sack I, Klotz U. Influence of diet and nutritional status on drug metabolism. Clin Pharm 1996;31(1):47–64.
12. Baloğlu İ, Bahadır A. Tüberküloz tedavisi sırasında ortaya çıkan hepatotoksosite. Tüberküloz Toraks 1999;47:68–72.
13. Yurdakul AS, Çalşır HC, Taci N. Tüberküloz tedavisi sırasında gelişen hepatotoksosite. Toraks Derg 2003;4:16–20.
14. Singh JA, Garg PK, Thakur VS, Pade JN, Tandon RK. Anti -tuberculosis treatment- induced hepatotoxicity; role of predictive factors. Postgrad Med J 1995;71(836):359–62.
15. Madebo T, Lindtjorn B, Aukrust P, Berge RK. Circulating antioxidants and lipid peroxidation products in untreated tuberculosis patients in Ethiopia. Am J Clin Nutr 2003;78(1):117–22.
16. Muzembo BA, Mbendi NC, Ngatu NR, Suzuki T, Wada K, Ikeda S. Serum selenium levels in tuberculosis patients: A systematic review and meta-analysis. J Trace Elem Med Biol 2018;50:257–62.
17. Shang P, Xia Y, Liu F, et al. Incidence, clinical features and impact on anti-tuberculosis treatment of anti-tuberculosis drug induced liver injury (ATLI) in China. PLoS One 2011;6(7):e21836.
18. Devarbhavi H, Singh R, Patil M, Sheth K, Adarsh CK, Balaraju G. Outcome and determinants of mortality in 269 patients with combination anti-tuberculosis drug-induced liver injury. J Gastroenterol Hepatol 2013;28(1):161–7.
19. Ejigu DA, Abay SM. N-acetyl cysteine as an adjunct in the treatment of tuberculosis. Tuberc Res Treatment 2020;2020:5907839.
20. Attri S, Rana SV, Vaiphei K, Sodhi CP, Katyal R, Goel RC, et al. Isoniazid and rifampicin-induced oxidative hepatic injury-protection by N-acetylcysteine. Hum Exp Toxicol 2000;19(9):517–22.
21. Baniyasi S, Eftekhari P, Tabarsi P, Fahimi F, Raoufy MR, Masjedi MR, et al. Protective effect of N-acetylcysteine on antituberculosis drug-induced hepatotoxicity. Eur J Gastroenterol Hepatol 2010;22(10):1235–8.
22. Bhilare NV, Dhaneshwar SS, Mahadik KR. Amelioration of hepatotoxicity by biocleavable aminothiols chimeras of isoniazid: Design, synthesis, kinetics and pharmacological evaluation. World J Hepatol 2018;10(7):496–508.