

## Laparoscopic Management of a Unicornuate Uterus with Non-communicating Rudimentary Horn: Case Report

Cem Çelik<sup>1</sup>, Şevki Goksun Gökulu<sup>2</sup>, Nicel Taşdemir<sup>1</sup>, Remzi Abalı<sup>1</sup>, Erson Aksu<sup>1</sup>, Utku Doğan<sup>3</sup>

<sup>1</sup>Namık Kemal Üniversitesi Tıp Fakültesi, Kadın Hastalıkları ve Doğum Bölümü, Tekirdağ.

<sup>2</sup>Ümraniye Eğitim ve Araştırma Hastanesi, Kadın Hastalıkları ve Doğum Bölümü, İstanbul.

<sup>3</sup>Selçuk Üniversitesi Tıp Fakültesi, Kadın Hastalıkları ve Doğum Bölümü, Konya

### ÖZET:

#### **Nonkominikan Rudimente Korn ile Birlikte Olan Unikornuat Uterusun Laparoskopik Yönetimi:**

Nonkominikan Rudimente Korn ile Birlikte Olan Unikornuat Uterusun Laparoskopik olarak çıkarılması bildirilmektedir. Preoperatif tanı fizik muayene, pelvik ultrasonografi ve histerosalpingografi ile konmuştur. Hastaya Histeroskopi ve laparoskopi uygulanmış ve 24 saatte taburcu edilmiştir. Müllerian anomalilerin tanı ve tedavisinde histeroskopi ve laparoskopi kullanılması pelvik anatominin daha iyi görüntülenmesini, yapışıklıkların minimal olmasını, operasyon sonrası ağrının azaltılmasını ve postoperatif dönemin kısaltılmasını sağlar.

**Anahtar kelimeler:** Müllerian anomaliler, Laparoskopi, Histeroskopi

#### **İletişim Bilgileri**

**İlgili Doktor** : Cem Çelik,

**Yazışma Adresi** : Namık Kemal Üniversitesi, Kadın Hast. ve Doğum bölümü, Tekirdağ, Türkiye

**Tel** : +90 (282) 263 30 10

**Fax** : +90 (282) 263 31 11

**E-mail** : cemcel@yahoo.com

### ABSTRACT :

Laparoscopic removal of a unicornuate uterus with non-communicating rudimentary horn is reported. Preoperative diagnosis was made according physical examination, pelvic ultrasonography and hysterosalpingography. The patient underwent hysteroscopy and laparoscopy. The patient was discharged from hospital in 24 hours. Hysteroscopy and laparoscopy in diagnosis and treatment of Müllerian abnormalities advance visualization of the pelvic anatomy, cause minimal adhesion formations, reduce post-operative pain and shorten postoperative period.

**Key words:** Müllerian abnormalities, Laparoscopy, Hysteroscopy

## INTRODUCTION

Congenital uterine anomalies result from abnormal formation, incomplete fusion or resorption of the mesonephric ducts[1]. Simon et al. (1991) reported the incidence of the uterine anomalies in a fertile population to be around 3.2%[2]. Recent study reports the prevalence of uterine anomalies was 5.5% in the unselected population, 8% in infertile women, 13.3% in those with a history of miscarriage and 24.5% in those infertility and miscarriage [3]. According to the American Society of Reproductive Medicine in 1988, unicornuate uterus with noncommunicating rudimentary horn was classified as type 2b [4]. Renal anomalies as unilateral renal agenesis or pelvic kidney are related with this anomaly [5]. The frequency of pregnancy within a noncommunicating rudimentary uterine horn

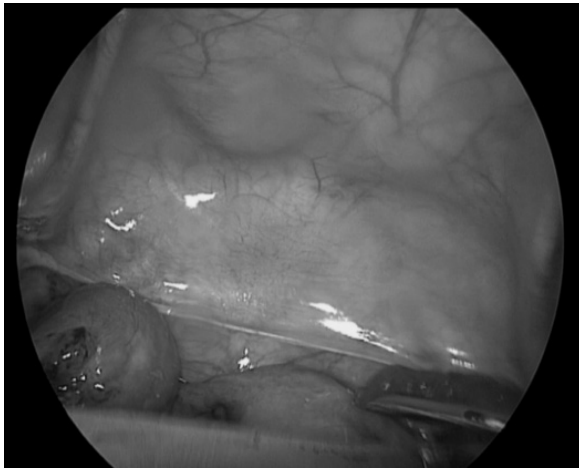
range between 1/76000 – 1/100000 [6,7]. We report the case of a laparoscopic removal of a unicornuate uterus with non communicating rudimentary horn.

## CASE

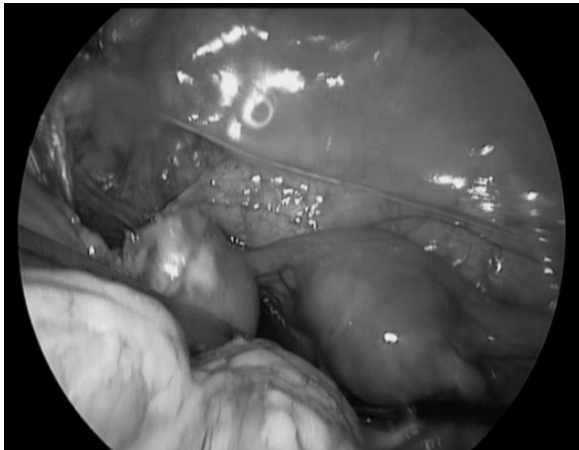
A 22-year-old infertile woman admitted to our department with a history of 4 recurrent miscarriages and 1 preterm stillbirth for the past 6 years during her marriage. Gynecologic examination revealed a normal vagina and cervix with a uterus in normal size, antevert and anteflex position. Pelvic ultrasonographic exam revealed two cavitated uterus with endometrium featuring didelphys uterus. No renal abnormalities were found. Hysterosalpingography was performed left fallopian tube could not be visualized. Antiphospholipid antibodies, lupus anticoagulant, an-

tithrombin autoantibodies and anti nuclear antibody markers were negatif. The patient underwent hysteroscopy and laparoscopy. Hysteroscopy showed a righth cornual ostium and one uterin cavity with no sign of ostium on the left side. Laparoscopy demonstrated right unicornuate uterus with normal right side adnexa, a left rudimentary noncommunicating horn with a normal size and shape left tube and ovary ( Fig. 1). The left rudimentary horn was attached to the unicornuate uterus by a two cm band of tissue (Fig. 2). Inspection revealed no endometriotic lesions (Fig. 3).

**Figure 1:** Noncommunicating horn with a normal size and shape left tube and ovary.



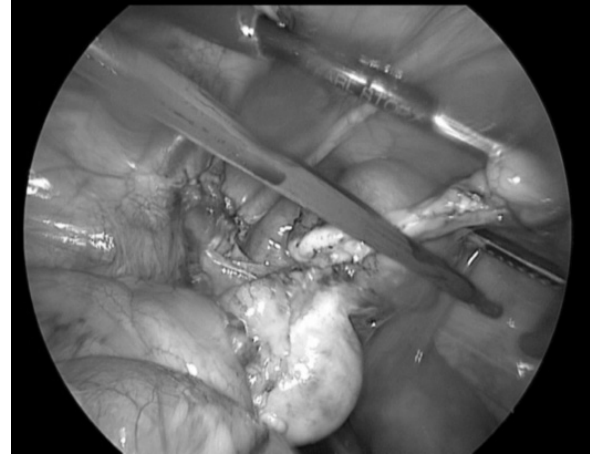
**Figure 2:** Laparoscopic view of Unicornuate uterus by a two cm band of tissue.



Left round ligament and left utero-ovarian ligament were coagulated and transected by bipolar cautery ( Fig. 2,3). The course of ureter was identified by the section of anterior and posterior leaf of the broad ligament . Left salpingectomy was started at fimbriated end (Fig. 3). The band of tissue was coagu-

lated with bipolar cauter. Rudimentary horn and left tuba finally cut by bipolar scissors and removed using a morcellator. Pathological examination showed a normal sized fallopian tube, uterin cavity with proliferated endometrium and no endometriosis. The patient was discharged from hospital in 24 hours.

**Figure 3:**View of Left salpingectomy..



## DISCUSSION

Unicornuate uterus is one of unification defects such as bicornuate and didelphic uteri. Unicornuate uterus is due a failure of one mullerian duct to migrate normal place. According to the American Society of Reproductive Medicine, a unicornuate uterus with a noncommunicating rudimentary horn belongs to group 2-b[4]. This subtype of anomaly is about 1/1000 in unselected population [3,8]. It is more common with patient with a history of miscarriage (0.5%), infertility (0.5%) and miscarriage in association with infertility(3.1%) [3]. The obstetrical complications of this anomaly are variable in different studys, abortion rate (43.8%), pre-term delivery(25%), live birth (43.7%) and term pregnancy rate(31.3%) [8]. Reichman found (20.1%) preterm delivery, (32%) abortion rate[9]. Ectopic pregnancy (22%) and unilateral renal agenesis(38%) also common in this anomaly[10]. Pregnant uterin horn rupture is an other commen problem during pregnancy according to the thin myometrial tissue of rudimentary horn [6,10]. About 75%-92 rudimentary horn cases are non-communicating [11, 12]. For this reason endometriosis is frequently seen in these cases by retrograde menstruation[6]. This anomaly

is commonly reported on the right side of the uterus(62%-80%), where else we report a left sided case [13].

Sensitivity of ultrasound examination for diagnosis was 26% . Diagnosis before clinical symptoms occurred in 14% [11]. Magnetic resonance imaging, three- dimensional sonography and urography are used for accurate diagnosis of mullerian abnormalities[ 14,15] . laparoscopic resection of rudimentary uterin horn has become the standart treatment of this type mullerian abnormalities to prevent ectopic pregnancy and endometriosis. We used downward dissection technique of the tube ,starting at the fimritated end. Ureter was also identified . The transection of the fibrous band allowed dissection and coagulation of the uterin artery, this provides minimal blood loss, smilar to the literature results. Anatomical varition in rudimentary horn directs the choice of the surgical technique. Rudimentary horn may firmly atatched to the unicornute uterus or it may be atatched by a band of tissue. Dissection of the firmly atatched unicornute uterus is not easy because there is no pedicle.Developing a plane between unicornuate uterus and rudimantary horn with using electrocauter and scissors my prevent heavy bleeding and compromise of myometrial integrity(15). Hysteroscopic transillumination can be used to prevent myometrial damage in this type(16). We used downward dissection from fimrited end ,detected the ureter and coagulated the fibroid band tissue without unicornute uterus damage. In conclusion, our report demonstrates that using hysteroscopy and laparoscopy in diagnosis and treatment of müllerin abnormalities have advantages such as; advance visualization of the pelvic anatomy, minimal adhesion formations, reduced post operative pain and shorter postoperative period.

#### KAYNAKLAR

1. Moore KL, Persaud TVN, Torchia MG. *The Urogenital System. Before We Are Born: Essential of Embryology and Birth Defects*, 7th edn, Philadelphia: Saunders/Elsevier, 2008, 162–189.

2 . C.simon, L. Martinez, F.Pardo, M. Tortajada and A. Pellicer, “Mullerian defects in women with normal reproductive outcome,” *Fertility and sterility*, vol. 56, no. 6, pp. 1192-1193, 1991.

3. Y.Y. Chan, K. Jayaprakasan, J. Zamora, J.G. Thornton, N. Raine-Fenning, and A. Coomarasamy, “The prevalence of congenital uterine anomalies in unselected and high-risk populations: a systematic review,” *Human Reproduction Update*, Vol.17, No.6 pp. 761–771, 2011

4. *The American Fertility Society. The American Fertility Society Classification of adnexal adhesions, distal tubal occlusion, tubal occlusion secondary to tubal ligation, tubal pregnancies, Mullerian anomalies and intrauterine adhesions. Fertil Steril* 1988; 49:944–55.

5. F.F.Marshall and D.S.Beisel, “ The association of uterin and renal anomalies, ” *Obstetrics and Gynecology*, vol. 51, no. 5, pp 559-562, 1978

6. Atmaca R, Tezcan Germen A ,Burak F, and Kafkasli A, “ Acute Abdomen in a Case With Noncommunicating Rudimentary Horn and Unicornuate Uterus, ” *JSLs*. 2005 Apr-Jun; 9(2): 235–237.

7. Lidia RosiMedeiros, Daniela Dornelles Rosa, Fabio Rosa Silva, Bruno Rosa Silva, and Maria Ines Rosa, “Laparoscopic Approach of a Unicornuate Uterus with Noncommunicating Rudimentary Horns,” *ISRN Obstetrics and Gynecology* 2011; 2011:906138. Epub 2010 oct 7

8. Francisco Raga, Celia Bauset, Jose Remohi1, Fernando Bonilla-Musoles1, Carlos Simo'n, and Antonio Pellicer1, “Reproductive impact of congenital Mullerian anomalies, ” *Human Reproduction* vol.12 no.10 pp.2277–2281, 1997

9 Reichman D, Laufer MR, Robinson BK. *Pregnancy outcomes in unicornuate uteri: a review. Fertil Steril* 2009; 91:1886–94.

10. Heinonen PK, “Unicornuate uterus and rudimentary horn,” *Fertil Steril.* 1997 Aug;68(2):224-30.
11. Jayasinghe Y, Rane A, Stalewski H, Grover S. “ The presentation and early diagnosis of the rudimentary uterine horn. ” *Obstet Gynecology* 2005 Jun;105(6):1456-67
- 12.V.C. Buttram Jr. And W.E. GibsonS “ Mullerian anomalies : a proposed classification (an analysis of 144 cases), ” *Fertility and sterility*, vol.32 , no. 1, pp 40-46, 1979
13. Fedele L, Bianchi S, Zanconato G, Berlanda N, Bergamini V. “ Laparoscopic removal of the cavitated noncommunicating rudimentary uterine horn: surgical aspects in 10 cases” *Fertil Steril.* 2005 Feb;83(2):432-6.
14. Perrotin F, Bertrand J, Body G, “Laparoscopic surgery of unicornuate uterus with rudimentary uterine horn. *Human Reproduction* vol.14 no.4 pp.931–933, 1999
15. Falcone T, Gidwani G, Paraiso M, et al “ Anatomical variation in the rudimentary horns of a unicornuate uterus : implications for laparoscopic surgery ” *Human Reproduction* vol.12 no.2 pp.263–265, 1997
16. Nezhat, F., Nezhat, C., Bess, O. et al. (1994) *Laparoscopic amputation of a non communicating rudimentary horn after a hysteroscopic diagnosis: a case study. Surg. Laparosc. Endosc.*4, 155–156