

TRICEPS TENDON RUPTURE

Case Report

TRİSEPS TENDON KOPMASI

Prof. Dr. Faik ALTINTAŞ

*Yeditepe University Hospital Department of
Orthopaedics and Traumatology İstanbul / Turkey*

Dr. Onur KOCADAL

*Yeditepe University Hospital Department of
Orthopaedics and Traumatology İstanbul / Turkey*

Dr. Ayberk ÖNAL

*Yeditepe University Hospital Department of
Orthopaedics and Traumatology İstanbul / Turkey*

Corresponding Author

Prof. Dr. Faik ALTINTAŞ

*Yeditepe Üniversitesi Hastanesi Ortopedi ve
Travmatoloji A.D
İletişim adresi: Yeditepe Üniversitesi Hastanesi
Devlet Yolu Ankara Cad. No: 102/104 34752
Kozyatağı- İstanbul
Tel: 0216 5784000 / 4046 e-posta:
f.altintas@superonline.com*

ÖZET

Triseps tendon rüptürü nadir görülen bir tendon yaralanmasıdır. Genellikle genç yaş grubunda ve erkeklerde kadınlara oranla sık görülür. Yaralanma ekstansiyondaki dirseğin ani fleksiyonu ile veya direkt travma sonucu oluşabilir. Parsiyel yırtıklar konservatif olarak tedavi edilebilirken, komplet yırtıklarda ve elit sporcular gibi yüksek beklentideki hastalarda cerrahi tedavi endikasyonu bulunmaktadır.

Sağ Triseps tendon yırtığı ve avülsiyon kırığı olan olguya posterior yaklaşımla, fiber wire kullanılarak tendon tamiri yapılmış ve breys içinde hareketlere başlanmıştır.

Travma sonucu oluşan yırtıklarda cerrahi tedavinin uygun bir yöntem olduğu sonucuna varılmıştır.

SUMMARY

Rupture of triceps tendon is a rare tendon injury and generally seen in young adults and males. This injury can be seen after direct or indirect trauma with or without underlying predisposing factors like over use, diabetes mellitus etc. Partial ruptures can be treated conservatively, but total ruptures and partial ruptures of athletes or patients with high demands should be treated surgically. We repaired total triceps tendon rupture and avulsion fracture of a 43 year old woman (direct trauma and no underlying factors) and applied an elbow brace at 110 degrees of flexion after surgery. By our experience and as reported in literature, surgical repair of total triceps tendon rupture is a successful treatment method.

INTRODUCTION

The triceps brachii muscle has medial, lateral and long head components, and its tendon begins about the middle of the muscle. Triceps brachii is a strong elbow extensor and is innervated by N. Radialis. The circumstances usually necessary to

produce a rupture of triceps tendon are a fall on the outstretched hand with elbow held in incomplete extension with or without a concomitant blow to the posterior aspect of the elbow. Generally american football players and weight bearing athletes have this type of tendon injury. Overuse, diabetes mellitus, corticosteroid usage and renal insufficiency can predispose this injury. Partial ruptures could be treated conseratively, but total ruptures and ruptures of athletes or patients with high demands must be operated. Postoperative rehabilitation program is important for the treatment and near perfect results after surgical treatment is reported.

CASE PRESENTATION

43 year old woman who fall from horse on her outstreched hand with elbow held in incompate extension with concomitant blow to her elbow from posterior. Pain with palpation, ecchymosis, swelling, lack of tendon tension and active extension was reported in physical examination. She had full supination and pronation. In XRAY an MRI, avulsion fracture at the olecranon tip was seen, and tendon rupture was seen in MRI. No predisposing factors were reported.

Surgical technique; patient was positioned at decubitus lateralis and a pneumatical tourniquet was used. A posterior approach to distal humerus and olecranon was used to reach the tendon. There was no tendon continuity at the attachment site (**Figure 1**).

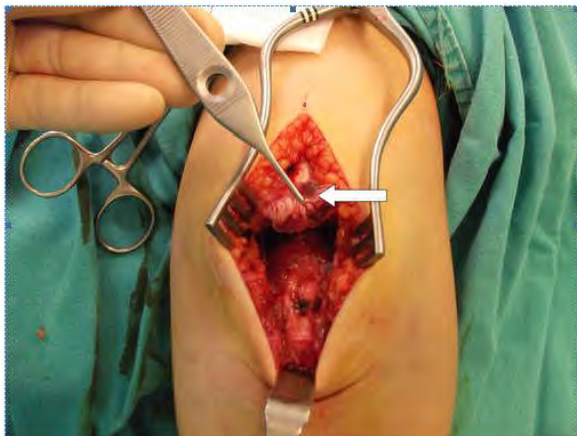
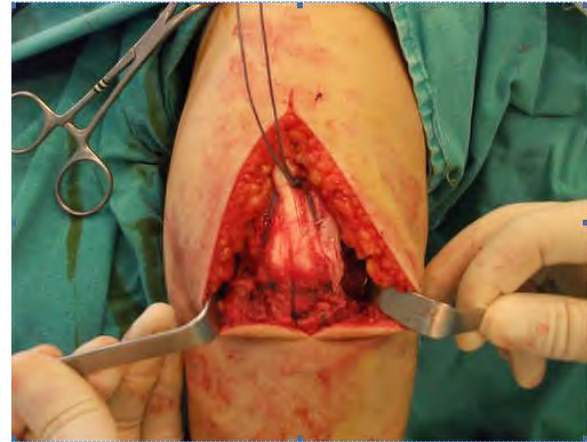


Figure 1: Complet rupture of Triceps tendon and avulsion fracture at the triceps tendon attachment site of olecranon.

to olecranon and avulsed olecranon fragman was seen at the end of tendon. Olecranon was drilled with a 2mm drill and No 5, round fiberwire was passed through the tunnel, then through tendon for repair and distal end was attached to olecranon with additional vicryl sutures (**Figure 2**).



After the operation, an elbow brace at 110 degrees flexion was applied.

DISCUSSION

Rupture of triceps tendon is a rare tendon injury . (2) In a study with 1019 tendon injury, only 9 triceps tendon injury was reported. (3) This injury was described by Patridge first time. (4) Generally seen in young adults (3. decade) and males. Generaly there is a concomitant avulsion fracture of olecranon at the attachment site of tendon. Our patient has had a concomitant avulsion fracture too. This injury can be seen after corticosteroid injection for olecranon bursitis. (5) Kennedy and Willis described that, corticosteroids can lead to collagen necrosis and can predispose triceps tendon injury after repetative injections. (6) Usage of anabolic steroids was described as a rick factor. (7) Other predisposing factors are; hyperparathyroidism, renal insufficiency, diabetes mellitus and overuse. High parathyroid serum levels in patients with

renal insufficiency can depolymerize the bone matrix and increase osteoclastic activity that can cause dystrophic calcifications in muscles so leads weakening of musculotendinous attachments. Acidosis after chronic renal insufficiency can cause elastosis that can lead weakening of musculotendinous attachments too. (8) But our patient has had no predisposing factors.

Lack of active elbow extension or painful elbow extension, gap at tendon attachment site, lack of tendon tension and positive modified thompson test should alert physician for triceps tendon rupture. Further investigations like XRAY, MRI can be used. MRI can show the location and grade of the rupture so helps deciding treatment method. Furthermore, predisposing factors and other pathologies can be detected with MRI too.

Grade of rupture is the major factor in treatment choice. (11) Partial ruptures can be treated conservatively, but ruptures more than %50 of tendon width or if severe lack of muscle strength is seen in examination, the treatment option should be surgery. Near perfect results after surgical treatment is reported. (1)

The surgery technique for this injury is described as drilling olecranon and fixing the tendon with the sutures passing through the tunnels. We used this technique by adding absorbable sutures to attachment site. (12).

Levy reported that, full ROM could be achieved 6 weeks after surgery in their study with 9 patients who undergo surgery for triceps tendon rupture. (13). 3 weeks of immobilization after surgery is suggested. Active flexion could be done with ROM limiting braces. (14). After 3 months, triceps tendon will retrieve preinjury strength. After soft tissue healing, rehabilitation with isometric exercises should begin. We applied a brace to our patient too. Surgical treatment of triceps tendon rupture is a

successful method for gaining preinjury functions.

REFERENCES

- 1) Strauch RJ. Biceps and triceps injuries of the elbow. *Orthop Clin North Am* 1999;30:95-107.
- 2) Anderson RL. Traumatic rupture of the triceps tendon. *J Trauma* 1979;19:134.
- 3) Anzel SH, Coney KW, Weiner AD, et al. Disruption of muscles and tendons: an analysis of 1014 cases. *Surgery*. 1959;45:406-414.
- 4) R Partridge, A case of rupture of the tendon of the triceps cubiti. *Med Times Hosp Gaz* 1 (1868), pp. 176-186.
- 5) Clayton ML, Thirupathi R. Rupture of the triceps tendon with olecranon bursitis. *Clin Orthop*. 1984;184:183-185.
- 6) Kennedy JC, Willis RB. The effects of local steroid injections on tendons: a biomechanical and microscopic correlative study. *Am J Sports Med*. 1976;4:11-21.
- 7) Bach BR Jr, Warren RF, Wickiewicz TL. Triceps rupture, a case report and literature review. *Am J Sports Med*. 1987;15:285-289.
- 8) 2. Clayton ML, Thirupathi RG. Rupture of the triceps tendon with olecranon bursitis. A case report with a new method of repair. *Clin Orthop* 1984;(184):183-5.
- 9) Viegas SF. Avulsion of the triceps tendon. *Orthop Rev*. 1990;19:533-53.
- 10) Gaines ST, Durbin RA, Marsalka DS. The use of magnetic resonance imaging in the diagnosis of triceps tendon ruptures. *Contemp Orthop*. 1990;20:607-611.
- 11) Farrar EL 3rd, Lippert FG 3rd. Avulsion of the triceps tendon. *Clin Orthop* 1981;(161):242-6.
- 12) Levy M, Goldberg I, Meir I. Fracture of the head of the radius with a tear or avulsion of the triceps tendon. *J Bone Joint Surg*. 1982;64B:70-72.
- 13) Levy M(1987) Repair of triceps tendon avulsions or ruptures. *J Bone Jt Surg* 69B:115.
- 14) Rupture of the triceps brachii tendon: a case report Cem Zeki Esenyel, Kahraman Ozturk, Ozgur Ortak, Ayhan Nedim Kara *Acta Orthopaedica et Traumatologica Turcica* 2003;37(2):178-181.