

VASOVAGAL SYNCOPE AND CARDIAC ARREST DURING URINARY CATHETER REMOVAL: A CASE REPORT

Case Report

ÜRİNER KATETER ÇEKİLMESİ SIRASINDA VAZOVAGAL SENKOP VE KARDİAK ARREST: OLGU SUNUMU

Murat Haliloglu

Yeditepe University Hospital, Department of Anesthesiology .

Neslihan Uztüre

Yeditepe University Hospital, Department of Anesthesiology .

Hatice Türe

Yeditepe University Hospital, Department of Anesthesiology.

Ozge Koner

Yeditepe University Hospital, Department of Anesthesiology

Corresponding Author:

Murat Haliloglu

Yeditepe University Hospital, Department of Anesthesiology , Istanbul/Turkey.

e-mail: murat.haliloglu@yeditepe.edu.tr

ABSTRACT

This case report presents a patient who experienced a vasovagal syncope and cardiac arrest during urinary catheter removal. Pain and phobic stress can result in bradycardia, hypotension, syncope and even cardiac arrest in susceptible individuals. Appropriate treatment for vasovagal syncope includes the administration of intravenous fluids, vagolytics, ephedrine, and the rapid use of the Trendelenburg position. Here we discuss the management of our patient.

Key Words: Vasovagal syncope; Cardiac arrest.

ÖZET

Bu olguda, üriner kateter çekilmesi sırasında yaşanan vazovagal senkop ve kardiyak arrest sunulmaktadır. Duyarlı kişilerde ağrı ve fobik stres, bradikardi, hipotansiyon, senkop ve hatta kardiyak arrestte neden olabilir. Vazovagal senkop için uygun tedavi intravenöz sıvı uygulaması, vagolitikler, efedrin ve hızlıca Trendelenburg pozisyonu verilmesidir. Bu olgu sunumunda, hastamızın tedavisini tartıştık.

Anahtar kelimeler: Vazovagal senkop; Kardiyak arrest.

INTRODUCTION

Vasovagal syncope is a clinical disorder that is often not taken seriously by either patients or physicians. However, this condition may be serious and syncope due to unexplained causes has been associated with a 6% mortality rate (1). In our case, the patient experienced cardiac arrest after a transsphenoidal clivus chordoma extraction surgery due to vasovagal syncope during removal of an urinary catheter.

CASE REPORT

A 45-yr-old otherwise healthy male patient (weight 76 kg, height 168 cm) underwent transsphenoidal clivus

chordoma extraction. After the operation, he was transferred to the intensive care unit (ICU). The postoperative arterial blood gas analysis, complete blood count, electrolyte, and coagulation tests were within normal limits.

The patient's blood pressure (BP) was 140/59 mm Hg, SpO₂ 98% and the heart rate was 76 bpm. Right after the removal of the urinary catheter, the patient felt dizzy; at the same time the ECG changed from a normal sinus rhythm (66 bpm) to deep bradycardia and finally to asystole (**Fig-1**).

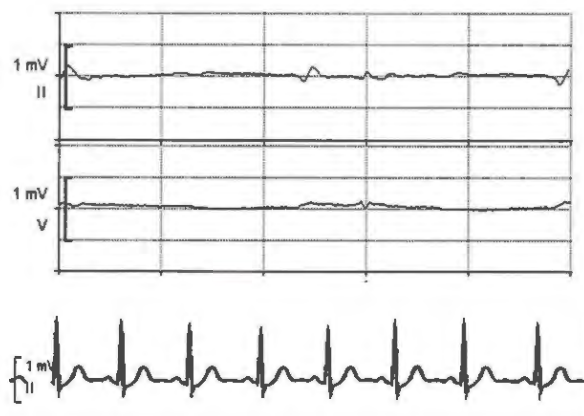


Fig-1. Electrocardiogram showing 1, Asystole. 2, Normalized electrocardiogram after asystole.

The patient became pale and unresponsive, then his eyeballs were deviated upwards, and finally collapsed. Atropine 1 mg iv was administered during the deep bradycardia period. Despite atropine, analysis of the ECG revealed an asystole period of 22-seconds. Before initiating the cardiopulmonary resuscitation, atrioventricular dissociative rhythm was observed in the ECG, followed by a normal sinus rhythm. Few seconds after regaining spontaneous ECG activity, the patient gained consciousness. The arterial blood gas analysis, complete blood count, electrolyte, coagulation tests, Troponin I levels, computed tomography imaging after the cardiac arrest were normal. Also, the ECG and chest X-ray showed no abnormality. He did not have any neurologic deficits or incontinence.

After 24 hours of ICU follow-up, the patient was transferred to the general ward and discharged from the hospital without any complications after 4 days.

DISCUSSION

Vasovagal response is the most common mechanism of syncope. Central triggers such as severe pain, anxiety, fear, and emotional stress during medical procedures may cause syncope and hemodynamic collapse (2,3). In the majority of subjects vasovagal responses are mild or moderate and generally spontaneously reversible. However severe vasovagal response occasionally results in death (4,5). Vasovagal response which is characterized by an inappropriate combination of bradycardia and paradoxical vasodilation can be caused by variety of mechanisms (6). In case of severe fear or pain, vasovagal response that is mediated by direct hypothalamic activation of the medullary cardiovascular center, results in vasodilation, decreased brain blood flow, hypotension, bradycardia, asystole, and fainting (7).

In our case, a few seconds after removing the catheter the patient complained of nausea and discomfort. Bradycardia with asystole occurred immediately thereafter. Pain and phobic stress at the time of pulling the catheter out may have triggered an increase in parasympathetic tone, resulting in bradycardia with asystole and hypotension. Vasovagal syncope which may be precipitated by intense emotional experience occurs most commonly in healthy young men. Vasovagal syncope rarely occurs in supine position, but in our case vasovagal syncope occurred while the patient was supine (8).

Vasovagal syncope can be treated by the administration of IV fluids, vagolytics, or epinephrine and the rapid use of the Trendelenburg or head-down position (9,10). The patient was treated by fluid administration and atropine. Although atropine has been used to treat vagally

mediated bradycardia, it may not prevent hypotension caused by vasodilation (11). During vasovagal syncope, hypotension may persist after the relief of bradycardia by atropine. We used initial dose of 1 mg of atropine and it was very effective for bradycardia and asystole. After the bradycardia was relieved, the hypotension was also improved. Ephedrine can be used to counteract the vasodilation, but α -agonist should be considered for persistent hypotension (11). External cardiac massage must be initiated for persisting cardiac arrest after prompt treatment with epinephrine (11). Our patient was recovered from asystole without the need of epinephrine or cardiac massage.

In this case, we wanted to share our experience on a patient with severe vasovagal cardiac arrest, during urinary catheter removing that occurred after a transsphenoidal clivus chordoma extraction surgery. To our knowledge, this is the first case report in Turkey documented the vasovagal cardiac arrest, during urinary catheter removal.

REFERENCES

- 1) Wolfe DA, Grubb, Kimmel SR. Head-upright tilt test: a new method of evaluating syncope. *Am Fam Physician* 1993;47:149-59.
- 2) Hart PS, Yanny W. Needle phobia and vasovagal syndrome. *Anaesthesia* 1998;53 : 1002-4.
- 3) McConachie I. Vasovagal asystole during spinal anesthesia. *Anaesthesia* 1991; 46: 281-2.
- 4) Engel GL. Psychologic stress. Vasodepressor (vasovagal) syncope, and sudden death. *Ann Intern Med* 1978;89:403-12.
- 5) McIntosh MD. The stabilizing and unstabilizing influences of neurogenic and vascular activities of the heart as related to sudden cardiac death. *J Am Coll Cardiol* 1985;5:105-10.
- 6) Lewis T. Vasovagal syncope and the carotid sinus mechanism with comments on Gower's and Nothnagel's syndrome. *British Medical Journal* 1932; I: 873-6.
- 7) Fenton AM, Hammil SC, Rea RF, Low PA, Shen WK. Vasovagal syncope. *Ann Intern Med* 2000;133:714-25.

8) Verill PJ, Aelling WH. Vasovagal faint in the supine position. *Br Med J* 1970;7:348.

9) Mackey DC, Carpenter RL, Thompson GE, Brown DL, Bodily MN. Bradycardia and asystole during spinal anesthesia: a report of three cases without morbidity. *Anesthesiology* 1989;70:866-8.

10) Caplan RA, Ward RJ, Posner K, Cheney FW. Unexpected cardiac arrest during spinal anesthesia: a closed claims analysis of predisposing factors. *Anesthesiology* 1988;68:5-11.

11) Kinsella SM, Tucky JP. Perioperative bradycardia and asystole: relationship to vasovagal syncope and Bezold-Jarisch reflex. *Br J Anaesth* 2001;86:859-68.