

## Gastrointestinal Involvement of Behcet's Disease

### Case Report

## Behçet Hastalığının Gastrointestinal Tutulumu

### Olgu Sunumu

Fevzi Firat Yalniz, Resident

*Yeditepe University Hospital, Department of Internal Medicine, Istanbul*

Baki Ekci, Assist. Prof.

*Yeditepe University Hospital, Department of General Surgery, Istanbul*

K.Muhammed Nuri, MD

*Cerrahpaşa Medical School, Department of General Surgery, Istanbul*

Mehmet Çağlıkülekcı, Prof. Dr.

*Yeditepe University Hospital, Department of General Surgery, Istanbul*

### Corresponding Author

Baki Ekci, Assist. Prof.

*Yeditepe University Hospital, Department of General Surgery, Istanbul*  
*E-mail: [bekci@yeditepe.edu.tr](mailto:bekci@yeditepe.edu.tr)*

### ABSTRACT

Behcet was a Turkish dermatologist who first described the triad of relapsing iridocyclitis with recurrent oral and genital ulcerations in 1937. The gastrointestinal manifestations of Behcet's disease (BD) have become recognized as a distinctive type of Behcet's syndrome called intestinal Behcet's syndrome. We describe a rare case of Behcet's disease with rectal ulcer and discuss the difficulties in making a differential diagnosis between Behcet's disease and the inflammatory bowel diseases.

**Keywords:** Behcet Disease, Gastrointestinal involvement

### ÖZET

Behçet hastalığının klasik triadı sayılan tekrarlayan oral ve genital ülserasyonlar, tekrarlayan iridosiklit bir Türk dermatoloğu olan Hulusi Behçet tarafından ilk olarak 1937 yılında tanımlanmıştır. Hastalık gastrointestinal sistemi lokal veya difüz olarak tutabilir. Biz bu yazımızda klinikte ender olarak rastlanılan, rektal ülserli bir Behçet hastasını ayırıcı tanıları ile taktim ediyoruz.

**Anahtar Kelimeler:** Behçet Hastalığı, Gastrointestinal tutulum

## INTRODUCTION

Collagen vascular diseases are known to present with gastrointestinal (GI) manifestations. Some of collagen vascular diseases that have well described GI involvement include lupus erythematosus, scleroderma, amyloidosis in rheumatoid arthritis, and Behçet disease (1). We describe a rare case of Behçet's disease with rectal ulcer and discuss the difficulties in making a differential diagnosis between Behçet's disease and the inflammatory bowel diseases.

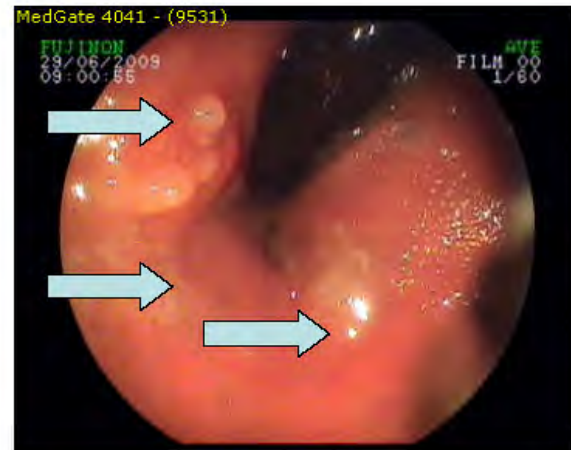
## CASE

39 year's old female patient presented to our clinic complaining of severe perianal pain with rectal hemorrhage following defecation. Ten months ago, she was evaluated for similar problems and anal fissure was diagnosed at that time. According to her past medical history, she had the diagnosis of Behçet's disease, based on recurrent oral and genital ulcers accompanied by relapsing iridocyclitis, two years ago. At the time of hospital admission, she was taking colchicine 0.5mg three times daily.

On physical examination, her blood pressure, pulse and respiratory rates were 90/60 mmHg, 100/min and 20 breaths/min, respectively. On her digital rectal examination, a solid lesion 1-2cm proximal to the anal verge was palpated.

As an initial diagnosis, we consider gastrointestinal involvement of Behçet's disease. Consequently she was referred to the gastroenterology department. A colonoscopy was performed and biopsy taken from mass lesion (fig 1) On microscopic examination there was non-specific surface ulcerations of the mucosa with granulation tissue and massive inflammatory cell infiltration rich in neutrophils and lymphocytes. After three days of treatment with sulphasalazine 500 milligrams two times a day and 1mg/kg methylprednisolone orally, her symptoms

relieved and the patient discharged under medical treatment with oral methylprednisolone 40 milligrams a day and sulphasalazine 500 milligrams two times daily.



**Figure 1:** Rectal ulcer

## DISCUSSION

Behçet's syndrome is a multisystem disorder presenting with recurrent oral and genital ulcerations as well as ocular involvement. Ulcers are usually painful, shallow or deep with a central yellowish necrotic base and are the mainstay for the diagnosis.

The disease is more frequent among people living around the Mediterranean area, Middle East, Far East and in Japan. (2). Turkey is the country with the highest prevalence of the disease, estimated between 20 and 420 per 100.000, whereas in Japan it is 0.99-30.5 per 100.000, and the prevalence in the UK and USA is estimated at 0-2.5 per 100.000(3,4,10). The mean age of onset is 30 years. Males and females are affected equally, but males often have more severe disease (5).

The etiology and pathogenesis of this syndrome remain obscure; however common histopathological lesion of all clinical manifestations appears to be a vasculitis. Although there is no information supporting the role of a single

microorganism as the specific etiologic agent, several microorganisms have been implicated in the etiology of BD, especially herpes simplex virus-1 and *Streptococcus sanguis* (6,7). The relationship between microbial antigens [heat shock proteins (HSP), lipoteichoic acid (LTA)] and immune mechanisms such as innate and adaptive responses against microorganisms are also discussed (8) but no relation has been proved yet. The presence of autoantibodies so lymphocyte sensitization to mucosal antigen has been observed but the precise significance of these findings in relation to the pathogenesis of the disease is presently undetermined.

Although HLA-B51 has not been shown to affect the severity of symptoms, the syndrome is associated with this alloantigen in endemic areas (9). A high frequency (about 80%) of both pathergy test positivity and HLA-B51 were encountered in patients from Japan and the Mediterranean countries including Turkey, in contrast to patients in the United Kingdom and the USA (10). In a study of tumor necrosis factor (TNF) polymorphisms, HLA-B5701 was associated with disease susceptibility in Caucasians from the United Kingdom (11).

Behcet disease could manifest as skin, ocular, neurologic, renal, arthritic, gastrointestinal and vascular involvement. The gastrointestinal manifestations of Behcet's syndrome have become recognized as a distinctive type of Behcet's syndrome and called intestinal Behcet's syndrome. GI involvement may affect all areas from the lips to the anus. The ulcers are most commonly found in the terminal ileum and the caecum (75% of patients) and less frequently in the colon, sparing the rectum (3%) in contrast to the ulcerative colitis (12,13).

BD involves the gastrointestinal tract in 10%-50% of patients, and gastrointestinal symptoms, such as nausea, vomiting and abdominal pain can sometimes occur, but the presence of intestinal ulceration is rare

(< 1%) (14). Bowel wall thickening is the most common finding on computed tomography (CT) scan. In our patient, a biopsy specimen revealed non-specific surface ulcerations of the mucosa with granulation tissue and massive inflammatory cell infiltration (15). Surgery may be required for perforation (21). The most common symptoms are abdominal pain that can be colicky, nausea, vomiting, diarrhea with or without blood in the stool, and constipation and it usually appear 4.5-6 years after the onset of the oral ulcers (16). The intestinal lesions of BD occur in two forms, mucosal inflammation and ischemia/infarction. Behcet disease causing massive hemorrhage was reported in the literature (17,18). In our patient, endoscopy showed minimal oozing hemorrhage from the ulceration and it did not necessitate invasive therapy. The clinical presentation of intestinal BD is similar to that of inflammatory bowel disease such as Chron's disease, which shares many extraintestinal features such as oral lesions, uveitis, and arthritis. Differential diagnosis are seen in table 1 (10).

Rectal and anal involvement is quite rare in Behcet's disease (7). Morphologically, rectal ulcers are aphthous ulcers (common), deep round or oval ulcers. Recurrent ulceration of the stoma is a relatively common complication, as is recurrence of disease adjacent to or at the surgical anastomosis. Most of these recurrent ulcers appear within two years of the resection. There are very few reports on the long term prognosis of intestinal BD (19). The disease has a variable course characterized by relapses and remissions, it needs therapy and prognosis depends on the clinical involvement. Loss of visual acuity and neurological disease are major causes of morbidity and disability. Relieving symptoms, achieving a rapid resolution of inflammation, preventing or limiting tissue damage, reducing frequency and severity of attacks, and avoiding complications are main goals of treatment. Corticosteroids, azathioprine, cyclophosphamide,

cyclosporine A, interferon-alpha, anti-tumour necrosis factor alpha agents are most available drugs (10,20). Corticosteroids represent the major therapeutic agent, but as stated in the Brodie and Ochsner's study, corticosteroid therapy may cause perforation (21). Our patient was successfully treated with oral corticosteroid treatment.

**Table 1:** Differential diagnosis (10)

Reiter's syndrome  
Sarcoidosis  
HSV infection  
Syphilis  
Multiple sclerosis  
Seronegative arthropathies  
Stevens–Johnson syndrome  
Familial Mediterranean fever  
Vogt-Koyanagi–Harada syndrome  
Sweet's syndrome  
Recurrent aphthous stomatitis  
Celiac disease  
Inflammatory bowel disease (Crohn's disease, Ulcerative colitis)  
Bullous skin disorders  
Systemic lupus erythematosus  
Erythema multiforme  
Mixed connective tissue diseases

## CONCLUSION

Behcet's disease involves the gastrointestinal tract in 10%-50% of patients. The clinical presentation of intestinal BD is similar to that of inflammatory bowel disease such as Crohn's disease or ulcerative colitis; therefore the differential diagnosis is challenging. It can involve all areas from lips to anus but rectal involvement is quite rare.

In conclusion, this relapsing condition necessitates careful follow up in order to detect any later complications or reactivation. This report describes a rare condition about BD.

## REFERENCES

- 1) Takahashi H, Ohara M, Imai K. Collagen diseases with gastrointestinal manifestations. *Nihon Rinsho Meneki Gakkai Kaishi*. 2004;27:145-55
- 2) Tunes RS, Amorim R, Santiago MB. Clinical aspects of Behcet's syndrome in Brazil: a review of 16 cases. *Acta Reumatol Port*. 2009;34:235-40.
- 3) Azizlerli G, Kose AA, Sarica R et al. Prevalence of Behcet's disease in Istanbul, Turkey. *Int J Dermatol* 2003;42:803-6.
- 4) Zouboulis CC, Kotter I, Djawari D et al. Epidemiological features of Adamantiades-Behcet's disease in Germany and in Europe. *Yonsei Med J* 1997;38:411-422.
- 5) Haralampos M. Moutsopoulos Harrison's principles of internal medicine, 16th ed, McGraw-Hill Companies, 2005, pp 2014-2015.
- 6) Lehner T. The role of heat shock protein, microbial and autoimmune agents in the aetiology of Behcet's disease. *Int Rev Immunol* 1997;14:21-32.
- 7) Direskeneli H. Behcet's disease: infectious aetiology, new autoantigens, and HLA-B51. *Ann Rheum Dis* 2001;60:996-1002.
- 8) Mumcu G, Inanc N, Yavuz S, Direskeneli H. The role of infectious agents in the pathogenesis, clinical manifestations and treatment strategies in Behcet's disease. *Clin Exp Rheumatol*. 2007;25:S27-33.
- 9) Mendes D, Correia M, Barbedo M, Vaio T, Mota M, Gonçalves O, Valente J. Behcet's disease--a contemporary review. *J Autoimmun*. 2009;32:178-88.
- 10) Yazici H, Chamberlain M A, Tuzun Y, Yurdakul S, Muftuoglu A M. A comparative study of the pathergy reaction among Turkish and British patients with Behcet's disease. *Ann Rheum Dis* 1984; 43: 74-5
- 11) Ahmad T, Wallace GR, James T, Neville M, Bunce M, Mulcahy-Hawes K, et al. Mapping the HLA association in Behcet's disease a role for tumor necrosis factor polymorphisms? *Arthritis Rheum* 2003;48:807-13.
- 12) Kasahara Y, Tanaka S, Nishino M, Umemura H, Shiraha S, Kuyama T. Intestinal involvement in Behcet's disease: review of 136 surgical cases in the Japanese literature. *Dis Colon Rectum* 1981;24: 103-6.
- 13) Shimizu T, Ehrlich G E, Inaba G, Hayashi K. Behcet's disease (Behcet's syndrome). *Semin Arthritis Rheum* 1979;8:223-60.
- 14) Kasahara Y, Tanaka S, Nishino M, Umemura H, Shiraha S, Kuyama T. Intestinal involvement in

*Behçet's disease: review of 136 surgical cases in the Japanese literature. Dis Colon Rectum 1981; 24: 103-106*

15) Ebert EC. *Gastrointestinal manifestations of Behçet's disease. Dig Dis Sci. 2009;54:201-7*

16) Bayraktar Y, Ersan O, David VT. *Gastrointestinal Manifestations of Behçet's Disease. Journal of Clinical Gastroenterology 2000;30:144-154*

17) Fujita H, Kiriya M, Kawamura T, Ii T, Takegawa S, Dohba S, Kojima Y, Adachi H, Morimoto H, Kobayashi A, Watanabe K. *Massive hemorrhage in a patient with intestinal Behçet's disease: report of a case. Surg Today. 2002;32:378-82.*

18) Hong YK, Yoo WH. *Massive gastrointestinal bleeding due to the rupture of arterial aneurysm in Behçet's disease: case report and literature review. Rheumatol Int. 2008;28:1151-4.*

19) Dowling CM, Hill AD, Malone C, Sheehan JJ, Tormey S, Sheahan K, McDermott E, O'Higgins N. *Colonic perforation in Behçet's syndrome. World J Gastroenterol 2008;14:6578-80*

20) Gul A. *Standard and novel therapeutic approaches to Behçet's disease. Drugs 2007;67:2013-22.*

21) Brodie TE, Ochsner JL. *Behçet's syndrome with ulcerative oesophagitis: report of the first case. Thorax 1973;28:637-640.*