

## Adductor Insertion Avulsion Syndrome (Thigh Splints): Diagnosis With MRI Follow-Up Case Report

## Adductor İnsersiyon Avulziyon Sendromu (Thigh Splints): MR Görüntüleme ile Ayırıcı Tanı Olgu Sunumu

Neslihan Taşdelen, MD

Yeditepe University, Faculty of Medicine,  
Department of Radiology

Faik Altıntaş, MD

Yeditepe University, Faculty of Medicine  
Department of Orthopaedics and Traumatology

Bengi Gürses, MD

Yeditepe University, Faculty of Medicine  
Department of Radiology

H.Duygu Kara, MD

Yeditepe University, Faculty of Medicine  
Department of Radiology

N.Özgür Kılıçkesmez, MD

Yeditepe University, Faculty of Medicine  
Department of Radiology

A.Nevzat Gürmen, MD

Yeditepe University, Faculty of Medicine  
Department of Radiology

### Corresponding Author

Neslihan Tasdelen, MD

Yeditepe University Hospital  
Department of Radiology  
Kozyatagi / Istanbul / Turkey  
E-mail: [ntasdelen@yeditepe.edu.tr](mailto:ntasdelen@yeditepe.edu.tr)

### ABSTRACT

Abductor insertion avulsion syndrome which is also known as thigh splints is a traction periostitis of the abductor muscles and may cause hip or leg pain. In this report MRI findings of this entity is described with a review of the related literature. But the main diagnostic criteria should be the follow-up of MRI findings with conservative therapy

**Key words:** Adductor insertion avulsion syndrome, Thigh splints, MRI

### ÖZET

Addüktör İnsersiyon Avulziyon Sendromu ("thigh splints") addüktör kasların traksiyon periostiti olup kalça ve bacak ağrılarına neden olmaktadır. Bu sunumda sendromun MR bulguları ile yayınlanmış diğer literatürler tanımlanmıştır. Ana diyagnostik kriter MR bulgularının takibi ve konservatif tedavi ye alınan yanıt olmalıdır.

**Anahtar kelimeler:** Addüktör İnsersiyon Avulziyon Sendromu, Thigh Splints, MRG

## INTRODUCTION

Adductor insertion avulsion syndrome which is described as mid-diaphyseal periostitis (thigh splints), affecting the insertion of the adductor muscle of the thigh. The tension on adductor muscles causes periosteal elevation along the posteromedial cortex and was first described in trainees in army (1). It is similar to shin splints, which involves the tibia at the site of attachment of soleus (2). Correct diagnosis by imaging methods is important because unnecessary surgical interventions may occur. In this report, we present a 10-year old boy who was diagnosed as adductor insertion avulsion syndrome, on the basis of clinical and radiological findings.

## CASE REPORT

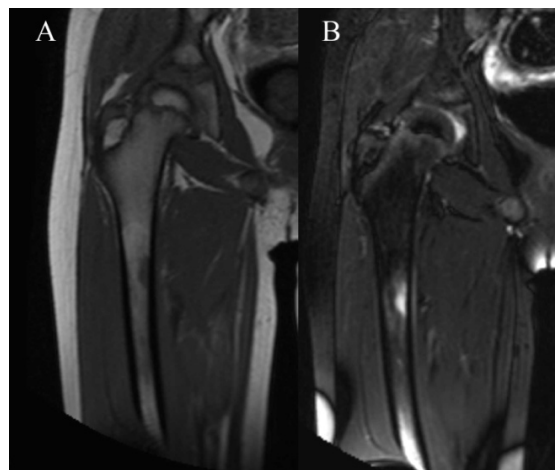
A 10 year-old boy presented with a history of right thigh and hip pain after exercise. Physical examination and laboratory findings were normal. The pain did not have a diurnal variation and was partially relieved by rest.

The conventional radiographs of pelvis, right femur and lumbar vertebra were normal. Magnetic resonance imaging of right hip joint was performed on a 3T MRI scanner (Intera Achieva, Philips, NL) using SENSE Torso coil. Coronal T1-weighted (Field of view (FOV 380 mm, repetition time (TR) 423 ms, echo time (TE) 10 ms, slice thickness 3,5 mm), axial fat-saturated T2 weighted (FOV 295 mm, TR 7389 ms, TE 62 ms, slice thickness 3,5 mm), coronal T2 weighted (FOV 380 mm, TR 3454 ms, TE 80 ms, slice thickness 3,5 mm), sagittal fat-saturated proton density (FOV 230 mm, TR 5178 ms, TE 30 ms, slice thickness 3,5 mm) images were obtained. After IV gadolinium injection, fat-saturated T1- weighted axial (FOV 420 mm, TR 609 ms, TE 10 ms, slice thickness 3,5 mm) and coronal (FOV 420 mm, TR 609 ms, TE 10 ms, slice thickness 3,5 mm) images were acquired. On T1 weighted images a hypointense area was observed on posteromedial

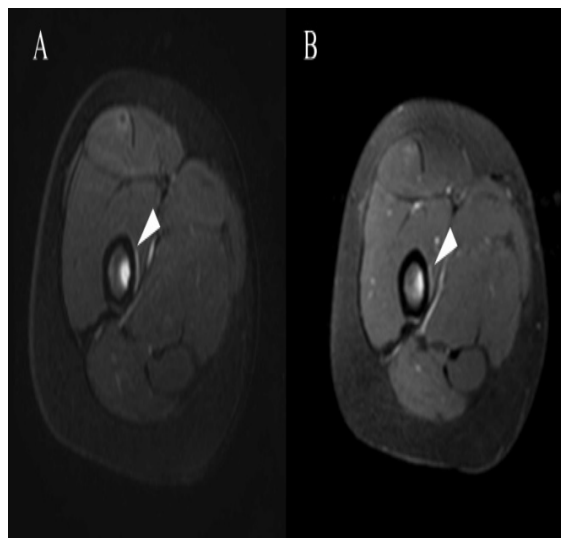
aspect of the femoral shaft which showed hyperintensity on fat-saturated T2 weighted images (Figure 1). On axial images of T2 weighted fatsaturated and contrast-enhanced T1 weighted fat saturated sequences revealed a thin rim of hyperintensity along the the periosteum and the medulla (Figure 2). There was no cortical destruction, erosion or abnormal signal within the cortex. Computed tomography (CT) images also showed no abnormality (Figure 3).

On the basis of clinical data, CT and plain radiograph findings, the findings on MR images were interpreted as focal bone marrow edema with periosteal reaction due to the avulsion of adductor muscles at the insertion on femoral diaphysis.

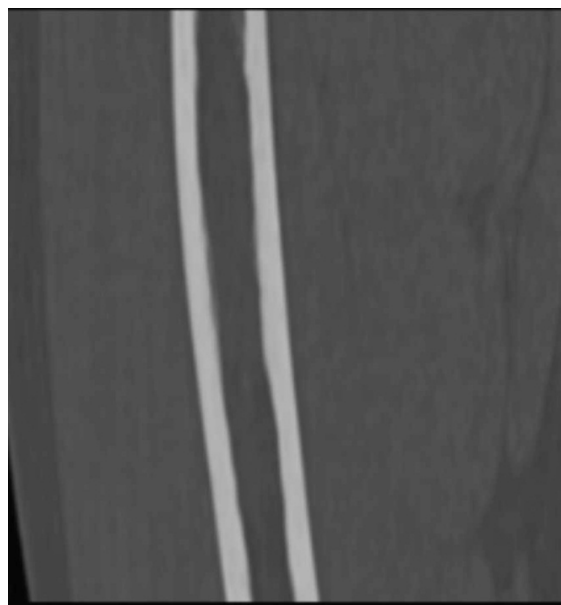The patient was instructed to rest and treated with conservative therapy. On the 3rd month follow-up MRI showed totally regression of the findings, confirming the diagnosis (Figure 4).



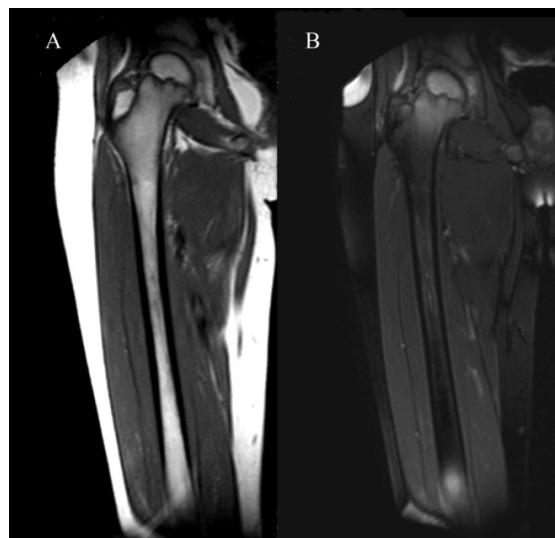
**Figure 1:** On the femoral diaphysis focal hypointensity is seen on T1W coronal image (A) which is hyperintense on fat saturated T2W coronal image (B).



**Figure 2:** On axial plane, periosteal (arrowhead) and medullary hyperintensity is demonstrated on fat saturated T2W (A) and contrast-enhanced fat saturated T1W (B) images.



**Figure 3:** There was no lucency with cortical erosion or destruction on coronal-reformatted CT image.



**Figure 4:** 3rd month follow-up MRI demonstrated complete regression of abnormal signal changes on T1W (A) and fat saturated T2W (B) sequences.

## DISCUSSION

Increased or unaccustomed activities may lead to abnormal stresses on bone. Also repetitive avulsive stresses at tendinous insertions on a bone may lead to a traction periostitis at these sites. According to the type and severity of these stresses, the response of bone may change from a periosteal reaction to a stress fracture (3, 4). The most well-known traction periostitis is shin splints which involves soleus tendon insertion on mid-tibia. Plain radiographs are mostly normal but sometimes they may demonstrate periosteal reaction. Typical scintigraphic finding is elongated foci of increased uptake along the tibia. MRI may show periosteal edema and abnormal signal intensity in the medullary cavity or the cortex (2,3). Also a similar condition is described in the upper extremity at the deltoid tendon insertion (5).

Thigh splints is another entity identical to shin splints except for the location. It involves the insertion of adductor muscles on posteromedial diaphysis of the femur. Clinically, these patients show exercise-related hip or leg pain which is relieved at rest. Radiographs and CT may reveal periosteal reaction along mid-diaphysial

femur but mostly they are normal as seen in our case. MRI and scintigraphy findings is typical and diagnostic. On scintigraphy linear attenuation may be seen medial aspect of femoral diaphysis (1,6). Anderson SE et al and Anderson MW et al retrospectively reviewed MRI findings which may be summarized as periosteal edema, abnormal signal intensity in the medullary cavity or cortex (3,7). In our patient also medullary hyperintensity and periosteal edema was present at the adductor insertion, similar to the literature. In addition to the literature, we also observed contrast enhancement at the periosteum and the medullary part of the bone in which edema exists.

These findings represent early periostitis which occurs after partially muscle avulsion. Many authors believe that this syndrome represents an early phase of fatigue reaction which may develop a stress fracture if not recognized (3, 4). But the differential diagnosis of this entity may include osteomyelitis and tumor especially Ewing's sarcoma, osteogenic sarcoma and eosinophilic granuloma. Absence of bone destruction and soft tissue mass may help to exclude these diagnoses (3,7). But follow-up with conservative therapy should be a part of this diagnostic process. In a report of Tshering-Vogel et al a patient with chronic osteomyelitis was presented who initially diagnosed as thigh splints with MRI findings (8). In our patient, whole findings seen on MRI was absent on control MRI study obtained on 3rd month.

As these patients usually represent with hip pain, in the evaluation of hip MRI femur becomes important. For this purpose, the field-of-view of the study should be enough to see the femoral diaphysis. Also the radiologist should take care not only the hip structures but also the femur which may contain described changes on the distal edge of the image obtained.

In conclusion, thigh splints is a traction periostitis involving the mid-femoral

diaphysis which may reveal medullary and periosteal edema as presented in this report. But the main diagnostic criteria should be the disappearance of the findings on follow-up of the patient with conservative therapy.

## REFERENCES

- 1) Charkes ND, Siddhivarn N, Schneck CD. Bone scanning in the adductor insertion avulsion syndrome ("thigh splints"). *J Nucl Med.* 1987;28(12):1835-8
- 2) Anderson MW, Ugalde V, Batt M, Gacayan J. Shin splints: MR appearance in a preliminary study. *Radiology.* 1997;204(1):177-80.
- 3) Anderson MW, Kaplan PA, Dussault RG. Adductor insertion avulsion syndrome (thigh splints): spectrum of MR imaging features. *AJR Am J Roentgenol.* 2001;177(3):673-5.
- 4) Lawande MA, Sankhe S, Pungavkar SA, Patkar DP. Adductor insertion avulsion syndrome with stress fracture of femoral shaft: MRI findings. *Australas Radiol.* 2007;51 Spec No.:B104-6.
- 5) Donnelly LF, Helms CA, Bisset GS 3rd. Chronic avulsive injury of the deltoid insertion in adolescents: imaging findings in three cases. *Radiology.* 1999;211(1):233-6
- 6) Singh AK, Dickinson C, Dworkin HJ et al. Adductor insertion avulsion syndrome. *Clin Nucl Med.* 2001;26(8):709-11
- 7) Anderson SE, Johnston JO, O'Donnell R. MR Imaging of sports-related pseudotumor in children: mid femoral diaphyseal periostitis at insertion site of adductor musculature. *AJR Am J Roentgenol.* 2001;176(5):1227-31
- 8) Tshering-Vogel D, Waldherr C, Schindera ST et al. Adductor insertion avulsion syndrome, "thigh splints": relevance of radiological follow-up. *Skeletal Radiol.* 2005 Jun;34(6):355-8.