

# Evaluation of the relationship between an impacted mandibular third molar and the inferior alveolar canal using cone-beam computed tomography

## Mandibular gömülü üçüncü molar dişler ile mandibular kanal arasındaki ilişkinin dental volümetrik tomografi ile değerlendirilmesi

**Dt. Mohammed Ghazı Allan Salahaldın**  
Istanbul University Faculty of Dentistry, Department of Oral Surgery, İstanbul

**Dr. Öğr. Üyesi Berkem Atalay**  
Istanbul University Faculty of Dentistry, Department of Oral Surgery, İstanbul

**Received:** 12 February 2018

**Accepted:** 26 July 2018

**doi:** 10.5505/yeditepe.2018.40326

### Corresponding author:

Dr. Berkem Atalay  
Istanbul Üniversitesi Diş Hekimliği Fakültesi Çene Cerrahisi A.D. Zemin Kat 34093, Fatih, İstanbul, Türkiye  
Tel: 905425812099  
E-mail: berkematalay@gmail.com

### SUMMARY

**Aim:** Protection and preservation of the inferior alveolar nerve are very important during oral surgery; therefore, the anatomical course should be identified precisely before surgical interventions. Cone-beam computed tomography (CBCT) can provide accurate, high-resolution images in limited regions thus can be used to locate the pathway of the inferior alveolar canal (IAC) and its relation to the other anatomical structures.

**Materials and Methods:** This retrospective study included 100 patients who referred to İstanbul University, Faculty of Dentistry, Department of Oral and Maxillofacial Surgery between November 2015-March 2016. Panoramic radiograph and CBCT were taken for each participant to evaluate impacted mandibular third molar (IMTM). The cases were classified, according to the anatomical relationship between the mandibular third molars and the IAC on panoramic radiograph and CBCT. Data were compared using the Tukey test.

**Results:** When the IMTM and IAC were examined, it was determined that in 62 cases IAC was closer than 1 mm and in 28 cases the distance was between 1-2 mm. IAC and teeth did not associate in 10 cases where the distance was more than 2 mm. Our findings showed that the IAC descended from the retromolar region to the molar region and ascended to the premolar region. The buccal bone is thicker in the molar region, whereas the lingual bone is thicker in the premolar region.

**Conclusion:** CBCT is useful before oral and maxillofacial surgery procedures to avoid inferior alveolar nerve injury.

**Key words:** Panoramic radiography, Cone-beam computed tomography, Impacted mandibular third molar, Oral surgical complications, Inferior alveolar nerve, Tooth Extraction.

### ÖZET

**Amaç:** Oral cerrahide inferior alveolar sinirin korunması çok önemlidir; Bu nedenle, anatomik pozisyonu, cerrahi müdahalelerden önce kesin olarak tanımlanmalıdır. Konik ışınlı bilgisayarlı tomografi (KİBT), sınırlı bölgelerde doğru yüksek çözünürlüklü görüntüler sağlayabilir, böylece inferior alveolar kanalın (İAK) yolunu ve diğer anatomik yapılarla ilişkisini bulmak için kullanılabilir.

**Gereç ve Yöntem:** Bu retrospektif çalışmaya İstanbul Üniversitesi Diş Hekimliği Fakültesi Oral ve Maksillofasiyal Cerrahi Anabilim Dalı'na Kasım 2015-Mart 2016 tarihleri arasında başvuran 100 hasta dahil edildi. Her bir katılımcıdan mandibular üçüncü molar dişlerin değerlendirilmesi için panoramik radyografi ve KİBT alındı. Olgular mandibuler üçüncü molar dişleri ile panoramik radyografi ve KİBT'deki İAK arasındaki anatomik ilişkiye göre sınıflandırıldı. Veriler, Tukey testi kullanılarak karşılaştırıldı.

**Bulgular:** Mandibular üçüncü molar diş ve İAK incelendiğinde, İAK'nın 62 olguda 1 mm'den daha yakın olduğu ve 28 olguda mesafenin 1-2 mm arasında olduğu saptanmıştır. Mesafenin 2 mm'den fazla olduğu 10 olguda İAK ve dişler birbirine karışmamıştır. Bulgularımız İAK'nın retromolar bölgeden

molar bölgeye indiğini ve premolar bölgeye çıktığını gösterdi. Bukkal kemik molar bölgede daha kalın iken, lingual kemik, premolar bölgede daha kalındır.

**Sonuç:** KIBT, inferior alveolar sinir hasarını önlemek için oral ve maksillofasial cerrahi işlemlerden önce yararlıdır.

**Anahtar kelimeler:** Panoramik radyografi, konik ışınli bilgisayarlı tomografi, gömülü mandibular üçüncü molar, oral cerrahi komplikasyonları, inferior alveolar sinir, diş çekimi.

## INTRODUCTION

Extraction of impacted mandibular third molar (IMTM) teeth is one of the most commonly implemented operations in oral surgery. Damage to the inferior alveolar nerve (IAN) is a severe complication associated with jaw surgery and may result in temporary or permanent sensory loss in the lower lip, depending on the level of the damage. The IAN can be damaged during extraction of the IMTM teeth, dental implant surgery, mandibular osteotomy, and other surgeries, such as apicoectomy, which involve surgery at the root apex. Given the close relationship between IMTMs and the inferior alveolar canal (IAC), and the scope of the surgical technique, the nerve may be damaged during extraction of the IMTM teeth and may result in a sensory loss in the lower lip.<sup>1</sup>

The IAC is a curved structure; its highest position is in the retromolar area, then it descends to the molar region, ascends at the premolar region, and ends in the mental foramen; the mental nerve extends further to the cheek.<sup>2</sup> The IAN may be injured during extraction of the mandibular third molar, which often results in severe complications for the patient.<sup>3,4</sup> The resulting complications are closely related to the anatomical proximity of the IAN, the patient's age and systemic condition, the morphology of the third molar roots, magnitude of the curvature, and the surgical technique used for removing the impacted third molar.<sup>5-8</sup> Many studies have recommended preoperative imaging approaches, such as panoramic radiography, periapical radiography, or cone-beam computed tomography (CBCT), prior to surgical removal of an impacted mandibular third molar.<sup>9-12</sup>

Many methods have been described for the evaluation of the relative position between the mandibular third molar and the IAC on panoramic radiography and computed tomography. Three-dimensional computed tomography (3D-CT) may be ideal for evaluation of the close relationship between the third molars and the IAC, as it provides a three-dimensional view.<sup>13,14</sup>

Many studies have reported that the proximity of the third molars to the IAC is an essential factor for determination of the risk of IAN damage after surgical extraction of the mandibular third molar.<sup>15-18</sup> In this study, we evaluated the usefulness of 3D-CT for the prevention of IAN damage du-

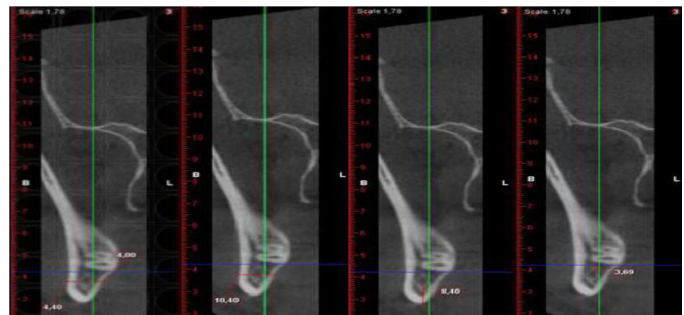
ring surgical removal of mandibular third molars by determining their proximity to the IAC.

## MATERIALS AND METHODS

This retrospective study included 100 patients who were older than 20 years of age and referred to İstanbul University, Faculty of Dentistry, Department of Oral and Maxillofacial Surgery between November 2015-March 2016.

Patients > 20 years of age and whose mandibular canal and IMTM teeth were visible on their radiographs were included in this study. Patients < 20 years of age, and those who had pathologies of the mandible, such as cysts, tumors, osteomyelitis, mandibular fractures, asymmetry of the mandible, blurry tomography images due to movement during tomography, or images without adequate resolution, were excluded.

All extractions were performed by oral and maxillofacial surgeons at İstanbul University Dental Hospital. Before planning treatment, we examined the teeth via dental volumetric tomography to detect the relationship between the IMTM teeth and anatomical landmarks on panoramic radiographs (especially the radiolucency of the apexes of the roots or/and narrowing in the mandibular canal), in order to avoid complications during or after oral surgery. All panoramic radiography and dental volumetric tomography were performed using the Planmeca 3D (Planmeca, Helsinki, Finland), the i-CAT (Imaging Sciences International, Hatfield, PA, USA), and the Soredex Scanora® 3DX (Soredex, Tuusula, Finland). (Figure 1). To determine the positions of the third molars, Pell-Gregory and Winter classifications were used.<sup>19,20</sup>



**Figure 1.** The distance between the mandibular third molar and the inferior alveolar canal was measured using the Pi-view program. A dot was placed on each molar and the adjacent IAC; then the shortest distance between the dots was measured on the coronal 3D-CT image. (a,b) Mandibular third molar root to IAN distance, >2 mm; (c,d) Mandibular third molar root to IAN distance, < 2 mm.

The variance of the mandibular canal diameter at distinct mandibular regions in different age groups (21–30 years, 31–40 years, and 41–57 years) was studied in 3D-CT images, which were obtained at a single radiology center and stored in the archives. Measurements were taken where the mandibular canal was the largest in the buccolingual and the premolar areas. The was measured from the highest point of the IAC in the retromolar region down

to the third molar tooth, and then up to the premolar region was measured using 3D-CBCT.

Data were analyzed using Tukey's test; a  $p$ -value  $< 0.05$  was considered significant.

## RESULTS

All cases in this study were classified according to the anatomical relationship between the mandibular third molars and the IAC on panoramic radiographs and 3D-CT imaging (Table 1). A total of 56 patients had an intact lingual bone; 44 patients did not. Patients were classified according to the third molar impaction from the second molar, as follows: 31 patients had third molar position A; 44 had molar position B, and 25 had molar position C. The total number of cases according to the ramus class was as follows: class I, 32; class II, 42; class III, 26.

**Table 1.** Impacted third molar morphology according to panoramic radiographs and 3D-computed tomography images

Impacted third molar	Percentage (n = 100)
Root development 1/3 completed	8
Root development 1/2 completed	7
Root development completed	85
One root	25
Two roots	75
Three roots	0
Vertical	54
Horizontal	5
Distoangular	4
Mesioangular	37
Position A	31
Position B	44
Position C	25
Class I	32
Class II	42
Class III	26

Of the 100 cases in our study, root formation was one-third complete in 8% of IMTMs, one-half complete in 7% of IMTMs, and complete in 85% of IMTMs. A total of 75% of teeth had 2 roots, while 25% had only a single root. In the sagittal view, it could be seen that 54% of IMTMs were

vertical, 37% were mesioangular, 5% were horizontal, and 4% were in a distoangular position.

In 62% of patients, the distance between the IAC and the lower third molar was 0–1 mm; in 28% the distance was 1–2 mm, and in 10% the distance was  $> 2$  mm. The IAC passed between the roots of the IMTM in 2 cases, buccally in 5 cases, lingually in 42 cases, and inferiorly in 51 cases. The IAN, the lingual nerve, and lingual cortex integrity were preserved in cases where the IAC was lingual to the teeth or between the roots (44%).

The thickness of the lingual bone decreased posteriorly, while the thickness of the buccal bone increased in premolar region, 2.34 ( $\pm 0.89$ ) mm; molar region, 1.98 ( $\pm 0.44$ ) mm; retromolar region, 2.15 ( $\pm 0.50$ ). The diameter of the IAC ranged from 1.32 to 4.1 mm; the mean diameter was 2.5 ( $\pm 0.6$ ) mm throughout the mandible in the patients overall. The height of the inferior bone under the IAC in the premolar area was 11.22 ( $\pm 4.8$ ) mm; in the molar area it was 6.89 ( $\pm 1.66$ ) mm, and in the retromolar area, it was 15.57 ( $\pm 5.05$ ) mm. The mandibular canal diameters of patients aged 21–30 years and 41–57 years showed significant differences ( $p < 0.05$ ), while that of patients aged 31–40 years did not differ significantly from the other 2 groups ( $p > 0.05$ ).

## DISCUSSION

In our study, both panoramic radiography and 3D-CT were performed to evaluate the anatomical relationship between the mandibular canal and the mandibular third molar, and to compare vertical alveolar bone measurements using digital panoramic radiographs and 3D-CBCT. The relationship between the lower third molar tooth and the inferior alveolar canal was identified, and the buccolingual bone thickness was determined. The buccal bone thickness increased, and the lingual bone thickness decreased from the premolar to the molar region, as reported previously.<sup>1</sup>

Evaluation of the pathway and possible variations in the course of the IAC of the mandible before surgery for IMTM extraction allows necessary precautions to ensure nerve preservation. However, in the obtained images, visualization of anatomical structures may be restricted, due to varying degrees of magnification, superposition, and distortion. Nevertheless, our own and other studies found that there was no significant difference between the actual size and the size obtained from CBCT images. However, a deviation from the real dimensions was observed in the buccal bone thickness (by 0.10 mm) and the bone height (0.2 mm) of 43 cadavers as compared to CBCT measurements, although the differences were not significant.<sup>21–23</sup>

In the computed tomography images of 40 patients, the area between the mental foramen and the ramus was divided into four equal parts. The bone height inferior to the

IAC was decreased from 11.8 mm in the retromolar region to 9.5 mm in the anterior region and 10.5 mm in the mental foramen region. In our study, the mean bone height inferior to the IAC in the retromolar region was 15.57 ( $\pm$  5.05) mm; it was 6.89 ( $\pm$  1.66) mm in the molar region and 11.22 ( $\pm$  4.86) in the premolar region. There was no significant difference between the values according to age or sex. Our study confirmed that the buccal bone was thicker in molar areas, while the lingual bone was thinner. In the premolar area, the lingual bone was thicker, and the buccal bone was thinner.

Identification of the anatomical pathway of the IAC in the mandible during operations can help prevent nerve damage. Our findings showed that the canal descended from the retromolar region to the molar region (approaching the lower mandibular edge), rose toward the premolar region, and ended at the mental foramen. The cases with the greatest risk for nerve damage are those in which the IAC is located buccally from the IMTM. Some features seen in the panoramic radiograph can predict the likelihood of injury of the IAC, such as bifid and radiolucency of the root tips, narrowing of the roots, complete monitoring of the radio-opacity of the canal, and deviation in the course of the canal. In our study, 5% of the pathways were located on the buccal side, which increases the risk of injury to the inferior alveolar nerve. The IAN, the lingual nerve, and lingual cortex integrity were preserved in cases where the IAC was lingual to the teeth or between the roots (44%), while in 40% of the cases, the IAC was located inferiorly to the IMTMs, and the IAN and lingual nerve and lingual bone was affected. Performing CBCT before surgery can help prevent complications during and after surgical extraction of IMTM teeth.<sup>24-29</sup>

Our study demonstrates that CBCT before oral and maxillofacial surgery can help to avoid injury to the IAN and to prevent surgical complications during and after surgical extraction of IMTMs.

### Acknowledgement

This study was approved by the ethics committee of Istanbul University, Faculty of Dentistry, Clinical Researches (Istanbul, Turkey; approval number 198).

### REFERENCES

1. Timock AM, Cook V, McDonald T, Leo MC, Crowe J, Benninger BL, et al. Accuracy and reliability of buccal bone height and thickness measurements from cone-beam computed tomography imaging. *Am J Orthod Dentofacial Orthop* 2011; 140: 734-44.
2. Olivier E. The inferior dental canal and its nerve in the adult. *Br Dent J* 1928; 49:3 56-58.
3. Ahmed A, Mohamed F, Hattab K. Surgical extraction of impacted mandibular third molars: postoperative complications and their risk factors. *Jamahiriyah Med J* 2009; 9: 272-275.
4. Blondeau F, Daniel NG. Extraction of impacted mandibular third molars: postoperative complications and their risk factors. *J Can Dent Assoc* 2007; 73: 325.
5. Atieh MA. Diagnostic accuracy of panoramic radiography in determining the relationship between inferior alveolar nerve and mandibular third molar. *J Oral Maxillofac Surg* 2010; 68: 74-82.
6. Brann CR, Brickley MR, Shepherd JP. Factors influencing nerve damage during lower third molar surgery. *Br Dent J* 1999; 186: 514-516.
7. Hillerup S. Iatrogenic injury to oral branches of the trigeminal nerve: records of 449 cases. *Clin Oral Investig* 2007; 11: 133-142.
8. Hillerup S. Iatrogenic injury to the inferior alveolar nerve: etiology, signs and symptoms, and observations on recovery. *Int J Oral Maxillofac Surg* 2008; 37: 704-709.
9. Bell GW, Rodgers JM, Grime RJ. The accuracy of dental panoramic tomography in determining the root morphology of mandibular third molar teeth before surgery. *Oral Surg Oral Med Oral Pathol Oral Radiol Endod* 2003; 95: 119-125.
10. Bou Serhal C, van Steenberghe D, Quirynen M, Jacobs R. Localisation of the mandibular canal using conventional spiral tomography: a human cadaver study. *Clin Oral Implants Res* 2001; 12: 230-236.
11. Macleod I, Heath N. Cone-beam computed tomography (CBCT) in dental practice. *Dent Update* 2008; 35: 590-598.
12. Maseda-Castellón E, Berini-Aytés L. Inferior alveolar nerve damage after lower third molar surgical extraction: a prospective study of 1589 surgical extractions. *Oral Surg Oral Med Oral Pathol Oral Radiol Endod* 2003; 94: 379-385.
13. Monaco G, Montevecchi M, Bonetti GA, Gatto MR, Checchi L. Reliability of panoramic radiography in evaluating the topographic relationship between the mandibular canal and impacted third molars. *J Am Dent Assoc* 2004; 135: 312-318.
14. Whaites E. *Essentials of dental radiography and radiology*. 4th ed. Edinburgh: New York: Churchill Livingstone; 2009.
15. Contar CM, de Oliveira P, Kanegusuku K, Berticelli RD, Azevedo-Alanis LR, Machado MA. Complications in third molar removal: a retrospective study of 588 patients. *Med Oral Patol Oral Cir Buca* 2010; 15: 74-78.
16. Ghaeminia H, Meijer GJ, Soehardi A, Borstlap WA, Mulder J, Vlijmen OJ, Bergé SJ, et al. The use of cone beam CT for the removal of wisdom teeth changes the surgical approach compared with panoramic radiography: a pilot study. *Int J Oral Maxillofac Surg* 2011; 40: 834-839.
17. Gowgiel JM. The position and course of the mandibu-

lar canal. *J Oral Implant* 1992; 18: 383-385.

**18.**Valmaseda-Castellón E, Gay-Escoda C. Inferior alveolar nerve damage after lower third molar surgical extraction: a prospective study of 1117 surgical extractions. *Oral Surg Oral Med Oral Pathol Oral Radiol Endod* 2001; 92: 377-383.

**19.**Pell GJ, Gregory BT. Impacted mandibular third molars: classification and modified techniques for removal. *Dent Digest* 1933; 39: 330-338.

**20.**Winter GB: Principles of Exodontia as Applied to the Impacted Third Molar. St Louis, MO, American Medical Books, 1926.

**21.**Kim YH, Lee JS, Yoon SJ, Kang BC. Reference dose levels for dental panoramic radiology in Anyang City. *Korean J Oral Maxillofac Radiol* 2009; 39: 199-203.

**22.**Lorenzoni DC, Bolognese AM, Garib DG, Guedes FR, Sant'Anna EF. Cone-beam computed tomography and radiographs in dentistry: aspects related to radiation dose. *Int J Dent*. 2012; doi:10.1155/2012/813768.

**23.**Lübbers HT, Matthews F, Damerau G, Kruse AL, Obwegeser JA, Grätz KW, et al. Anatomy of impacted lower third molars evaluated by computerized tomography: is there an indication for 3-dimensional imaging? *Oral Surg Oral Med Oral Pathol Oral Radiol Endod* 2011; 111: 547-550.

**24.**Ohman A, Kivijarvi K, Blomback U, Flygare, L. Pre-operative radiographic evaluation of lower third molars with computed tomography. *Dentomaxillofac Radiol*. 2006; 35: 30-35.

**25.**Renton T. Prevention of iatrogenic inferior alveolar nerve injuries in relation to dental procedures. *SADJ* 2010; 65: 342-351.

**26.**Savi A, Manfredi M, Pizzi S, Vescovi P, Ferrari S. Inferior alveolar nerve injury related to surgery for an erupted the third molar. *Oral Surg Oral Med Oral Pathol Oral Radiol Endod* 2007; 103: 7-9.

**27.**Sedaghatfar M, August MA, Dodson TB. Panoramic radiographic findings as predictors of inferior alveolar nerve exposure following third molar extraction. *J Oral Maxillofac Surg* 2005; 63: 3-7.

**28.**Suomalainen A, Ventä I, Mattila M, Turtola L, Vehmas T, Peltola JS. Reliability of CBCT and other radiographic methods in the preoperative evaluation of lower third molars. *Oral Surg Oral Med Oral Pathol Oral Radiol Endod* 2010; 109: 276-284.

**29.**Tantanapornkul W, Okouchi K, Fujiwara Y, Yamashiro M, Maruoka Y, Ohbayashi N, et al. A comparative study of cone-beam computed tomography and conventional panoramic radiography in assessing the topographic relationship between the mandibular canal and impacted third molars. *Oral Surg Oral Med Oral Pathol Oral Radiol Endod* 2007; 103: 253-259.