

Horizontal Mattress Sutures with Gauze Support for the Closure of Large Skin Defects: A Simple and Inexpensive Technique

Büyük Cilt Defektlerinin Kapatılmasında Gazlı Bez Destekli Matris Sütür Uygulamaları: Basit ve Düşük Maliyetli Bir Teknik

Ömer Cengiz^{1*}, Ferdi Dırvar², Necdet Demir³, Oytun Derya Tunç⁴

¹Muş Devlet Hastanesi, Ortopedi Ve Travmatoloji Bölümü, Muş, Türkiye

²Metin Sabancı Kemik Hastalıkları Eğitim Ve Araştırma Hastanesi, Ortopedi Ve Travmatoloji Bölümü, İstanbul, Türkiye

³Biruni Üniversitesi Tıp Fakültesi Hastanesi, Ortopedi Ve Travmatoloji Bölümü, İstanbul, Türkiye

⁴Marmara Üniversitesi Pendik Eğitim Ve Araştırma Hastanesi, Ortopedi Ve Travmatoloji Abd, İstanbul, Türkiye

ABSTRACT

Objectives: The study examined the feasibility of a suturing technique involving the use of horizontal mattress sutures with gauze support, which is based on the distribution of tensile forces over a wider area and the use of mechanical creep and stress relaxation of skin, for primary or staged closure of skin defects.

Material and Methods: A total of 15 wounds of eight patients were included. Direct wound closure was not possible in any of these wounds and all wounds were closed using horizontal sutures supported by gauzes where a gauze was placed between suture material and skin to spread the pressure over a wider area. Defects were closed either primarily or gradually.

Results: Size of the wounds ranged between 1.5 x 1.5 cm and 17 x 11cm. Successful skin edge apposition could be accomplished in all fifteen wounds using the technique described herein. In one patient, skin apposition failed subsequently, and the patient was managed with skin grafting; thus, conventional methods including skin grafts/flaps or secondary healing could be avoided in the remaining patients. No scar-related complications occurred during follow-up (mean duration, 8 months) after wound healing.

Conclusion: Preliminary results of this simple technique suggest that the technique has the potential to be used for the closure of primary non-closable wounds with low complication rate.

Key Words: Large skin defect, horizontal mattress suture, suture support, wound dehiscence, primary closure, suture failure

ÖZET

Amaç: Bu çalışmada, primer kapatılmayan cilt defektlerinin primer ya da kademeli kapatılmasında, germe kuvvetlerinin daha geniş bir alana yayılmasını ve mekanik sürünme ile ciltteki gerilimden faydalanılmasını esas alan yatay matris sütür tekniğinin gazlı bez desteği ile uygulanmasının fizibilitesinin incelenmesi amaçlanmıştır.

Gereçler ve Yöntem: Toplamda sekiz hastada bulunan 15 primer kapatılmayan yara çalışmaya alındı. Yaraların hiçbirinin direkt kapatılması mümkün değildi; bu yüzden gazlı bez desteğiyle yatay sütür tekniğine başvuruldu. Gazlı bez sütür materyali ile cilt arasına yerleştirilerek basıncın daha geniş bir alana yayılması amaçlandı. Defektler primer veya kademeli olarak kapatıldı.

Bulgular: Yaraların boyutu 1.5 x 1.5 cm ile 17 x 11 cm arasında değişmekteydi. Söz konusu teknik ile olguların tamamında yara dudaklarının karşılıklı getirilmesi mümkün oldu. Müteakip dönemde bir hastada apozisyonun yetersiz kalması nedeniyle greft uygulandı. Böylelikle, diğer hastalarda cilt greft/flepleri veya sekonder iyileşme gibi geleneksel yöntemlerden kaçınılmış oldu. Yaraların iyileşmesi sonrasında, ortalama sekiz aylık takip süresi boyunca hiçbir hastada yarayla ilişkili bir komplikasyon görülmedi.

Sonuç: Bu basit tekniğin elde edilen ilk bulguları, tekniğin primer kapatılmayan yaraların kapatılmasında uygulanabileceğini ve takip eden süreçte bir komplikasyon gelişmeyeceğini göstermektedir.

Anahtar Kelimeler: Büyük cilt defekti, primer kapatma, sütür desteği, sütür yetersizliği, yara açılması, yatay matris sütür

Introduction

Reconstruction of large soft tissue defects caused by surgery or trauma remains a major technical challenge. Immediate closure of the wound is generally preferred on the basis of practicability and better outcomes. However, factors such as inappropriate suture techniques, failure to apply the correct technique of skin closure, as well as inability to gauge the tension following closure may pave the way for wound dehiscence.

A number of different surgical techniques, skin stretching devices, and tissue expanders have been used to facilitate the reconstruction of large defects. Surgical techniques such as skin grafts, local flaps, and free flaps are generally complex, may result in significant morbidity, and may lead to less satisfactory cosmetic results as compared to primary repair.

Although sutures are used in a variety of patterns for the primary closure of large defects, very little evidence exists to support one configuration over another. Furthermore, various techniques have been described for staged wound closure by skin stretching [1-4]. Some of the suture techniques used for closing skin under excessive tension include the wound coverage by skin stretching with K wire [5], Donati-Allgöwer suture pattern [6], staged linear closure and the shoelace technique [7]. An ideal suture technique should be able to approximate the wound edges without compromising skin perfusion, since revascularization of the wound is an essential component of the wound healing process. Simultaneous presence of soft tissue injury, edema, and wound tension after trauma poses a particular risk for problems associated with cutaneous blood circulation [6]. Tensile forces to which a wound is subjected not only lead to a predisposition for circulatory problems but also tissue tearing and wound dehiscence as well. Mechanical stress is a risk factor for dehiscence; therefore, incisional support is necessary when a wound is at risk for breakdown or tear [8]. In addition, extra-cutaneous loops of the suture material on the surface of the skin may compress the epidermis. These loops may cause strangulation, necrosis, tearing and scarring of the skin when the suture is too tight [9]. The use of bolsters or compressible cushions beneath the suture loops have been proposed to address this problem [9-11]. Another approach commonly used for pulling the wound edges to cover a distance consists of horizontal mattress sutures.

The aim of our study was to determine the efficacy of a suturing technique involving the use of horizontal mattress sutures with gauze support for primary or staged closure of large skin defects. This technique is based on the distribution of tensile forces over a wider area and the use of mechanical creep and stress relaxation of skin.

Subjects and Methods: This study included eight patients with a total of 15 wounds between 2013 and 2016. The exclusion criteria included patients with burns and primary closable wounds. Direct wound closure was not possible in any of these wounds and all wounds were closed using horizontal sutures supported by gauzes.

Surgical technique: The wound planned for closure is adequately debrided, while particular attention is paid to the skin edges. Materials used for horizontal matrix suture technique, shown in Figures 1a through 1d, include 2.0 prolene sutures and gauze. The suture is sewn through the skin and subcutaneous tissue approximately 1.5- 2 cm from the wound (Fig. 1a). The main technical trick is the placement of a gauze between suture and skin. Gauze spreads the pressure over a wider area preventing suture failure through skin (Fig.1b). The amount of tension applied is subjectively determined and is mainly based on the clinical mobility of the skin adjoining the wound. Skin pallor and tightness represent the main factors to consider when judging how much stretching force can be applied safely to wound margins (Figs. 1c). Gradual closure might be necessary in larger defects. In our experience, it was possible to provide closure up to half of the skin gap in most of the patients on the first attempt (Fig. 1d). Re-application of the technique with tightening of the suture is performed after 2 weeks in line with our clinical experience, to close the rest of the skin gap in cases where staged closure is to be done. No additional treatment was performed at the second stage except for the suture technique. Sutures are removed two weeks after opposition of the skin edges. Prolonged strain can cause superficial necrosis of the skin underlying the gauze. Superficial skin necrosis may be ignored; however, suture cut should not occur.

Results

The characteristics of patients are depicted in Table 1. There were four male and four female patients, with a mean age of 58.7 years (range, 38-80). Size of the wounds ranged between 1.5 x 1.5 cm and 17 x 11cm. Recommended conventional approaches for these defects would include the

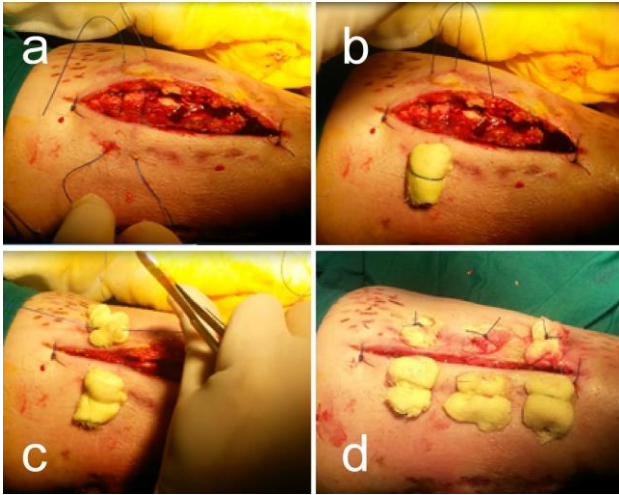


Fig. 1. Illustration of the technique without any additional accordion incision. (a) the suture is sewn through the skin and subcutaneous tissue, (b) gauze is placed between suture and skin, (c) tension applied to approximate the edges, (d) closure (direct or staged as appropriate).

following: six rotational flaps, six skin grafts, one free flap and two secondary healing. Four of the wounds were infected at the time of the procedure, for which appropriate antibiotics were given after debridement. In one patient, skin apposition failed subsequently, and the patient was managed with skin grafting. This patient (pt. 6) had multiple previous revisions for an infected total knee prosthesis with poor skin mobility, which might provide an explanation for the failure of the technique. Two illustrative cases are shown in Figures 2 and 3. The mean duration of follow-up of our patients was 8 months (range, 6–13 months). There were no scar-related complications after wound healing.

Discussion

Here we describe the outcomes of a surgical technique that can be utilized for the closure of any kind of skin defects. It appears from our results that it is possible to achieve quite satisfactory surgical outcomes with this simple and cost-effective technique in such lesions.

Collagen and elastin fibers are embedded and float in a gel-like base in the epidermis and dermis and comprise the majority of these layers (i.e. about 75% and 4% of the dry weight, respectively) [3]. The skin's ability to stretch and expand is largely imparted by the reorientation of this interwoven network of elastin and mainly collagen fibers [12]. Also, biomechanical properties of the skin, and particularly mechanical creep and stress relaxation, allow skin to stretch beyond its inherent

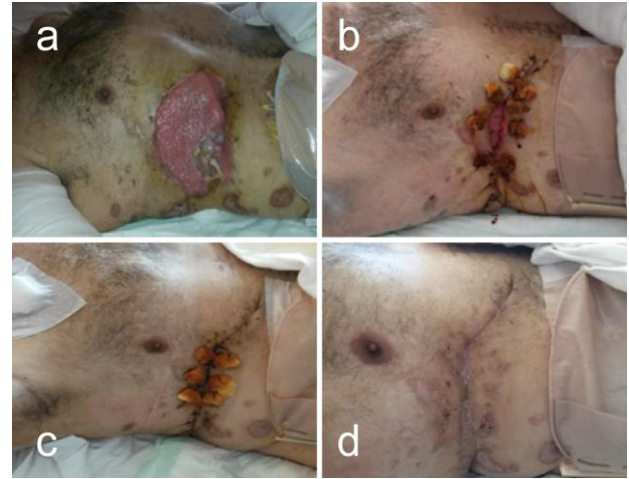

Fig. 2. A 44 -year-old patient (pt. 1) with multiple wounds from bomb blast injury. Figures show the staged closure of the wound at the right thorax sized 17x11 cm. Reapplication and tightening of the suture was performed after 2 weeks to close the rest of the skin gap. Sutures were removed on the twelfth day. The patient had perfect functional results at the end of 6 weeks. (a) before surgery, (b) partial closure using the technique, (c) complete closure at the second session, (d) six weeks after wound closure.

extensibility within a relatively short period of time. According to the mechanical creep phenomenon, skin will stretch and elongate with time as long as the force is applied. If the skin is stretched to a constant distance in a state of stress relaxation, it will expand, leading to a gradually reduced tension on the skin. Wound closing tension decreases as a result of skin stretching, allowing primary closure of large defects [13].

Although stress-relaxation is a well-established mechanism of skin stretching in laboratory settings, its clinical utility in conventional suturing techniques remains limited due to the inherent and simultaneous induction of ischemia, necrosis and subsequent suture failure. Thus, skin defects that cannot be primarily closed represent a common technical challenge in reconstructive procedures [14].

Simple interrupted or vertical mattress sutures focus tension across the wound edge and often result in tissue tearing [15]. Factors commonly associated with an increased risk of failure in skin closure include advanced age, connective tissue disorders, location of the incision, prior surgery or history of radiation, diabetes, obesity, infection, malnutrition, and use of immunosuppressive drugs [16, 17]. A number of different skin stretching devices have been introduced to assist closure through skin stretching, with reported complications of partial wound dehiscence, necrosis of skin edges, local infection [2, 4, 18]. In

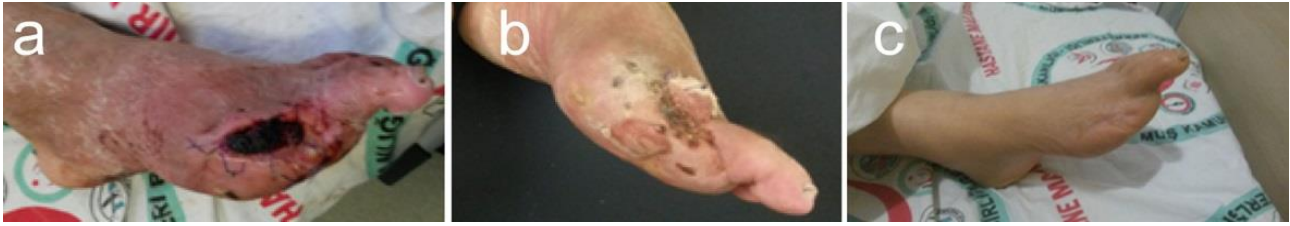

Fig. 3. A 68-year-old patient with uncontrolled type II diabetes (pt. 8) with an open wound occurring after disarticulation at metatarsophalangeal joint. Primary suture cut out occurred due to the patient being discordant with the treatment. The patient then underwent wound coverage by skin stretching with our technique and had perfect outcome at the end of 6 weeks with full weight bearing. Left, before surgery; right, six weeks after wound closure.

Table 1. Characteristics of the patients and the wounds

Patient no.	Age	Area	Mechanism	Recommended conventional treatment	Size (cm)	Wound culture	Co-morbidity
1	44	Thorax	Gunshot	Free flap	17x11		Malnutrition
		Upper arm	Gunshot	Skin graft	12x10		Malnutrition
		Leg	Fasciotomy	Skin graft	20x3		Malnutrition
		Leg	Gunshot	Rotational flap	3.5x2.5	MRSA	Malnutrition
		Leg	Gunshot	Rotational flap	1.5x1.5	MRSA	Malnutrition
2	40	Heel	Pressure sore	Rotational flap	3.5x3.5	MSSA	
3	38	Thigh	Postop necrosis	Rotational flap	4x3		Morbid obesity
		Thigh	Postop necrosis	Rotational flap	4x2		Morbid obesity
4	70	Ankle	Postop necrosis	Rotational flap	1x3		
5	80	Leg	Fasciotomy	Skin graft	12x4		Diabetes
		Leg	Fasciotomy	Skin graft	14x4		Diabetes
6	64	Knee	Postop necrosis	Skin graft	6x2		
7	68	Foot	Diabetic foot	Secondary healing	3.5x2		Diabetes
		Foot	Diabetic foot	Secondary healing	3.5x3		Diabetes
8	66	Knee	Postop necrosis	Skin graft	2x2	Klebsiella	Rheumatoid arthritis

MRSA, methicillin resistant staphylococcus aureus; MSSA, methicillin sensitive staphylococcus aureus

the study of 15 patients conducted by Eui-Tai Lee [19] about wound closure with Serial Tightening of Loop Suture, wound dehiscence occurred in 3 cases and 2 cases had skin laceration complications. In their study they conducted on 8 patients and 10 primary non-closeable wounds, Ravichand Ismavel et al. [5] applied a skin tension-assisted wound closure technique using Kirschner wires. Kirschner wires cut out in three patients and two patients had partial wound dehiscence. In contrast, in our group of patients where a simple and inexpensive skin closure method was used, wound dehiscence or wound necrosis did not

occur, the use of an auxiliary tool or device for skin tensioning was not needed and the method could even be successfully used in four infected wounds, with no recurrent infections. Furthermore, despite the presence of risk factors for wound dehiscence in a substantial proportion of our patients (5 patients, malnutrition; 2 patients, obesity; 4 patients, diabetes; and 1 patient on immunosuppressive treatment), skin closure could be successfully undertaken in most wounds. The only case of failure had a prior history of multiple surgeries for infected knee prosthesis. In that patient, although wound

dehiscence or necrosis did not occur, skin stretching could not be achieved, most probably due to presence of excessive fibrotic tissue.

The advantages of our procedure, on the other hand include the fact that it can be performed under local anesthesia with the use of readily available gauze and conventional sutures, significantly reducing the costs as compared to prefabricated skin stretching devices. Also, experience in reconstructive soft tissue procedures is not a prerequisite for the surgeon. Our technique is not associated with any donor site morbidity and can even be used for infected wounds. Therefore, this approach can be used in settings where commercial wound closure devices are either unavailable or considered too costly. However, it should also be borne in mind that this technique can and should only be implemented in mobile skin. Certain parameters such as the skin pallor and tightness can be exploited to gauge the amount of force required for stretching. Although undermining of the wound margins results in only a small additional decrease in skin tension, but also may lead to complications including skin edge necrosis and seromas [20].

The main limitations of this study include its small sample size and the differences across the patients in terms of co-morbid conditions, age as well as the mechanism, site, and size of the wounds.

In conclusion, our experience with this simple technique suggests that it has the potential to replace most reconstructive techniques used for the closure of primary non-closable wounds, with low complication rate.

References

1. Turgut G, Ozcan A, Sumer O, Yesiloglu N, Bas L. Reconstruction of complicated scalp defect via skin traction. *J Craniofac Surg*. 2009; 20(1): 263-264.
2. Hirshowitz B, Lindenbaum E, Har-Shai Y. A skin-stretching device for the harnessing of the viscoelastic properties of skin. *Plast Reconstr Surg* 1993; 92(2): 260-270.
3. Molea G, Schonauer F, Blasi F. Progressive skin extension: clinical and histological evaluation of a modified procedure using Kirschner wires. *Br J Plast Surg* 1999; 52(3): 205-208.
4. Barnea Y, Gur E, Amir A, Leshem D, Zaretski A, Shafir R et al. Our experience with Wisebands: a new skin and soft-tissue stretch device. *Plast Reconstr Surg* 2004; 113(3): 862-869.
5. Ravichand Ismavel, Sumant Samuel, P. R. J. V. C. Boopalan and Samuel B. Chittaranjan. A Simple Solution for Wound Coverage by Skin Stretching. *J Orthop Trauma* 2011; 25: 127-132.
6. Sagi HC, Papp S, Dipasquale T. The effect of suture pattern and tension on cutaneous blood flow as assessed by laser Doppler flowmetry in a pig model. *J Orthop Trauma* 2008; 22(3): 171-175.
7. Zorrilla P, Marín A, Gómez LA, Salido JA. Shoelace technique for gradual closure of fasciotomy wounds. *J Trauma* 2005; 59(6): 1515-1517.
8. West J, Gimbel M. Acute surgical and traumatic wound healing. In: Bryant R, editor. *Acute and chronic wounds: nursing management*. 2nd ed. St. Louis, MO: Mosby 2000; 189-196.
9. Zuber TJ. Skin biopsy, excision, and repair techniques. *Soft tissue surgery for the family physician (illustrated manuals, videotapes, and CDROMs of soft tissue surgery techniques)*. Kansas City, MO: American Academy of Family Physicians 1998; 100-106.
10. Stegman SJ, Tromovitch TA, Glogau RG. *Basics of dermatologic surgery*. Chicago: Year Book Medical 1982.
11. Swanson NA. *Atlas of cutaneous surgery*. Boston Little, Brown; 1987.
12. Elsner P, Wilhelm KP, Maibach HI, Berardesca E. *Bioengineering of the skin: skin biomechanics*. New York: CRC Press 2001.
13. Liang MD, Briggs P, Heckler FR, Futrell JW. Presuturing--a new technique for closing large skin defects: clinical and experimental studies. *Plast Reconstr Surg* 1988; 81(5): 694-702.
14. Topaz M, Carmel NN, Topaz G, Li M, Li YZ. Stress-relaxation and tension relief system for immediate primary closure of large and huge soft tissue defects: an old-new concept: new concept for direct closure of large defects. *Medicine (Baltimore)* 2014; 93(28): e234.
15. Davis M, Nakhdejvani A, Lidder S. Suture/Steri-Strip combination for the management of lacerations in thin-skinned individuals. *J Emerg Med* 2011; 40(3): 322-323.
16. Olivecrona C, Ponzer S, Hamberg P, Blomfeldt R. Lower tourniquet cuff pressure reduces postoperative wound complications after total knee arthroplasty: a randomized controlled study of 164 patients. *J Bone Joint Surg Am* 2012; 94(24): 2216-2221.
17. Ovaska MT, Makinen TJ, Madanat R, Huotari K, Vahlberg T, Hirvensalo E et al. Risk factors for deep surgical site infection following operative treatment of ankle

- fractures. J Bone Joint Surg Am 2013; 95(4): 348-353.
18. Samis AJ, Davidson JS. Skin-stretching device for intraoperative primary closure of radial forearm flap donor site. Plast Reconstr Surg 2000; 105(2): 698-702.
 19. Eui-Tai Lee. A New Wound Closure Achieving and Maintaining Device Using Serial Tightening of Loop Suture and its Clinical Applications in 15 Consecutive Patients for up to 102 Days. Ann Plast Surg 2004; 53(5): 436-441.
 20. Melis P, Noorlander ML, van der Horst CM, van Noorden CJ. Rapid alignment of collagen fibers in the dermis of undermined and not undermined skin stretched with a skin-stretching device. Plast Reconstr Surg 2002; 109(2): 674-680.