

Prenatal Diagnosis of Campomelic Dysplasia: A Case Report

Ismet Gün

Abstract

A fatal skeletal anomaly was diagnosed in the fetus of a 23-year-old pregnant woman at 23rd weeks of gestation with detailed ultrasonography. Amniocentesis was performed and it yielded a normal karyotype of 46, XX. Presumed diagnosis was a lethal skeletal dysplasia called campomelic dysplasia. Therefore, pregnancy was terminated by induction with misoprostol. In conclusion, second trimester ultrasonography performed by obstetricians should focus on the detection of common malformations.

Key words: Prenatal diagnosis, skeletal dysplasia, campomelic dysplasia, ultrasonography

The leading cause of infant death was reported to be congenital malformations, deformations and chromosomal abnormalities, accounted for 20.1% of all infant deaths (1). The overall prevalence of congenital malformations is 3.2% and the major malformation rates range between 0% to 6.9% (2,3). The campomelic dysplasia is one of the chromosomal abnormalities transmitted by autosomal dominantly or seen sporadically and the mutation is located at 17 q 24.3 – q 25.1 (4).

Compared with the general population of live births, infants with major malformations had a 6.3 times higher risk of death and being born with a malformation outweighs most of the other risks for infant mortality (5). Therefore, prenatal diagnosis of congenital abnormalities constitutes the most important part of antenatal care.

Antenatal ultrasound scanning at about 18 to 20 weeks of gestation permits the detection of considerable proportion of major fetal structural anomalies (6).

Skeletal dysplasias represent an important and relatively common abnormality group among all congenital abnormalities. Prenatal diagnosis has considerable importance for skeletal dysplasias, especially for ones having fatal course and these abnormalities are easily diagnosed by ultrasonography performed during second trimester (7).

The aim of this study is to describe a case of campomelic dysplasia diagnosed at 23rd weeks of gestation and to discuss the prenatal diagnosis of skeletal dysplasias

Case Report

A 23-year-old, gravida 2, parity 1 woman was referred to our center with a diagnosis of fetal skeletal anomaly at 23rd weeks of gestation. Her past medical history was unremarkable and her antenatal visits were regular. Ultrasonographic evaluation showed that fetal femur and humerus length was 5 weeks shorter than expected while other measurements were in accordance with the gestational age.

On detailed ultrasonography, the bones of all extremities were short and symmetrical angular in shape (Figure 1), also bilateral talipes equinovarus, a small scapula, a narrow thorax, pelvicaliectasia at right kidney (Figure 2), and limitation in fetal extremity movements were detected. Amniocentesis was performed due to the presence of multiple fetal abnormalities and yielded a normal karyotype of 46, XX. Presumed diagnosis was a lethal skeletal dysplasia called campomelic dysplasia. Therefore, pregnancy was terminated by induction with misoprostol after informing the patient and her husband about the fatality of the fetal disease. In addition to sonographically detected prenatal findings, thumbs of both feet were separated and absence of left 12th costa was seen on plain X-ray of aborted fetus (Figure 3).

Mailing Address: Dr. Ismet GÜN

Adana Military Hospital, Department of Obstetrics and Gynecology, Adana, Turkey

E-mail of co-author: drsmetgun@yahoo.com

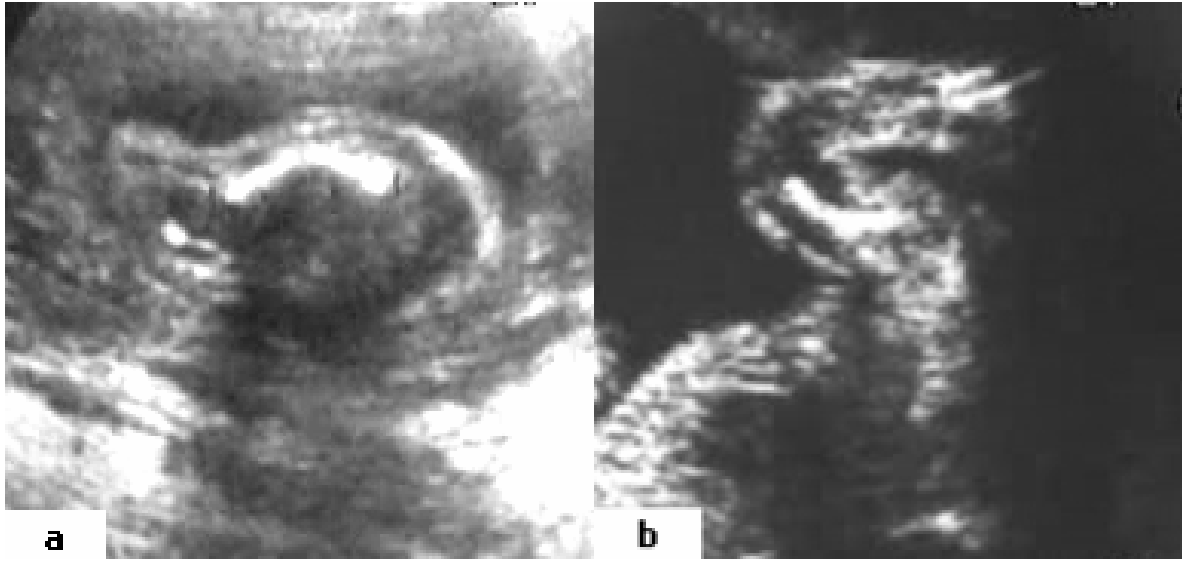


Figure 1. Short femur (a) and humerus (b) in angular shape

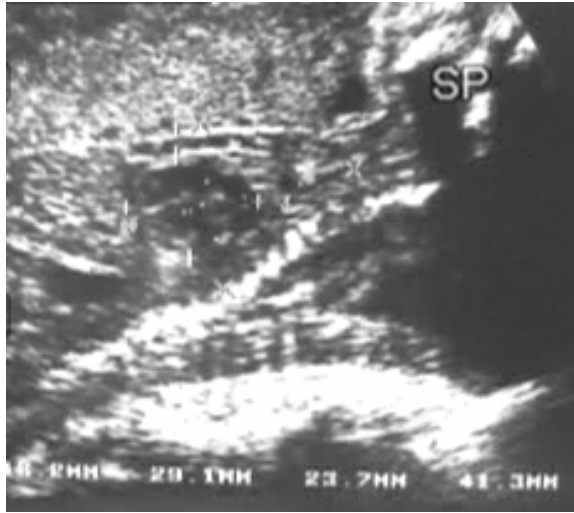

Figure 2. Pelvicaliectasia at right kidney

Discussion

In many countries, prenatal diagnosis achieved by ultrasound scan is now a routine part of prenatal care. The detection rate and the specificity of prenatal diagnosis by ultrasonographic examination were improved in course of time. Ultrasonographic examination was reported to detect 26.2% of fetuses having isolated malformations and 66.0% of fetuses having multiple malformations (8).

Prenatal diagnosis is especially important for malformations incompatible with postnatal life. Therefore, increase in rate of prenatal diagnosis of congenital malformations also results in increased pregnancy terminations (2).

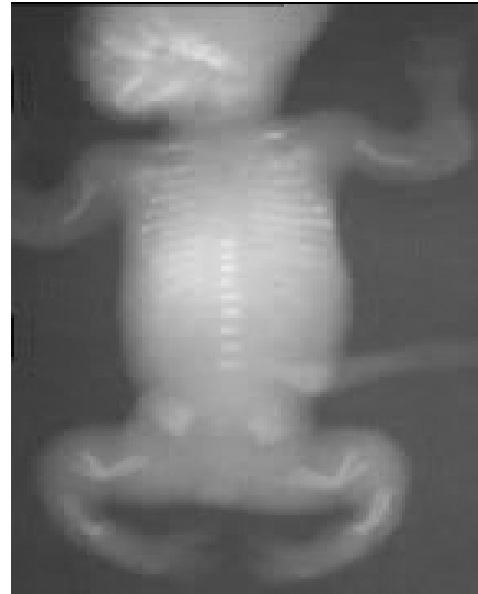

Figure 3. X-ray of aborted fetus

Skeletal dysplasias constitute a group of abnormalities which are relatively common and are mostly lethal. These abnormalities should be considered when long bones of fetus are measured to be shorter than expected. Thus, routine ultrasonography performed between 16th and 24th weeks of gestation is the leading mode of diagnosis for skeletal dysplasias (9). The mean gestational age was 22.7 weeks (range, 14-32.3 weeks) at diagnosis of skeletal dysplasias (10). In accordance with the literature, the diagnosis of our case was also achieved at 23rd weeks via ultrasonographic examination.

Although accurate diagnosis of skeletal dysplasias may be problematic, the ability to predict lethality of the abnormality was reported to be as high as 100% with no false-positive findings with respect to lethality (10). Anyway, accurate differentiation of a lethal versus a non-lethal abnormality agrees with the aim of prenatal care. Among all skeletal dysplasias, campomelic dysplasia is a rare and generally a lethal one observed with an incidence of 0.05-1.6 in 10,000 live births (11).

The disease may be sporadic or inherited autosomal recessively and the term "campomelic" refers to the angulations of long bones. In addition to the mentioned abnormalities detected in our case, cerebrovascular dilatation, cleft palate, and cardiac defects may also be present. Phenotypic appearance is usually female. However, phenotypic female fetuses may have XY genotype with testes in situ. In general, the babies born with these abnormalities die because of laryngotracheomalasia resulting in severe respiratory distress (7, 12).

Therefore, the diagnosis of this fatal abnormality is extremely important since the patient and her family should be directed to medical abortion in case of such a diagnosis. After diagnosis, we informed the family of our case and they agreed to terminate the pregnancy because of the severity of disease.

In conclusion, second trimester ultrasonography performed by obstetricians should focus on detection of common malformations having a fatal course in order to achieve pregnancy termination as early as possible. Thus, birth of severely malformed fetuses may be decreased effectively.

Kampomelik Displazinin Prenatal Tanısı: Vaka Sunumu

Özet

23 yaşında bir gebenin fetusunda, 23. gebelik haftasında ayrıntılı ultrasonografi ile ölümcül bir iskelet anomalisi tespit edildi. Amniyosentez yapıldı ve sonucu 46 XX normal karyotip olarak raporlandı. Eldeki veriler doğrultusunda ölümcül bir iskelet displazisi campomelic dysplasia olarak adlandırıldı. Takiben, gebelik misoprostol indüksiyonu ile sonlandırıldı. Sonuç olarak obstetrisyenler tarafından, 2. trimester ultrasonografilerine yaygın anomalileri taramak için odaklanılmalıdır.

Anahtar kelimeler: Prenatal tanı, iskelet displazi, kampomelik displazi, ultrasonografi

References

- 1 Heron MP, Smith BL. Deaths: leading causes for 2003. Natl Vital Stat Rep. 2007 Mar 15;55(10):1-92.
- 2 De Vigan C, Khoshnood B, Lhomme A, Vodovar V, Goujard J, Goffinet F. Prevalence and prenatal diagnosis of congenital malformations in the Parisian population: twenty years of surveillance by the Paris Registry of congenital malformations. J Gynecol Obstet Biol Reprod (Paris). 2005 Feb;34(1 Pt 1):8-16.
- 3 Rimm AA, Katayama AC, Diaz M, Katayama KP. A meta-analysis of controlled studies comparing major malformation rates in IVF and ICSI infants with naturally conceived children. J Assist Reprod Genet. 2004 Dec;21(12):437-443.
- 4 Oriole IM, Costilla EE, Barbosa-Neto JG. Birth prevalence rate of skeletal dysplasias. J Med Genet. 1986; 23:328-332.
- 5 Druschel C, Hughes JP, Olsen C. Mortality among infants with congenital malformations, New York State, 1983 to 1988. Public Health Rep. 1996 Jul-Aug;111(4):359-365.
- 6 Manning FA. The anomalous fetus. In Fetal Medicine. Principles and Practice. Norwalk, CT: Appleton & Lange, 1995: 451.
- 7 Balcar I, Bieber FR. Sonographic and radiologic findings in campomelic dysplasia. AJR Am J Roentgenol. 1983 Sep;141(3):481-482.
- 8 Stoll C, Dott B, Alembik Y, Roth MP. Evaluation of routine prenatal diagnosis by a registry of congenital anomalies. Prenat Diagn. 1995 Sep;15(9):791-800.
- 9 Sharony R, Browne C, Lachman RS, Rimoin DL. Prenatal diagnosis of the skeletal dysplasias. Am J Obstet Gynecol. 1993 Sep;169(3):668-675.
- 10 Parilla BV, Leeth EA, Kambich MP, Chilis P, MacGregor SN. Antenatal detection of skeletal dysplasias. J Ultrasound Med. 2003 Mar;22(3):255-258; quiz 259-261.
- 11 Goldstein I, Reece EA, Pulu G, Bovicelli L, Hobbins JC. Cerebellar measurement with ultrasonography in the evaluation of fetal growth and development. Am J Obstet Gynecol. 1987;156:1065-9.
- 12 Clement D, Schiffrin BS, Kates RB. Acute oligohydramnios in postdate pregnancy. Am J Obstet Gynecol 1987;157:884-6.