

Frequency and Morphometry of the Sternal Foramen

Suleyman Emre Akin¹, Ahmet Dursun², Huseyin Alper Kiziloglu³, Hasan Ekrem Camas¹,
Veysel Atilla Ayyildiz⁴

¹Suleyman Demirel University, Faculty of Medicine, Thoracic Surgery Department, Isparta, Türkiye

²Karamanoglu Mehmetbey University, Faculty of Medicine, Department of Anatomy, Karaman, Türkiye

³Tokat Gaziosmanpasa University, Faculty of Medicine, Department of Radiology, Tokat, Türkiye

⁴Kocaeli City Hospital, Department of Radiology, Kocaeli, Türkiye

Abstract

Introduction: The sternal foramen is a defect associated with incomplete fusion of neonatal sternal cartilage. These variations are frequently observed and usually asymptomatic. The clinical importance of sternal foramen is that if its existence is unknown, can complicate invasive procedures and be confused with pathologies.

Materials and Methods: Computed Tomography images of 500 patients were analyzed retrospectively. The sternal foramen's diameters were measured and adjacent organs were recognized. The foramen's distance from the sternum's upper and lower edges, midline, xiphoid's lowest point, and incisura jugularis were measured.

Results: 54 foramen sternales were detected in 48(9.6%) patients. When the organs adjacent to foramen sternale were examined, 36(67%) heart, 7(13%) lungs, 5(9%) liver, 2(4%) diaphragm, 1(2%) stomach, 3(5%) were both heart and lung. The mean distance of the highest point of foramen from the midsagittal line to incisura jugularis was 157.6±23.9 mm in men and 119.9±15.51 mm in women. There was a statistically significant difference. The position of 38 male patients' foramen with respect to the line connecting nipples was investigated, and it was determined that the highest point of foramen was on the line in 1 patient and below in 37 patients.

Conclusion: Although the sternal foramen is an asymptomatic defect, it can confused with pathologies and may cause life-threatening complications during invasive procedures. Relevant physicians and specialists should keep in mind the presence of sternal foramen.

Key words: Sternum; foramen; anatomic variation; computerized tomography.

Introduction

The sternum is located in the midline anterior to the chest wall, and consists of the manubrium, corpus and xiphoid process. Morphology of the sternum shows considerable variability that is associated with the development of postnatal ossification centers. Sternal foramen (SF) is associated with incomplete fusion of neonatal sternal cartilage. Prevalence is 0.2-43.2%¹. Anatomical variations are frequently observed and usually asymptomatic. These variations are encountered incidentally in cross-sectional imaging and confused with pathological conditions. If they can not be noticed, they can cause serious complications in interventional procedures performed on anterior chest wall, due to their proximity to vital organs^{2,3}. SF can cause even fatal cardiac tamponade in blind sternal acupuncture and sternal bone marrow aspiration⁴. SF is encountered incidentally in 3.2-56.1% of

autopsy series¹. When assessing forensic events, SF should be differentiated from traumatic events, injuries, and bullet entry points. Also, SF appears as photopenic solitary areas in bone scintigraphy, which can be confused with lytic lesions such as cysts, granulomas, metastases, chordomas, and sarcomas⁵. If SF is unknown, scintigraphy may result in misdiagnosis. Our study was carried out to define SF and give medical professionals an opinion on the matter. In the literature, there are studies describing the incidence of SF, and their distribution according to gender, localization, foramen diameter, and skin-intrathoracic space distance¹. In our study, we aimed to take into consideration similar points. However, we evaluated the relationship between foramen locations and diameters, which are not mentioned in the literature, and the relationship between foramen diameters and gender. We also examined

*Corresponding Author: Suleyman Emre Akin Suleyman Demirel University, Medical Faculty Department of Thoracic Surgery, 32260, Isparta, Turkey **E-mail:** suleymanemreakin@yahoo.com

Orcid: Suleyman Emre Akin [0000-0002-0641-5229](https://orcid.org/0000-0002-0641-5229), Ahmet Dursun [0000-0003-4568-8761](https://orcid.org/0000-0003-4568-8761) Huseyin Alper Kiziloglu [0000-0002-6921-8716](https://orcid.org/0000-0002-6921-8716)
Hasan Ekrem Camas [0000-0003-0212-0439](https://orcid.org/0000-0003-0212-0439) Veysel Atilla Ayyildiz [0000-0003-0252-9023](https://orcid.org/0000-0003-0252-9023)



the position of SF to adjacent organs, its position to the line connecting the nipple for male individuals, and incisura jugularis. The goal of this study is to define SF, which is an asymptomatic and incidentally detected variation, and increase the awareness of practitioners against secondary complications for interventional procedures related to sternum (acupuncture, bone marrow biopsies). Also, we aimed to prevent radiologists, nuclear medicine, and forensic medicine physicians from misdiagnosing.

Materials and Methods

The ethics committee decision dated 12.01.2022-20 and numbered 12.01.2022-20 was obtained from the Suleyman Demirel University Faculty of Medicine Clinical Research Ethics Committee. Patients who applied to our center between January 2010-January 2020 for various reasons (investigation of pulmonary nodules, suspected interstitial lung disease, traumatic conditions, suspicion of malignancy, metastas screening) were evaluated. Thoracic computed tomography (CT) was obtained. 500 patients aged 18 years and over were evaluated retrospectively. Images were obtained by 128-slice MDCT (Multidetector CT) Siemens (Somatom Definition AS, Siemens Healthcare, Erlangen, Germany) device. Technical parameters of CT examination: detector collimation is 128x0.6 mm, tube voltage is 120 kV, slice thickness is 1 mm, pitch value is 0.8, matrix 512x512, FOV (Field of View) is 30-35 cm. CT scans were obtained as images containing; the entire sternum, including thoracic inlet and adrenal glands in supine position. Images were obtained retrospectively from PACS (Picture Archiving and Communication Systems), evaluated, and rendered 3D in the program with RadiAnt DICOM Viewer 2021.2.2 version. In the evaluation of images, sagittal and coronal multiplanar reconstruction (MPR) over axial images in bone algorithm are used. 3D reforming, maximum intensity projection (MIP), and volume rendering technique (VRT) were used. Patients were first evaluated in terms of age, gender, and skeletal system pathologies. Patients with fractures, previous surgery to anterior chest wall, and tumors were not included. Diameters of SF were measured transverse and vertical in coronal plane of CT bone window (Figure 1). In transverse plane passing through the center of SF, the tissue thickness from skin-intrathoracic area was detected. Organs adjacent to foramen were identified in axial plane of CT mediastinal window. Distances from the foramen to the upper and lower border of sternum, midsagittal line,

lowest point of xiphoid, and superiorly to incisura jugularis were measured (Figure 2).

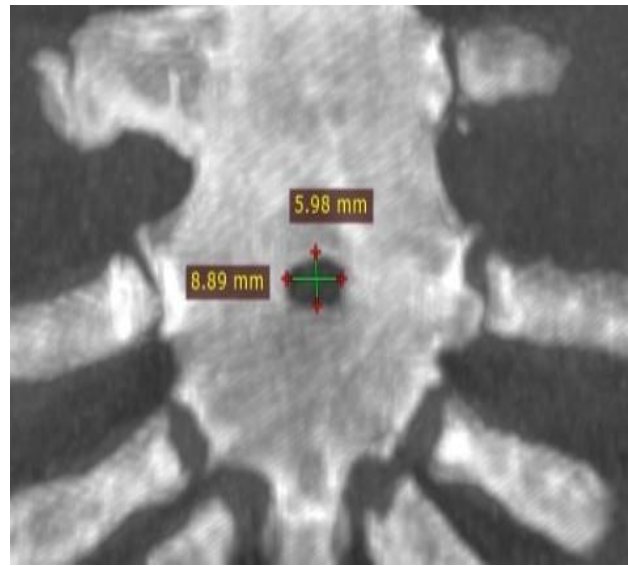


Figure 1: Transverse and vertical width measurement of the sternal foramen in the coronal plane.

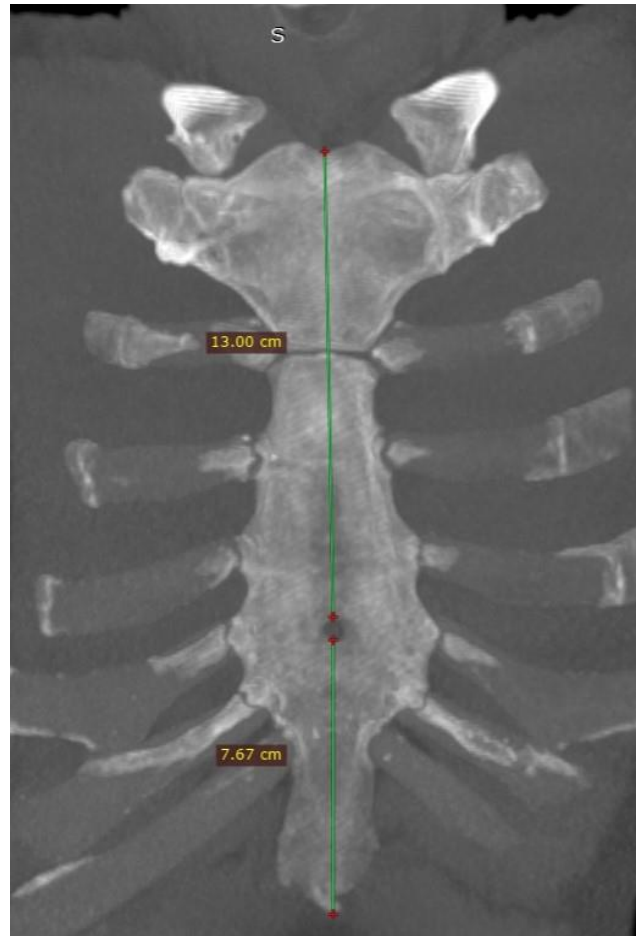


Figure 2: Measurement of the distance from the midsagittal line of the sternal foramen to the lowest point of the xiphoid and incisura jugularis.

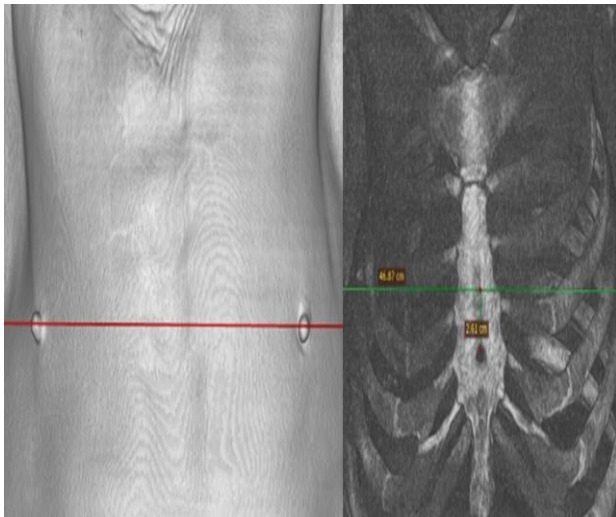


Figure 3: Measurement of the distance from the proximal point of the foramen to the line connecting the nipples in male patients with a foramen.

In male patients, the position and distance of proximal foramen point relative to the line connecting nipples were measured (Figure 3).

Ethical approval: The Decision of the Clinical Research Ethics Committee of Suleyman Demirel University Faculty of Medicine dated 12.01.2022

and numbered 20 was taken. This study has been carried out in accordance with the standards set out in the Code of Ethics of the World Medical Association (Declaration of Helsinki).

Statistical analysis: Data were analyzed with SPSS (Statistical Package for Social Sciences Version 21.0). Data were checked for normality with Kolmogorov Smirnov test. Independent samples and t-test were used for group comparisons. P values less than 0.05 were considered significant.

Results

500 patients (250 males, 250 females) aged between 18-95 were included in the study. 54 SF were detected in 48 (9.6%) patients (10 females, 38 males). In 6 (1.2%) patients (1 female, 5 males), 2 SFs were detected. The mean age of patients with SF is 62.37 ± 20.03 (20-92 years). The prevalence of foramen sternale was found 9.6% (15.2% in men and 4% in women) (Table 1) 24 (44.4%) of SFs in the corpus and 30 (55.6%) in the xiphoid.

Table 1: Descriptive data of patients with Sternal Foramen.

Informations	Sex		Total
Prevalence (%)	Male	15.2 %	9.6%
	Female	4%	
Number	Male	38	48
	Female	10	
Double sternal foramen	Male	5	6 (1.2%)
	Female	1	
Mean age of cases with sternal foramen (years)±Std. deflection	Male	63.84 ± 19.5	62.37 ± 20.03

Table 2: Morphometric data and comparison according to the localization of the sternal foramen.

Localization	Number (%)	Transverse Width (mm)	Vertical Width (mm)	Distance between skin and intrathoracic area (mm)
Corpus	24 (44.4%)	6.04 ± 2.78	7.63 ± 3.86	29.64 ± 10.5
Xifoid Process	30 (55.6%)	5.74 ± 3.06	6.63 ± 3.5	31.27 ± 8.97
P		0.710	0.328	0.548

The mean transverse width of foramen in corpus was 6.04 ± 2.78 mm, and the vertical width was 7.63 ± 3.86 mm. The transverse width in xiphoid was 5.74 ± 3.06 mm, and the vertical width was 6.63 ± 3.5 mm. There was no significant difference

between localization and transverse width ($p=0.710$) - vertical width ($p=0.328$) (Table 2). Transverse and vertical width were compared between genders, and no significant difference was found. In axial planes, the distance between

skin-intrathoracic space, measured at the axial axis passing through the center of SF was 29.64 ± 10.5 mm in corpus and 31.27 ± 8.97 mm in xiphoid. There was no significant difference ($p = 0.548$). When adjacent organs to SF were investigated; 36(67%) heart, 7(13%) lungs, 5(9%) liver, 2(4%) diaphragm, 1(2%) stomach and 3(5%) were adjacent to both heart and lung (Figure 4). The position of foramen in 38 male patients was investigated according to the line connecting nipples, it was determined that the highest point of foramen was on the line in 1 patient and below in 37 patients. The distance to

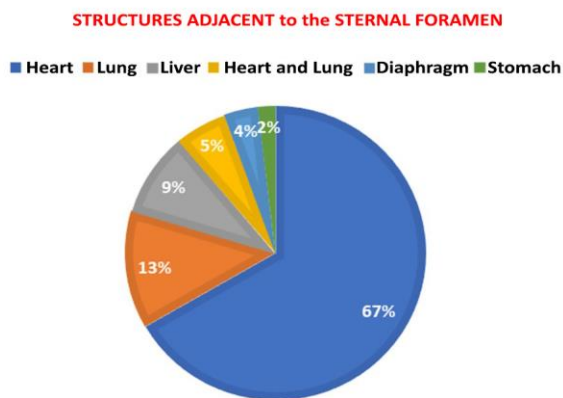


Figure 4: Distribution graph of organs adjacent to the sternal foramen.

line connecting nipples was 43.29 ± 25.11 mm (0-85.4mm). The mean distance of the highest point of foramen from midsagittal line to incisura jugularis was 157.6 ± 23.9 mm in men and 119.9 ± 15.51 mm in women, and there was a significant difference ($p < 0.001$). The distance from the lowest point of foramen to the lowest point of midsagittal line and the lowest point of sternum was 36.96 ± 20.66 mm in men and 37.67 ± 20.28 mm in women, and there was no significant difference for genders ($p = 0.919$).

Discussion

The sternum is an important anatomical structure located in front of the chest wall. Many anatomical variations can be seen that are confused with various pathologic conditions. In the 5th intrauterine month, two sternal bands that is on the right and left, develop in the midline of anterior chest wall, then fuse to form cartilaginous components of corpus, xiphoid, and manubrium. With birth, the development of manubrium and xiphoid process is completed². SF and sternal cleft occur when the right and left sternal bands fail to fuse. Yekeler et al. detected SF 4.5% in the Turkish population². Gossner et al. found a

frequency of 4.5% in their 352 series of CT study³. Nayak et al. found 6.7% in cadaver specimens⁶. Turkey et al. determined the frequency of SF 5.2%⁷. We found an SF frequency of 9.6%. We think that the study's population's different demographics contributed to dissimilar prevalence. Singh et al. detected more foramen in males without detecting significant differences between the two genders⁸. Similarly, we found a higher prevalence in males. In studies carried out on organs that are adjacent to SF, Turkey et al. found that SF adjacent to lung at the highest rate⁷. Similarly, Gossner et al. found that SF was most closely adjacent to lung with a rate of 53.3%³. Moreover, Papadimitriou et al. showed that SF is the most frequently adjacent to the heart in a rate of 93.3%⁹. Kuzucuoglu et al. showed that SF is most frequently adjacent to heart¹⁰. Similarly, Vatzia et al. found that SF was most closely adjacent to the pericardium (specifically to the right ventricle) with a rate of 37.14%¹¹. We found that the organ with the highest neighborhood rate is heart. This situation, in our opinion, is due to the fact that the study's target population was different. Due to its proximity to vital organs such as heart and lungs, this is especially important in blind bone marrow biopsies and acupuncture needle applications. Bone marrow biopsies are usually performed by using the iliac bone and sternum. Detailed evaluation and control with ultrasonography are recommended for biopsies that will be performed in the inferior part of sternum⁴. Undesirable complications such as cardiac tamponade and pneumothorax may occur in biopsies performed by neglecting SF. Yekeler et al. detected SF in xiphoid with a rate of 85.9%². Kuzucuoglu et al. detected SF in corpus sterni 66.2%¹⁰. Yurasakpong et al found SF in corpus sterni %53,6 on chest computed tomography of 1000 patients¹². We found the highest frequency in xiphoid with a rate of 55.6%. We associated the difference with variety in the human population in which the study carried on. Many studies on SF diameters have yielded different results. Yekeler et al. reported the mean foramen width of 6.5 mm (2-16 mm) in the Turkish population². Gossner et al. calculated mean width of 3.3 mm, and Vulovic et al. calculated a transvers width of 3.9 in the Serbian population^{3,13}. Kuzucuoglu et al. measured the mean transverse width 5.13 mm and vertical width 7.75 mm¹⁰. We calculated diameters for corpus and xiphoid separately and calculated the mean transverse width in corpus as 6.04 ± 2.78 mm and the vertical width as 7.63 ± 3.86 mm. We calculated the transverse width in xiphoid

5.74±3.06 mm and the vertical width 6.63±3.5 mm. We found the mean vertical width 7.07 mm, and the transverse width 5.87 mm on average, regardless of location. In addition, we did not find a statistically significant difference when foramen diameters were compared between genders. The difference in data determined about SF can be interpreted in relation to the difference in human population in which the study carried on. We think that more information about SF will be gathered by increasing the number of participants in studies that concern certain regions in these sections. In patients with SF, the distance between skin-intrathoracic space is important for interventional procedures. Awareness is important to prevent possible unwanted complications. Gossner et al.³ measured the mean distance between skin-intrathoracic areas as 49.6 mm. Babinski et al. measured the mean distance 42 mm for men and 34 mm for women (total average is 37 mm)¹⁴. Kuzucuoglu et al. measured the mean distance 20.95 mm for men and 22.27 mm for women (total mean 22.64 mm)¹⁰. We measured the mean distance of 29.64±10.5 mm in corpus and 31.27±8.97 mm in xiphoid, and we could not find a significant difference in terms of location. This is related to the difference in skin thickness in individuals, and a large distance may provide an advantage in reducing the possibility of undesirable complications for sternal interventions. The position of foramen in 38 male patients was investigated according to the line connecting nipples, it was determined that the most proximal point of foramen was on the line in 1 patient and below in 37 patients. We could not find any study in the literature examining the relationship between nipple lines and foramen localization in men. Another point that was not mentioned in the literature but that we referred to was a distance of SF to proximal and distal ends of sternum. For this purpose, the incisura jugulare proximally and the most distal end of xiphoid process distally were considered. Among these distances, the distance from the most proximal point of SF to midsagittal line and incisura jugularis was 157.6±23.9 mm in men and 119.9±15.51 mm in women, and there was a significant difference between genders. Although distal distance was higher in women, there was no significant difference between genders. We think that distance from the most proximal point of SF to midsagittal and even incisura jugularis can be used to determine gender, especially in forensic anthropology.

Study limitations: Our research's primary limitation is its retrospective approach. Although a

balanced sample was taken from all age ranges, the study was conducted in a limited population. Multicenter studies that involve a greater number of persons living in different geographical places can better reveal the anatomy of the sternal foramen.

Conclusion

SF is an asymptomatic defect. However, in some interventional conditions such as sternal bone marrow biopsy and acupuncture, if the presence of SF is overlooked, it may cause vital complications. Moreover, SF should be differentiated from lytic lesions, fractures, and traumatic penetrating lesions similar to bullet entry points. The fact that SF is below the line connecting nipple in all male cases, and staying above nipple line in interventional procedures to sternum will contribute to preventing complications. The fact that the distance of SF to incisura jugularis, which is the proximal distance in men is significantly higher can be used to determine gender in forensic anthropology. Especially radiologists, pathologists, nuclear medicine physicians, pulmonologists, thoracic surgeons, cardiologists, cardiovascular surgeons, orthopedists, emergency medicine and forensic medicine physicians, and hematology specialists should keep in mind presence of SF.

Conflict of interest: The authors declare that there is no conflict of interest.

Funding: No funding was received from any source for this study.

Author Contributions: Concept (SEA, AD, VAA), Design (AD, VAA, SEA, HAK), Data Collection and/or Processing (SEA, AD, HEC, VAA), Analysis and/or Interpretation (SEA, HAK, AD, HEC), Writing-Rewiev and Revision (SEA, AD, HAK, HEC, VAA)

References

1. Pasięka P, Pasięka PM, Komosa A, Barnowska A, Pękala J, Malinowski K, et al. Prevalence and morphometry of sternal and xiphoid foramen: a meta-analysis on 16,666 subjects. *Surg Radiol Anat* 2023;45(5), 623-635.
2. Yekeler E, Tunaci M, Tunaci A, Dursun M, Acunas G. Frequency of sternal variations and anomalies evaluated by MDCT. *AJR Am J Roentgenol* 2006;186(4):956-960.
3. Gossner J. Relationship of sternal foramina to vital structures of the chest: a computed tomographic study. *Anat Res Int* 2013;780193.

4. Choi PJ, Iwanaga J, Tubbs TS. A comprehensive review of the sternal foramina and its clinical significance. *Cureus* 2017;9(12):e1929.
5. Ishii S, Shishido F, Miyajima M, Sakuma K, Shigihara T, Kikuchi K, et al. Causes of photopenic defects in the lower sternum on bone scintigraphy and correlation with multidetector CT. *Clin Nucl Med* 2011;36(5):355-8.
6. Nayak G, Mohanty BB, Pradhan S () Study of sternal foramina in Eastern Indian dry Sterna. *IOSR J Dent Med Sci* 2018;17(7):87-90.
7. Turkey R, Inci E, Ors S, Nalbant MO, Gurses IA. Frequency of sternal variations in living individuals. *Surg Radiol Anat* 2017;39(11):1273-1278.
8. Singh J, Pathak RK. Sex and age related non-metric variation of the human sternum in a Northwest Indian postmortem sample: a pilot study. *Forensic Sci Int* 2013;228(1-3):181-e1.
9. Papadimitriou P, Chalkias A, Mastrokostopoulos A, Kapniari I, Xanthos T. Anatomical structures underneath the sternum in healthy adults and implications for chest compressions. *Am J Emerg Med* 2013;31:549-555.
10. Kuzucuoglu M, Albayrak I. Topographic evaluation of sternal foramen patients with thoracic computed tomography. *Surg Radiol Anat* 2020;42(4):405-409.
11. Vatzia K, Fanariotis M, Makridis KG, Vlychou M, Fezoulidis IV, Vassiou K. Frequency of sternal variations and anomalies in living individuals evaluated by MDCT. *Eur J Radiol* 2021;142:109828.
12. Yurasakpong L, Asuvapongpatana S, Weerachayanukul W, Meemon K, Jongkamonwiwat N, Kruepunga N, et al. Anatomical variants identified on chest computed tomography of 1000+ COVID-19 patients from an open-access dataset. *Clin Anat* 2022;35(6), 723-731.
13. Vulovic M, Zivanovic-Macuzic I, Jeremic D, Djonovic N, Radunovic A, Jovanovic M et al. Multidetector Computed tomography (MDCT) estimation of prevalence and anatomic characteristics of the sternal body foramen in the population of central Serbia. *Vojnosanit Pregl* 2019;76(2):186-191
14. Babinski MA, de Lemos L, Babinski MS, Goncalves MV, De Paula RC, Fernandes RM Frequency of sternal foramen evaluated by MDCT: a minor variation of great relevance. *Surg Radiol Anat* 2015;37:287-291.