

Spontaneous Splenic Rupture and Hemoperitoneum Due to Brucellosis Infection: A Case Report

Ahmet Cumhuri Dülger *, Mustafa Yılmaz *, Enver Aytemiz *, Kadir Bartın **, Mehmet Deniz Bulut ***, Özgür Kemik **, Aziz Sümer **

Abstract

A rare case of splenic brucellosis complicated by splenic rupture and hemoperitoneum is reported. A 37-year-old woman was admitted to our hospital because of abdominal pain and distention, dizziness and nocturnal fever. On examination in the emergency department, the blood pressure was 60/40 mmHg, and the pulse 110 beats per minute. Orthostatic vital signs revealed moderate postural changes. There was a palpable tender mass in the left upper quadrant. Intravenous fluids and norepinephrine were administered. Computed tomography of the abdomen showed markedly enlarged spleen, splenic rupture and intraabdominal fluid. A peritoneal lavage catheter was inserted and nearly 1000 ml of blood was removed. Blood was obtained for culture and serologic studies. Four units of erythrocyte suspensions were given. Serum agglutination test for brucella was positive (1:1240). Postoperatively, she received a combination of brucellosis therapy for 6 weeks. After completing conservative therapy with rifampin and doxycycline, the patient has remained healthy, with no recurrence of the abdominal pain.

Key words: Spontaneous splenic rupture, brucellosis, hemoperitoneum

Introduction

Spontaneous rupture of the spleen was first described by the English surgeon, Atkinson, in 1874 (1). Spontaneous splenic rupture is a relatively uncommon entity. It is usually associated with a wide variety of infectious, neoplastic, or hematologic diseases. Spontaneous splenic rupture also has occasionally been reported in normal spleens (2). Knoblich in 1966 suggested that the term "spontaneous" be replaced by "pathologic" in atraumatic rupture of the diseased spleen (3).

Brucellosis is the most common zoonotic infection worldwide. More than 500 000 new cases occur annually but with an uneven global distribution. Yearly incidence rates range from 0.3 cases per million in the United Kingdom and most parts of the United States to above 1 case per 1000 in endemic regions, where the disease represents a considerable and increasing health burden. The number of annual cases of human brucellosis in Turkey is approximately 15.000 (4). This number is believed to be a massive underestimation of the true prevalence of the disease. Splenic enlargement in brucellosis has been reported in 29- 56.6% of the cases (5, 6).

To our knowledge, spontaneous splenic rupture and haemoperitoneum, as a complication of brucellosis, is a rare condition. Since only such three brucellosis associated cases have been reported since 1980 (7-9). According to case reports of splenic abscess and rupture, patients were managed conservatively with good response (10, 11).

Clinicians should be aware of splenic rupture and hemoperitoneum as potential complications of brucellosis in endemic areas.

*Yüzüncü Yıl Üniversitesi Tıp Fakültesi Gastroenteroloji AD, Van.

**Yüzüncü Yıl Üniversitesi Tıp Fakültesi Genel Cerrahi AD, Van.

***Yüzüncü Yıl Üniversitesi Tıp Fakültesi Radyoloji AD, Van.

Yazışma Adresi: Ahmet Cumhuri Dülger Yüzüncü Yıl Üniversitesi Tıp Fakültesi Gastroenteroloji AD./ Van.

E- mail: acdulger@yahoo.com
Tel:+90 432 2164711

Case

A 37-year-old woman presented to the emergency department with a complaint of vertigo, nocturnal fever, arthralgia and left upper quadrant pain for five days. The patient had been well until five days before admission. She was a farmer and no family members or contacts had been ill. There were no allergies and no history of trauma either prior to operation or retrospectively after operation.

On physical examination, the patient was pale, and appeared sick. Her skin was cool and she had pale conjunctiva. Her temperature was 37.5°C, with a blood pressure of 60/40 mmHg, a pulse of 110 beats per minute, respirations of 18 per minute. The oxygen saturation was 90 percent while she was breathing room air. The liver edge was palpable 1 cm below the costal margin. There was a palpable tender mass in the left upper quadrant. The results of the remainder of the examination were normal. The patient solely well responded to intravenous fluid resuscitation with normal saline.

Laboratory studies performed at admission revealed a WBC count of 11.300 cells/mm³, a hemoglobin level of 7.2 g/dL, a platelet count of 350.000 platelets/mm³, an aspartate aminotransferase level of 56 U/L, an alanine aminotransferase level of 25 U/L, an alkaline phosphatase level of 58 U/L, and a gama glutamyl transferase level of 36 U/L. Erythrocyte sedimentation rate was 64 mm/hr and C-Reactive Protein level was 44 U/L. Serum levels of electrolytes, amylase, lipase, and tumour markers were normal, as were the results of renal-function testing and a urinalysis. Specimens of blood were sent for culture, testing for antibodies against brucella and other virologic studies. Serologic tests for Epstein-Barr virus, cytomegalovirus, and hepatitis viruses were negative.

Ultrasonography and Computed Tomography scan (CT scan) of abdomen showed a large splenic hematoma and hemoperitoneum (Figure 1). There were no evidence of perisplenic adhesions or scarring of the spleen, which suggests trauma or previous rupture.

After the diagnosis of hemoperitoneum was confirmed by ultrasound guided puncture in this patient, the surgeons performed a peritoneal lavage catheter in the operating room. The amount of free blood was determined as 1500 mL by the peritoneal lavage way. After four units of packed red blood cells, the patient's hemoglobin raised from 7.2 g/dl to 9.8 g/dl and the vital findings of the patient became normal. The peritoneal catheter was removed on the second

postoperative day. At the same day, serum agglutination test for Brucella was positive and its titer was 1/1240. Rifampin (600 mg/day for 6 week) and doxicyclin (100 mg twice daily for 6 week) were started.

She was discharged on the eighth postoperative day with anti-brucellar treatment she was well on the sixth week of treatment.

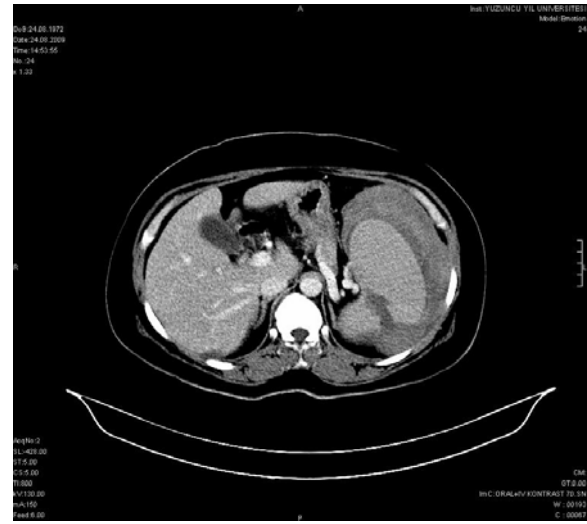


Fig. 1. Axial contrast-enhanced CT scan shows large subcapsular splenic hematoma with splenic laceration and hemoperitoneum.

Discussion

Spontaneous rupture of the spleen has been described mainly as case reports. Unlike traumatic splenic rupture spontaneous non-traumatic splenic rupture is extremely rare. The term spontaneous splenic rupture is poorly defined (12).

Wiedemann first defined the term as resulting from an "incident without external force", Knoblich distinguished the non-traumatic rupture of a pathological spleen from the extremely rare non-traumatic splenic rupture of unknown origin (3).

Spontaneous splenic rupture has been reported in numerous infectious, neoplastic, and inflammatory diseases that cause a sudden enlargement of the spleen. It has been seen in relation to Epstein-Barr virus infection, cytomegalovirus infection, tuberculosis, brucellosis, systemic lupus erythematosus, and several solid or hematologic tumors. Some cases are related to the presence of focal lesions, such as abscesses or cysts that favor capsule rupture (13).

Patients typically present with left upper quadrant pain, which may be associated with orthostatic symptoms. Kehr's sign (left diaphragmatic irritation resulting in pain referred to the left shoulder) and Ballance's sign (palpable tender mass in the left upper quadrant) are also suggestive of splenic rupture (14).

Ultrasonography and computed tomography remain the primary modalities in the diagnosis of splenic injury. Sonographic findings include splenomegaly, areas of decreased echogenicity within the spleen, subcapsular and pericapsular fluid collections, and free intraperitoneal fluid (15). Computed tomography has a sensitivity and specificity of at least 95% in the detection of splenic injury (16). Our case was diagnosed by computed tomography.

The rate of splenectomy was considerably lower for spontaneous splenic rupture compared with that of traumatic splenic rupture which has been described to be up to 50% (17).

Brucellae are small, gram negative and oxidase- and urease-positive coccobacilli that resemble fine grains of sand. Brucellosis is a disease of domestic and wild animals that is transmittable to humans (zoonosis). It is a systemic infection in which any organ or system of the body can be involved (18).

Gastrointestinal symptoms are noted in 40% of patients with brucellosis with anorexia, weight loss, constipation and abdominal pain being the most common. Abnormal gastrointestinal findings are present in 12% of patients, where hepato-splenomegaly is the most common. Abdominal pain is usually mild and vague. Occasionally, severe brucellar gastrointestinal localizations such as brucellar hepatitis with abscess formation, splenic abscess, spontaneous rupture of the spleen, cholecystitis, peritonitis, intestinal obstruction or perforation, erosive colitis and pancreatitis, may present with localized and intense abdominal pain (19). As seen in our patient, when a patient presents with splenomegaly and undulant fever, we must consider Brucellosis.

Finally, every organ and system of the human body can be affected in brucellosis. Brucella-associated spontaneous splenic rupture complicated by haemoperitoneum is responsible for this patient's symptoms and signs.

Splenectomy is the traditional treatment although conservative management may be adopted in haemodynamically stable patients to avoid the potentially severe septic complications post-splenectomy (20, 21). So, splenectomy was not the first line treatment for this patient.

This case report indicates that brucellosis may also be associated with spontaneous rupture of the spleen. Therefore, conservative management rather than splenectomy, is considered the treatment of choice for cases of brucella-associated splenic rupture and hemoperitoneum.

Brusella Enfeksiyonuna Bağlı Spontan Splenik Rüptür ve Hemoperitoneum: Olgu Sunumu

Özet

Splenik rüptür ve hemoperitonium ile komplike olmuş bir splenik bruselloz olgusunu sunuyoruz. 37 yaşında bayan hasta hastaneye karın ağrısı, karında şişkinlik, baş dönmesi ve geceleri olan ateş nedeniyle başvurdu. Acil Servisteki muayenesinde arteriyel kan basıncı 60/40 mmHg, nabız dakikada 110 idi. Ortostatik vital bulgular orta derecede postural değişiklikler gösteriyordu. Sol üst kadranda ele gelen hassas kitle saptandı. Hastaya intravenöz sıvı ve norepinefrin uygulandı. Batın bilgisayarlı tomografisinde (BT) dalakta belirgin büyüme, splenik rüptür ve intraabdominal sıvı saptandı. Peritoneal lavaj kateteri ile batına girildi ve yaklaşık 1000 mL kan boşaltıldı. Kültür ve serolojik incelemeler için kanlar alındı. Hastaya dört ünite eritrosit süspansiyonu verildi. Brusella aglütinasyon testi 1:1240 olarak pozitif. Operasyon sonrasında 6 haftalık kombine bruselloz tedavisi verildi. Rifampin ve doksisisiklinden oluşan konservatif tedaviyi tamamladıktan sonra hastanın sorunu olmadı ve karın ağrısı tekrarlamadı.

Anahtar kelimeler: Spontan dalak rüptürü, brusella, hemoperitoneum.

References

1. Atkinson E. Death from idiopathic rupture of the spleen. *BMJ* 1874; 2:403-404.
2. Bird D, Kelly MJ, Baird RN. Spontaneous rupture of the normal spleen: diagnosis by computerized tomography. *Br J Surg* 1979; 66:598.
3. Knoblich R. Pathologic (so-called spontaneous) rupture of spleen in leukemia and lymphoma. *Mich Med* 1966; 65:105-110.
4. Pappas G, Papadimitriou P, Akritidis N, Christou L, Tsianos EV. The new global map of human brucellosis. *Lancet Infect Dis* 2006; 6:91-99.
5. Malik GM. A clinical study of brucellosis in adults in the Asir region of southern Saudi Arabia. *Am J Trop Med Hyg* 1997; 56:375-377.
6. Al-Aska AK. Gastrointestinal manifestation of brucellosis in Saudi Arabian patients. *Trop Gastroenterol* 1989; 10:217-219.

7. Marín León I, Manzaneque González L, Beiztegui Sillero A, Monteagudo Parreño A, Dastis Bendala C, García Bragado F. Atraumatic rupture of the spleen. A proposal of new attitudes. Apropos a case in brucellosis. *An Med Interna* 1990; 7:474-476.
8. Rivera JM, Pérez-Jiménez F, Rivera J, Mata M, Escauriaza J, Jiménez Perepérez JA. New case of spontaneous splenic rupture in brucellosis. *Med Clin (Barc)* 1982; 78:168.
9. Benjamin B, Annobil SH. Childhood brucellosis in Southwestern Saudi Arabia: A 5 year experience. *J Trop Paed* 1992; 38:167-172.
10. Seçmeer G, Ecevit Z, Gülbulak B, Ceyhan M, Kanra G, Anlar Y. Splenic abscess due to brucella in childhood. A case report. *Turk J Pediatr* 1995; 37:403-406.
11. Marín León I, Manzaneque González L, Beiztegui Sillero A, Monteagudo Parreño A, Dastis Bendala C, García Bragado F. Atraumatic rupture of the spleen. A proposal of new attitudes. Apropos a case in Brucellosis. *An Med Interna* 1990; 7:474-476.
12. Hyun BM, Varga CF, Rubin RJ. Spontaneous and pathologic rupture of the spleen. *Arch Surg* 1972; 104:652-657.
13. Badenoch DF, Maurice HD, Gilmore OJ. Spontaneous rupture of a normal spleen. *J R Coll Surg Edinb* 1985; 30:326-327.
14. Tu AS, Tran MH, Larsen CR. Spontaneous splenic rupture: Report of five cases and a review of the literature. *Emergency Radiology* 1997; 6:415-418.
15. Putterman C, Almog Y. Sonographic diagnosis of spontaneous splenic rupture in infectious mononucleosis. *Isr J Med Sci* 1992; 28:801-804.
16. Jeffrey RB, Laing FC, Federle MP, Goodman PC. Computed tomography of splenic trauma. *Radiology* 1981; 141:729-732.
17. McKenney KL, Nuñez DB Jr, McKenney MG, Asher J, Zelnick K, Shipshak D. Sonography as the primary screening technique for blunt abdominal trauma: experience with 899 patients. *AJR Am J Roentgenol* 1998; 170:979-985.
18. Pappas G, Akritidis N, Bosilkovski M, Tsianos E. Brucellosis. *N Engl J Med* 2005; 352:2325-2336.
19. Madkour Monir M. Gastrointestinal brucellosis. In: Madkour Monir M, ed. *Madkour's Brucellosis*. 2nd ed. Berlin, Germany: Springer-Verlag 2001:150-158.
20. Guth AA, Pachter HL, Jacobowitz GR. Rupture of the pathologic spleen: is there a role for nonoperative therapy? *J Trauma* 1996; 41:214-218.
21. Pachter HL, Guth AA, Hofstetter SR, Spencer FC. Changing patterns in the management of splenic trauma: the impact of nonoperative management. *Ann Surg* 1998; 227:708-717.