



Comparison of the efficacy of microneedling combined with 5-fluorouracil 5% cream versus microneedling combined with tacrolimus 0.1% ointment in the treatment of vitiligo

Vitiligo tedavisinde mikro iğneleme ve 5-florourasil krem kombinasyonu ile mikro iğneleme ve takrolimus merhem kombinasyonunun etkinliklerinin karşılaştırılması

Parwaaz Matharoo, Saurabh Sharma, Jasleen Kaur, Roopam Bassi*

Sri Guru Ram Das Institute of Medical Sciences and Research, Department of Dermatology, Venereology and Leprosy; *Department of Physiology, Amritsar, India

Abstract

Background and Design: Vitiligo is an acquired depigmenting disorder associated with profound psychological effects. It can manifest as depigmented macules that can be localized or generalized in nature. Various morphological types are seen in patients. Despite existing therapeutic options, none is yet proven to be an ideal method for all patients.

Materials and Methods: Sixty lesions in 30 patients with vitiligo were divided into two groups and subjected to microneedling with DermaPen after topical application of 5-fluorouracil (5-FU) cream 5% in one group and tacrolimus ointment 0.1% in another group. This procedure was repeated every 2 weeks for a maximum of 10 sessions. Patients were followed up for 6 months after the last session.

Results: The overall repigmentation rate was significantly higher with 5-FU than with tacrolimus. Good-to-excellent response was seen in 76.7% of the lesions with 5-FU and 63.7% of the lesions with tacrolimus. Acral areas showed good-to-excellent response in 50% of the lesions in group A, and in group B, good response was seen in 50% lesions, whereas none attained excellent improvement.

Conclusion: Microneedling with 5-FU and tacrolimus appears to be safe and effective therapeutic intervention for stable refractory vitiligo. Both combinations were tolerated well, but 5-FU demonstrated significantly quicker and higher response.

Keywords: Fluorouracil, tacrolimus, vitiligo

Öz

Amaç: Vitiligo, kazanılmış depigmentasyon ile karakterize, önemli psikolojik etkileri olan bir hastalıktır. Lokalize ya da generalize depigmente maküller olarak kendini gösterir. Hastalarda farklı morfolojik tipler görülebilir. Çeşitli tedavi seçenekleri olmakla birlikte, henüz tüm hastalar için ideal yöntem olduğu kanıtlanmış bir modalite mevcut değildir.

Gereç ve Yöntem: Otuz vitiligo hastasındaki 60 lezyon iki gruba ayrıldı ve DermaPen ile mikro iğneleme sonrası bir gruptaki lezyonlara topikal 5-florourasil (5-FU) krem, diğer gruba ise takrolimus %0,1 pomad uygulandı. Bu işlem 2 haftada bir, maksimum 10 seansa kadar tekrarlandı. Hastalar son seanstan sonra 6 ay süreyle izlendi.

Bulgular: Toplam repigmentasyon 5-FU alan grupta, takrolimus alan gruba göre anlamlı derecede daha fazlaydı. İyi-mükemmel yanıt 5-FU uygulanan lezyonların %76,7'sinde ve takrolimus uygulanan lezyonların %63,7'sinde görüldü. Akral alanlarda her iki grupta da lezyonların %50'sinde iyi-mükemmel yanıt alınırken, iyi yanıt %50 lezyonda izlendi, hiçbir lezyonda mükemmel iyileşme görülmedi.

Sonuç: Stabil dirençli vitiligo için mikro iğneleme ile 5-FU ve takrolimus tedavileri etkili ve güvenli görünmektedir. Her iki kombinasyon da iyi tolere edilmiştir, fakat 5-FU ile anlamlı daha hızlı ve yüksek yanıt elde edilmiştir.

Anahtar Kelimeler: Florourasil, takrolimus, vitiligo

Address for Correspondence/Yazışma Adresi: Saurabh Sharma MD, Sri Guru Ram Das Institute of Medical Sciences and Research, Department of Dermatology, Venereology and Leprosy, Amritsar, India

Phone: +9815162491 **E-mail:** drsaurabhsharma@yahoo.co.in **Received/Geliş Tarihi:** 06.02.2021 **Accepted/Kabul Tarihi:** 14.01.2022

ORCID: orcid.org/0000-0003-2808-136X

Cite this article as: Matharoo P, Sharma S, Kaur J, Bassi R. Comparison of the efficacy of microneedling combined with 5-fluorouracil 5% cream versus microneedling combined with tacrolimus 0.1% ointment in the treatment of vitiligo. Turkderm-Turk Arch Dermatol Venereol 2022;56:64-9

©Copyright 2022 by Turkish Society of Dermatology and Venereology
Turkderm-Turkish Archives of Dermatology and Venereology published by Galenos Yayınevi.



Introduction

Vitiligo is a common acquired depigmentary disorder with an unpredictable course. It is a multifactorial and polygenic disease that is usually progressive. It is characterized by chalky white macules presenting in various patterns such as patchy depigmentation to near-total involvement of the body¹. It affects the world population, with an overall prevalence of 1%². Despite its benign nature, it can have ravaging psychosocial effects. It is attributed to cosmetic disfigurement, and patients experience depression, social rejection, and low self-esteem, causing negative effects on the quality of life³.

Although it is an ancient malady, its etiology remains an enigma till date. Various theories have been proposed, which includes autoimmune theory, neural theory, antioxidant deficiency theory, free radical species model, melanocyte growth factor reduction hypothesis, melanocytorrhagy, apoptosis, and composite theory. With ongoing research in understanding its pathophysiology, newer insights into the etiology keeps emerging. Vitiligo is divided into two major subtypes: Segmental and non-segmental. Rare clinical phenotypes include trichrome, quadrichrome, pentachrome, red vitiligo, and blue vitiligo⁴.

Since time immemorial, vitiligo continues to be a real challenge for dermatologists, regardless of the availability of surplus treatment options. The management of vitiligo can be divided into medical and surgical therapy. Medical treatment includes phototherapy, oral and topical corticosteroids, topical calcineurin inhibitors, topical vitamin D analogs, topical 5-fluorouracil (5-FU), antioxidants, levamisole, and immunosuppressants. Surgical treatment includes tissue and cellular grafts, therapeutic wounding, or lasers⁵.

Microneedling is a novel technique that causes repigmentation by creating micropores through the epidermis until the papillary dermis. It enhances drug delivery, stimulates repigmentation, and incites inflammation leading to migration of melanocytes. It can be used as monotherapy and in conjunction with several drugs. It was proven to be beneficial in combination therapy⁶. Microneedling combined with tacrolimus has shown better outcomes than tacrolimus monotherapy⁷. Needling with topical 5-FU has also been evaluated and resulted in better response⁸. As none of the therapeutic options have been proven to be an ideal method, this study aimed to compare the efficacy of the two combinations in the treatment of stable vitiligo lesions.

Materials and Methods

Participants and study design

This was a hospital-based interventional comparative study conducted in the outpatient department of dermatology, venereology, and leprosy for 1 year from January 2019 to December 2019.

Thirty patients with stable vitiligo for more than 1 year and with no history of previous treatment since the last 3 months were enrolled in this study.

Clinical assessment

A written consent form was obtained from each patient along with full history taking, general assessment, and dermatological examination before the study initiation. The study includes patients aged 12-60 years who were willing to come for regular follow-up and who were unresponsive to medical treatment. Patients with active Koebner's

phenomenon, infection, pregnancy or lactation, immunosuppression, and keloidal tendency were excluded. Vitiligo was diagnosed clinically, and not more than two lesions were selected in each patient. Sixty lesions in 30 study cases were categorized by the mid-sagittal line and divided into two groups. Lesions that are present over the right side were labeled as group A, whereas those on the left side were in group B.

A layer of 5-FU cream 5% was applied over the lesion in group A, and a layer of tacrolimus ointment 0.1% was used in group B. Following this, microneedling was performed with DermaPen using the lowest speed with needle penetration depth ranging from 0.25 to 0.5 mm over the face and 1-2 mm over the body in the horizontal and vertical directions until pin-point bleeding was observed. After cleaning with betadine, equal quantities of 5-FU cream 5% and fusidic acid cream 2% were applied under occlusive dressing for the same day in group A, and tacrolimus ointment 0.1% was used in group B. This procedure was repeated every 2 weeks for a maximum of 10 sessions. Group A patients were advised to apply 5-FU cream, and group B applied tacrolimus ointment once daily in between the sessions. The patients were followed up for 6 months after the last session. Any adverse effects or complication was recorded.

Repigmentation was assessed by an independent observer with the help of photographs, which were taken at baseline, before each session, and at follow-ups. Repigmentation response was graded as follows: G0 <25% poor; G1 25-50%, fair; G2 50-75%, good; and G3 >75%, excellent. The observation of excellent response in the lesion was considered the endpoint of treatment.

Informed written consent was taken on a prestructured proforma from every adult patient and from guardians in case of minors. The study was approved by the Sri Guru Ram Das Institute of Medical Sciences and Research Institutional Ethics Committee (approval number: Patho 182/19, date: 26.02.2019).

Statistical Analysis

The data collected were organized and analyzed using IBM SPSS Statistics for Windows, version 19 (IBM Corp., Armonk, NY, USA). The frequency, mean, and standard deviation were calculated. The Wilcoxon signed-rank test and Pearson chi-square test was used in this study. P<0.05 was considered significant.

Results

This study comprised 30 patients with clinically diagnosed stable non-segmental vitiligo. There were 19 women and 11 men. The demographic data are shown in Table 1. Clinical data between group A and group B is shown in Table 2.

Repigmentation response: Repigmentation started earlier in group A than in group B, 6.7% lesions achieved excellent response after a single session in group A, whereas the minimum number of sessions required in group B to achieve excellent response was 3, as shown in Table 2. Excellent response was found in 46.7% of the lesions with 5-FU and 16.7% of the lesions with tacrolimus. Good response was noted in 30% of the lesions in group A and 46.7% in group B. The difference between the two groups was significant. The total number of sittings and duration in weeks for response was less with 5-FU than with tacrolimus. A marginal type was the predominant pattern of

repigmentation in both groups, i.e., in 66.7% in group A and 80% in group B. Perifollicular pattern was found in 16.7% in group A and 20% in group B. Repigmentation started as erythema and pigments after a single session, and excellent response was observed within 4 weeks with 5-FU, whereas it was 6 weeks with tacrolimus. Figure 1 shows the before and after pictures of vitiliginous patches in group A (5-FU). Figure 2 shows the before and after pictures of vitiliginous patches in group B (tacrolimus).

The comparison results between the type of response and site of lesion in group A and group B are shown in Table 3. Maximum lesions were present over the limbs, followed by acral areas, trunk, and head and neck in both groups. 5-FU showed good-to-excellent response in 76.7% of the lesions in different body sites. Moreover, 100% of the lesions on the head and neck showed excellent response in groups A and B. The trunk showed good-to-excellent response, which was comparable in both groups. Good-to-excellent (>50%) response was observed in 83.3% of the lesions present over the limbs with 5-FU and in 63.6%

with tacrolimus. Acral areas showed good-to-excellent response in 50% of the lesions in group A, whereas no lesion attained excellent improvement in group B. Overall, group A had better outcomes over the limbs, followed by acral areas, than group B had.

Side effects were noted with 5-FU in the form of ulceration in 23.7% of the lesions and ecchymosis in 6.7%, whereas no complications were observed with tacrolimus. The statistical difference between the two drugs was 0.005. Repigmentation was stable in both groups, and no long-term complications were observed during the follow-up period.

Discussion

Vitiligo is a chronic disorder manifesting as pigmentation loss. It bears no correlation with ethnic, socio-economic, or racial differences among patients. The etiopathogenesis remains unknown. A plethora of various hypothesis and treatments have been suggested. Medical treatment remains the mainstay, but in refractory cases, surgical therapy is an option. Various surgical options are available; along with their pros and cons. They require skill, experience, and equipment, which can be sometimes expensive and time consuming. Multiple combination treatments have also been attempted till date. Great potential has been found in microneedling when used in combination with other drugs⁶. Combined treatments act synergistically, improving the outcome and reducing the time required to achieve repigmentation. Thus far, no single treatment method produces satisfactory results for all patients. Hence, this study was conducted to evaluate the efficacy of the combination of microneedling with topical 5-FU and tacrolimus for the treatment of stable vitiligo. The initiation of response was faster in lesions treated with 5-FU than with tacrolimus. Repigmentation started in the form of erythema or pigment after 2 weeks in 73% of the lesions treated with 5-FU. Excellent repigmentation was attained within 4 weeks with 5-FU and 6 weeks with tacrolimus. This was faster than reported in another study by Mina et al.⁹, who reported that repigmentation started within 6 weeks in 44% of the patches treated with 5-FU. This might be attributed to the difference in procedure. In our study, the first thick layer of topical 5-FU or tacrolimus was applied, followed by

Table 1. Clinical data of 30 study cases

	Number	Percentage	
Age (years)			
<30	24	80.0	
>30	6	20.0	
		Mean ± SD	
Minimum-maximum	13-57	25.35±12.979	-
Sex	Male	Female	
	11	19	36.7 63.3
Duration (years)	<4	>4	53.3 46.7
	16	14	
	Positive	Negative	
Family history	2	28	6.7 93.3
Type of vitiligo			
Generalized	22	73.3	
Mixed	8	26.7	

SD: Standard deviation

Table 2. Comparison of clinical data in group A and group B

	Group A		Group B		p-value
	Number	Percentage	Number	Percentage	
Type of response					
Excellent >75%	14	46.7	5	16.7	0.042
Good 50-75%	9	30.0	14	46.6	
Fair 25-50%	4	13.3	9	30.0	
Poor <25%	3	10.0	2	6.7	
Pattern of repigmentation					
Marginal	20	66.6	24	80.0	0.003
Perifollicular	5	16.7	6	20.0	
Diffuse	5	16.7	0	0	
Minimum number of sittings	1	6.7	3	3.3	
Number of sessions					
Mean ± SD	6.80±3.595		9.10±2.090		-

SD: Standard deviation

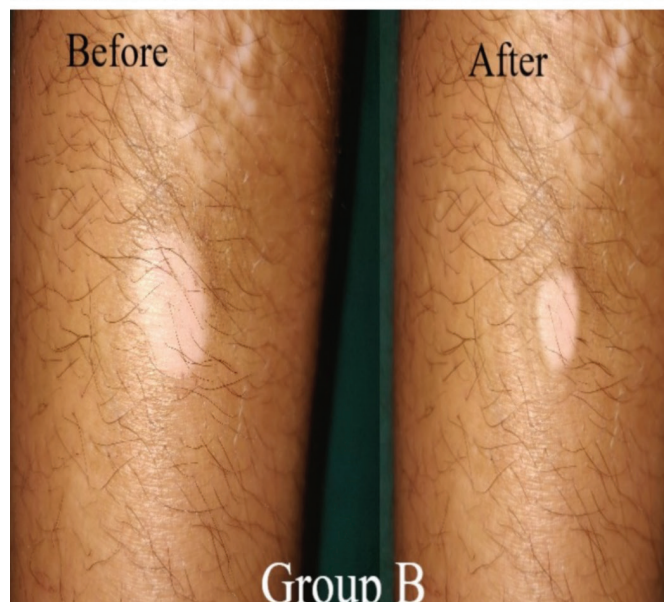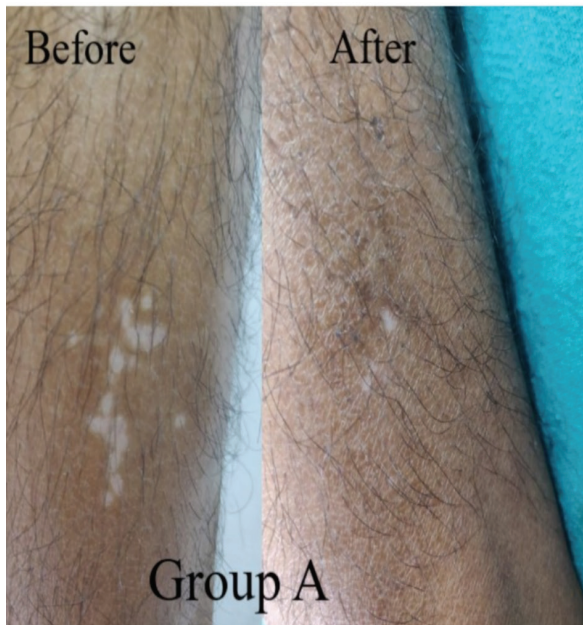
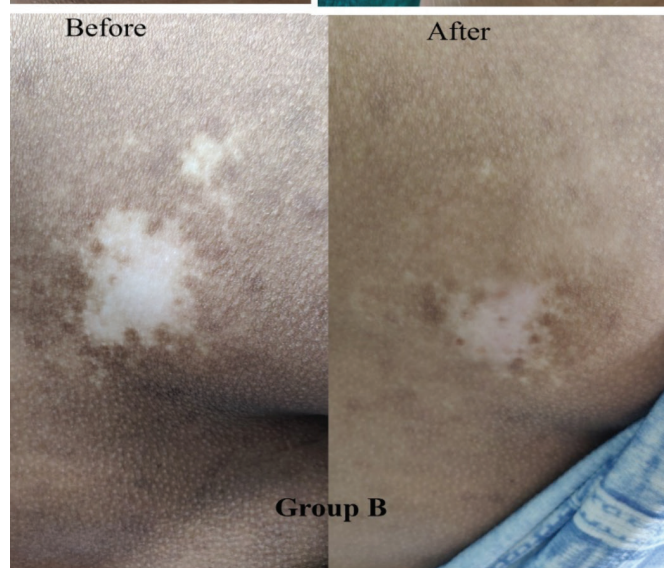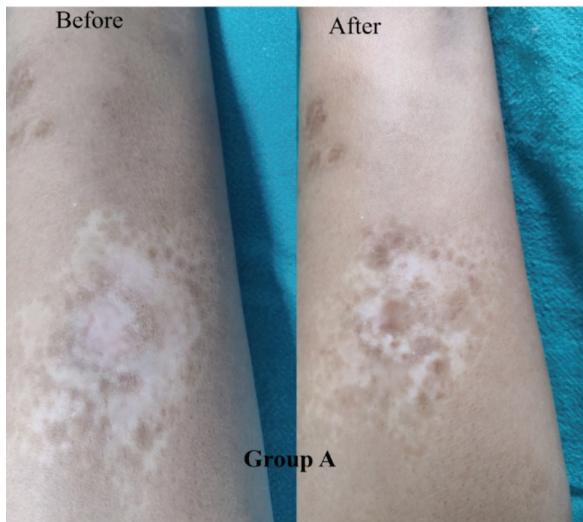
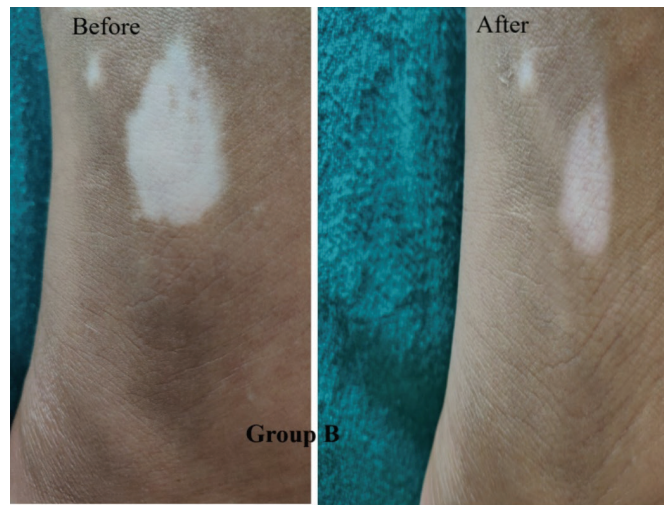
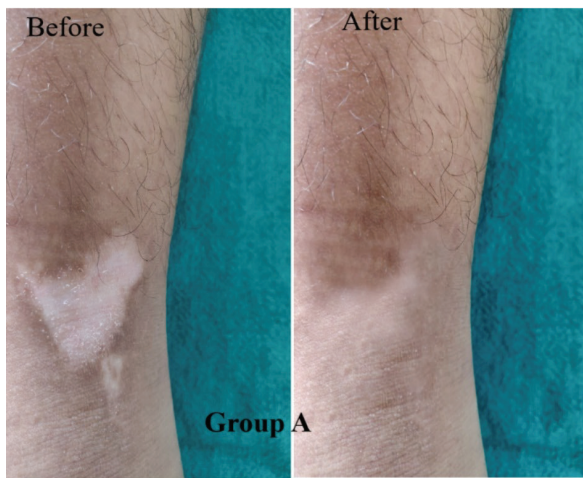


Figure 1. Before and after treatment pictures of vitiliginous patches in group A (5-FU)

5-FU: 5-fluorouracil

Figure 2. Before and after treatment pictures of vitiliginous patches in group B (tacrolimus)

Table 3. Relation between the type of response and site of lesion in group A and group B

Type of response										
	Site of lesion	Total	Excellent		Good		Fair		Poor	
5-FU group A	Head and neck	2	2	14.28%	0	0	0	0	0	-
	Trunk	6	4	28.57%	2	22.2%	0	0	0	-
	Limbs	12	6	42.85%	4	44.4%	2	50%	0	-
	Acral areas	10	2	14.28%	3	3.3%	2	50%	3	100%
	-	30	14		9		4		3	
Tacrolimus group B	Head and neck	1	1	20.0%	0	0	0	0	0	0
	Trunk	3	1	20.0%	1	7.14%	1	11.1%	0	0
	Limbs	22	3	60.0%	11	78.57%	8	88.9%	0	0
	Acral areas	4	0	0	2	14.28%	0	0	2	100%
	-	30	5		14		9		2	

5-FU: 5-fluorouracil

microneedling, whereas microneedling was performed before topical application by Mina et al.⁹ In another study, Zahra et al.¹⁰ reported the initiation of repigmentation at the end of 1 month in the form of erythema in 65% of the patches. The combination of microneedling with 5-FU attained better outcomes than dermabrasion with 5-FU, as reported by Garg et al.¹¹, who revealed that repigmentation started within 2 months in 50% of the patches. Microneedling enhances drug penetration up to the basal cell layer via a calculated depth and leads to the mechanical migration of melanocytes from the periphery to the center of the depigmented patch, resulting in rapid repigmentation. Santosh et al.¹² reported erythema and hyperpigmentation in 40% of the patients 1 month after the procedure. In our study, good-to-excellent response (>50%) was noted in 76.7% of the lesions with 5-FU. This was comparable with the findings of Shashikiran et al.¹³ who reported excellent response in 49% of the patches and Zahra et al.¹⁰ who found excellent response in 47% of the patches. Our findings were better than those of Mina et al.⁹ who reported good-to-excellent response in 52% of their patients. Another study observed excellent response in only 3.7% of the patients within 3 months⁸. The efficacy of 5-FU with microneedling is better than that with laser dermabrasion, where excellent repigmentation was observed in 40% of the patients¹⁴. Another study quoted excellent repigmentation in 45% of patients with dermabrasion and topical 5-FU¹⁵. Sethi et al.¹⁶ reported good-to-excellent repigmentation in 56.7% of the patients with dermabrasion and 5-FU. The better outcomes with microneedling could be explained by the fact that DermaPen produces microchannels that allow the penetration of the drug until the basal cell layer, whereas dermabrasion only removes the stratum corneum barrier. Our results were close to those of Abd El-Samad and Shaaban¹⁷ who observed excellent repigmentation in 48.3% of the patches. On the contrary, repigmentation with tacrolimus started in 33% of the lesions in our study, and excellent response was attained in 3.3% of the lesions in 6 weeks. This was faster than the rate reported by Mina et al.⁹ who studied 0.03% tacrolimus with microneedling and observed that repigmentation started within 6 weeks. Tacrolimus and microneedling showed good-to-excellent response in 63.7% of the lesions in our study. This was better than that reported by Mina et al.⁹, who found >50% response in 40% of the lesions treated with tacrolimus. In a

study by Ebrahim and Albalate¹⁸ excellent response was seen in 66.6% of the patients. Another study showed excellent response in 50% of the patients with tacrolimus and excimer laser.¹⁹ In the present study, according to the body site, the head and neck, followed by the limbs, showed the best response in both groups. However, 5-FU had better outcomes in the limbs, followed by acral areas, where good-to-excellent response was noted in 50% of the lesions. Our findings were in accordance with those of Mina et al.⁹ who observed repigmentation with 5-FU in different body sites along with acral areas, and tacrolimus had best response in the legs. Zahra et al.¹⁰ revealed that best response in truncal lesions, followed by the head and neck, and least response in acral lesions. Microneedling with 5-FU was better than intradermal 5-FU with NB UVB where acral areas hardly repigmented.¹⁷ As per the side effects associated with 5-FU, they were minor and temporary. The procedure was well tolerated by all patients. With 5-FU, ulceration was observed in 23.3% of the lesions and ecchymosis in 6.7%. Ulceration healed with hyperpigmentation that gradually returned to normal pigmentation, and no systemic side effects were observed in any patients. Our findings were comparable to those of Mina et al.⁹ who observed hyperpigmentation in 16%, inflammation in 12%, and ulceration in 4% of the patients. Another study reported pain in 40% of the patients, as well as erythema, itching, and ulceration in a few patients.¹⁰ Attwa et al.⁸ quoted pain and itching as side effects in a few patients. Pain was not a complication in our study, as lesions were infiltrated with local anesthesia before microneedling. In the present study, side effects were milder than those observed by Sethi et al.¹⁶, i.e., erythema and serous discharge in all patients, as well formation of pseudomembrane and hypertrophic scarring with dermabrasion with topical 5-FU. Hence, microneedling is a safe and well tolerated procedure with minimal complications and no scarring. As regards tacrolimus, no side effects were observed in our study. This finding was similar to those of Mina et al.⁹ where no complications were reported with tacrolimus. However, Ebrahim and Albalate¹⁸ observed mild pain, itching, and erythema as side effects in a few patients. Our study was an attempt to search for a simple and cost-effective procedure for vitiligo treatment. This procedure offers several advantages over other surgical modalities, as it does not require any expensive equipment, laboratory facilities, or trained personnel.

Study Limitations

We did not consider patient-based outcome measure or scale to evaluate repigmentation after treatment. Also, response of this combination was not evaluated on mucosal vitiligo.

Conclusion

Microneedling is a simple, quick, and cost-effective method that can be safely combined with 5-FU or tacrolimus. We recommend the use of microneedling after the application of topical medication to achieve better outcomes with uniform and deep penetration of the drug. We can infer from the results that both combinations achieved satisfactory repigmentation. Overall, 5-FU had significantly better outcomes in terms of repigmentation, number of sittings, total duration of treatment, and repigmentation of acral areas.

Ethics

Ethics Committee Approval: The study was approved by the Sri Guru Ram Das Institute of Medical Sciences and Research Institutional Ethics Committee (approval number: Patho 182/19, date: 26.02.2019).

Informed Consent: Informed written consent was taken on a pre-structured proforma from every adult patient and from guardians in case of minors.

Peer-review: Externally peer-reviewed.

Authorship Contributions

Surgical and Medical Practices: P.M., S.S., J.K., R.B., Concept: P.M., S.S., J.K., R.B., Design: P.M., S.S., J.K., R.B., Data Collection or Processing: P.M., S.S., J.K., R.B., Analysis or Interpretation: P.M., S.S., J.K., R.B., Literature Search: P.M., S.S., J.K., R.B., Writing: P.M., S.S., J.K., R.B.

Conflict of Interest: The authors declare that they have no conflict of interest.

Financial Disclosure: The authors declared that this study received no financial support.

References

1. Mahajan VK, Vashist S, Chauhan PS, Mehta KIS, Sharma V, Sharma A: Clinico-epidemiological profile of patients with vitiligo: A retrospective study from a Tertiary Care Center of North India. *Indian Dermatol Online J* 2019;10:38-44.
2. Sehgal VN, Srivastava G: Vitiligo: Compendium of clinic-epidemiological features. *Indian J Dermatol Venereol Leprol* 2007;73:149-56.
3. Xu AE, Zhang DM, Wei XD, Huang B, Lu LJ: Efficacy and safety of tacrolimus cream 0.1% in the treatment of vitiligo. *Int J Dermatol* 2009;48:86-90.
4. Arora AK, Kumaran MS: Pathogenesis of vitiligo: An update. *Pigment Int* 2017;4:65-77.
5. Majid I: Vitiligo Management: An Update. *British Journal of Medical Practitioners* 2010;3:a332.
6. Salloum A, Bazzi N, Maalouf D, Habre M: Microneedling in vitiligo: A systematic review. *Dermatol Ther* 2020;17:e14297.
7. Ebrahim HM, Elkot R, Albalate W: Combined microneedling with tacrolimus vs tacrolimus monotherapy for vitiligo treatment. *J Dermatolog Treat* 2021;32:999-1004.
8. Attwa EM, Khashaba SA, Ezzat NA: Evaluation of the additional effect of topical 5-fluorouracil to needling in the treatment of localized vitiligo. *J Cosmet Dermatol* 2020;19:1473-8.
9. Mina M, Elgarhy L, Al-Saeid H, Ibrahim Z: Comparison between the efficacy of microneedling combined with 5-fluorouracil vs microneedling with tacrolimus in the treatment of vitiligo. *J Cosmet Dermatol* 2018;17:744-51.
10. Zahra FT, Adil M, Amin SS, Mohtashim M, Bansal R, Khan HQ: Efficacy of topical 5% 5-fluorouracil with needling versus 5% 5-fluorouracil alone in stable vitiligo: A randomized controlled study. *J Cutan Aesthet Surg* 2020;13:197-203.
11. Garg T, Chander R, Jain A: Combination of microdermabrasion and 5-fluorouracil to induce repigmentation in vitiligo: an observational study. *Dermatol Surg* 2011;37:1763-6.
12. Santosh SK, Sushantika, Mohan L, Gupta AK, Mohammad A, Kumar N: Treatment of Vitiligo with 5-Fluorouracil after Microneedling of the lesion. *Int J Sci Stud* 2018;5:125-7.
13. Shashikiran AR, Gandhi S, Muruges SB, Kusagur M; Sugareddy. Efficacy of topical 5% fluorouracil needling in vitiligo. *Indian J Dermatol Venereol Leprol* 2018;84:203-5.
14. George M, Mallikarjun M, Manjunath P, Gangadhar B: Efficacy laser dermabrasion followed by topical 5- fluorouracil in the treatment of stable vitiligo. *Int J Health Sci Res* 2017;7:144-7.
15. El Abd Yones KH, Elden E, Mohamed MR, Mosbeh A, Tawfik KM: Efficacy of dermabrasion plus topical 5-fluorouracil in stable vitiligo. *Gulf J Dermatol Venereol* 2013;20:31-4.
16. Sethi S, Mahajan BB, Gupta RR, Ohri A: Comparative evaluation of the therapeutic efficacy of dermabrasion, dermabrasion combined with topical 5% 5-fluorouracil cream, and dermabrasion combined with topical placentex gel in localized stable vitiligo. *Int J Dermatol* 2007;46:875-9.
17. Abd El-Samad Z, Shaaban D: Treatment of localized non-segmental vitiligo with intradermal 5-fluorouracil injection combined with narrow-band ultraviolet B: a preliminary study. *J Dermatolog Treat* 2012;23:443-8.
18. Ebrahim HM, Albalate W: Efficacy of microneedling combined with tacrolimus versus either one alone for vitiligo treatment. *J Cosmetic Dermatol* 2020;19:855-62.
19. Nisticò S, Chiricozzi A, Saraceno R, Schipani C, Chimenti S: Vitiligo treatment with monochromatic excimer light and tacrolimus: results of an open randomized controlled study. *Photomed Laser Surg* 2012;30:26-30.