



# Two hearts beat as one: An easy method to design a hard flap

## Tek atan iki yürek-zor bir flebin kolay tasarımı

© Leyla Huseynova, © Gonca Elçin

Hacettepe University Faculty of Medicine, Department of Dermatology and Venereology, Ankara, Turkey

### 1-What is a bilobed flap?

Bilobed flap is a double transposition flap with a random blood supply. It consists of two lobes: The first lobe is used for reconstruction of the surgical defect, and the second lobe is used to repair the defect resulting from the first lobe<sup>1</sup>. A bilobed flap enables transposition of the skin over a large distance than did a single flap. The characteristic geometrical pattern of the bilobed flap allows distribution of tension vectors in various directions and across a wide surface, thus enabling the closure of the defect without distortions and redundancy, especially in areas with inelastic skin<sup>1,2</sup>.

### 2-History of the bilobed flap

The bilobed flap was first described by Esser in 1918 for repair of nasal tip defects. Owing to the large, greater than 180° axis of transportation, undesirable cosmetic outcomes such as cutaneous deformities were observed in that version. Thus, in 1989, Zitelli, a dermatologic surgeon, proposed a modified version of the original bilobed flap. By reducing angles between the lobes to <100°, Zitelli avoided prominent tissue protrusion. Nowadays, Zitelli-modified version is widely preferred among dermatologic surgeons.

### 3-Where can we use the bilobed flap?

Although it is broadly used in different areas of the body, a bilobed flap is considered one of the "workhorse" flap of

facial reconstruction<sup>4</sup>. It is widely used in repairing surgical defects of the nose as well as the cheek, chin, forehead, and ear. It is especially advantageous for defects located on the lower one-third of the nose, with a diameter <2 cm<sup>4</sup>.

### 4-How to design a bilobed flap?

Below, you will find a simply step-by-step description of the Zitelli bilobed flap. The whole concept of the bilobed flap design is based on a geometrical pattern that spans a 90°-100° pivotal arc. To achieve desirable results, it is crucial to properly define the boundaries and angulation of the lobes of the flap. So, let's begin.

First, measure the diameter of the defect. For example, if the defect has a diameter of 2 cm, the radius of the defect is 1 cm. Add one more radius, in our case 1 cm, from the free edge of the defect and mark this point. This point will be your pivot point, i.e., the point over which the flap will be rotated. Refer to this point as point P (Figure 1a). Then, draw two concentric circles around point P. The radius of the first circle must be two times the radius of the defect, and the radius of the second circle must be three times the radius of the defect. Now, we have two concentric circles with radii of 2 cm and 3 cm (Figure 1b). The bases of both lobes of the bilobed flap must lie on the first circle, and the apex of the first lobe must reach the second circle. The base of the first lobe must be equal to or a little narrower than the diameter

**Address for Correspondence/Yazışma Adresi:** Leyla Huseynova MD, Hacettepe University Faculty of Medicine, Department of Dermatology and Venereology, Ankara, Turkey Phone: +90 507 808 67 64 E-mail: leyla.huseynova@gmail.com

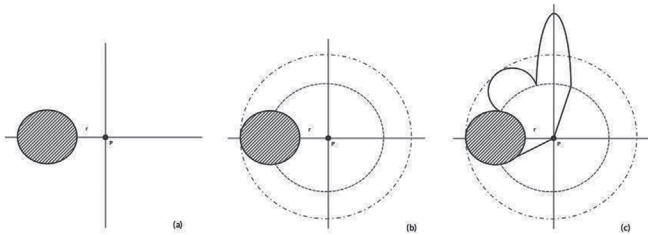
**Received/Geliş Tarihi:** 02.10.2020 **Accepted/Kabul Tarihi:** 22.11.2020 **ORCID:** orcid.org/0000-0003-3562-1491

**Cite this article as:** Huseynova L, Elçin G. Two hearts beat as one: An easy method to design a hard flap. Turkderm-Turk Arch Dermatol Venereol 2021;55:99-101.

©Copyright 2021 by Turkish Society of Dermatology and Venereology  
Turkderm - Turkish Archives of Dermatology and Venereology published by Galenos Yayınevi.



of the defect. The width of the second lobe along the first circle must be equal to or slightly narrower than the radius (half of the diameter) of the defect. The height of the second lobe must be longer than the height of the first lobe, that is, one radius further from the second circle, and it must have a triangular tip (Figure 1c). Congratulations, your bilobed flap design is ready. Is not it a little riddling?



**Figure 1.** Design of the ideal bilobed flap. **a)** Pivot point (point P) is placed one radius away from the free edge of the defect. **b)** Two concentric circles with radii equal to two and three times the radius of the defect is drawn around the pivot point. **c)** The base of the first lobe along the first circle is equal or a little narrower than the diameter of the defect. The base of the second lobe along the first circle is equal to or a little narrower than the radius (half of the diameter) of the defect. The apex of the first lobe lies on the second circle, whereas the apex of the second lobe extends one radius further from the second circle and has a triangular tip

### 5-Still confused about the design of a bilobed flap? Then, check this method.

Although it is not stated in the written literature, in practice, most European dermatologic surgeons design the bilobed flap by drawing two overlapping “hearts” (Figure 2). That is the reason why the flap is called with the original epithet “two hearts beat as one.” To design the bilobed flap by this method, draw two overlapping “hearts.” Then, extend further the apex of the second half of the second heart and give it a triangular shape. Make sure to draw the second half of the second heart a little narrower than the other halves of “hearts” (Figure 2). As seen in Figure 2, the defect and standing cutaneous cone constitute the first half of the “first heart.” The overlapping halves of the first and second hearts form the first lobe of the bilobed flap, and the second half of the second heart composes the second lobe of the flap.


### 6-What are the disadvantages of bilobed flap?

Owing to the curvilinear design of the bilobed flap, it is impossible to put incisions parallel to the skin tension lines and hide scars in the borders of cosmetic units and subunits. However, incisions on the nose heal well when delicately closed<sup>2</sup>.

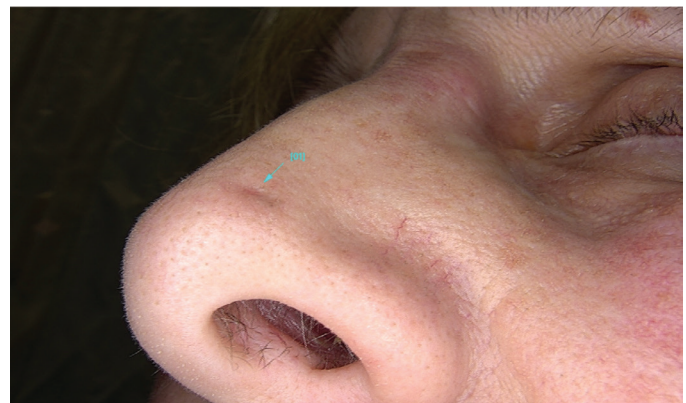### Case Report

Herein, we present a 55-year-old woman who was admitted to our clinic with a pink to skin-colored lesion with irregular borders located on the lower third of the nose for 4 years (Figure 3). Punch biopsy taken from the lesion was consistent with basal cell carcinoma of

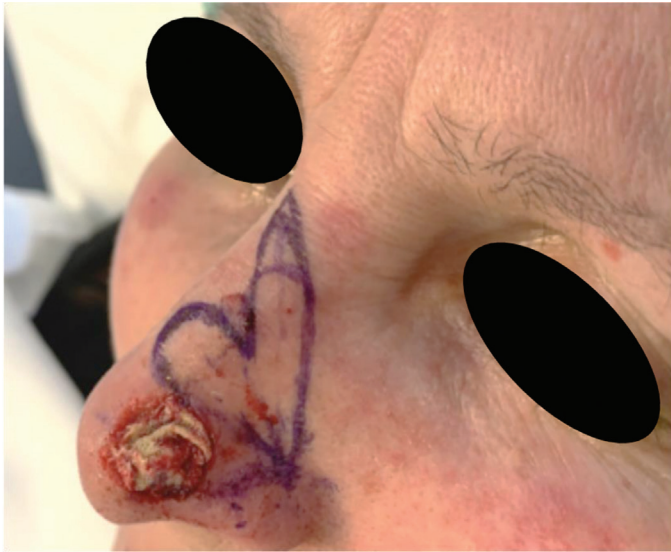adenoid and focal infiltrative types. The patient underwent Mohs micrographic surgery. After the first stage of Mohs micrographic surgery, tumor-free surgical margins were achieved (Figure 4). The bilobed flap was planned to repair the final surgical defect with a defect size of 14x12 mm<sup>2</sup> (Figure 5-7).



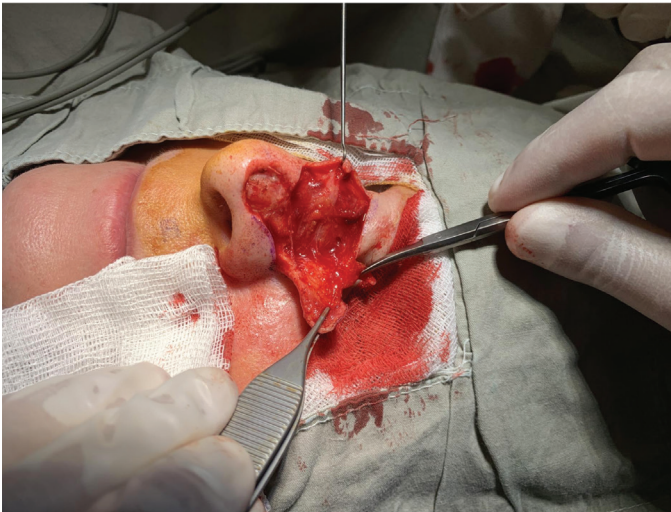
**Figure 2.** Design of the bilobed flap with two overlapping hearts. Easy design of the bilobed flap with the use of two overlapping hearts. The defect is marked as circle, the first heart is marked pink, and the second heart is marked green. First half of the first heart composes of the defect and the standing cutaneous cone, overlapping halves of the hearts form the first lobe of the bilobed flap, and the second half of the second heart composes the second lobe of the bilobed flap. Note the triangular shape of the second half of the second heart



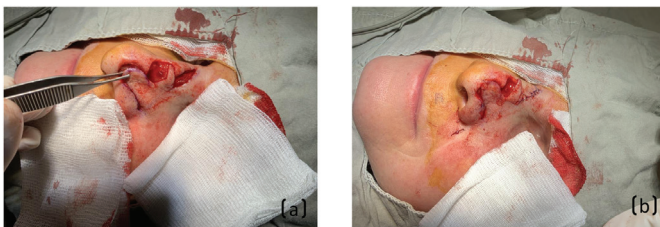**Figure 3.** Basal cell carcinoma located on the lower one-third of the nose



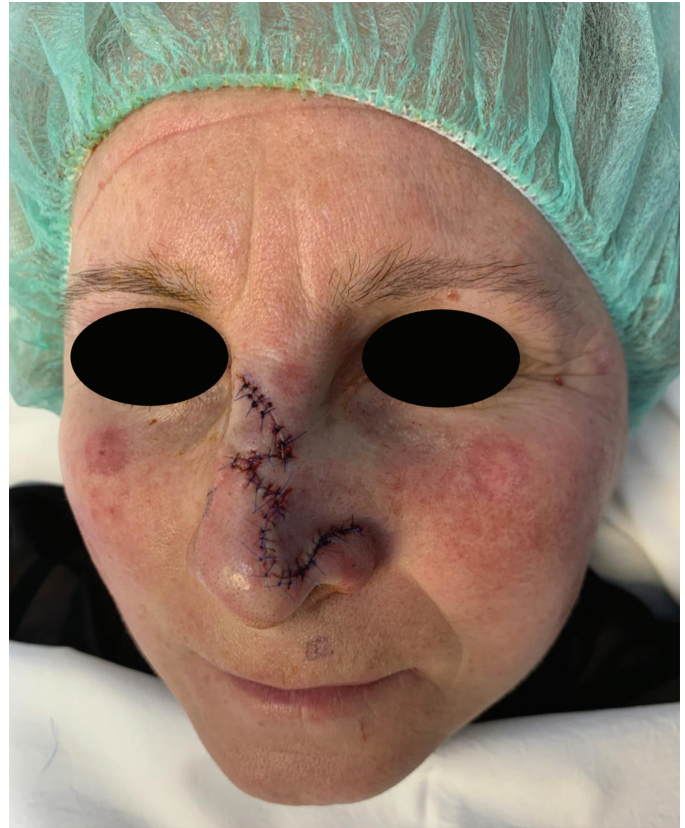**Figure 4.** Tumor-free margins with 14x12 mm<sup>2</sup> surgical defect were achieved after the first stage of Mohs micrographic surgery. Repair with a laterally based bilobed flap was planned. Note the location of the pivot point and the incision line along the alar crease. The arc of total rotation, angle between the midline of the defect, and second lobe is a little wider than 90°



**Figure 5.** Intense undermining of the whole area including the flap, skin adjacent to the defect, and skin overlying the left nasal side wall



**Figure 6. a)** Proper placement of the lobes in a tension-free manner. **b)** The authors of this manuscript prefer repairing the tertiary defect first



**Figure 7.** Immediate postoperative photo of the patient

Informed consent and permission for publication of the photos and medical data was taken from the patient.

## References

1. Tissiani LAL, Alonso N, Carneiro MH, Bazzi K, Rocco M: Versatility of the bilobed flap. *Rev Bras Cir Plást* 2011;26:411-7.
2. Steiger JD: Bilobed flaps in nasal reconstruction. *Facial Plast Surg Clin North Am* 2011;19:107-11.
3. Zitelli JA: The bilobed flap for nasal reconstruction. *Arch Dermatol* 1989;125:957-9.
4. Starkman SJ, Williams CT, Sherris DA: Flap basics I: rotation and transposition flaps. *Facial Plast Surg Clin North Am* 2017;25:313-21.