



Pityriasis rubra pilaris developing after COVID-19

COVID-19 sonrası gelişen pitriazis rubra pilaris

● Mine Müjde Kuş, ● Perihan Öztürk, ● Hülya Nazik, ● Mehmet Kamil Mülayim,
● Tutku Bulut, ● Esra Rabia Akgüç, ● Sezen Koçarlan*

Kahramanmaraş Sütçü İmam University Faculty of Medicine, Department of Dermatology; *Department of Pathology, Kahramanmaraş, Turkey

Abstract

Coronavirus disease-2019 (COVID-19) has been associated with multiple skin lesions as well as causing common respiratory symptoms. We presented a case of pityriasis rubra pilaris that developed after COVID-19 infection and treated with anti-tumor necrosis factor (adalimumab), which was not previously reported in an adult.

Keywords: Pityriasis rubra pilaris, COVID-19, skin, viral infection, treatment, anti-TNF

Öz

Koronavirüs hastalığı-2019 (COVID-19) yaygın respiratuvar semptomlara yol açmasının yanı sıra çok sayıda deri lezyonu ile ilişkilendirilmiştir. Daha önce erişkinde bildirilmemiş, COVID-19 enfeksiyonu sonrasında gelişen ve anti-tümör nekroz faktörü (adalimumab) ile tedavi edilen pitriazis rubra pilaris olgusu sunduk.

Anahtar Kelimeler: Pitriyazis rubra pilaris, COVID-19, deri, viral enfeksiyon, tedavi, anti-TNF

Introduction

The Coronavirus disease-2019 (COVID-19) pandemic was announced by the World Health Organization in March 2020¹. The first COVID-19 case in Turkey was seen on March 11, 2020. Since then, many skin manifestations have been reported with common symptoms related to COVID-19 such as fever, cough, shortness of breath, and anosmia². Skin conditions are divided into two groups: Inflammatory and vascular lesions. Inflammatory skin conditions can be seen as maculopapular/morbilliform, urticarial, and vesicular lesions. On the other hand, vascular lesions may present as pseudopernio, petechiae/purpura, and livedo reticularis³. We presented a classic type of adult pityriasis rubra pilaris

(PRP) that emerged after COVID-19 infection, which has never been reported in adults in the literature but has been reported only in one case in children.

Case Report

A 34-year-old male patient was admitted with erythematous squamous papules-plaques on the body, both lower extremities, face, scalp, genitals, and bilateral axillae and with hyperkeratosis protruding from the palmoplantar region to the lateral parts of the hands and feet (Figure 1, 2). He had been followed up for 10 years with a diagnosis of hypertension and depression and had been using olmesartan medoxomil and paroxetine. While there

Address for Correspondence/Yazışma Adresi: Mine Müjde Kuş MD, Kahramanmaraş Sütçü İmam University Faculty of Medicine, Department of Dermatology, Kahramanmaraş, Turkey

Phone: +90 507 204 55 36 **E-mail:** mmujde_ozdemir@hotmail.com **Received/Geliş Tarihi:** 09.06.2021 **Accepted/Kabul Tarihi:** 26.10.2021

ORCID: orcid.org/0000-0003-3928-7005

Cite this article as: Kuş MM, Öztürk P, Nazik H, Mülayim MK, Bulut T, Akgüç ER, Koçarlan S. Pityriasis rubra pilaris developing after COVID-19. Turkderm-Turk Arch Dermatol Venereol 2022;56:42-5

©Copyright 2022 by Turkish Society of Dermatology and Venereology
Turkderm-Turkish Archives of Dermatology and Venereology published by Galenos Yayınevi.



was no skin lesion before, the lesions had started presenting about 5 months ago. We learned that he had a COVID-19 infection about 2 weeks before the lesions started. Results from PCR testing conducted 5 months ago confirmed that he was positive for COVID-19. At that time, he showed symptoms of arthralgia, myalgia, sore throat, cough, shortness of breath, and anosmia but had no skin manifestations. All complaints related to COVID-19 regressed within 1 week by using favipiravir at home. About 2 weeks after his recovery from COVID-19, the lesions started to appear on his hands. When he had his checkup with us, his laboratory findings showed the following: Sedimentation: 2 mm/h, C-reactive protein: 4.6 mg/L, hemoglobin: 17 g/dL, leukocyte:

10.04 ($10^9/L$), neutrophil: 55.2 ($10^9/L$), aspartate aminotransferase: 25 U/L, alanine aminotransferase: 30 U/L, creatinine: 0.96 mg/dL, blood urea nitrogen: 18 mg/dL, anti-human immunodeficiency virus (anti-HIV) negative, and anti-hepatitis C virus negative. Tissue samples were taken from the patient for histopathological examination with prediagnoses of psoriasis and PRP. Histopathological manifestations were consistent with PRP, orthokeratosis, parakeratosis, prominent acanthosis, mild to moderate perivascular lymphocytic infiltration, and rare erythrocyte extravasation in the papillary dermis (Figure 3). Diagnosis of PRP was made with clinical and histopathological findings. We did not start with acitretin as the first-line treatment in

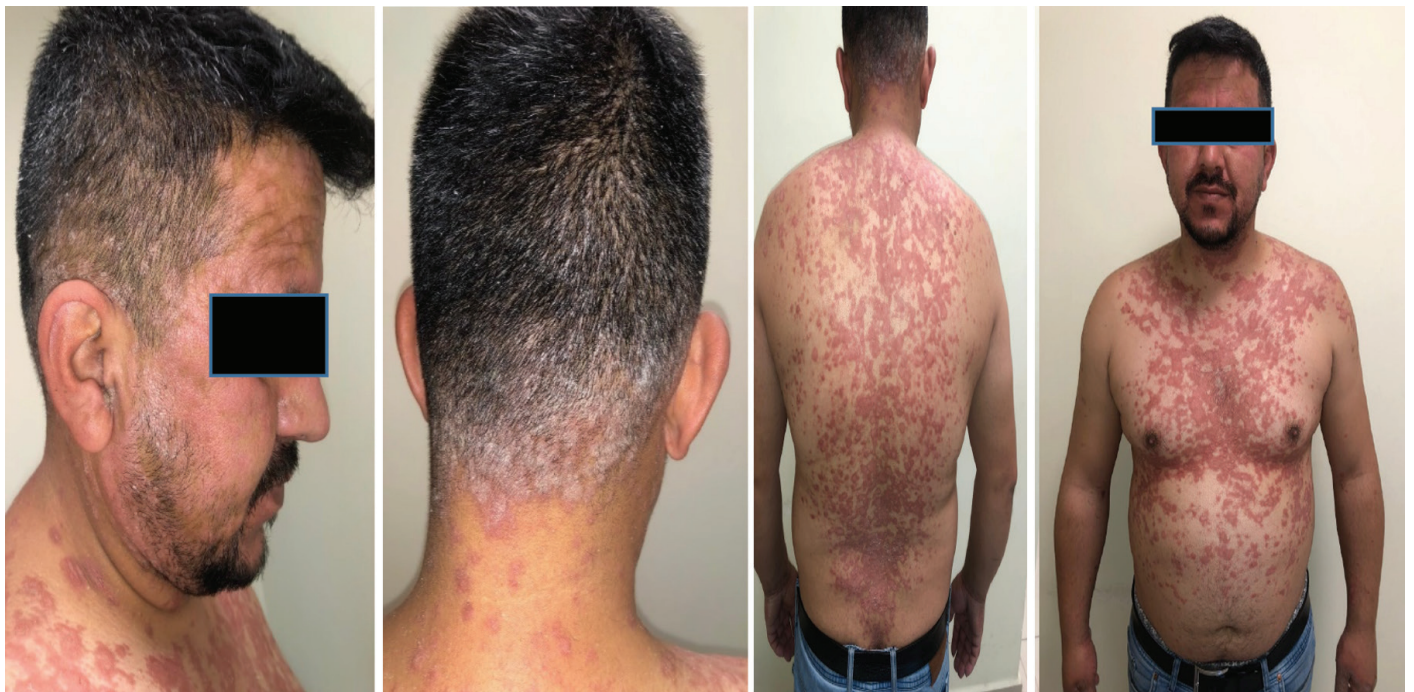

Figure 1. Erythematous squamous papule-plaques on the scalp, face, trunk, and shoulders with intact islets of skin between them

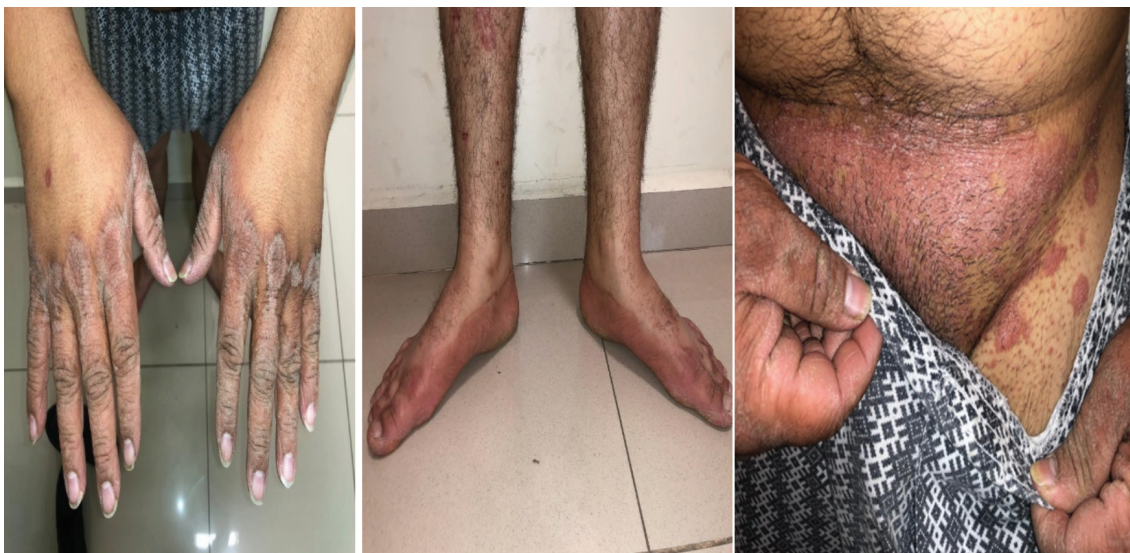

Figure 2. Hyperkeratosis protruding from the palmoplantar region to the lateral parts of the hand and foot. Erythematous squamous papule-plaques on the genital area with intact islets of skin between them

PRP treatment because the patient had a history of depression. Since the recommended methotrexate dose was 10 mg or less during the pandemic, we started treatment with methotrexate (10 mg) with folic acid, topical emollient, and topical steroid was started. We discontinued methotrexate because of gastrointestinal adverse effects and started with anti-tumor necrosis factor therapy (adalimumab). The patient received 80 mg adalimumab subcutaneously in the first week and 40 mg in the 2nd week. He started receiving maintenance therapy in the 4th week. At the end of the first month, we observed a noticeable regression in the squama, enduration, and erythema (Figure 4).

Consent was obtained from the patient presented in the case report to share information and photographs.

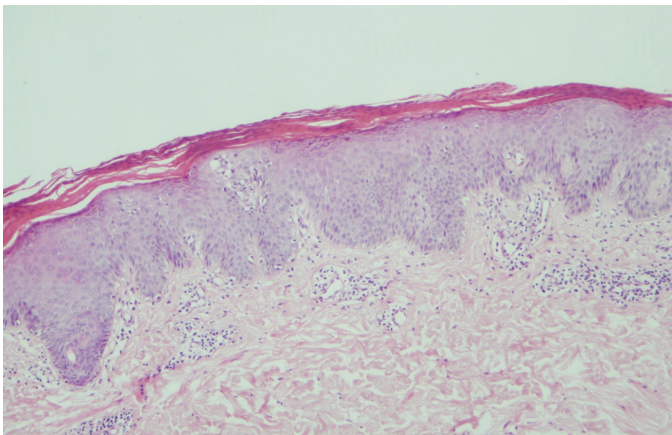


Figure 3. Histopathological examination: Orthokeratosis, parakeratosis, prominent acanthosis, and mild to moderate perivascular lymphocytic infiltration (hematoxylin and eosin, x10)

Discussion

In addition to commonly known respiratory symptoms, COVID-19 shows many extra respiratory symptoms⁴. Skin manifestations can be categorized as inflammatory skin conditions (maculopapular/morbilliform, urticarial, and vesicular) or vascular lesions (pseudopernio, petechiae/purpura, and livedo reticularis)³. A previous study reported that lesions may develop before the diagnosis of COVID-19, at the onset of symptoms, or up to 2 weeks after diagnosis⁵. Moreover, even if you do not have COVID-19 during the pandemic period, long-term exposure to personal protective equipment and excessive personal hygiene can cause various dermatoses as well as exacerbation of preexisting skin diseases⁶. Furthermore, changes in our lives during the pandemic and concern for transmission lead to stress, which is known to cause exacerbation of symptoms as well as being a factor in many skin diseases⁷.

Previously, PRP has been reported in a 32-month-old boy whose family had a COVID-19 infection 2 months ago. The boy did not have COVID-19 symptoms and was COVID-19 immunoglobulin M (IgM) negative and COVID-19 IgG positive⁸. In our case, lesions appeared 3 weeks after the onset of COVID-19 symptoms. The patient tried topical treatments for psoriasis from an external center, but his condition did not improve. The patient had erythematous scaly papule-plaques on the body, both lower extremities, face, scalp, genital area, and bilateral axillae as well as hyperkeratosis in the palmoplantar region extending to the lateral parts of the hands and feet, consistent with the symptoms of PRP (Figure 1, 2). Histopathological examination confirmed the diagnosis of PRP.

Six subtypes of PRP have been defined. The most common, type 1, is the classic adult type, and our case's symptoms matched this subtype. Infections, autoimmune diseases, and malignancies have been associated with PRP. For example, type 6 has been identified as a

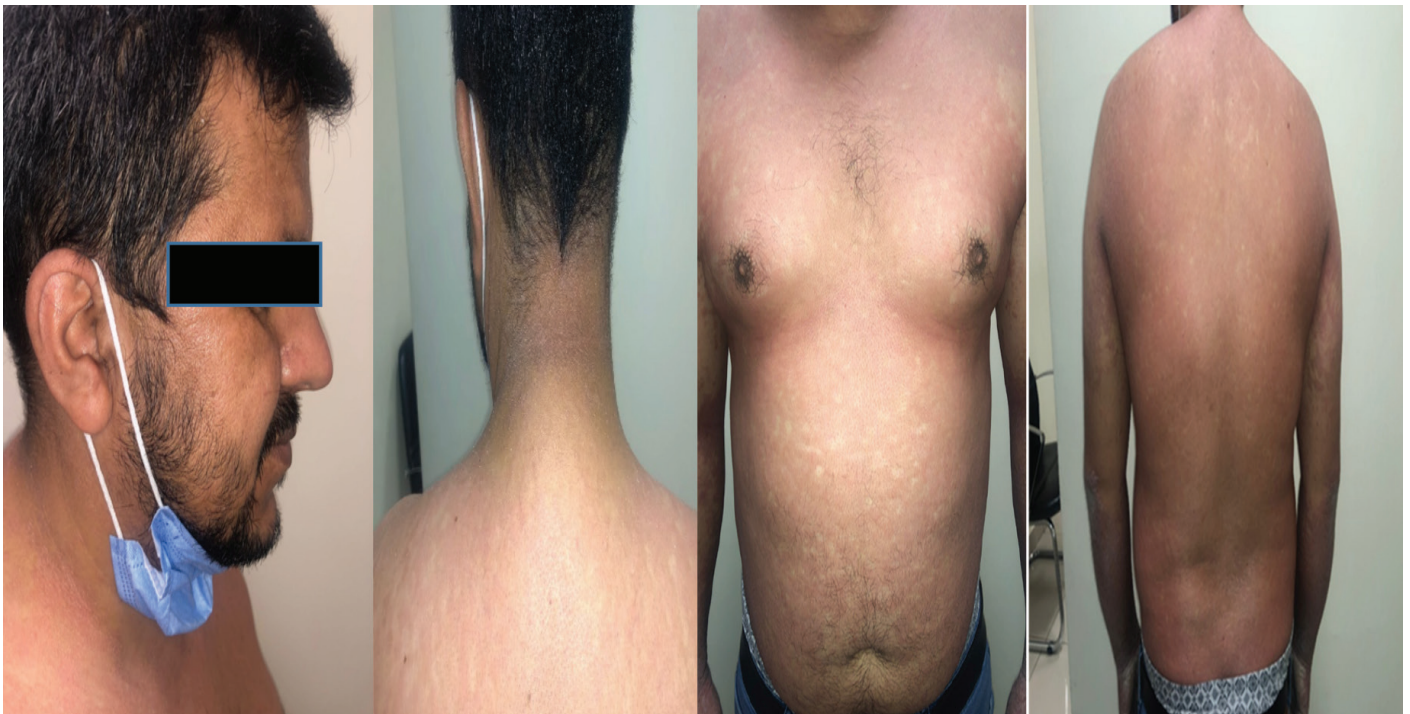

Figure 4. One month after starting adalimumab treatment

new subtype associated with HIV. Studies have reported that viral and bacterial infections have a role in the development of PRP, which is the most significant association documented in HIV infections^{9,10}. Although PRP has been reported to occur during or after viral infection with Epstein-Barr virus, cytomegalovirus, rubella, influenza, and chickenpox, the relationship between viral infection and PRP has not been clarified. Seeing more and more patients with PRP that is related to viral infection has brought forward a new subtype classification proposed as "PRP associated with non-HIV virus infection" type 7^{11,12}. Our patient had PRP that developed after COVID-19 infection, a viral infection. More cases and further studies are needed to explain the relationship of PRP with COVID-19 and other viral infections.

Ethics

Informed Consent: Consent was obtained from the patient presented in the case report to share information and photographs.

Peer-review: Externally and internally peer-reviewed.

Authorship Contributions

Surgical and Medical Practices: M.M.K., E.R.A., T.B., S.K., Concept: M.M.K., E.R.A., P.Ö., H.N., M.K.M., Design: M.M.K., P.Ö., Data Collection or Processing: T.B., M.K.M., S.K., Analysis or Interpretation: M.M.K., P.Ö., H.N., E.R.A., Literature Search: M.M.K., P.Ö., H.N., M.K.M., S.K., Writing: M.M.K., T.B.

Conflict of Interest: No conflict of interest was declared by the authors.

Financial Disclosure: Abdi İbrahim Pharmaceutical Company supported the translation of the article into English.

References

1. World Health Organization: WHO announces COVID-19 outbreak a pandemic. (Published: 2020; Accessed: May 23, 2020). World Health Organization; 2020.
2. Perna A, Passiatore M, Massaro A, et al.: Skin manifestations in COVID-19 patients, state of the art. A systematic review. *Int J Dermatol* 2021;60:547-53.
3. Klejtman T: Skin and COVID-19. *J Med Vasc* 2020;45:175-6.
4. Lai CC, Ko WC, Lee PI, Jean SS, Hsueh PR: Extra-respiratory manifestations of COVID-19. *Int J Antimicrob Agents* 2020;56:106024.
5. Sachdeva M, Gianotti R, Shah M, et al.: Cutaneous manifestations of COVID-19: Report of three cases and a review of literature. *J Dermatol Sci* 2020;98:75-81.
6. Darlenski R, Tsankov N: COVID-19 pandemic and the skin: What should dermatologists know? *Clin Dermatol* 2020;38:785-7.
7. Katsarou-Katsari A, Filippou A, Theoharides TC: Effect of stress and other psychological factors on the pathophysiology and treatment of dermatoses. *Int J Immunopathol Pharmacol* 1999;12:7-11.
8. Aguilar-Gamboa FR, Cubas-Alarcon D, Villegas-Chiroque M, Failoc-Rojas VE: Pityriasis rubra pilaris post-infection due COVID-19: Case report. *Colomb Med* 2021;52:e7014577.
9. Wang D, Chong VC, Chong WS, Oon HH: A review on pityriasis rubra pilaris. *Am J Clin Dermatol* 2018;19:377-90.
10. Blauvelt A, Nahass GT, Pardo RJ, Kerdel FA: Pityriasis rubra pilaris and HIV infection. *J Am Acad Dermatol* 1991;24:703-5.
11. Kawara S, Miyake M, Oiso N, Kawada A: Pityriasis rubra pilaris with preceding cytomegalovirus infection. *Dermatology* 2009;219:350-2.
12. Wang T, Liu J, Liu Y, Zheng H: Pityriasis rubra pilaris (PRP) with preceding Epstein-Barr virus infection: A new type PRP with non-HIV virus infection? *Chin Med J (Engl)* 2014;127:2391.