



# Clinical and histopathological evaluation of the effects of platelet rich plasma, platelet poor plasma and topical serum physiologic treatment on wound healing caused by radiofrequency electrosurgery in rats

*Sıçanlarda radyofrekans elektrocerrahi ile oluşturulmuş yarada trombosit zengin plazma, trombosit fakir plazma ve topikal serum fizyolojik tedavisinin yara iyileşmesine etkisinin klinik ve histopatolojik olarak değerlendirilmesi*

● Aslı Duran, ● Şirin Yaşar\*, ● Sema Aytekin\*, ● Pembegül Güneş\*\*, ● Rıza Adaleti\*\*\*, ● Alpay Duran\*\*\*\*

Şanlıurfa Balıklıgöl State Hospital, Clinic of Dermatology, Şanlıurfa, Turkey

\*University of Health Sciences, Haydarpaşa Numune Training and Research Hospital, Clinic of Dermatology,

\*\*Clinic of Pathology, \*\*\*Clinic of Microbiology, İstanbul, Turkey

\*\*\*\*Şanlıurfa Mehmet Akif İnan Training and Research Hospital, Clinic of Plastic and Reconstructive Surgery, Şanlıurfa, Turkey

## Abstract

**Background and Design:** The aim of our study was to histopathologically evaluate the effects of platelet rich plasma (PRP) and platelet poor plasma (PPP) treatment in wound healing process in rats with partial thickness wound.

**Materials and Methods:** Rats were divided into three groups as topical serum physiologic (SP) (group 1, n=9), PPP (group 2, n=9), and PRP (group 3, n=9). Wound model was created by radiofrequency-electrosurgery. Each group was treated once with SP, PRP and PPP. Four-millimeter punch biopsies were collected from each rat on the 4<sup>th</sup>, 7<sup>th</sup>, 14<sup>th</sup> and 21<sup>st</sup> days. One rat in each of the PRP and SP groups was lost before the study was completed.

**Results:** In our study, we observed that PRP significantly increased granulation tissue formation and angiogenesis after the fourth day of treatment. PPP increased granulation tissue formation and angiogenesis to a lesser extent than PRP but to a greater extent compared to SP. An increase in fibroblast density was observed in PRP and PPP groups compared to that in SP group on the 7<sup>th</sup>, 14<sup>th</sup> and 21<sup>st</sup> days. Epidermal detachment was significantly increased in the PRP group compared to PPP group on the 4<sup>th</sup> day. On 7<sup>th</sup> and 14<sup>th</sup> days, a higher increase was observed in the PPP and PRP groups compared to SP group. On the 21<sup>st</sup> day, epidermal detachment was observed in all the three groups. In terms of collagen synthesis levels, a significant increase was observed in PPP group compared to SP group on the 4<sup>th</sup> day and a significant increase was observed in PRP group compared to PPP group on the 21<sup>st</sup> day. There was no significant difference between groups on the 7<sup>th</sup> and 14<sup>th</sup> days.

**Conclusion:** In our study, we observed that both PRP and PPP stimulate and increase angiogenesis, reepithelization, granulation tissue and collagen synthesis compared to SP. We observed that there was a significant increase in angiogenesis and granulation tissue formation in PRP group compared to PPP group.

**Keywords:** PRP, PPP, SP, wound healing, angiogenesis, granulation, fibrosis, epithelization

## Öz

**Amaç:** Çalışmamızın amacı trombosit zengin plazma (PRP) ve trombosit fakir plazmanın (PPP) kısmi kalınlıklı yara oluşturulmuş ratlarda yara yeri iyileşmesinde oluşturacağı etkilere histopatolojik olarak değerlendirilmesidir.

**Address for Correspondence/Yazışma Adresi:** Aslı Duran MD, Şanlıurfa Balıklıgöl State Hospital, Clinic of Dermatology, Şanlıurfa, Turkey

Phone: +90 531 427 04 68 E-mail: uner1981@hotmail.com **Received/Geliş Tarihi:** 05.03.2017 **Accepted/Kabul Tarihi:** 28.11.2017

**ORCID ID:** orcid.org/0000-0003-3840-3318



**Gereç ve Yöntem:** Sıçanlar, serum fizyolojik (SF) (grup 1, n=9), PPP (grup 2, n=9), PRP (grup 3, n=9) grubu olacak şekilde 3 gruba ayrıldı. Radyofrekans-elektrocerrahi yöntemi ile yara modeli oluşturuldu. Her bir gruba SF, PRP, PPP uygulaması bir kez uygulandı. Her sıçandan, işlemi takip eden 4. 7. 14. ve 21. günlerde 4 mm punch biyopsiler alındı. SF ve PRP uygulanan deney gruplarında birer sıçan çalışma süresince kaybedilmiştir.

**Bulgular:** Çalışmamızda 4. gün sonrası PRP'nin SF ve PPP grubuna göre granülasyon dokusu ve anjiyogenezi anlamlı düzeyde arttırdığı sonucuna ulaşıldı. Bununla birlikte PPP'nin de PRP'den daha az oranda olmakla birlikte anjogenez ve granülasyon dokusu oluşumunu SF grubuna göre anlamlı düzeyde arttırdığı sonucuna saptandı. Fibroblast yoğunlukları değerlendirildiğinde 7. 14. ve 21. günlerde PRP ve PPP gruplarında SF grubuna oranla fibroblast yoğunluğunda anlamlı bir artış belirlendi. Çalışmamızda epidermal ayrışmayı PRP grubunun 4. günde PPP grubuna göre anlamlı düzeyde arttırdığı sonucuna ulaşıldı. Yedinci ve on dördüncü günlerde PPP ve PRP grubunda SF gruplarına oranla anlamlı artış sağlandı. Yirmi birinci günde ise her üç grupta epidermal ayrışma gözlemlendi. Çalışmamızda kollajen sentez düzeyleri değerlendirildiğinde yapılan ikili karşılaştırmalarda 4. günde PPP grubunda SF grubuna göre, 21. günde ise PRP grubunun PPP grubuna oranla anlamlı düzeyde arttırdığı saptanırken 7. ve 14. günlerde gruplar arası anlamlı fark saptanmadı.

**Sonuç:** Çalışmamızda gerek PRP grubunun, gerekse PPP grubunun, kontrol grubuna göre anjiyogenez, reepitelizasyon, granülasyon dokusu ve kollajen oluşumunu anlamlı düzeyde daha fazla uyardığı ve arttırdığı saptandı. Özellikle PRP grubunda anjiyogenez ve granülasyon dokusu oluşumunun PPP grubuna oranla daha anlamlı düzeyde artış gösterdiği sonucuna ulaşıldı.

**Anahtar Kelimeler:** TZF, TFP, SF, yara iyileşmesi, anjiyogenez, granülasyon, fibrozis, epitelizasyon

## Introduction

Response to traumas, whether they are a result of external factors or surgical processes, is via wound healing and tissue regeneration. After destructive pathologies, such as surgical procedures, trauma, burns or degenerative diseases, the repair of tissues and veins is the foundation of wound healing. Efforts to reduce the problems associated with wound areas have a long history. Now, in conjunction with advances in the field of biotechnology, new treatment models have been developed<sup>1,2</sup>.

Platelet rich plasma (PRP) involves a number of biologically active matters, such as thrombocyte granules, catecholamine, serotonin, adenosine triphosphate, albumin, fibrinogen, osteonectin, osteocalcin, calcium, and various coagulation factors, as well as growth factors, such as platelet-derived growth factor (PDGF), transforming growth factor alpha (TGF- $\alpha$ ), TGF- $\beta$ , insulin-like growth factor, fibroblast growth factor (FGF), vascular endothelial growth factor (VEGF), interleukin-1, platelet-derived angiogenesis factor, and epidermal growth factor (EGF), which have local effectiveness<sup>3,6</sup>. These growth factors and cytokines within PRP speed up extracellular matrix (ECM) formation resulting in tissue regeneration. The interaction between these bioactive proteins and receptors has a key role in the process of wound healing<sup>7,8</sup>.

PRP is used in the treatment of chronic cutaneous and soft tissue ulcerations and especially in periodontal and oral surgery, maxillofacial surgery, orthopedic and traumatic surgery, cosmetic and plastic surgery, spinal surgery, heart by-pass surgery, and in burns<sup>9,23</sup>. The purpose of our study was to examine the histopathological effects of topical PRP and PPP treatments in wound healing on rats with partial thickness wounds.

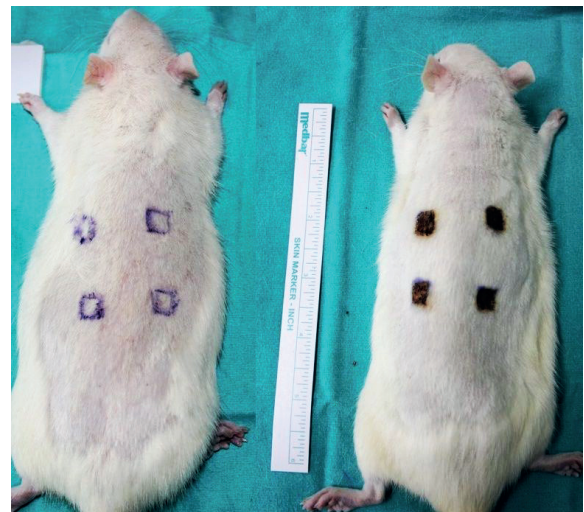
## Materials and Methods

This study was conducted in Marmara University, Experimental Animals Implementation and Research Center (DEHAMER) after obtaining the approval of the Marmara University Local Ethics Committee (approval number: 57.2014.mar, 02.10.2014). In the study, 27 three- to five-month-old male Sprague-Dawley rats weighing 250-300 g raised by DEHAMER were used. The rats were provided shelter in separate and suitable cages, at the temperature of 21  $\pm$  2 °C, in a way that would be suitable for a 12-hour day and night rhythm. Before the study, all rats were provided unlimited quantities of standard food and tap water. Three groups were randomly formed: nine rats were in the control group [serum physiologic (SP)] (group 1); nine were in the platelet poor

plasma (PPP group) (group 2); and nine were in the PRP group (group 3). One rat was lost in both the SP and PRP groups during the study. Thus, the study was completed with eight rats in control group (group 1), nine rats in PPP group (group 2), and eight rats in PRP group (group 3).

### Experimental protocol

All surgical procedures were conducted under anesthesia provided with intraperitoneal administration of 70 mg/kg ketamine and 3 mg/kg chlorpromazine. After general anesthesia, an area measuring 4x6 cm on the back of the Sprague-Dawley rats was shaved with an electric shaving machine. Test subjects were coded separately according to test subject coding form. The area was cleaned with 0.9% NaCl normal saline and dried. Four areas with a size of 1 cm<sup>2</sup> each for each procedure were marked with a skin marking pen with the help of a stencil prepared in advance so that each area would be 2 cm from the other. Ellman-Surgitron-Model (FFPFEMC-DS-2008-NY,USA) was applied using the radiofrequency-electro surgery method on the marked areas, and a wound model with 30-50 milimicron thickness, which went down deeply into the dermis, was formed (Figure 1). This measurement was determined in a digital environment on an Olympus DP-72 camera with computer microscopically as the area from the topmost layer of the epidermis to the area of necrosis.



**Figure 1.** Wound model was created by radiofrequency-electro surgery. 4 mm punch biopsies were collected from every rat on the fourth, seventh, fourteenth and twenty-first days

### Platelet rich plasma, platelet poor plasma preparation and treatment

In order to prepare rich and poor plasma from thrombocytes, 3 mL venous blood was taken from the jugular vein in each rat and put into tubes with anticoagulant involving 10% acid citrate dextrose (ACD). Thrombocyte concentrations of each full blood sample were determined before the PRP and PPP separation process. The tubes were shaken for 10 seconds in order to ensure intermingling with the anticoagulant.

The tubes with anticoagulant involving 10% ACD were centrifuged at low speed (1000 rpm for 10 minutes) and three parts were separated to be used in the PPP group. The components were separated as follows: the erythrocytes at the bottom, the thrombocyte-leukocyte mixture, called the buffy coat, in the middle, and plasma at the topmost level. The topmost layer in the tube was transferred to different tubes for use in the PPP group and the procedure was completed. After the process, PPP concentrations from thrombocytes were determined. Prior to the treatments on the rats, calcium gluconate with a thrombocyte agonist was added to the tubes with anticoagulant and 10% ACD and the thrombocytes were activated.

The tubes with anticoagulant with 10% ACD were centrifuged at a high speed (5000 rpm for 10 minutes) and three parts were separated for use on the PRP group. Again, the mixture was separated into layers as described above. The layer that remained at the bottom was the PRP with high concentration and it was transferred to different tubes to be used in the test. After the process, PRP concentrations from thrombocytes were determined. Before treatments on the rats, calcium gluconate with a thrombocyte agonist was added to the tubes with anticoagulant and 10% ACD and the thrombocytes were activated.

For the test, 0.1 mL of serum was applied to four areas in the SP group (group 1 n=9), 0.1 mL of prepared PPP was applied to four areas in the PPP group (group 2 n=9), 0.1 mL of PRP was subcutaneously applied to four areas in the PRP group (group 3 n=9). On days 4, 7, 14, and 21, 4 mm punch biopsies were taken from the areas determined in advance with test subject forms.

### Histopathological assessment

Biopsy materials were kept in bottles with formalin solution and a 10% tampon inside. Each biopsy sample was examined by a pathologist who had no information about specimens. Epithelization, collagen synthesis, fibrosis and fibroblast density, angiogenesis, and formation of granulation tissue were evaluated in hematoxylin and eosin-stained sections using a semi-quantitative scoring system. A histopathological examination form created from the criteria determined before the test with the pathologist was filled during these examinations. In these scoring system, no change was scored as 0, low density was scored as 1, mild density as 2, and high density as 3 by the pathologist.

### Statistical Analysis

The Number Cruncher Statistical System 2007 (Kaysville, Utah, USA) program was used for statistical analyses. While study data were being assessed, in addition to definitive statistical methods (average, standard deviation, median, frequency, ratio, minimum, and maximum), for the comparison of qualitative data, in the comparison of groups of three and four that did not show normal distribution, the Kruskal-Wallis test was used and in the determination of the group that showed

the reason of difference, the Mann-Whitney U test was employed. In the comparison of quantitative data, Pearson's chi-square test was used. In the comparison of the parameters that did not show normal distribution, the Friedman test was employed and in the assessment of binary comparisons, the Wilcoxon signed-ranks test was used. Significance was assessed at the levels of  $p < 0.01$  and  $p < 0.05$ .

## Results

In our study, the effects of PPP and PRP on fibroblast density epidermal separation, angiogenesis, granulation, and collagen synthesis degrees were assessed. The findings are summarized in Table 1, 2, 3, 4 and 5. Before separating the groups, no statistically significant difference was determined between thrombocyte concentrations in full blood ( $p = 0.241$ ;  $p > 0.05$ ). In the measurements made before PRP and PPP treatments, a significant difference was determined at the advanced level between PRP and PPP thrombocyte concentrations ( $p = 0.001$ ;  $p < 0.01$ ): the number of thrombocytes in the PRP group (group 3) was at a significantly higher level than that in the PPP group (group 2). In our study, the average number of thrombocytes in the PRP and PPP groups was  $1218.88 \pm 133.78$  K/ $\mu$ L and  $342.75 \pm 135.29$  K/ $\mu$ L, respectively.

### Fibroblast density

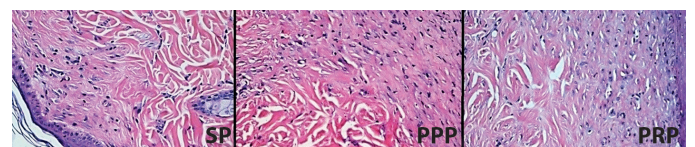
The day 4 fibroblast density levels in the PPP group were found to be significantly higher than those in the SP group ( $p = 0.020$ ;  $p < 0.05$ ). Fibroblast density levels on days 7, 14, and 21 in the PPP group and PRP group were significantly higher than those in the SP group ( $p = 0.001$ ;  $p = 0.001$ ;  $p < 0.01$ , respectively) (Figure 2) (Table 1).

### Epithelization

The day 4 epidermal detachment levels in the PRP group were significantly higher than those in the PPP group ( $p = 0.003$ ;  $p = 0.01$ ). Epidermal separation levels on days 7 and 14 in the PPP group were higher than those in the SP group and PRP group (day 7:  $p = 0.001$ ;  $p = 0.015$ ;  $p < 0.006$ ; day 14:  $p = 0.006$ ;  $p = 0.027$ ;  $p < 0.05$ , respectively). There was no significant difference between epidermal separation levels in the SP and PRP groups on days 7 and 14 (day 7:  $p = 0.064$ ;  $p > 0.05$ ; day 14:  $p = 0.317$ ;  $p > 0.05$ ). In all study groups, no epidermal separation was seen on day 21 (Table 2).

### Angiogenesis

No statistically significant difference was determined in day 4 angiogenesis levels between the groups ( $p = 0.077$ ;  $p > 0.05$ ). Day 7 angiogenesis levels in the PPP group and PRP group were significantly higher than those in the SP group ( $p = 0.001$ ;  $p = 0.001$ ;  $p < 0.01$ ). Statistically, day 7 angiogenesis levels in the PRP group were higher than those in the PPP group ( $p = 0.032$ ;  $p = 0.005$ ). Day 14 angiogenesis levels



**Figure 2.** Twenty first day fibroblast proliferation and collagen synthesis of the platelet rich plasma, platelet poor plasma groups were higher than the serum physiologic group (hematoxylin and eosin x20)



in the PPP and PRP groups were significantly higher than those in the SP group ( $p=0.001$ ;  $p=0.001$ ;  $p<0.01$ ). In addition, a statistically significant difference was not found in day 14 angiogenesis levels between the PPP and PRP groups ( $p=0.824$ ;  $p>0.05$ ). Day 21 angiogenesis levels in the PRP group were significantly higher than those in the SP and PPP groups ( $p=0.001$ ) (Figure 3) A significant difference was not found in the day 21 angiogenesis levels between the PPP group and the SP group ( $p=1.000$ ;  $p>0.05$ ) (Table 3).

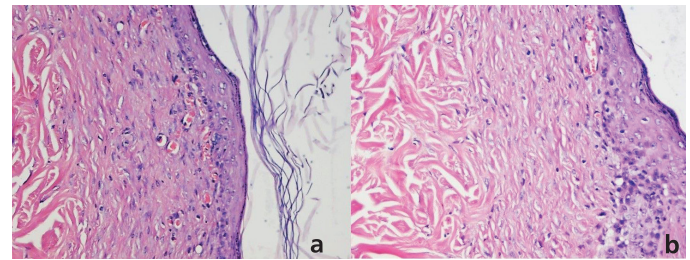
**Granulation density**

There was no statistically significant difference determined in the day 4 granulation grade levels between the groups. The day 7 granulation grade levels in the PPP group and PRP group were significantly higher than those in the SP group ( $p=0.001$ ;  $p=0.001$ ;  $p<0.01$ ). The day 7 granulation grade levels in the PRP group were significantly higher than those in the PPP group ( $p=0.023$ ;  $p=0.05$ ). In addition, the day 14 granulation grade levels in the PPP and PRP groups were significantly higher than those in the SP group ( $p=0.001$ ;  $p=0.001$ ;  $p<0.01$ ). No statistically significant difference was found in the day 14-granulation grade levels between the PPP and PRP groups ( $p=0.246$ ;  $p>0.05$ ). On day 21, the granulation grade levels in the PRP group were significantly higher than those in the SP and PPP groups ( $p<0.01$ ;  $p=0.001$ ;  $p=0.001$ ) (Figure 2). A statistically significant difference was not determined in

the day 21 granulation grade levels between the PPP and PRP groups ( $p=1.000$ ;  $p>0.05$ ) (Table 4).

**Collagen synthesis**

The day 4 collagen synthesis levels in the PPP group were significantly higher than those in the SP group ( $p=0.003$ ;  $p<0.01$ ), and a statistically significant difference was also determined between days 7 and 14 (day 7:  $p=0.807$ ;  $p>0.05$ ; day 14:  $p=0.074$ ;  $p>0.05$ ). On day 21, the collagen synthesis levels in the PPP group were significantly lower than those in the PRP group ( $p=0.010$ ;  $p<0.05$ ). There was no statistically significant difference in the day 21-collagen synthesis levels between the PPP and SP groups ( $p=0.175$ ;  $p>0.05$ ) (Figure 1) (Table 5).



**Figure 3a, 3b.** a) Twenty first day angiogenesis, b) and granulation tissue levels of the platelet rich plasma group were significantly higher (hematoxylin and eosin x20)

**Table 1. The effects of serum physiologic, platelet poor plasma, platelet rich plasma on fibroblast density [group 1 (serum physiologic) vs group 2 (platelet poor plasma)-3 (platelet rich plasma)]. Significance was assessed at the levels of \*\* $p<0.01$  and \* $p<0.05$**

Fibroblast density		Group 1 SP (n=8)	Group 2 PPP (n=9)	Group 3 PRP (n=8)	p	Effects of treatments
4 <sup>th</sup> day	Minimum-maximum (Median)	1-3 (1)	1-3 (2)	0-3 (1)	0.043*	2>1
	Average ± SD	1.25±0.71	2.22±0.83*	1.38±0.92		
7 <sup>th</sup> day	Minimum-maximum (Median)	0-0 (0)	1-2 (1)	1-3 (1.5)	0.001**	2=3>1
	Average ± SD	0.00±0.00	1.22±0.44**	1.63±0.74**		
14 <sup>th</sup> day	Minimum-maximum (Median)	0-0 (0)	1-2 (2)	1-3 (2)	0.001**	2=3>1
	Average ± SD	0.00±0.00	1.78±0.44**	2.13±0.83**		
21 <sup>st</sup> day	Minimum-maximum (Median)	0-0 (0)	0-2 (2)	1-3 (2)	0.001**	2=3>1
	Average ± SD	0.00±0.00	1.11±1.05**	1.88±0.64**		

\*:  $p<0.05$ , \*\*:  $p<0.01$ , SD: Standard deviation, SP: Serum physiologic, PPP: Platelet poor plasma, PRP: Platelet rich plasma

**Table 2. The effects of serum physiologic, platelet poor plasma, platelet rich plasma on epithelialization [group 1 (serum physiologic) vs group 2 (platelet poor plasma)-3 (platelet rich plasma)]. Significance was assessed at the levels of \*\* $p<0.01$  and \* $p<0.05$**

Epithelialization		Group 1 SP (n=8)	Group 2 PPP (n=9)	Group 3 PRP (n=8)	p	Effects of treatments
4 <sup>th</sup> day	Minimum-maximum (Median)	1-3 (2)	0-2 (2)	2-3 (3)	0.013*	3>2
	Average ± SD	2.13±0.83	1.44±0.73	2.63±0.52*		
7 <sup>th</sup> day	Minimum-maximum (Median)	0-0 (0)	1-3 (2)	0-3 (0)	0.001**	2>1=3
	Average ± SD	0.00±0.00	2.22±0.83**	0.75±1.16		
14 <sup>th</sup> day	Minimum-maximum (Median)	0-0 (0)	0-2 (1)	0-1 (0)	0.006**	2>1=3
	Average ± SD	0.00±0.00	0.78±0.67**	0.13±0.35		
21 <sup>st</sup> day	Minimum-maximum (Median)	0-0 (0)	0-0 (0)	0-0 (0)	-	-
	Average ± SD	0.00±0.00	0.00±0.00	0.00±0.00		

\*:  $p<0.05$ , \*\*:  $p<0.01$ , SD: Standard deviation, SP: Serum physiologic, PPP: Platelet poor plasma, PRP: Platelet rich plasma

## Discussion

Together with the development of wound healing phases, cellular parameters are also important in wound healing<sup>24</sup>. It is crucial to take biopsies for assessments on the days when cellular parameters show variation. To ensure the compatibility of the biopsy with these parameters, biopsy procedures were conducted on days 4, 7, 14, and 21. Normally, at least one million platelets should be in a PRP<sup>25</sup>. Previous studies have found TGF- $\beta$  to increase 7-fold, PDGF to increase 30-fold, and EGF to increase 10-fold in PRP.

About four days after injury, temporary ECM begins to exchange places with granulation tissue. This morphological change, which is connected to the invasion of capillaries, also shows itself with the formation of permanent elements of the dermis at the cellular level in the area. Collagens and blood veins are formed by fibroblasts<sup>26,27</sup>. In addition, granulation tissue involves macrophages that form a bridge between the inflammation phase and proliferative phase thanks to growth factors and cytokines they have produced. In our study, when granulation degrees were assessed, a significant increase was observed in the PRP and PPP groups on days 7, 14, and 21 when compared to the SP group. There was a significant increase in the PRP group on days 7 and 21 when compared to the PPP group.

Angiogenesis is the formation of a new vein, i.e., neovascularization. It occurs on the wound area in at least three ways: formation of a vascular network as nova, anastomosis of existing veins, or formation

of new vascular connections from veins around the vein area. When angiogenesis, which is an indicator of the proliferative phase, was assessed in our study, a significant increase was determined in the PRP and PPP groups on days 7, 14, and 21 when compared to the SP group. There was a more significant increase in angiogenesis in the PRP group on days 7 and 21 when compared to the PPP group.

PRP is the natural resource of growth factors and a number of cytokines. Platelets realize the release of growth factors from  $\alpha$ -granules by activating after the release of calcium or thrombin<sup>27,28</sup>. There are studies related to the integration of these growth factors showing variety in order to imitate the natural environment of tissue formation, especially in tissue engineering research. In some studies, it was stated that PRP triggers neovascularization induction, angiogenesis, and granulation tissue formation via release of active protein biologically<sup>29,30</sup>. During the process of wound healing, VEGF increases neovascularization by increasing vein permeability. Sano et al.<sup>31</sup> determined on the 4<sup>th</sup> day of healing that microcirculation transcutaneous oxygen pressure increased from 38 mmHg to 55 mmHg in 10 patients whose chronic wound was treated with PRP. This increase supports the theory that PRP increases neovascularization<sup>31</sup>. Kubota et al.<sup>32</sup> showed that growth factors of connective tissue also increased angiogenetic activity and fibrosis.

Similar to the studies in the literature, our study found that after day 4, PRP increased granulation tissue and angiogenesis. Additionally,

**Table 3. The effects of serum physiologic, platelet poor plasma, platelet rich plasma on angiogenesis [group 1 (serum physiologic) vs group 2 (platelet poor plasma)-3 (platelet rich plasma)]. Significance was assessed at the levels of \*\*p<0.01 and \*p<0.05**

Angiogenesis	Group 1 SP (n=8)	Group 2 PPP (n=9)	Group 3 PRP (n=8)	p	Effects of treatments
Minimum-maximum (Median)	1-2 (1)	0-1 (1)	0-1 (1)	0.077	NS
Average $\pm$ SD	1.25 $\pm$ 0.46	0.78 $\pm$ 0.44	0.75 $\pm$ 0.46		
Minimum-maximum (Median)	0-0 (0)	1-2 (1)	1-2 (2)	0.001**	3>2>1
Average $\pm$ SD	0.00 $\pm$ 0.00	1.11 $\pm$ 0.33	1.63 $\pm$ 0.52**		
Minimum-maximum (Median)	0-0 (0)	1-2 (1)	1-2 (1.5)	0.001**	2=3>1
Average $\pm$ SD	0.00 $\pm$ 0.00	1.44 $\pm$ 0.53**	1.50 $\pm$ 0.53**		
Minimum-maximum (Median)	0-0 (0)	0-0 (0)	1-2 (1)	0.001**	3>2=1
Average $\pm$ SD	0.00 $\pm$ 0.00	0.00 $\pm$ 0.00	1.13 $\pm$ 0.35**		

\*\* : p<0.01, SD: Standard deviation, NS: Not significant, SP: Serum physiologic, PPP: Platelet poor plasma, PRP: Platelet rich plasma

**Table 4. The effects of serum physiologic, platelet poor plasma, platelet rich plasma on granulation density [group 1 (serum physiologic) vs group 2 (platelet poor plasma)-3 (platelet rich plasma)]. Significance was assessed at the levels of \*\*p<0.01 and \*p<0.05**

Granulation density		Group 1 SP (n=8)	Group 2 PPP (n=9)	Group 3 PRP (n=8)	p	Effects of treatments
4 <sup>th</sup> day	Minimum-maximum (Median)	1-1 (1)	0-1 (1)	0-1 (1)	0.210	NS
	Average $\pm$ SD	1.00 $\pm$ 0.00	0.67 $\pm$ 0.50	0.75 $\pm$ 0.46		
7 <sup>th</sup> day	Minimum-maximum (Median)	0-0 (0)	1-2 (1)	1-3 (2)	0.001**	3>2>1
	Average $\pm$ SD	0.00 $\pm$ 0.00	1.11 $\pm$ 0.33	2.00 $\pm$ 0.93**		
14 <sup>th</sup> day	Minimum-maximum (Median)	0-0 (0)	1-2 (1)	1-2 (1.5)	0.001**	2=3>1
	Average $\pm$ SD	0.00 $\pm$ 0.00	1.22 $\pm$ 0.44**	1.50 $\pm$ 0.53**		
21 <sup>st</sup> day	Minimum-maximum (Median)	0-0 (0)	0-1 (0)	1-1 (1)	0.001**	3>2=1
	Average $\pm$ SD	0.00 $\pm$ 0.00	0.11 $\pm$ 0.33	1.00 $\pm$ 0.00**		

\*\* : p<0.01, SD: Standard deviation, NS: Not significant, SP: Serum physiologic, PPP: Platelet poor plasma, PRP: Platelet rich plasma

**Table 5. The effects of serum physiologic, platelet poor plasma, platelet rich plasma on collagen synthesis degrees [group 1 (serum physiologic) vs group 2 (platelet poor plasma)-3 (platelet rich plasma)]. Significance was assessed at the levels of \*\*p<0.01 and \*p<0.05**

Collagen synthesis		Group 1 SP (n=8)	Group 2 PPP (n=9)	Group 3 PRP (n=8)	p	Effects of treatments
4 <sup>th</sup> day	Minimum-maximum (Median)	1-3 (1)	2-3 (2)	1-3 (1.5)	0.015*	2>1
	Average ± SD	1.25±0.71	2.44±0.53*	1.88±0.99		
7 <sup>th</sup> day	Minimum-maximum (Median)	0-2 (2)	1-2 (2)	1-2 (2)	0.807	NS
	Average ± SD	1.63±0.74	1.78±0.44	1.63±0.52		
14 <sup>th</sup> day	Minimum-maximum (Median)	1-3 (2)	1-2 (1)	1-2 (2)	0.074	NS
	Average ± SD	2.13±0.64	1.44±0.53	1.75±0.46		
21 <sup>st</sup> day	Minimum-maximum (Median)	1-3 (2)	0-2 (2)	2-3 (2)	0.017*	3>2
	Average ± SD	2.00±0.53	1.11±1.05	2.38±0.52**		

\*: p<0.05, \*\*: p<0.01, SD: Standard deviation, NS: Not significant, SP: Serum physiologic, PPP: Platelet poor plasma, PRP: Platelet rich plasma

although the PPP had a smaller ratio than the thrombocyte concentration of PRP, it increased the angiogenesis and granulation tissue formation significantly. In a study conducted by Takikawa et al.<sup>33</sup>, PRP and PPP were assessed in terms of the quantities of growth factors they involved. The rates of FGF2, VEGF, and PDGF measured were 10 times more in PRP than in PPP<sup>33</sup>. This explains superior results in the PRP group compared to the PPP group in wound healing in our study. Fibroblasts are the most important mesenchymal cells with a role in wound healing as they have both production and mechanic duties. Fibroblasts are responsible for the production of collagen-based matrix that will take the place of the temporary matrix. Their mechanical duty is to provide wound contractions thanks to their contractive characteristics. When fibroblast densities were assessed in our study, a significant increase was determined on days 7, 14, and 21 in the PRP and PPP groups compared to the SP group. Density increase was high in the PRP group compared to the PPP group but the difference was significant<sup>34,35</sup>. In a study conducted by Kim et al.<sup>36</sup>, collagen and fibroblast activity was measured by incubating PRP and PPP in fibroblast culture obtained from foreskin. According to the results, it was concluded that both PRP and PPP increased type 1 collagen and fibroblast activity. In the literature, a number of studies state that PRP forms fibroblast proliferation in tendon, dermis, gingiva, and synovium. The results of this study showed an increase in fibroblast proliferation similar to that found in previous studies<sup>36</sup>.

The purpose of the epidermis at the stage of reepithelization after skin injury is to provide full layer epidermis formation. In order to realize this purpose at this stage, migration of keratinocytes to the wound area in the proliferative phase, proliferation of keratinocyte and the basal membrane zone have to be restructured. In our study, significantly increased epidermal separation was seen in the PRP group on day 4 when compared to the PPP group. However, in comparison with the SP group, a significant difference was not found. Epithelization was realized via wound contractions and remodelling EGF<sup>37</sup>. In the studies, these collective biological characteristics are said to support the clinical use of platelet derivatives in providing haemostasis and assisting in the process of healing<sup>38,39</sup>.

Collagen production begins on days 3 to 5 after tissue damage. Net collagen production increases continuously until about day 21. After this stage, a decrease is observed in collagen synthesis<sup>40,41</sup>. In our

study, when collagen synthesis levels were assessed, in the binary comparisons conducted, it was determined that they increased in the PPP group on day 4 when compared to the SP group, and on day 21, increased significantly in the PRP group when compared to the PPP. On days 7 and 14, no significant difference was found between the groups. In a study conducted by Carter et al.<sup>42</sup>, which assessed the effects of PRP on the differentiation and regeneration stage in wound healing, the animal model was equine.

Conde-Montero et al.<sup>43</sup> applied intralesional PRP to neuropathic ulcers in four patients with leprosy and stated that wound area healing was better when compared to traditional treatments. In a controlled study involving 200 patients, P Waiker et al.<sup>44</sup> compared traditional methods with PRP. They determined that PRP increased wound graft adherence; retarded hematoma formation; and shortened the graft process, duration of medical dressing<sup>44</sup>.

## Conclusion

In our study, it was determined that both the PRP and PPP groups, when compared to the control group, experienced stimulated and increased angiogenesis, epithelization, granulation tissue, and collagen formation in the wound model. However, it was concluded that especially in the PRP group, angiogenesis and formation of granulation tissue increased more significantly when compared to the PPP group.

## Ethics

**Ethics Committee Approval:** The study was approved by the Marmara University Local Ethics Committee (approval number: 57.2014.mar, 02.10.2014).

**Informed Consent:** This study involves animals only.

**Peer-review:** External and internal peer-reviewed.

## Authorship Contributions

Surgical and Medical Practices: A.D., A.D., Concept: Ş.Y., S.A., Design: Ş.Y., A.D., P.G., Data Collection or Processing: A.D., A.D., Ş.Y., Analysis or Interpretation: A.D., R.A., P.G., S.A., Literature Search: S.A., Ş.Y., P.G., A.D., Writing: A.D., A.D., Ş.Y., S.A.

**Conflict of Interest:** No conflict of interest was declared by the authors.

**Financial Disclosure:** The authors declared that this study received no financial support.

## References

- Velnar T, Bailey T, Smrkolj V: The wound healing process: an overview of the cellular and molecular mechanisms. *J Int Med Res* 2009;37:1528-42.
- Barrientos S, Stojadinovic O, Golinko MS, Brem H, Tomic-Canic M: Growth factors and cytokines in wound healing. *Wound Repair Regen* 2008;16:585-601.
- Suzuki S, Morimoto N, Ikada Y: Gelatin gel as a carrier of platelet-derived growth factors. *J Biomater Appl* 2013;28:595-606.
- Bennett NT: Growth factors and wound healing. Part II. Role in normal and chronic wound healing. *Am J Surg* 1993;166:74-81.
- Knighthon DR, Ciresi K, Fiegel VD, Schumether S, Butler E, Cerra F: Stimulation of repair in chronic, nonhealing, cutaneous ulcers using platelet derived wound healing formula. *Surg Gynecol Obstet* 1990;170:55-60.
- Declair V: The importance of growth factors in wound healing. *Ostomy Wound Manage* 1999;45:64-8.
- Cohen IK, Die-gelmann RF, Lindblad WJ, Hugo NE: Wound healing: biochemical and clinical aspects. *Plast Reconstr Surg* 1992:926.
- Weibric G, Buch RS, Kleis WK, Hafner G, Hitzler WE, Wagner W: Quantification of thrombocyte growth factors in platelet concentrates produced by discontinuous cell separation. *Growth Factors* 2002;20:93-7.
- Lekovic V, Camargo PM, Weinlaender M, Vasilic N, Aleksic Z, Kenney EB: Effectiveness of a combination of platelet-rich plasma, bovine porous bone mineral and guided tissue regeneration in the treatment of mandibular grade II molar furcations in humans. *J Clin Periodontol* 2003;30:746-51.
- Camargo PM, Lekovic V, Weinlaender M, Vasilic N, Madzarevic M, Kenney EB: Platelet-rich plasma and bovine porous bone mineral combined with guided tissue regeneration in the treatment of intrabony defects in humans. *J Periodontol* 2002;37:300-6.
- Pietrzak WS, Eppley BL: Platelet rich plasma: biology and new technology. *J Craniofac Surg* 2005;16:1043-54.
- Eppley BL, Pietrzak WS, Blanton M: Platelet-rich plasma: a review of biology and applications in plastic surgery. *Plast Reconstr Surg* 2006;118:147-59.
- Salemi S, Rinaldi C, Manna F, Guarneri GF, Parodi PC: Reconstruction of lower leg skin ulcer with autologous adipose tissue and platelet-rich plasma. *J Plast Reconstr Aesthet Surg* 2008;61:1565-7.
- Lindeboom JA, Mathura KR, Aartman IH, Kroon FH, Milstein DM, Ince C: Influence of the application of platelet-enriched plasma in oral mucosal wound healing. *Clin Oral Implants Res* 2007;18:133-9.
- El-Sharkawy H, Kantarci A, Deady J, et al: Platelet-rich plasma: growth factors and pro- and anti-inflammatory properties. *J Periodontol* 2007;78:661-9.
- Nikolidakis D, Jansen JA: The biology of platelet-rich plasma and its s in oral surgery: literature review. *Tissue Eng Part B Rev* 2008;14:249-58.
- Shashikiran ND, Reddy VV, Yavagal CM, Zakirulla M: Applications of platelet-rich plasma (PRP) in contemporary pediatric dentistry. *J Clin Pediatr Dent* 2006;30:283-6.
- Wrotniak M, Bielecki T, Gazdzik TS: Current opinion about using the platelet-rich gel in orthopaedics and trauma surgery. *Ortop Traumatol Rehabil* 2007;9:227-38.
- Mishra A, Woodall J, Vieira A: Treatment of tendon and muscle using platelet-rich plasma. *Clin Sports Med* 2009;28:113-25.
- Frechette JP, Martineau I, Gagnon G: Platelet-rich plasmas: growth factor content and roles in wound healing. *J Dent Res* 2005;84:434-9.
- Bhanot S, Alex JC: Current applications of platelet gels in facial plastic surgery. *Facial Plast Surg* 2002;18:27-33.
- Bir SC, Esaki J, Marui A, et al: Angiogenic properties of sustained release platelet-rich plasma: characterization in-vitro and in the ischemic hind limb of the mouse. *J Vasc Surg* 2009;50:870-879.
- Henderson JL, Cupp CL, Ross EV, et al: The effects of autologous platelet gel on wound healing. *Ear Nose Throat J* 2003;82:598-602.
- Eppley BL, Woodell JE, Higgins J: Platelet quantification and growth factor analysis from platelet-rich plasma: implications for wound healing. *Plast Reconstr Surg* 2004;114:1502-8.
- Turan Y, Erbil H, Koç E: Plateletten zengin plazma ve Dermatoloji. *Dermatoz* 2011;2:355-60.
- Singer AJ, Clark RA: Cutaneous wound healing. *N Engl J Med* 1999;341:738-46.
- Lawrence WT: Physiology of the acute wound. *Clin Plast Surg* 1998;25:321-40.
- Man D, Plosker H, Winland-Brown JE: The use of autologous platelet-rich plasma (platelet gel) and autologous platelet-poor plasma (fibrin glue) in cosmetic surgery. *Plast Reconstr Surg* 2001;107:229-37.
- Bhanot S, Alex JC: Current applications of platelet gels in facial plastic surgery. *Facial Plast Surg* 2002;18:27-33.
- Scimeca CL, Bharara M, Fisher TK, Kimbriel H, Armstrong DG: Novel use of platelet-rich plasma to augment curative diabetic foot surgery. *J Diabetes Sci Technol* 2010;4:1121-6.
- Sano H, Ichioka S, Minamimura A, Tanaka R, Ikebuchi K, Suzuki M: Treatment of chronic ulcer with elastic plasma protein and platelet film for wound dressing. *J Plast Surg Hand Surg* 2013;47:462-6.
- Kubota S, Kawata K, Yanagita T, Doi H, Kitoh T, Takigawa M: Abundant retention and release of connective tissue growth factor (CTGF/CCN2) by platelets. *J Biochem* 2004;136:279-82.
- Takikawa M, Sumi Y, Ishihara M, et al: PRP&F/P MPs improved survival of dorsal paired pedicle skin flaps in rats. *J Surg Res* 2011;170:189-96.
- Liu Y, Kalén A, Risto O, Wahlström O: Fibroblast proliferation due to exposure to a platelet concentrate in vitro is pH dependent. *Wound Repair Regen* 2002;10:336-40.
- Colige A, Nusgens B, Lapiere CM: Effect of EGF on human skin fibroblasts is modulated by the extracellular matrix. *Arch Dermatol Res* 1988;280(Suppl):42-6.
- Kim DH, Je YJ, Kim CD, et al: Can Platelet-rich Plasma Be Used for Skin Rejuvenation? Evaluation of Effects of Platelet-rich Plasma on Human Dermal Fibroblast. *Ann Dermatol* 2011;23:423-4.
- Li J, Chen J, Kirsner R: Pathophysiology of acute wound healing. *Clin Dermatol* 2007;25:9-18.
- Brown GL, Curtsinger LJ, White M, et al: Acceleration of tensile strength of incisions treated with EGF and TGF- $\beta$ . *Ann Surg* 1988;208:788-94.
- Akingboye AA, Giddings S, Gamston P, Tucker A, Navsaria H, Kyriakides C: Application of autologous derived-platelet rich plasma gel in the treatment of chronic wound ulcer: diabetic foot ulcer. *J Extra Corpor Technol* 2010;42:20-9.
- Villela DL, Santos VL: Evidence on the use of platelet-rich plasma for diabetic ulcer: a systematic review. *Growth Factors* 2010;28:111-6.
- Hunt TK, Knighton DR, Thakral KK, Goodson WH 3rd, Andrews WS: Studies on inflammation and wound healing: angiogenesis and collagen synthesis stimulated in vivo by resident and activated wound macrophages. *Surgery* 1984;96:48-54.
- Carter CA, Jolly DG, Worden CE Sr, Hendren DG, Kane CJ: Platelet-rich plasma gel promotes differentiation and regeneration during equine wound healing. *Exp Mol Pathol* 2003;74:244-55.
- Conde-Montero E, Horcajada-Reales C, Clavo P, Delgado-Sillero I, Suárez-Fernández R: Neuropathic ulcers in leprosy treated with intralesional platelet-rich plasma. *Int Wound J* 2016;13:726-8.
- P Waiker V, Shivalingappa S: Comparison between Conventional Mechanical Fixation and Use of Autologous Platelet Rich Plasma (PRP) in Wound Beds Prior to Resurfacing with Split Thickness Skin Graft. *World J Plast Surg* 2015;4:50-9.