



How to perform the whole nail unit excision and grafting?

Tüm tırnak ünitesinin eksizyonu ve greftlemesi nasıl yapılır?

© Ozan Erdem, © Yusuf Kelleci, © Begüm Çalım Gürbüz*, © Fatih Göktay**

University of Health Sciences Türkiye, Başakşehir Çam and Sakura City Hospital, Clinic of Dermatology and Venereology; *Clinic of Pathology, İstanbul, Türkiye

**Private Dermatology Practice, İstanbul, Türkiye

1- What does the excision of the whole nail unit mean?

The nail unit is a complex organ that consists of three distinct epithelial structures: The nail matrix, which is the germinative part from where the nail plate is produced; the nail bed, which is the supporting mesenchymal portion that attaches the nail plate firmly to the distal phalanx; and the nail folds, which are the framing portions that surround the nail plate¹. The excision of the whole nail unit refers to the procedure of removing all these three structures in one piece along with a safety margin by preserving the underlying bone². Thus, it means the complete removal of nail apparatus without compromising the patient's functionality.

2- When to excise the nail unit completely?

The whole nail unit excision may be necessary for cases of malignant nail unit tumors and severe post-traumatic nail dystrophy². The latter is rarely indicated, and dermatologists usually excise the whole nail unit to remove the subungual squamous cell carcinoma and *in situ* melanoma³. Mohs micrographic surgery is the ideal option for subungual squamous cell carcinoma whenever available⁴, whereas, as an exceptional condition, *in situ* melanoma is best treated with the whole nail unit excision procedure⁵. Any malignant keratinocytic tumor with bone involvement (as proven by a biopsy or radiologically) or invasive melanomas are candidates for amputation. On the other hand, whole nail unit excision

technique has been proposed for the treatment of thinner T1(≤ 0.8 mm) nail unit melanomas, but further investigations are warranted⁶.

3- How to perform excision of the whole nail unit?

This procedure can be performed in a local operating room under local anesthesia, and a basic surgery tray is sufficient for this purpose. Before starting this procedure, the incision lines should be marked carefully, considering the safety margin that depends on the tumor type and location. Keratinocytic tumors without any bone involvement are marked no less than 4 mm of the normal tissues from the tumor margin⁷. On the other hand, *in situ* melanomas should be excised with at least a 6 mm safety margin from the most proximal edge of the nail matrix, two lateral nail folds, and the hyponychium⁸. If Hutchinson's sign is detected, a 10 mm safety margin should be drawn from Hutchinson's sign⁹. Care must be taken while marking the proximal corners because the nail matrix usually tends to extend laterally, especially on the toes. When the marking is completed, a tourniquet should be placed to ensure a complete bloodless field during the surgery. It is also crucial that the patient experience no pain during the surgery. We prefer distal digital or wing block to achieve complete anesthesia of the nail unit for this purpose. Buffering lidocaine (plain or supplemented with epinephrine) with sodium bicarbonate significantly decreases pain during injection¹⁰.

Address for Correspondence/Yazışma Adresi: Ozan Erdem MD, University of Health Sciences Türkiye, Başakşehir Çam and Sakura City Hospital, Clinic of Dermatology and Venereology, İstanbul, Türkiye

Phone: +90 545 210 49 11 **E-mail:** erdemozan@hotmail.com **Received/Geliş Tarihi:** 20.08.2022 **Accepted/Kabul Tarihi:** 04.04.2023

ORCID: orcid.org/0000-0002-6012-0528

Cite this article as: Erdem O, Kelleci Y, Çalım Gürbüz B, Göktay F. How to perform the whole nail unit excision and grafting?. Turkderm-Turk Arch Dermatol Venereol 2023;57:69-72

©Copyright 2023 by Turkish Society of Dermatology and Venereology / Turkderm-Turkish Archives of Dermatology and Venereology is published by Galenos Yayınevi. Licensed under a Creative Commons Attribution-NonCommercial-NoDerivatives 4.0 (CC BY-NC-ND) International License.



After anesthesia is provided, an incision is made from one corner of the proximal part using surgical blade number 15. The incision should be made down to the bone and not just superficially. The scalpel is then rotated around the nail unit, following the marking lines by feeling the bone constantly. After the nail unit is circumscribed, the tissue is grabbed from one corner using a clamp and pulled upwards very gently. Following that, the base of the tissue should be carefully dissected just above the bony phalanx by using fine scissors or a sharp scalpel. Ideally, the periosteum should be removed during dissection as well². Staying just above the bone provides the tumor to be excised in one piece with adequate depth and avoids puncturing the nail bed from its base. The extensor tendon, which is visible as a shiny, white structure attached to the proximal base of the phalanx, should be protected with great caution during dissection². It is also critical to inspect the surgical site thoroughly for any matrix remnants that may trigger spicule formation or recurrence of the tumor after the surgery³.

4- How to harvest a full-thickness skin graft and cover the nail unit defect?

The nail bed heals perfectly by secondary intention. However, the subsequent healing time is much longer, and regular wound care can be frustrating for some patients. In such cases, repairing the defect with a full-thickness skin graft is an excellent option¹¹⁻¹³. In such cases, the donor site is usually selected according to textural similarity, the possibility of hiding the scar, and patient preference. The non-hair-bearing forearm is suitable for most patients. The graft size depends on the defect, and it is more appropriate to determine the graft size after the removal of the nail unit. Meticulous measurement with a ruler is, therefore, a must. The width of the graft should be the same as or slightly larger than the defect size. The long axis of the graft should be positioned parallel to Langer's lines on the donor site in accordance with the basic fusiform excision rules^{2,3}.

After the donor site is anesthetized, the lateral borders are incised superficially. The skin is then elevated with forceps or hook and harvested using the surgical blade number 15, leaving no fat underneath the graft. Keeping the non-operating hand on the epidermal side of the graft provides tension and a sense of graft thickness. Any fatty tissue underside the graft must be trimmed using curved scissors while holding the graft over the nonoperating index finger. The harvested graft is then placed in a Petri dish with sterile saline during the donor site closure. Next, the graft is laid to the recipient site and secured with four-corner sutures. The graft should sit on the bone with slight tension to avoid fluid collection. The redundant skin of the graft is removed with scissors to fit the defect area after which the remaining sutures are created. A few small incisions made over the surface of the graft can help drain the excess fluid and prevent postoperative edema. A large amount of greasy ointment should be applied over the graft, and a bulky dressing should be made with sterile gauze^{2,3}.

5- How to care operation site after surgery and what awaits the patient?

The postoperative pain and infection risk are considerably low. Oral analgesics and antibiotics can be used if needed in such cases. The operated limb should be elevated during the first 48 h to prevent swelling. The first dressing change is performed after 48 h. At this stage, it is normal that the graft looks bluish and edematous, and superficial blisters are often present. The dressing is then repeated, and the new dressing is left in place for 7 days. A non-adherent petrolatum-soaked gauze (e.g., tulle gras) is the most appropriate dressing, if

available². The patient is then instructed to keep the limb elevated and avoid trauma of any sort to the operated site. The graft intake can be achieved in most patients through this approach¹¹. Any graft failure should be followed conservatively and left secondary intention healing. The sutures can be removed on the 14th day. The patient is usually fully recovered within a month of this intervention. In addition, the cosmetic results are generally satisfying. The limb's function is incredibly preserved, and even sensation develops with time. The most common undesirable outcome is hair growth over the graft, which can be treated with lasers subsequently. Epidermal implantation cysts are also common, usually occurring 1-2 years after the surgery and can be made recurrent after appropriate management¹⁴.

Case report

Herein, we have presented the case of a 55 year-old-man with a subungual mass on the left fifth nail bed for 6 months (Figure 1A). We had performed an incisional biopsy previously (Figure 1B, C), and the pathology report was consistent with that of keratoacanthoma (Figure 2 A-C). There was no evidence of bone involvement radiologically (Figure 3A, B). We, therefore, suggested to the patient that the remnant of the lesion be excised locally (Figure 4A, B). As the lesion keratoacanthoma is currently considered a low-grade squamous cell carcinoma¹⁵, we marked this lesion with a 4 mm safety margin (Figure 4C). After discussing the treatment options with the patient, we decided on the excision of the whole nail unit rather than performing wide local excision of the lesion since a very narrow nail plate would remain,

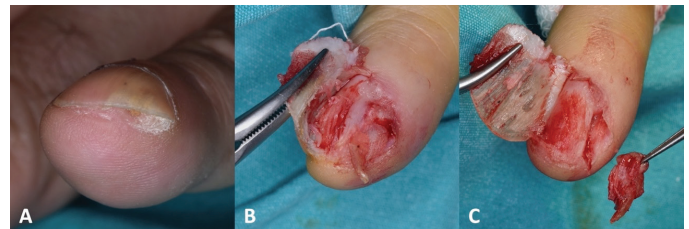


Figure 1. (A) Onycholysis and splinter hemorrhages due to subungual hyperkeratotic mass. (B) Exploration of the tumor after nail plate avulsion. (C) An incisional biopsy was performed

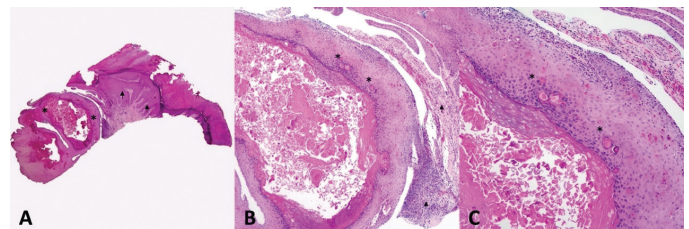


Figure 2. Histopathological examination of the incisional biopsy. (A) Low-power view: the epidermis on the right side depicts parakeratotic hyperkeratosis and irregular acanthosis with elongated rete ridges (arrow). On the left side, the endophytic proliferation of the lesion can be seen (asterisk). (B, C) High-power view: Keratinocytes in the upper epidermis have abundant pale-eosinophilic cytoplasm. Basal keratinocytes demonstrating minimal cellular atypia (asterisk). A mixed inflammatory infiltrate mainly consisting of lymphocytes and eosinophils in the dermis can be seen (arrow)

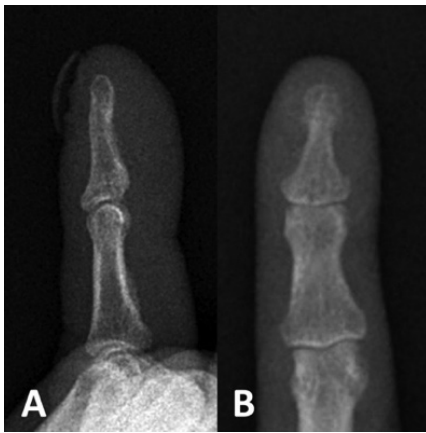


Figure 3. Radiography of the left fifth phalanx displays no bone involvement. **(A)** Lateral view. **(B)** Antero-posterior view

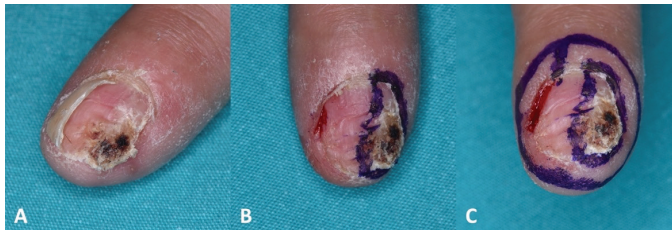

Figure 4. **(A)** Oblique view of the tumor 1 month after the incisional biopsy. **(B)** Marking the visible tumor margins revealed that the tumor encompasses nearly half of the nail bed. **(C)** A 4 mm safety margin was marked around the tumor. Note: After the safety margin was drawn, a very little piece of the normal nail plate remained, because of which we removed the entire nail unit

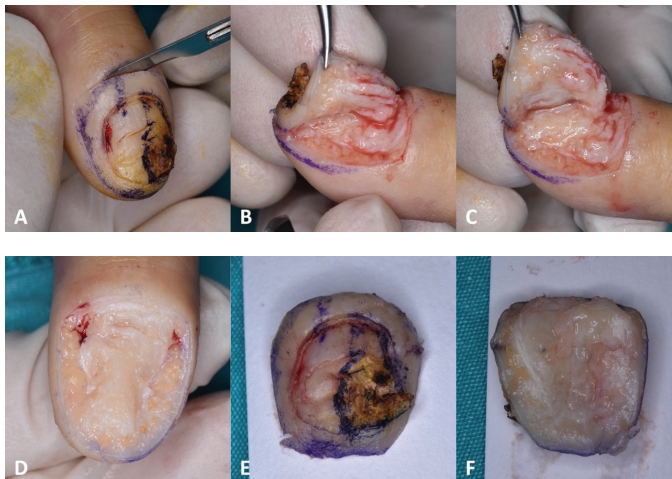


Figure 5. **(A)** The incision circles the nail unit from the proximal corner. Always touch the bone with the scalpel. **(B,C)** Gently lift one side of the tissue. Using delicately curved scissors or a keen scalpel to remove tissues. Keep it slightly above the bony phalanx. Dissection should proceed with the tooltip touching the bone. **(D)** Complete nail unit removal shows bony phalanx and bilateral neurovascular bundles. **(E,F)** Superior and inferior aspects of the excised tissues. Note that the nail unit is in one piece and was not punctured during dissection

which could result in cosmetically and functionally poor outcome. The whole nail unit was then removed completely, as mentioned earlier (Figure 5A-F). We opted to repair the defect with a full-thickness skin graft in the same session because no margin positivity was expected. The donor site was selected from the inner lateral aspect of the non-hair-bearing forearm (Figure 6A). The graft was harvested (Figure 6B, C) and then placed into the defect (Figure 7A-C). The postoperative period was comfortable as expected, and full graft intake was accomplished subsequently (Figure 8A). No intractable pain or complication was observed. The surgical margins were free of tumors. Almost complete healing and reepithelization were achieved by the end of the month (Figure 8B). After 2 months, the patient reported being extremely pleased with the cosmetic outcome (Figure 8C).

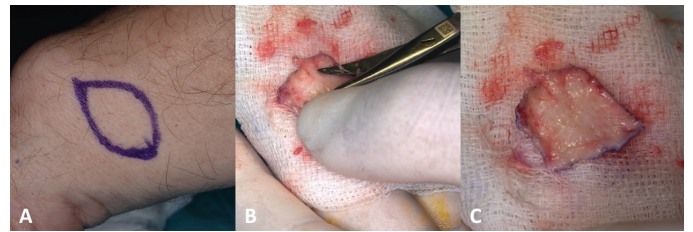


Figure 6. **(A)** Non-hair bearing inner forearm is usually suitable for harvesting a graft. **(B)** Excess fatty tissue underneath the graft should be removed with curved scissors. **(C)** The graft is ready to be put in place

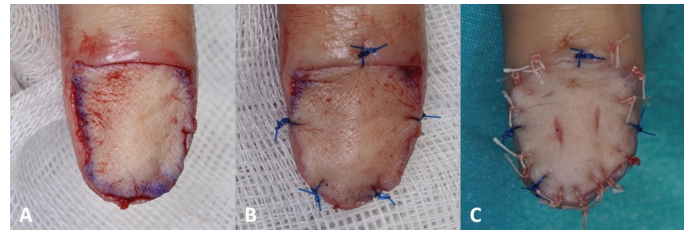


Figure 7. **(A)** The graft is laid down into the defect. **(B)** Corner sutures are placed in a slight tension and the redundant skin is removed with scissors. **(C)** The remaining 5/0 rapidly absorbable sutures are placed. Note: A few small incisions are made for the drainage of the fluid that possibly accumulates under the graft

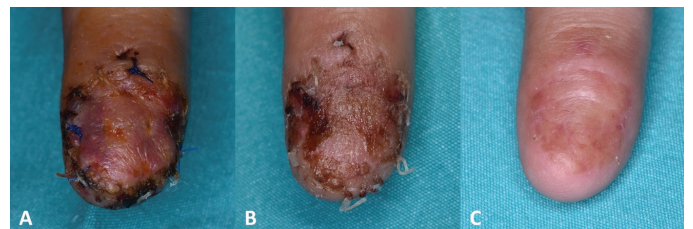


Figure 8. **(A)** The graft looks slightly edematous and bluish. This is quite normal, and there is no sign of graft failure—a black eschar—in the graft. Total graft intake was accomplished. **(B)** Almost complete healing and reepithelization were achieved by the end of 1 month. **(C)** Two months after the surgery, the patient was very satisfied with the cosmetic outcome. Note: Tiny hairs can be seen in the graft, which did not bother the patient

References

1. Haneke E: Anatomy of the nail unit and the nail biopsy. *Semin Cutan Med Surg* 2015;34:95-100.
2. Haneke E, Richert B, Di Chiacchio N: Surgery of the whole nail unit. *Nail Surgery*. In: Richert B, Di Chiacchio N, Haneke E (eds). CRC Press; 2011:137-43.
3. Abimelec P, Dumontier C: Advanced Surgery and Complications. In book: Scher and Daniel's Nails. Springer. In: Rubin, Adam I, et al. (eds). Cham; 2018:607-36.
4. Dika E, Fanti PA, Patrizi A, Misciali C, Vaccari S, Piraccini BM: Mohs surgery for squamous cell carcinoma of the nail unit: 10 years of experience. *Dermatol Surg* 2015;41:1015-9.
5. Jo G, Cho SI, Choi S, Mun JH: Functional surgery versus amputation for in situ or minimally invasive nail melanoma: A meta-analysis. *J Am Acad Dermatol* 2019;81:917-22.
6. Swetter SM, Tsao H, Bichakjian CK, et al.: Guidelines of care for the management of primary cutaneous melanoma. *J Am Acad Dermatol* 2019;80:208-50.
7. Starace M, Alessandrini A, Dika E, Piraccini BM: Squamous cell carcinoma of the nail unit. *Dermatol Pract Concept* 2018;8:238-44.
8. Duarte AF, Correia O, Barros AM, Ventura F, Haneke E: Nail melanoma in situ: clinical, dermoscopic, pathologic clues, and steps for minimally invasive treatment. *Dermatol Surg* 2015;41:59-68.
9. Haneke E: Melanonychia. In: Rubin AI, Jellinek NJ, Daniel CR, Scher RK (eds). *Scher and Daniel's Nails*. Springer, Cham, 2018. https://doi.org/10.1007/978-3-319-65649-6_16.
10. Göktaş F, Atış G: How to perform a biopsy for nail disorders?. *Turkderm-Turk Arch Dermatol Venereol* 2017;51:62-5.
11. Puhaindran ME, Cordeiro PG, Disa JJ, Mehrara BJ, Athanasian EA: Full-thickness skin graft after nail complex resection for malignant tumors. *Tech Hand Up Extrem Surg* 2011;15:84-6.
12. Lazar A, Abimelec P, Dumontier C: Full thickness skin graft for nail unit reconstruction. *J Hand Surg Br* 2005;30:194-8.
13. Flores-Terry M, Romero-Aguilera G, Mendoza C, et al.: Functional surgery for malignant subungual tumors: a case series and literature review. *Actas Dermosifiliogr (Engl Ed)* 2018;109:712-21.
14. Topin-Ruiz S, Surinach C, Dalle S, Duru G, Balme B, Thomas L: Surgical treatment of subungual squamous cell carcinoma by wide excision of the nail unit and skin graft reconstruction: An evaluation of treatment efficiency and outcomes. *JAMA Dermatol* 2017;153:442-4.
15. Elder, D. E., Massi, D., Scolyer, R. A., & Willemze, R: WHO Classification of Skin Tumours. WHO Classification of Tumours. World Health Organization 2018:36-27.