

Magnesium and dexmedetomidine combination reduces sodium nitroprusside requirement in laparoscopic pheochromocytoma

✉ Nükhet Sivriköz, M.D.,¹ ✉ Özlem Turhan, M.D.,¹ ✉ Hacer Ayşen Yavru, M.D.,¹ ✉ Demet Altun, M.D.,¹
✉ Yalın İşcan, M.D.,² ✉ İsmail Cem Sormaz, M.D.,² ✉ Zerrin Sungur, M.D.¹

¹Department of Anesthesiology and Reanimation, İstanbul University İstanbul Faculty of Medicine, İstanbul-Türkiye

²Department of General Surgery, İstanbul University İstanbul Faculty of Medicine, İstanbul-Türkiye

ABSTRACT

BACKGROUND: Anesthesia management of pheochromocytoma excision surgery is associated with severe hemodynamic fluctuations. The objective of this study is to compare the number of hypertensive crisis requiring sodium nitroprusside (SNP) administration between the groups treated with magnesium (Mg)-dexmedetomidine (Dex) and conventional group in pheochromocytoma.

METHODS: This retrospective cohort study included patients who underwent pheochromocytoma surgery between 2011 and 2020. Patients were examined into two groups: 1-Conventional group (GC) included patients who were operated between 2011 and 2015 under standard anesthesia care and who did not receive perioperative additional medication. 2- Mg-Dex therapy group (GMD) comprised the patients who were operated between 2015 and 2020 and who had received 300 mg Mg per oral daily 1 week before the surgery and Mg-Dex infusion intraoperatively. Blood pressure, heart rate (HR), and SNP requirement were recorded throughout surgery as well as demographics and operative data. Hypertensive crisis was defined as systolic blood pressure (SBP) > 180 mmHg, and tachycardia was defined as HR > 110 bpm.

RESULTS: A total of 78 patients' data were analyzed from 108 patients' documentary. (38 in GC, 40 in GMD) SNP requirement was significantly higher in GC (39.5%) comparing GMD (7.5%) ($p=0.001$). SBPs during tumor manipulation period were statistically higher in GC than in GMD at 10th, 15th, 20th, 25th, 30th, and 35th min. HR values were significantly higher in GC compared to GMD at 10th and 15th min of tumor manipulation period ($p<0.05$).

CONCLUSION: Combination of Mg-Dex seems to be an alternative therapy for reducing vasodilator requirement in perioperative management of pheochromocytoma.

Keywords: Dexmedetomidine; magnesium; nitroprusside; pheochromocytoma.

INTRODUCTION

Pheochromocytoma (Pheo) is a rare neuroendocrine tumor that originates from chromaffin cells of the sympathoadrenal system, leading to catecholamine secretion. Clinical presentation is mainly affected by the excessive catecholamine synthesis.^[1]

Since 1980's, surgical removal of the tumor has been accept-

ed as the only curative option of the disease; and minimal invasive approach has been largely adopted. However, perioperative period constitutes a considerable challenge for anesthesiologist with hemodynamic fluctuations within different stages of surgery. Both noxious stimuli and tumor removal are associated with hypertensive episodes; whereas hypotension may occur after excision of the mass and continue in the postoperative early periods.

Cite this article as: Sivriköz N, Turhan Ö, Yavru HA, Altun D, İşcan Y, Sormaz İC, et al. Magnesium and dexmedetomidine combination reduces sodium nitroprusside requirement in laparoscopic pheochromocytoma. *Ulus Travma Acil Cerrahi Derg* 2022;28:1563-1569.

Address for correspondence: Nükhet Sivriköz, M.D.

İstanbul Üniversitesi İstanbul Tıp Fakültesi, Anesteziyoloji ve Reanimasyon Anabilim Dalı, İstanbul, Türkiye

Tel: +90 212 - 414 20 00 / 1742 E-mail: nsivrikoz@yahoo.com

Ulus Travma Acil Cerrahi Derg 2022;28(11):1563-1569 DOI: 10.14744/tjtes.2022.92672 Submitted: 21.03.2022 Revised: 21.03.2022 Accepted: 10.05.2022
OPEN ACCESS This is an open access article under the CC BY-NC license (<http://creativecommons.org/licenses/by-nc/4.0/>).



Although the pre-operative preparation which consists of α -blockade and fluid intake is well established, intraoperative management is still a topic of debate.^[2,3] Sodium nitropruside (SNP) has conventionally been first choice of treatment for hypertensive episodes during adrenal surgery for Pheo.^[4] Besides well-known but rare side effects as cyanide toxicity, titration of SNP may be problematic in these patients with unwarranted hemodynamic fluctuations. Large variety of drugs were currently shown to be effective in this context and intraoperative management changed in the recent years.^[2] Hemodynamic stability is the cornerstone of perioperative management and should be achieved with proactive control as stated in a recent review.^[5] However, appropriate choice of treatment is yet to be determined.

Recently, use of magnesium (Mg) was found to be safe and effective for hemodynamic control during adrenal surgery for Pheo.^[6] Dexmedetomidine (Dex) is relatively a new α -2 adrenergic agonist which has sedative, analgesic, and sympatholytic properties.^[7] It has been shown to provide perioperative hemodynamic stability.^[8]

In this retrospective study, patients prepared according to Roizen criteria to surgery were chronologically divided into two groups. The first group was conventional group (GC) in which patients were underwent surgery after adequate preparation. The second was Mg and Dex therapy group (GMD), in which similarly prepared patients were preoperatively treated with Mg and perioperatively received infusions of Mg and Dex.

The primary aim was to compare the number of hypertensive crisis requiring SNP therapy between these groups. Our hypothesis was that Mg and Dex combination therapy would require less SNP intervention than conventional approach. The secondary outcomes were hemodynamic fluctuations (hypotension, tachycardia, and severe hypertensive crisis) which needed vasoactive therapy.

MATERIALS AND METHODS

This study was designed as a retrospective cohort in patients who underwent unilateral transperitoneal adrenalectomy for Pheo between January 2011 and March 2020. Ethics committee approval was obtained from the İstanbul University İstanbul Faculty of Medicine Clinical Research Ethics Committee (2021/42). After ethics committee approval, the study was registered at clinicaltrials.gov (registration number: NCT05102058). The STROBE guideline for cohort studies was adhered.

Data Source

The study's documentary was obtained retrospectively from patients' files, which were classified ASA I-III, clinically and biochemically diagnosed Pheo.

Patients who were evaluated according to Endocrine Society Practice Guideline and the Roizen criteria and whom tumor sizes <5 cm and body mass index <35 kg.m⁻², were included in the study. Roizen criteria are defined as follows; blood pressure <160/90 mmHg for 24 h before surgery, no orthostatic hypotension with blood pressure is measured <80/45 mmHg, no changes in the ST or T waves a week before surgery or no premature ventricular contractions >5 per minute).^[3,9] Exclusion criteria were determined as open surgery, bilateral Pheo, larger than 5 cm tumors, and incomplete data.

Study Protocol

In the study, data of patients who underwent Pheo excision between 2011 and 2020 were screened. The data were examined in two groups: The conventional group (GC) and the Mg and Dex therapy group (GMD). Patients are administered Mg and Dex therapy during perioperative period in our institute since 2015. The conventional group consists of patients who had surgery between 2011 January and 2015 January, did not have Mg and Dex therapy during perioperative period. The Mg and Dex therapy group consists of patients who received Mg and Dex during perioperative period between 2015 February to 2020 March. In GMD, patients were medicated with 300 mg of oral Mg daily 1 week before surgery. In the pre-anesthetic room, patients were monitored and Mg infusion (50 mg.kg⁻¹.h⁻¹) was initiated 1 h before surgery. In the operating room, invasive blood pressure was monitored and loading dose of Dex (1 μ g.kg⁻¹) was administered in 10 min before anesthesia induction.

In both groups, endotracheal intubation was performed after induction with midazolam (0.03 mg.kg⁻¹), fentanyl (2–4 μ g.kg⁻¹), propofol (1–3 mg.kg⁻¹), and rocuronium (0.6 mg.kg⁻¹). Anesthesia maintenance was achieved with sevoflurane in a mixture of 40% O₂ and 60% air. After induction, a central venous catheter was inserted. Infusion of crystalloid (5–7 mL.kg⁻¹.h⁻¹) continued in all patients, in addition 15 mg.kg⁻¹.h⁻¹ of Mg and 0.5 μ g.kg⁻¹.h⁻¹ of Dex infusions were administered to GMD.

Demographic and operative data (duration of anesthesia, surgery, and tumor manipulation) were all noted. Anesthesia period was detailed as 3-time intervals considering hemodynamic properties. Time intervals were as: From anesthesia induction to tumor manipulation (T1), from surgical manipulation to ligation of tumor blood supply (T2-tumor manipulation), and finally from tumor removal to the end of surgery (T3). Systolic blood pressure (SBP) and heart rate (HR) with an interval of five minutes were extracted from medical records.

In both groups, hypertensive crisis which required SNP was defined as SBP greater than 180 mmHg.^[10] Severe hypertensive crisis was defined as SBP >200 mmHg in any time of surgery. Hypertensive crisis was treated with SNP infusion of 0.5 μ g.kg⁻¹.min⁻¹ at beginning and titrated according to blood pressures. SNP requirement during surgery was document-

ed. Tachycardia was described as HR higher than 110 bpm and treated with esmolol infusion (initial dose: 50 $\mu\text{g.kg.min}^{-1}$). Hypotension was defined as SBP lower than 80 mmHg. If hypotension occurred Mg and Dex infusions stopped in GMD and 500 mL of crystalloids bolus was administered in both groups. Persistent hypotension despite fluid therapy was treated with noradrenalin (0.01–0.1 $\mu\text{g.kg}^{-1}.\text{min}^{-1}$) infusion. At the end of the operation, all patients were transferred to the intensive care unit for postoperative monitoring.

Surgical Technique

All patients underwent laparoscopic transperitoneal unilateral adrenalectomy. After anesthesia induction and patient positioning (lateral decubitus), pneumoperitoneum was created with open technique to avoid injuries. Intra-abdominal pressure was preserved below 12 mmHg. Standard four 10 mm ports were used in right sided Pheo excision and three 10 mm ports in left sided Pheo excision. Dissection was carried out to clip the adrenal vein first. After clipping the adrenal vein, the adrenal gland was excised with periadrenal fatty tissue. After the adrenal gland was completely mobilized, the specimen was removed with an endobag. During dissection, surgical team was in close communication with anesthesia staff for hemodynamic disturbance.

Statistical Analysis

Before investigation, we assumed that the ratio of SNP requirement in GMD would be 10%, which we also saw in a pilot study of 10 patients not included in the analysis as there was no literature regarding the incidence of SNP requirement in such a regime. We also assumed that the incidence of SNP requirement would be higher at least by 30% in conventional therapy so that with an alpha error of 0.05 and a beta error of 0.2 we would need to investigate at least 30 patients per group. As these cases are scarce and we would expect a case frequency of at least 10 cases per year, we decided to include

2011–2015 for conventional and 2015–2020 for Mg and Dex therapy group considering possible loss.

Distribution of data was assessed by Kolmogorov–Simonov test. Quantitative data were expressed as mean \pm standard deviation, or median (minimum-maximum). Normally distributed quantitative data compared by Student t-test, and non-normally distributed data by Mann–Whitney U test. Categorical data were presented as number (percentage) and analyzed with Chi-Square test. All statistical analysis was performed using IBM SPSS for Windows, version 15.0 (IBM Corp., Armonk, NY) and p-value of <0.05 was considered as being statistically significant.

RESULTS

One hundred and eight patients were enrolled in the study. After exclusion of 30 patients' data from the study, a total of 78 patients' data in GC (n=38) and in GMD (n=40) were evaluated for statistical analysis (Fig. 1). Demographic and operative data were similar between groups (Table 1). All patients were under α -blockade preoperatively and β -blocker use was similar between groups. Mean duration of T1, T2, and T3 periods was similar for GC and GMD (19.47 \pm 3.2 min vs. 22.62 \pm 4.32 min; 46.18 \pm 6.41 min vs. 44.62 \pm 9.36 min; and 17.23 \pm 4.39 min vs. 18.75 \pm 5.44 min, respectively, p>0.05). Time from tumor manipulation to adrenal vein clamping was similar between GC (30.75 \pm 7.3 min) and GMD (26.45 \pm 8.9 min) (p=0.267).

SBP and HR were similar during T1 period between groups (Table 2). SBP during T2 period were lower in GMD than in GC at 10th, 15th, 20th, 25th, 30th, and 35th min (Table 3). Severe hypertension was significantly higher in GC compared to GMD (nine (23%) versus two (5%) patients, respectively; p=0.02). The primary outcome of the study, that is, SNP requirement in T2 period, was significantly higher in GC (39.5%) compared to GMD (7.5%) (p=0.001). During T2,

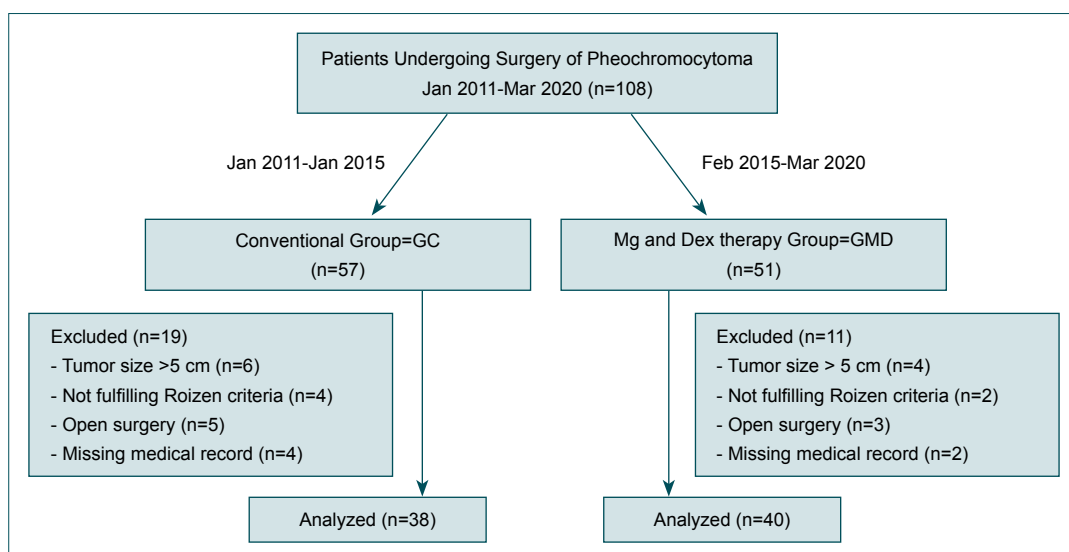


Figure 1. Study flow chart.

Table 1. Demographic and operative data

	GC (n=38)	GMD (n=40)	p-value
Gender (female/male)	20/18	23/17	0.66
ASA I/II/III (n)	10/22/6	10/26/4	0.44
Patients using β blockers (n)	25	22	0.33
Age (year)	44.29 \pm 12.46	42.48 \pm 10.64	0.49
BMI (kg.m ⁻²)	26.50 \pm 1.99	25.89 \pm 1.75	0.15
Duration of anesthesia (min)	94.34 \pm 9.53	96.13 \pm 11.18	0.45
Duration of surgery (min)	67.89 \pm 8.59	66.37 \pm 10.49	0.48
Duration of tumor manipulation (min)	46.18 \pm 6.41	44.62 \pm 9.36	0.39
Tumor size (diameter, cm)	4.53 \pm 3.03	4.32 \pm 2.96	0.76

ASA: American Society of Anesthesiologists; BMI: Body mass index; GC: Conventional group; GMD: Magnesium and dexmedetomidine therapy group. Data are expressed as mean \pm standard deviation or number.

Table 2. Hemodynamic data in T1 period

T1 period		GC (n=38)	GMD (n=40)	p-value
0 th min	SBP	132 (110–151)	130 (105–154)	0.09
	HR	75 (65–87)	73 (62–94)	0.54
5 th min	SBP	123 (105–155)	125 (95–168)	0.78
	HR	73 (58–82)	72 (55–92)	0.69
10 th min	SBP	122 (95–155)	118 (97–143)	0.70
	HR	72 (59–81)	72 (55–90)	0.62
15 th min	SBP	118 (88–152)	117 (85–144)	0.78
	HR	71 (60–84)	70 (58–93)	0.42
20 th min	SBP	117 (90–144)	115 (88–140)	0.48
	HR	71 (58–85)	68 (55–87)	0.39
25 th min	SBP	110 (90–142)	119 (90–145)	0.59
	HR	70 (60–90)	71 (56–92)	0.62

GC: Conventional group; GMD: Magnesium and dexmedetomidine therapy group; HR: Heart rate; SBP: Systolic blood pressure; T1: Anesthesia induction to tumor manipulation. Data are expressed as median (minimum–maximum).

SNP infusion initiated to 15 (39.5%) patients of GC (five patients at 10th min, four at 15th min, three at 20th min, two at 25th min and one patient at 30th min). SNP infusion was required in three (7.5%) patients of GMD (one patient at 5th min, one at 10th min, and one at 15th min). HRs were higher in GC than in GMD at 10th and 15th min during T2 period (Table 3). Eight (21%) patients in GC and two (5%) in GMD received esmolol infusion due to tachycardia during tumor manipulation period without statistical difference ($p=0.074$). In T3 period, SBP and HR were similar in both groups at all-time points (Table 4).

Hypotension episodes were statistically lower in GMD than GC (one [2.5%] versus eight [21%] patients, respectively; $p=0.01$). Except one in GC who needed noradrenaline in-

Table 3. Hemodynamic data in T2 period

T2 period		GC (n=38)	GMD (n=40)	p-value
0 th min	SBP	140 (110–165)	132 (93–163)	0.16
	HR	77 (61–102)	73 (62–96)	0.3
5 th min	SBP	145 (118–166)	141 (91–197)	0.08
	HR	80 (63–96)	75 (61–110)	0.25
10 th min	SBP	144 (74–248)	138 (94–221)	0.01
	HR	80 (61–126)	76 (59–108)	0.04
15 th min	SBP	143 (72–266)	129 (83–215)	0.04
	HR	82 (63–146)	73 (57–119)	0.001
20 th min	SBP	139 (109–247)	133 (85–164)	0.02
	HR	76 (61–128)	74 (59–95)	0.14
25 th min	SBP	142 (98–258)	127 (74–170)	0.01
	HR	77 (64–135)	72 (60–98)	0.11
30 th min	SBP	140 (75–195)	130 (88–162)	0.01
	HR	73 (62–96)	71 (58–87)	0.28
35 th min	SBP	140 (107–178)	131 (89–155)	0.001
	HR	73 (60–87)	70 (57–86)	0.12
40 th min	SBP	138 (105–156)	122 (91–158)	0.09
	HR	71 (58–83)	68 (55–88)	0.09
45 th min	SBP	136 (106–155)	128 (93–157)	0.06
	HR	70 (62–78)	67 (56–81)	0.13

GC: Conventional group; GMD: Magnesium and dexmedetomidine therapy group; HR: Heart rate; SBP: Systolic blood pressure; T2: Tumor manipulation. Data are expressed as median (minimum–maximum).

fusion (for 3 h), all hypotensive episodes resolved with fluid bolus during T2 period. Regardless of groups, eight (44.4%) of the 18 patients who required SNP had hypotension episodes during surgery, whereas only one (1.6%) patient had hypotension episode in 60 patients who did not required SNP ($p<0.001$).

Table 4. Hemodynamic data in T3 period

T3 period		GC (n=38)	GMD (n=40)	p-value
0 th min	SBP	119 (90–149)	115 (89–138)	0.40
	HR	68 (56–83)	67 (55–86)	0.72
5 th min	SBP	115 (84–143)	111 (84–134)	0.14
	HR	66 (55–80)	68 (50–95)	0.83
10 th min	SBP	108 (77–150)	105 (82–132)	0.48
	HR	65 (51–78)	66 (55–93)	0.84
15 th min	SBP	116 (86–143)	109 (87–133)	0.67
	HR	67 (54–73)	66 (58–84)	0.76
20 th min	SBP	114 (90–135)	110 (95–131)	0.95
	HR	67 (56–76)	64 (56–81)	0.57

GC: Conventional group; GMD: Magnesium and dexmedetomidine therapy group; HR: Heart rate; SBP: Systolic blood pressure; T3: Total removal to the end of surgery. Data are expressed as median (minimum–maximum).

DISCUSSION

Perioperative management of Pheo represents a considerable challenge to anesthesiologist with severe hemodynamic fluctuations. Combination of Mg and Dex resulted in preservation of blood pressure control for tumor removal phase - the most vulnerable stage of surgery. Need of SNP for this period was significantly lower in GMD compared to GC. Interestingly, hypotensive episodes were significantly lower in combination therapy group. To our knowledge this is the first study investigating effects of Mg and Dex combination on hemodynamics in anesthesia management of adrenalectomy for Pheo.

Pheochromocytoma is associated with increased catecholamine secretion which mainly determines clinical presentation. The hallmark of preoperative therapy to control catecholamine excess is α -blockade initially and then β -blockade if necessary. Intraoperative period may also be associated with hypertensive attacks either by stimuli activating sympathetic system or by direct manipulation of the tumor.^[11]

Sympathetic stimuli can be caused by intubation, surgical pain, or pneumoperitoneum; and generally, responds to increased anesthesia level. Manipulation of tumor leading to catecholamine release has been defined as the main cause for hypertension and often requires vasoactive therapy.^[12]

SNP is an effective agent for the treatment of hypertensive response in Pheo with both venous and arterial vasodilatations.^[13,14] In a large historical cohort series of 143 patients, about one half experienced hypertensive attack and SNP seemed to be effective.^[15] Short onset and effective vasodilatation makes SNP an attractive agent in perioperative management of Pheo. However, titration of the drug may be problematic with large swings in blood pressure.^[10] Guidelines clearly defined preoperative preparation for Pheo, whereas well-es-

tablished protocols for intraoperative hypertension is lacking. Clinical practice allowed a large variety of vasodilator agents.

Mg is a considerable option in perioperative management of Pheo as it reduces the catecholamine release from adrenal medulla and peripheral nerve endings in addition to its vasodilator and antiarrhythmic properties.^[16] In a retrospective study, Livingstone et al.^[17] reported that “the lack of intraoperative Mg use” was associated with hemodynamic instability during Pheo resection. Although this paper emphasizes hemodynamic benefits of Mg, its use was merely limited to intraoperative period which constitutes major difference from our work. Effectiveness on hemodynamic control of Mg has been mostly described in case reports with special population like pediatric or pregnant patients.^[18–20] It ensured hemodynamic stability which could not be established with SNP or phentolamine in a postpartum patient.^[21] Our study is unique with preoperative administration of Mg in Pheo 1 week before surgery. Combination with Dex appeared to be advantageous especially in the phase of tumor manipulation. This period represents the exaggerated part of surgery because any manipulation might cause new catecholamine release with abrupt hypertensive response. Hemodynamic control very commonly requires vasoactive agent such as SNP. In our study, incidence of hypertension requiring SNP therapy was limited to this period and it was significantly lower in Mg and Dex combination group. Moreover, severe hypertensive episode was significantly less in Mg and Dex group.

Dex - the second agent of combination group - is a relatively new selective α -2 agonist with central and peripheral sympatholytic action which is responsible for cardiovascular effects. It has also been shown to reduce noradrenaline uptake which makes Dex a suitable drug in Pheo patients.^[22] However, clinical use of Dex in patients with Pheo was restricted to case reports with controversial results.^[23–25] Two case reports related inadequacy of Dex infusion during tumor removal and need of additional intervention.^[24,25] Meanwhile, an older paper reported excellent blood pressure control under Dex infusion for both awake intubation and tumor manipulation for the perioperative management of Pheo.^[23] Similar drug combination with our study has been described in two case reports with adequate hemodynamic control. The main difference was that Mg and Dex infusion was restricted to perioperative period in this case report.^[18,26] In our study, Mg was initiated 1 week before surgery and followed by Mg and Dex combination perioperatively. We think that Dex ensued a more stable blood pressure trend during adrenalectomy.

What is more prominent about our combination was its association with lesser hypotensive episode compared to control group. Hypotension after tumor extirpation was mainly due to increased venous capacitance.^[2] In this study, we think that lower incidence of hypotension can be explained by decreased SNP need in Mg and Dex therapy. In a speculative way, Pheo patients might be considered more sensitive to SNP due to

the long-standing catecholamine exposure. Our study exhibited that combination group was associated with more stable hemodynamic control with lower SNP requirement and less severe hypertensive episode as well as reduced hypotension. One of scarce study investigating hypotensive episodes in perioperative management of Pheo revealed that tumor size, preoperative α -blockade, initial high mean arterial pressure, and anesthesia technique were associated risk factors with hemodynamic instability.^[27,28] In our study, both tumor size and preoperative therapy were comparable between groups. We can suggest that incidence of hypotension might be closely related to perioperative hemodynamic management.

One may criticize our primary outcome of SNP requirement as it is not encountered in the previous Pheo literature. However, our choice of primary outcome was mainly based on our previous observations that the use of SNP was associated with more hemodynamic disturbances following surgical removal as supported by our results of hypotensive patient incidence in patients requiring SNP. Yet, interestingly, before starting this study we could not note any study looking at this outcome. As we could only assume the incidence of SNP before study for sample size analysis, we also performed a post hoc analysis of power which we found to be 95%.

This study has some limitations. First, this retrospective study spanning in 10 years compared two hemodynamic approaches in Pheo based on medical records. Second issue could be surgical approach; however, laparoscopic tumor removal has been an established therapy in our institution with this team. Third, our study group consisted of low-risk patients (low ASA, relatively small tumor size). Combination of Mg and Dex would be interesting in a group with comorbidities, larger tumor size, or high-risk patients. Further studies would be required for these issues.

Conclusion

Pheochromocytoma is associated with wide swings of blood pressures in perioperative course and anesthetic management is mainly focused on this issue. Combination of Mg and Dex achieves lower need for vasodilator during tumor removal time which is the most dynamic period of surgery and lower hypotensive episodes after mass extirpation. This study differs from others as it investigates hemodynamic disturbance in different phases of surgery. In conclusion, we think that Mg and Dex combination therapy is a reliable alternative for perioperative management of Pheo patients.

Ethics Committee Approval: This study was approved by the İstanbul University İstanbul Faculty of Medicine Clinical Research Ethics Committee (Date: 08.01.2021, Decision No: NCT05102058).

Peer-review: Internally peer-reviewed.

Authorship Contributions: Concept: N.S., A.Y.; Design: N.S., A.Y., Ö.T.; Supervision: N.S., Ö.T., H.A.Y., D.A., Y.İ.,

İ.C.S., Z.S.; Data: D.A., Y.İ., İ.C.S.; Analysis: N.S., Ö.T.; Literature search: Z.S., D.A., Y.İ., C.S.; Writing: Z.S., N.S.; Critical revision: N.S., Ö.T., H.A.Y., D.A., Y.İ., İ.C.S., Z.S.

Conflict of Interest: None declared.

Financial Disclosure: The authors declared that this study has received no financial support.

REFERENCES

1. Thompson JP, Bennett D, Hodson J, Asia M, Ayuk J, O'Reilly MW, et al. Incidence, risk factors and clinical significance of postoperative hemodynamic instability after adrenalectomy for pheochromocytoma. *Gland Surg* 2019;8:729–39. [CrossRef]
2. Naranjo J, Dodd S, Martin YN. Perioperative management of pheochromocytoma. *J Cardiothorac Vasc Anesth* 2017;31:1427–39. [CrossRef]
3. Lenders JW, Duh QY, Eisenhofer G, Gimenez-Roqueplo AP, Grebe SK, Murad MH, et al. Pheochromocytoma and paraganglioma: An endocrine society clinical practice guideline. *J Clin Endocrinol Metab* 2014;99:1915–42. [CrossRef]
4. Ramachandran R, Rewari V, Sharma A, Kumar R, Trikha A. Laparoscopic surgery for pheochromocytoma and paraganglioma removal: A retrospective analysis of anaesthetic management. *Curr Hypertens Rev* 2016;12:222–7. [CrossRef]
5. Fernandez-Robles C, Carr ZJ, Oprea AD. Endocrine emergencies in anesthesia. *Curr Opin Anaesthesiol* 2021;34:326–34. [CrossRef]
6. Lord MS, Augoustides JG. Perioperative management of pheochromocytoma: Focus on magnesium, dehidipine, and vasopressin. *J Cardiothorac Vasc Anesth* 2012;26:526–31. [CrossRef]
7. Weerink MA, Struys MM, Hannivoort LN, Barends CR, Absalom AR, Colin P. Clinical pharmacokinetics and pharmacodynamics of dexmedetomidine. *Clin Pharmacokinet* 2017;56:893–913. [CrossRef]
8. Colin PJ, Hannivoort LN, Eleveld DJ, Reynjens KM, Absalom AR, Verecke HE, et al. Dexmedetomidine pharmacodynamics in healthy volunteers: 2. Haemodynamic profile. *Br J Anaesth* 2017;119:211–20. [CrossRef]
9. Roizen MF, Horrigan RW, Koike M, Eger EI, Mulroy ME, Frazer B, et al. A prospective randomized trial of four anesthetic techniques for resection of pheochromocytoma. *Anesthesiology* 1982;57:A43. [CrossRef]
10. Hottinger DG, Beebe DS, Kozhimannil T, Prielipp RC, Belani KG. Sodium nitroprusside in 2014: A clinical concepts review. *J Anaesthesiol Clin Pharmacol* 2014;30:462–71. [CrossRef]
11. Pisarska M, Pędziwiatr M, Budzyński A. Perioperative hemodynamic instability in patients undergoing laparoscopic adrenalectomy for pheochromocytoma. *Gland Surg* 2016;5:506–11. [CrossRef]
12. Lentschener C, Gaujoux S, Thillois JM, Duboc D, Bertherat J, Ozier Y, et al. Increased arterial pressure is not predictive of haemodynamic instability in patients undergoing adrenalectomy for pheochromocytoma. *Acta Anaesthesiol Scand* 2009;53:522–7. [CrossRef]
13. Friederich JA, Butterworth JF 4th. Sodium nitroprusside: Twenty years and counting. *Anesth Analg* 1995;81:152–62. [CrossRef]
14. Santhi R, Worthley LI. Hypertension in the critically ill patient. *Crit Care Resusc* 2003;5:24–42.
15. Kinney MA, Warner ME, Vanheerden JA, Horlocker TT, Young WF Jr., Schroeder DR, et al. Perioperative risks and outcomes of pheochromocytoma and paraganglioma resection. *Anesth Analg* 2000;91:1118–23.
16. Herroeder S, Schönherr ME, De Hert SG, Hollmann MW. Magnesium-essentials for anesthesiologists. *Anesthesiology* 2011;114:971–93.
17. Livingstone M, Duttchen K, Thompson J, Sunderani Z, Hawboldt G, Rose MS, et al. Hemodynamic stability during pheochromocytoma

- resection: Lessons learned over the last two decades. *Ann Surg Oncol* 2015;22:4175–80. [CrossRef]
18. Bryskin R, Weldon BC. Dexmedetomidine and magnesium sulfate in the perioperative management of a child undergoing laparoscopic resection of bilateral pheochromocytomas. *J Clin Anesth* 2010;22:126–9. [CrossRef]
 19. Minami T, Adachi T, Fukuda K. An effective use of magnesium sulfate for intraoperative management of laparoscopic adrenalectomy for pheochromocytoma in a pediatric patient. *Anesth Analg* 2002;95:1243–4.
 20. Bierlaire D, Péa D, Monnier F, Delbreil JP, Bessout L. Pheochromocytoma and pregnancy: Anaesthetic management about two cases. [Article in French]. *Ann Fr Anesth Reanim* 2009;28:988–93. [CrossRef]
 21. James MF, Cronjé L. Pheochromocytoma crisis: The use of magnesium sulfate. *Anesth Analg* 2004;99:680–6. [CrossRef]
 22. Singh S, Singh A. Dexmedetomidine induced catecholamine suppression in pheochromocytoma. *J Nat Sci Biol Med* 2014;5:182–3. [CrossRef]
 23. Polavarapu HV, Kurian AA, Josloff R. Is dexmedetomidine the agent of choice in the resection of pheochromocytoma? *Am Surg* 2012;78:E127–8. [CrossRef]
 24. Erdogan MA, Ozkan AS, Ozgul U, Colak Y, Ucar M. Dexmedetomidine, remifentanyl, and sevoflurane in the perioperative management of a patient during a laparoscopic pheochromocytoma resection. *J Cardiothorac Vasc Anesth* 2015;29:e79–80. [CrossRef]
 25. Khetarpal M, Yadav M, Kulkarni D, Gopinath R. Role of dexmedetomidine and sevoflurane in the intraoperative management of patient undergoing resection of pheochromocytoma. *Indian J Anaesth* 2014;58:496–7. [CrossRef]
 26. Shrestha G, Rupakhetee S, Pathak S, Acharya P, Parajuli BD, Shrestha A. Dexmedetomidine and magnesium sulphate as the anaesthetic adjuncts for intraoperative management for resection of pheochromocytoma. *J Soc Anesthesiol Nepal* 2016;3:87–9. [CrossRef]
 27. Jeon S, Cho AR, Ri HS, Lee HJ, Hong JM, Lee D, et al. The effect of combined epidural-general anesthesia on hemodynamic instability during pheochromocytoma and paraganglioma surgery: A multicenter retrospective cohort study. *Int J Med Sci* 2020;17:1956–63. [CrossRef]
 28. Connor D, Boumphrey S. Perioperative care of pheochromocytoma. *BJA Educ* 2016;5:153–8. [CrossRef]

ORİJİNAL ÇALIŞMA - ÖZ

Laparoskopik feokromositomada magnezyum ve deksmedetomidin kombinasyonu sodyum nitroprussid gereksinimini azaltır

Dr. Nühket Sivriköz,¹ Dr. Özlem Turhan,¹ Dr. Hacer Aysen Yavru,¹ Dr. Demet Altun,¹ Dr. Yalın İşcan,² Dr. İsmail Cem Sormaz,² Dr. Zerrin Sungur¹

¹İstanbul Üniversitesi İstanbul Tıp Fakültesi, Anesteziyoloji ve Reanimasyon Anabilim Dalı, İstanbul

²İstanbul Üniversitesi İstanbul Tıp Fakültesi, Genel Cerrahi Anabilim Dalı, İstanbul

AMAÇ: Feokromositoma eksizyon cerrahisinin anestezi yönetimi ciddi hemodinamik dalgalanmalarla ilişkilidir. Bu çalışmanın amacı, feokromositomada magnezyum-deksmedetomidin ile tedavi edilen grup ile geleneksel grup arasında sodyum nitroprussid uygulaması gerektiren hipertansif kriz sayısını karşılaştırmaktır.

GEREÇ VE YÖNTEM: Bu geriye dönük kohort çalışması, 2011–2020 yılları arasında feokromositoma ameliyatı geçiren hastaları içermektedir. Hastalar iki gruba ayrıldı: 1- Geleneksel grup (GC); 2011–2015 yılları arasında standart anesteziyoloji hazırlığı ile ameliyat edilen ve perioperatif ek ilaç almayan hastaları içeriyordu. 2-Magnezyum-deksmedetomidin tedavi grubu (GMD); 2015–2020 yılları arasında ameliyat edilen ameliyattan bir hafta önce günde oral 300 mg Magnezyum ve intraoperatif olarak magnezyum-deksmedetomidin infüzyonu alan hastalardan oluşuyordu. Ameliyat boyunca kan basıncı, kalp atım hızı ve sodyum nitroprussid gereksinimi, demografik ve operatif veriler kaydedildi. Hipertansif kriz sistolik kan basıncı >180 mmHg, taşikardi ise kalp atım hızı >110 atım olarak tanımlandı.

BULGULAR: Toplam 108 hastanın dökümanlarından 78 hastanın verileri analiz edildi (GC'de 38, GMD'de 40 hasta). Sodyum nitroprussid gereksinimi GC'de (%39.5) GMD'ye (%7.5) göre anlamlı derecede yüksekti (p=0.001). Tümör manipülasyonu dönemindeki sistolik kan basınçları, GC'de 10., 15., 20., 25., 30. ve 35. dakikalarda GMD'ye göre istatistiksel olarak daha yüksekti. Tümör manipülasyon periyodunun 10. ve 15. dakikalarında kalp atım hızı değerleri GC'de GMD'ye göre anlamlı derecede yüksekti (p<0.05).

TARTIŞMA: Magnezyum-deksmedetomidin kombinasyonu, feokromositomanın perioperatif yönetiminde vazodilatatör gereksinimini azaltmak için alternatif bir tedavi gibi görünmektedir.

Anahtar sözcükler: Deksmetomidin; feokromositoma; magnezyum; nitroprussid.

Ulus Travma Acil Cerrahi Derg 2022;28(11):1563-1569 doi: 10.14744/tjtes.2022.92672