

Importance of diagnostic laparoscopy in the assessment of the diaphragm after left thoracoabdominal stab wound: A prospective cohort study

Metin Yücel, M.D.,¹ Adnan Özpek, M.D.,¹ Hüseyin Kerem Tolan, M.D.,¹ Fatih Başak, M.D.,¹ Gürhan Baş, M.D.,² Ethem Ünal, M.D.,¹ Orhan Alimoğlu, M.D.²

¹Department of General Surgery, Ümraniye Training and Research Hospital, İstanbul-Turkey

²Department of General Surgery, Medeniyet University Faculty of Medicine, İstanbul-Turkey

ABSTRACT

BACKGROUND: Stab wounds in the left thoracoabdominal region may cause diaphragmatic injury. The aim of the present study was to determine incidence of diaphragmatic injury and role of diagnostic laparoscopy in detection of injury in patients with left thoracoabdominal stab wound.

METHODS: Total of 81 patients (75 male, 6 female; mean age 27.5±9.8 years; range 14 to 60 years) who presented with left thoracoabdominal stab wound between April 2009 and September 2014 were evaluated. Laparotomy was performed on patients who had hemodynamic instability, signs of peritonitis, or organ evisceration. Remaining patients were followed conservatively. After 48 hours, diagnostic laparoscopy was performed on patients without laparotomy indication to examine the left diaphragm for injury. Follow-up and treatment findings were prospectively evaluated.

RESULTS: Thirteen patients underwent laparotomy while diagnostic laparoscopy was performed on remaining 68 patients. Left diaphragmatic injury was observed in 19 patients (23.5%) in the study group. Four injuries were diagnosed by laparotomy and 15 were diagnosed by laparoscopy. Presence of hemopneumothorax did not yield difference in incidence of diaphragmatic injury ($p=0.131$). No significant difference was detected in terms of diaphragmatic injury with respect to entry site of stab wound in the thoracoabdominal region ($p=0.929$).

CONCLUSION: It is important to evaluate the diaphragm in left thoracoabdominal stab injuries, and diagnostic laparoscopy is still the safest and most feasible method.

Keywords: Diagnostic laparoscopy; diaphragm injury; left thoracoabdominal stab injury.

INTRODUCTION

Thoracoabdominal injuries may result in diaphragmatic injury, in addition to intraabdominal and intrathoracic injuries. Diaphragm injury is observed in 10% to 50% of left thoracoabdominal stab injuries. Early diagnosis of diaphragm injury is difficult based on physical examination and imaging modalities, unless obvious signs and symptoms are present.^[1-8] Delay in

diagnosis and treatment may lead to diaphragmatic hernia, due to pressure difference between the 2 cavities, a condition that may cause morbidity or even death.^[2,9,10] In patients who undergo laparotomy due to hemodynamic instability or peritonitis, it may be easy to evaluate the diaphragm. However, such an evaluation may be challenging in asymptomatic patients who are followed conservatively. Patients must be examined to rule out diaphragm injury. Laparoscopy is efficient technique to diagnose and treat diaphragm injury at early stage.

The aim of this study was to evaluate role of laparoscopy in detecting diaphragmatic injury in patients with left thoracoabdominal stab wounds and assess incidence of diaphragmatic injuries.

MATERIALS AND METHODS

This study was performed in general surgery clinic with the permission of the Ümraniye Training and Research Hospital

Address for correspondence: Metin Yücel, M.D.

Ümraniye Eğitim ve Araştırma Hastanesi, Genel Cerrahi Kliniği,
Ümraniye, İstanbul, Turkey

Tel: +90 216 - 632 18 18 E-mail: drmetin69@myynet.com

Quick Response Code



Ulus Travma Acil Cerrahi Derg
2017;23(2):107-111
doi: 10.5505/tjtes.2016.91043

Copyright 2017
TJTES

ethics committee (21.04.2009–4749/261). Patients who were admitted to emergency department with left thoracoabdominal stab wound between April 2009 and September 2014 were evaluated prospectively.

Thoracoabdominal region was defined as the area between the sternum, the fourth intercostal space, and the arcus costa anteriorly, and as the area between the vertebra, the inferior margin of the scapula and the last costal margin posteriorly. Region was divided into 3 subgroups: anterior (between the sternum and the anterior axillary line), lateral (between the anterior and posterior axillary lines) and posterior (between the posterior axillary line and the sternum).

After initial evaluation and efficient resuscitation, patients who were hemodynamically unstable or showing signs of peritonitis were taken for emergency laparotomy. Remaining patients were followed conservatively according to an algorithm (Fig. 1). Hemodynamic instability was determined with hypovolemia finding, such as systolic blood pressure below 90 mmHg; tachycardia; dry, pale or cold skin; or signs of fatigue and dehydration after sufficient fluid resuscitation. Diagnosis of peritonitis was made based on physical examination findings, such as rigidity and/or rebound in the abdomen and severe pain in other regions of the abdomen far from the stab wound.

Conservative treatment constituted hospitalization of the patient and close follow-up for 48 hours. In addition to performing physical examination, hemogram, as well as chest and abdominal X-rays were obtained. Patients who did not require emergency surgery 48 hours after being admitted were offered option of undergoing diagnostic laparoscopy to evaluate the left diaphragm, even though they did not have symptoms. For those who provided consent, laparoscopy was performed under general anesthesia with single port inserted

using open approach above the umbilicus. Additional ports were added if needed.

When hemopneumothorax was detected on chest X-ray, diagnostic laparoscopy was followed by tube thoracostomy. Tubes were removed after expansion of the lungs and termination of drainage. This study was fully compliant with the Strengthening the Reporting of Observational Studies in Epidemiology criteria.^[11]

Statistical Analyses

Patient data were collected prospectively and recorded in digital database. SPSS Statistics 22 program (IBM Corp., Armonk, NY, USA) was used to analyze the data. Normally distributed continuous variables were expressed as mean±SD. Categorical variables were expressed as frequencies and percentages. Fisher's exact test, chi-square test, and Fisher-Freeman-Halton exact test were used to compare continuous parametric variables. P value <.05 was considered to be statistically significant.

RESULTS

Total of 104 patients were hospitalized with left thoracoabdominal stab wound during study period. Twenty-three patients who declined diagnostic laparoscopy were excluded. In all, 81 patients were included in the study; 75 patients (92.6%) were male and 6 patients (7.4%) were female with mean age in cohort of 27.5±9.8 years (range: 14–60 years).

Thirteen patients underwent therapeutic laparotomy due to hemodynamic instability or findings of peritonitis. Left diaphragm injury was found in 4 (30.8%) laparotomy patients. In addition to diaphragmatic injury, there was splenic injury in 1 patient and multiple small bowel injuries in another. There was no associated pathology in the remaining 2 patients.

Diagnostic laparoscopy was performed on the remaining 68 patients. Left diaphragm injury was observed in 15 (22.1%) of these patients; no additional pathology was detected (Table 1). Procedure of 2 patients with diaphragm injury was converted to laparotomy due to technical difficulties. Remaining patients with diaphragm injuries were treated laparoscopically (Fig. 2).

Four diaphragmatic injuries were in the central region and

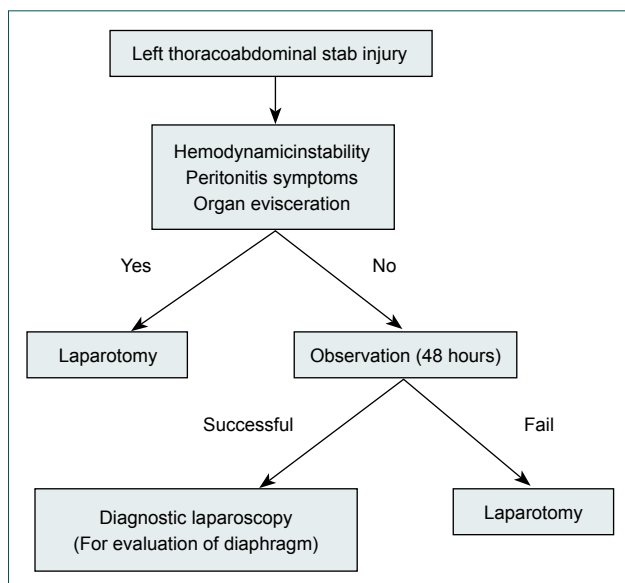


Figure 1. Algorithm used for left thoracoabdominal stab injury.

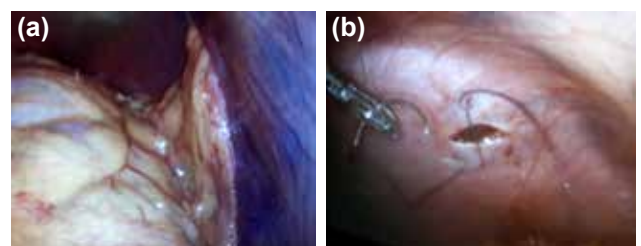


Figure 2. Omental tissue in diaphragmatic defect (a), and polipropylene suture repair (b).

remaining 15 injuries were in the periphery. Average size of defect was 2 cm (range: 1–3 cm) and separate 2/0 polypropylene sutures were used to repair diaphragmatic defect. Relationship between entry site of the stab in the left thoracoabdominal region and presence of diaphragmatic injury was examined. Left diaphragmatic injury was detected in 10 of 45 patients (22.2%) who had anterior area injuries, in 7 of 27 patients (25.9%) who had lateral area injuries, and in 2 of 9 patients (22.2%) who had posterior area injuries. No significant difference was found related to location of stab entry ($p=0.929$; Table 2).

Seven of the 19 patients (36.8%) who had hemopneumothorax, and 12 of the 62 patients (19.4%) who did not have hemopneumothorax had left diaphragm injuries. There was

no statistically significant difference between patients with or without hemopneumothorax in terms of diaphragmatic injury ($p=0.131$; Table 3).

Four of the patients who underwent emergent laparotomy due to hemodynamic instability died; however, patient deaths were not related to diaphragm injury. Mortality rate was 4.9%. Average 42-month (range: 6–79 months) follow-up revealed no morbidity, recurrence or complications.

DISCUSSION

In the past, laparotomy was performed routinely in cases with penetrating abdominal stab injuries to minimize risk of missing potential intraabdominal pathologies. With the guidance of clinical research, it has been demonstrated that unnecessary laparotomy rate was high, as well as morbidity and mortality. Therefore, routine laparotomy has largely been abandoned and more selective conservative treatments have been adopted.^[12–16]

Selective conservative approach consists of immediate surgery for patients with hemodynamic instability or peritonitis, while remaining patients are followed conservatively and discharged from the hospital 48 hours after admission if no need for surgical intervention is observed. The situation is different for thoracoabdominal region stab wounds. In early stage, diaphragm injury may not demonstrate any clinical signs or symptoms. Presence of the liver on right side under the diaphragm may reduce risk of developing herniation in right diaphragm injuries but risk of herniation is high in left diaphragm injuries.

Diaphragm injuries caused by left thoracoabdominal stab wound can be small and asymptomatic in early hours after the injury. Wound in the diaphragm may enlarge over time and lead to herniation of intraabdominal organs into the thoracic cavity, causing mortality in up to 48% of cases.^[2,8–10,17,18] Early diagnosis and treatment is essential.

Use of laparoscopy in trauma patients was first described by Adamthwaite.^[19] Application of procedure has become widespread over time, and high sensitivity and specificity have contributed to it becoming preferred method to diagnose and treat diaphragmatic injuries.^[8,19,20] Majority of routine laparotomies performed to evaluate the diaphragm in left thoracoabdominal stab injuries may be unnecessary and result in a high rates of morbidity and mortality.^[14,15,21–23] Diagnostic laparoscopy is minimally invasive procedure that offers advantage of early detection and treatment of diaphragmatic injuries.^[4,6–8,17,21,24,25] Diaphragm injury rates have been reported in range of 10% to 50% in several studies that investigated left thoracoabdominal stab injuries using diagnostic laparoscopy.^[1–5,8,22,26,27] In the present study, diaphragm injury rate was 23.5% in all patients and 22.1% in patients who underwent diagnostic laparoscopy.

Table 1. Rate of diaphragmatic injury in left thoracoabdominal stab wound

	n	Diaphragmatic injury	
		n	%
Total	81	19	23.5
Laparotomy	13	4	30.8
Diagnostic laparoscopy	68	15	22.1

Table 2. Diaphragmatic injury according to left thoracoabdominal area subgroup

	Diaphragmatic injury			
	Yes		No	
	n	%	n	%
Anterior	10	22.2	35	77.8
Lateral	7	25.9	20	74.1
Posterior	2	22.2	7	77.8
p	0.929			

Fisher Freeman Halton exact test.

Table 3. Diaphragmatic injury according to chest X-ray findings

	Diaphragmatic injury			
	Yes		No	
	n	%	n	%
Hemopneumothorax	7	36.8	12	63.2
Normal	12	19.4	50	80.6
p	0.131			

Fisher's exact test.

Early diagnosis of diaphragm injuries in left thoracoabdominal stab injuries is challenging based on physical examination, chest X-ray, ultrasonography, and tomography.^[1,2,5,28,29] Signs and symptoms may not be enough for diagnosis. In a study performed by Powell et al., 68% of patients with diaphragm injuries had normal chest X-ray.^[30] Mjoli et al. reported that 10 of 26 patients (38.5%) who had abnormal radiological findings on plain chest radiography had diaphragmatic injury, and 12 of 28 patients (42.9%) with normal chest radiography had diaphragmatic injury.^[8] Similar results have been reported in other studies.^[1,3,5] In our study, 36.8% of patients with diagnosis of hemopneumothorax had diaphragmatic injury, and 19.4% of patients with normal chest X-ray had diaphragm injury. In light of these findings, we can assume that presence of hemopneumothorax is not determining factor for diaphragm injury.

In a study conducted by Bagheri et al., stab wounds at the eighth intercostal space were found to be most responsible for diaphragm injuries in comparison of left thoracoabdominal injuries by area subgroup.^[31] Mjoli et al. found site of injury to thoracoabdominal area was anterior in 11 cases (20%), lateral in 23 (41.8%), and posterior in 20 (36.4%); anterior penetrating wounds had highest incidence of diaphragmatic injury.^[8] Anterior region was most common site of stab wound in our population; however, we found no significant difference between subgroups in terms of incidence of diaphragm injury. In contrast to studies reporting high morbidity and mortality in cases of diaphragm injury that were overlooked early on, other experimental studies have demonstrated spontaneous healing of injured diaphragm in time without any treatment. In a study performed by Shatney et al., diaphragm injury model was created in 16 pigs. Spontaneous healing was observed in 15 of the pigs (93.75%) in 6 weeks.^[32] However, data are insufficient and there have been no studies indicating spontaneous healing of the diaphragm in humans. Early evaluation of the diaphragm for injury after left thoracoabdominal stab wound continues to be important at the present time.

Limitation of this study was size of study group. Therefore, larger future studies examining impact of routine diagnostic laparoscopy are needed to clarify this issue.

Conclusion

Shortly after left thoracoabdominal stab wound, patients with diaphragm injury may be asymptomatic. Physical examination and imaging modalities may not be adequate as result of low sensitivity and specificity for diagnosing diaphragm injury. Patients who do not require laparotomy should be informed about possible latent diaphragm injury. Diagnostic laparoscopy is safe and efficient method to evaluate the diaphragm for any injury and should be presented as an option before the patient is discharged. Well-conducted, randomized, controlled studies are needed to further investigate stab wounds.

Funding

The authors declare that this study was not funded by any company or person.

Informed Consent

Informed consent was obtained from all patients.

Conflict of interest: None declared.

REFERENCES

- Murray JA, Demetriades D, Cornwell EE 3rd, Asensio JA, Velmahos G, Belzberg H, et al. Penetrating left thoracoabdominal trauma: the incidence and clinical presentation of diaphragm injuries. *J Trauma* 1997;43:624–6. [Crossref](#)
- Reber PU, Schmied B, Seiler CA, Baer HU, Patel AG, Büchler MW. Missed diaphragmatic injuries and their long-term sequelae. *J Trauma* 1998;44:183–8. [Crossref](#)
- Leppäniemi A, Haapiainen R. Occult diaphragmatic injuries caused by stab wounds. *J Trauma* 2003;55:646–50. [Crossref](#)
- Shaw JM, Navsaria PH, Nicol AJ. Laparoscopy-assisted repair of diaphragm injuries. *World J Surg* 2003;27:671–4. [Crossref](#)
- Friese RS, Coln CE, Gentilello LM. Laparoscopy is sufficient to exclude occult diaphragm injury after penetrating abdominal trauma. *J Trauma* 2005;58:789–92. [Crossref](#)
- Zantut LF, Ivatury RR, Smith RS, Kawahara NT, Porter JM, Fry WR, et al. Diagnostic and therapeutic laparoscopy for penetrating abdominal trauma: a multicenter experience. *J Trauma* 1997;42:825–31. [Crossref](#)
- Fabian TC, Croce MA, Stewart RM, Pritchard FE, Minard G, Kudsk KA. A prospective analysis of diagnostic laparoscopy in trauma. *Ann Surg* 1993;217:557–65. [Crossref](#)
- Mjoli M, Oosthuizen G, Clarke D, Madiba T. Laparoscopy in the diagnosis and repair of diaphragmatic injuries in left-sided penetrating thoracoabdominal trauma: laparoscopy in trauma. *Surg Endosc* 2015;29:747–52.
- Madden MR, Paull DE, Finkelstein JL, Goodwin CW, Marzulli V, Yurt RW, et al. Occult diaphragmatic injury from stab wounds to the lower chest and abdomen. *J Trauma* 1989;29:292–8. [Crossref](#)
- Degiannis E, Levy RD, Sofianos C, Potokar T, Florizoone MG, Saadia R. Diaphragmatic herniation after penetrating trauma. *Br J Surg* 1996;83:88–91. [Crossref](#)
- von Elm E, Altman DG, Egger M, Pocock SJ, Gøtzsche PC, Vandenbroucke JP. The strengthening of reporting of observational studies in epidemiology (STROBE) Statement: guidelines for reporting observational studies. *Int. J. Surg* 2014;12:1495–9. [Crossref](#)
- Inaba K, Demetriades D. The nonoperative management of penetrating abdominal trauma. *Adv Surg* 2007;41:51–62. [Crossref](#)
- Schmelzer TM, Mostafa G, Gunter OL Jr, Norton HJ, Sing RF. Evaluation of selective treatment of penetrating abdominal trauma. *J Surg Educ* 2008;65:340–5. [Crossref](#)
- Ohene-Yeboah M, Dakubo JC, Boakye F, Naeeder SB. Penetrating abdominal injuries in adults seen at two teaching hospitals in Ghana. *Ghana Med J* 2010;44:103–8.
- Como JJ, Bokhari F, Chiu WC, Duane TM, Holevar MR, Tandoh MA, et al. Practice management guidelines for selective nonoperative management of penetrating abdominal trauma. *J Trauma* 2010;68:721–33.
- Jansen JO, Inaba K, Rizoli SB, Boffard KD, Demetriades D. Selective non-operative management of penetrating abdominal injury in Great Britain and Ireland: survey of practice. *Injury* 2012;43:1799–804. [Crossref](#)

17. Hallfeldt KK, Trupka AW, Erhard J, Waldner H, Schweiberer L. Emergency laparoscopy for abdominal stab wounds. *Surg Endosc* 1998;12:907–10. [Crossref](#)
18. Okan I, Baş G, Ziyade S, Alimoğlu O, Eryılmaz R, Güzey D, et al. Delayed presentation of posttraumatic diaphragmatic hernia. *Ulus Travma Acil Cerrahi Derg* 2011;17:435–9. [Crossref](#)
19. Adamthwaite DN. Traumatic diaphragmatic hernia: a new indication for laparoscopy. *Br J Surg* 1984;71:315. [Crossref](#)
20. Ertekin C, Onaran Y, Güloğlu R, Günay K, Taviloğlu K. The use of laparoscopy as a primary diagnostic and therapeutic method in penetrating wounds of lower thoracic region. *Surg Laparosc Endosc* 1998;8:26–9.
21. Simon RJ, Rabin J, Kuhls D. Impact of increased use of laparoscopy on negative laparotomy rates after penetrating trauma. *J Trauma* 2002;53:297–302. [Crossref](#)
22. Berg RJ, Karamanos E, Inaba K, Okoye O, Teixeira PG, Demetriades D. The persistent diagnostic challenge of thoracoabdominal stab wounds. *J Trauma Acute Care Surg* 2014;76:418–23. [Crossref](#)
23. Keen G. Chest injuries. *Ann R Coil Surg Engl* 1974;54:124–31.
24. Cherry RA, Eachempati SR, Hydo LJ, Barie PS. The role of laparoscopy in penetrating abdominal stab wounds. *Surg Laparosc Endosc Percutan Tech* 2005;15:14–7. [Crossref](#)
25. Chol YB, Lim KS. Therapeutic laparoscopy for abdominal trauma. *Surg Endosc* 2003;17:421–7. [Crossref](#)
26. McQuay N Jr, Britt LD. Laparoscopy in the evaluation of penetrating thoracoabdominal trauma. *Am Surg* 2003;69:788–91.
27. Yucel T, Gonullu D, Matur R, Akinci H, Ozkan SG, Kuroglu E, et al. Laparoscopic management of left thoracoabdominal stab wounds: a prospective study. *Surg Laparosc Endosc Percutan Tech* 2010;20:42–5.
28. Nau T, Seitz H, Mousavi M, Vecsei V. The diagnostic dilemma of traumatic rupture of the diaphragm. *Surg Endosc* 2001;15:992–6. [Crossref](#)
29. Mahajna A, Mitkal S, Bahuth H, Krausz MM. Diagnostic laparoscopy for penetrating injuries in the thoracoabdominal region. *Surg Endosc* 2004;18:1485–7. [Crossref](#)
30. Powell BS, Magnotti LJ, Schroepel TJ, Finnell CW, Savage SA, Fischer PE, et al. Diagnostic laparoscopy for the evaluation of occult diaphragmatic injury following penetrating thoracoabdominal trauma. *Injury* 2008;39:530–4. [Crossref](#)
31. Bagheri R, Tavassoli A, Sadrizadeh A, Mashhadi MR, Shahri F, Shojaeian R. The role of thoracoscopy for the diagnosis of hidden diaphragmatic injuries in penetrating thoracoabdominal trauma. *Interact Cardiovasc Thorac Surg* 2009;9:195–8. [Crossref](#)
32. Shatney CH, Sensaki K, Morgan L. The natural history of stab wounds of the diaphragm: implications for a new management scheme for patients with penetrating thoracoabdominal trauma. *Am Surg* 2003;69:508–13.

ORJİNAL ÇALIŞMA - ÖZET

Sol torakoabdominal bölge delici kesici alet yaralanması olan hastalarda diafragmanın değerlendirilmesinde tanısal laparoskopinin önemi: İleriye yönelik kohort çalışması

Dr. Metin Yücel,¹ Dr. Adnan Özpek,¹ Dr. Hüseyin Kerem Tolan,¹ Dr. Fatih Başak,¹ Dr. Gürhan Baş,² Dr. Ethem Ünal,¹ Dr. Orhan Alimoğlu²

¹Ümraniye Eğitim ve Araştırma Hastanesi, Genel Cerrahi Kliniği, İstanbul

²Medeniyet Üniversitesi Tıp Fakültesi, Genel Cerrahi Anabilim Dalı, İstanbul, Türkiye

AMAÇ: Sol torakoabdominal bölge delici kesici alet yaralanmaları potansiyel olarak diafragma yaralanmasına neden olabilir. Bu çalışmanın amacı, sol torakoabdominal bölge delici kesici alet yaralanması olan hastalarda diafragma yaralanmasının insidansını belirlemek ve laparoskopinin diafragma yaralanmasını tespit etmedeki rolünü değerlendirmek idi.

GEREK VE YÖNTEM: Nisan 2009 ve Eylül 2014 tarihleri arasında sol torakoabdominal bölge delici kesici alet yaralanması nedeniyle kliniğimize başvuran 81 hasta (75 erkek, 6 kadın; yaş ortalaması 27.5±9.8 yıl; dağılım 14–60) çalışmaya dahil edildi. Hemodinamik instabil, peritonit bulguları ve organ eviserasyonu olan hastalara laparotomi yapılırken, diğer hastalar selektif konservatif olarak takip edildi. Laparotomi endikasyonu olmayan ve semptomsuz seyreden hastalara 48 saatlik gözlem sonunda sol diafragmayı değerlendirmek için tanısal laparoskopi uygulandı. Takip ve tedavi sonuçları ileriye yönelik olarak değerlendirildi.

BULGULAR: On üç hastaya laparotomi, kalan 68 hastaya tanısal laparoskopi uygulandı. Laparotomi yapılan hastaların dördünde, tanısal laparoskopi yapılan hastaların ise 15'inde olmak üzere toplam 19 hastada (%23.5) sol diafragmada yaralanma tespit edildi. Hemopnömotoraks olan ve olmayan hasta grupları arasında diafragma yaralanmasının insidansında fark saptanmadı (p=0.131). Diafragmatik yaralanma açısından sol torakoabdominal bölgede delici kesici aletin giriş yerleri arasında istatistiksel fark saptanmadı (p=0.929).

TARTIŞMA: Sol torakoabdominal bölge delici kesici alet yaralanmalarında diafragma değerlendirilmelidir. Tanısal laparoskopi, günümüzde hala bu amaçla kullanılan en güvenli yöntemdir.

Anahtar sözcükler: Diafragma yaralanması; sol torakoabdominal delici kesici alet yaralanması; tanısal laparoskopi.

Ulus Travma Acil Cerrahi Derg 2017;23(2):107–111 doi: 10.5505/tjtes.2016.91043