

Hemostatic effects of traditional *Inula viscosa* and *Capsella bursa-pastoris* plant mixture extract on rat liver parenchymal bleeding model

Özcan Utku Öztürk, M.D.,¹ Mustafa Uğur, M.D.,¹ Yelda Güzel, PhD.,² Mehmet Ali Öztürk, PhD.,³ Didar Gürsoy, M.D.,⁴ Serdar Doğan, M.D.,⁵ Muhyittin Temiz, M.D.¹

¹Department of General Surgery, Hatay Mustafa Kemal University Faculty of Medicine, Hatay-Türkiye

²Department of Biology, Hatay Mustafa Kemal University Faculty of Arts and Science, Hatay-Türkiye

³Institute of Biology, University of Freiburg, Freiburg-Germany

⁴Department of Pathology, Hatay Mustafa Kemal University Faculty of Medicine, Hatay-Türkiye

⁵Department of Biochemistry, Hatay Mustafa Kemal University Faculty of Medicine, Hatay-Türkiye

ABSTRACT

BACKGROUND: Failure to achieve effective bleeding control and problems related to transfusion in liver surgery are the most common causes of post-operative mortality and morbidity. Various methods/drugs including topical hemostatic agents have been employed for bleeding control in liver surgery. This study was aimed to investigate the hemostatic properties of the herb mixture extract of *Inula viscosa* and *Capsella bursa-pastoris* (IvCbp) in rat liver laceration model, which have been traditionally used as antiseptic and hemostatic agents public in Hatay/Tukey.

METHODS: Thirty rats were divided into three groups equally and blood samples were taken from all rats for preoperative hemoglobin (Hb) measurements. Then, the standard liver resection model was applied to all rats. Sponge for the first rat group, Ankaferd Blood Stopper® Trend-Tech for the second rat group and IvCbp plant extract mixture for the third group were applied to resection areas for 3 minutes. Liver samples of all rats were evaluated in terms of inflammation and necrosis intensity on the 5th post-operative day.

RESULTS: Post-operative Hb values were found as 11.0±1.1 g/dL in the sponge group, 11.9±2.0 g/dL in the Ankaferd group, and 14.1±1.2 g/dL in the IvCbp herb mixture group (p<0.001). In the histopathological examination, less necrosis was observed in the herb mixture group compared to the sponge and Ankaferd groups (p=0.001). In addition, no statistically significant necrosis difference was observed between sponge and Ankaferd groups. While less inflammation was observed in the herb mixture group compared to the other groups, Ankaferd group had the highest inflammation score (p<0.001).

CONCLUSION: IvCbp herb mixture extract group provide effective hemostatic control, caused less Hb decrease and resulted in less inflammation and necrosis compared to Ankaferd and sponge groups in a rat liver resection model.

Keywords: Bleeding; *Capsella bursa-pastoris*; ethnomedicine; hemostasis; *Inula viscosa*; liver surgery.

INTRODUCTION

One of the biggest problems in liver surgery is bleeding control and issues related to transfusion.^[1] Although many agents or surgical methods have been developed for the control of

bleeding in deep liver injuries due to blunt and penetrating traumas, and in the surgical treatment of metastatic and primary tumors of the liver, the mortality rate varies between 3% and 14%.^[2] The most common cause of morbidity and mortality is bleeding.^[3] The challenge of controlling hepatic

Cite this article as: Öztürk OU, Uğur M, Güzel Y, Öztürk MA, Gürsoy D, Doğan S, et al. Hemostatic effects of traditional *Inula viscosa* and *Capsella bursa-pastoris* plant mixture extract on rat liver parenchymal bleeding model. *Ulus Travma Acil Cerrahi Derg* 2022;28:1059-1065.

Address for correspondence: Mustafa Uğur, M.D.

Hatay Mustafa Kemal Üniversitesi Tıp Fakültesi, Genel Cerrahi Anabilim Dalı, Hatay, Türkiye

Tel: +90 326 - 229 10 00 E-mail: drmustafaugur@gmail.com

Ulus Travma Acil Cerrahi Derg 2022;28(8):1059-1065 DOI: 10.14744/tjtes.2022.90838 Submitted: 28.03.2022 Accepted: 23.05.2022

Copyright 2022 Turkish Association of Trauma and Emergency Surgery



hemorrhages is due to its sinusoidal structure, which has an excessive vascular network and lacks smooth muscle that provides vasoconstriction to stop bleeding.^[4] Although anatomical resection, hepatic artery ligation, hepatotomy, debridement, ligation, omental packing, and hepatic packing methods can be used to stop liver bleeding, the use of topical hemostatic agents has increased in recent years due to their easier application and effectiveness. Sponge control is a conventional method for liver bleeding control.^[5] Due to limited effectiveness of the sponge control method, topical hemostatic agents were investigated such as chitosan a microintermittent polysaccharide hemisphere, fibrin glue, aluminum sulfate, polyglactin, oxidized cellulose, and microfibrillar collagen in liver bleeding and found to be effective in hemostatic control.^[6] For this purpose, some medicinal plants are used as hemostatic agents.^[7] An important agent in this field is Ankaferd Blood Stopper® Trend-Tech (ABS) which has been widely used in Turkey due to its hemostatic and anti-infective properties.^[8] *Inula viscosa* and *Capsella bursa-pastoris* (IvCbp) are plants that have been used as hemostatic and wound healing agents in Hatay, Turkey.^[9] There is a minor evidence that this plant extract mixture might be a promising alternative for hemostatic control and applied as anti-infective agent.

Currently, there is no ideal hemostatic/anti-infective agents to prevent bleeding in liver surgeries. It is valuable to find locally produced, easily accessible, and cheaper hemostatic agents for bleeding control. Therefore, we aimed to investigate the hemostatic properties of the mixture of IvCbp plant mixture extract, and compared anti-bleeding features with the sponge and Ankaferd applications by using histopathological and biochemical examinations.

MATERIALS AND METHODS

This experimental study was carried out at Hatay Mustafa Kemal University (HMKU) Experimental Research Center, with the approval of the Animal Experiments Local Ethics Committee, dated 19/02/2020 and numbered 2020/02-10.

Obtaining Plant Extracts

IvCbp were collected from their natural habitats in Hatay. Herbarium samples of plants were preserved in the herbarium of the Department of Biology of HMKU (voucher specimens: *Inula viscosa*, Y Guzel-3110, *Capsella bursa-pastoris*, Y Guzel-3111). After drying the aerial parts of the plants in room conditions, they were powdered with a herb grinder and prepared by mixing them in half and half as weight in accordance with the recipe used by the local people. The mixture was extracted in pure ethanol with stirring on a magnetic stirrer for 48 h. The solvent of the filtered extract was evaporated with a vacuum evaporator at low pressure at 40°C. The crude extract, obtained with a yield of 15%, was dissolved in pure ethanol at a rate of 50 mg/ml with the help of an ultrasonic bath, and after it was absorbed into the

bandages, the alcohol was completely evaporated in the vacuumed sterile cabinet. Bandages were used in the experiments.

Laceration Model and Surgical Procedure Details

Thirty Wistar Albino male rats were used in this study. Rats were left in experimental animal production cages covered with plastic bottom sides and wire mesh and were fed with fabricated feed specially produced for experimental animals. Rats were kept in 6-character cages. Before the operation, blood was taken from the tail veins of all rats and the Hb value was determined after centrifugation. This value was recorded as pre-operative values. After the rats were divided into three equal groups, a standard non-anatomical liver laceration model was applied to each group.

To create the parenchymal bleeding, the standardized rat model of Aysan et al.^[10] was followed. In this model, standard and effective bleeding was achieved by creating a laceration at the widest horizontal edge of the left lateral lobe, which is the largest lobe in the rat liver. The advantage of this hepatic resection model is that it can create a severe bleeding pattern with a standardized wound.^[11]

All rats fasted for 6 h before the surgical procedure. Anesthesia was provided by intraperitoneal administration of ketamine hydrochloride (50 mg/kg), Xylazine (10 mg/kg) in all rats, and then analgesia was provided by administering 0.05 mg/kg intraperitoneal morphine sulfate. After shaving and

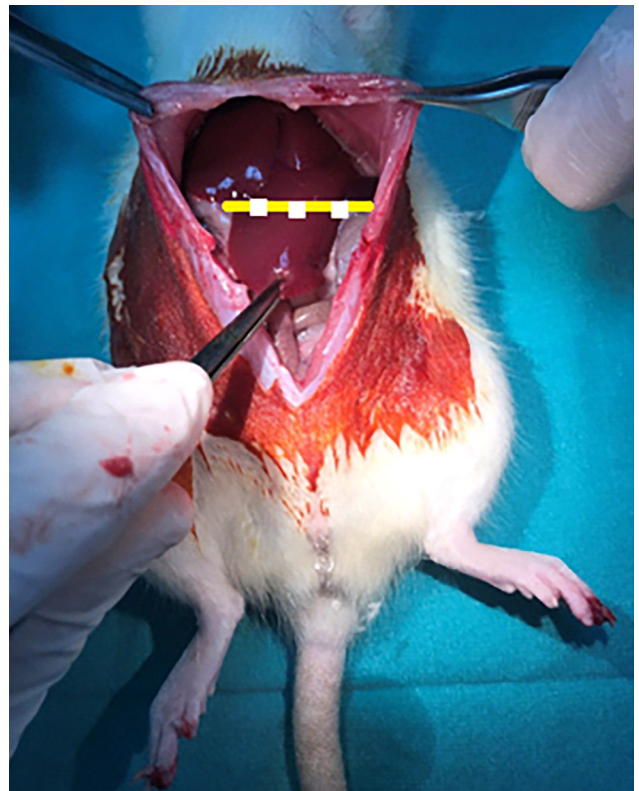


Figure 1. The left lateral lobe of rat's liver used in laceration is shown.

cleaning the abdomen of all rats, it was wiped with 7.5% Povidone-iodine.

After the anesthesia procedure, a midline incision is made and the liver; right medial and left lateral lobes were retracted upwards and left medial lobe was exposed, the longest transverse line was determined without changing the anatomical position of the lobe, and non-anatomical resection was performed on this line (Fig. 1). After waiting for 3 min of compression and bleeding times, the midline abdominal incision was closed in two layers with 3/0 polypropylene. After the procedure, all groups were given 0.05 mg/kg intraperitoneal morphine sulfate every 4 h to maintain analgesia.

Group 1: (control group, n=10); medium pressure compression was applied on the resection model with gauze pads of 5×5 cm size, impregnated with 0.9% NaCl solution for 3 min, to stop the bleeding. After 3 min, the gauze was removed from the abdomen.

Group 2 (Ankaferd group, n=10): Medium pressure compression was applied to the resection model with a 5×5 cm gauze impregnated with 1 ml ABS for 3 min to stop the bleeding. After 3 min, the gauze was applied to the abdomen and was taken out.

Group 3 (IvCbp group n=10): Medium pressure compression was applied for 3 min to stop the bleeding with a 5×5 cm gauze cloth impregnated with 1 ml of (IvCbp) extract on the resection model. Finally, the gauze was removed from the abdomen.

Scarification and Evaluation

One rat from the control group died at the post-operative 20th h. In the necropsy study performed on the animal, it was observed that blood was leaking from the incision scar and there was a very widespread hematoma in the abdomen. Blood for Hb was taken from all other rats on the post-operative 5th day, and these values were recorded as postoperative values. After general anesthesia was applied with the same operational anesthesia technique, relaparotomy was performed and hepatectomy was performed including the laceration area. Then, all subjects were sacrificed by administering a high dose of ketamine (50 mg/kg).

Biochemical Analysis of Blood

The blood samples taken were placed in EDTA tubes and studied on the Mindray BC-6800 (Shenzhen, China) hemogram device.

Histopathological Analysis of Liver

Liver tissues were fixed with 10% formalin for 24 h. Section faces were sampled to include the laceration area. After routine tissue follow-up procedures, 3–4 µm-thick sections were taken from paraffin-embedded tissues and stained with Hematoxylin-Eosin (H+E). H+E stained preparations were

evaluated at ×100 magnification according to the intensity of necrosis and inflammation under the light microscope (Olympus BX53, Japan). Scoring was done as follows:

Tissue Necrosis

- 0: No necrosis
- 1: Focal, minimal (1%)
- 2: Mild (<25%)
- 3: Medium (25–50%)
- 4: Severe (>50%)

Inflammation Intensity

- 0: No inflammation
- 1: Focal, minimal
- 2: Lightweight
- 3: Medium
- 4: Severe

Statistical Analysis

Research data were evaluated using the statistical program SPSS 24.0 (IBM Corp. Released 2016. IBM SPSS Statistics for Windows, Version 24.0. Armonk, NY: IBM Corp.). The descriptive statistics of the study are shown as numbers, percentages, and mean±standard deviation. The conformity of the variables to the normal distribution was evaluated with the Shapiro–Wilk test, the steepness and skewness coefficients, and the histogram. Chi-square tests were used for categorical data in statistical analysis. When applying multi-eye Chi-square tests, exact statistics were used since there were 20% or more eyes with a minimum expected value of <5. In case of statistically significant differences in multi-eye chi-square analysis, post hoc evaluation was made with the residuals method and the group or groups that caused the difference was determined.

One-way ANOVA was used for the comparison of the three groups in independent groups since the data conformed to the normal distribution, and Tukey tests were used because the variances were homogeneously distributed in the post hoc evaluation. Paired t-test was used for the comparison of the two groups in the dependent groups, since the differences fit the normal distribution. Type I error level was determined as p<0.05. Bonferroni correction was applied for pairwise analyzes in three groups.

RESULTS

Biochemical Evaluation

Mean pre-operative hemoglobin (Hb) value was 14.7±1.5 g/dL in the group that was compressed only with sponge (Span-dach), 15.1±1.3 g/dL in the group that was compressed with ABS it was found to be 15.2±1.3 g/dL in the IvCbp mixture group, and there was no statistical difference of pre-operative Hb values among groups (p=0.711).

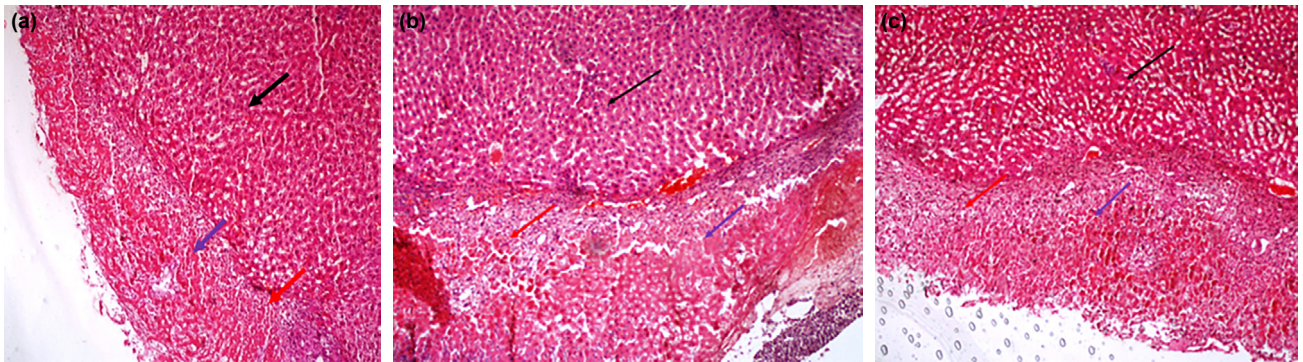


Figure 2. (a) Moderate necrosis and focal minimal inflammation in the *Inula viscosa* and *Capsella bursa-pastoris* group (H and E, ×100) black arrow: normal liver parenchyma, blue arrow: necrosis, red arrow: inflammation. (b) Severe necrosis and mild inflammation in the Ankaferd group (H and E, ×100) black arrow: normal liver parenchyma, blue arrow: necrosis, red arrow: inflammation. (c) Moderate necrosis and moderate inflammation in the sponge group (H and E, ×100) black arrow: normal liver parenchyma, blue arrow: necrosis red arrow: Inflammation.

Mean post-operative Hb values in all groups were statistically significantly lower than pre-operative Hb values ($p < 0.001$).

Table 1. Mean preoperation and postoperation hemoglobin values of rats

| | Preop Hb | Postop Hb | Hb variation | p |
|----------|----------|-----------|--------------|--------|
| | Mean±SD | Mean±SD | Mean±SD | |
| Sponge | 14.7±1.5 | 11.0±1.1 | 3.7±0.8 | <0.001 |
| Ankaferd | 15.1±1.3 | 11.9±2.0 | 3.2±1.5 | <0.001 |
| lvCbp | 15.2±1.3 | 14.1±1.2 | 1.2±0.6 | <0.001 |
| p | 0.711 | <0.001 | | |

Hb: Hemoglobin; lvCbp: *Inula viscosa* and *Capsella bursa-pastoris*; SD: Standard deviation.

Post-operative Hb values were determined as 11.0±1.1 g/dL in the sponge group, 11.9±2.0 g/dL in the Ankaferd group, and 14.1±1.2 g/dL in the lvCbp group which is higher compared to other groups ($p < 0.001$), (Table 1).

Histopathological Evaluation

Tissue necrosis

While 11.1% (n=1) focal/minimal necrosis, 55.6% (n=5) mild, 33.3% (n=3) moderate necrosis were seen in the sponge group, in the Ankaferd group, 70.0% (n=7) mild, 30.0% (n=3) moderate necrosis; in the lvCbp group, 40.0% (n=4) no necrosis, 50.0% (n=5) mild necrosis, and 10.0% (n=1) moderate necrosis were observed. Less necrosis was observed in the lvCbp group compared to other groups ($p = 0.001$), no statistically significant difference was ob-

Table 2. Comparison of tissue necrosis severity among groups

| Group | No necrosis | | Focal/minimal | | Mild | | Moderate | | p |
|----------|-------------|----|---------------|---|------|------|----------|------|---|
| | n | % | n | % | n | % | n | % | |
| | Sponge | 0 | 0 | 1 | 11.1 | 5 | 55.6 | 3 | |
| Ankaferd | 0 | 0 | 0 | 0 | 7 | 70.0 | 3 | 30.0 | |
| lvCbp | 4 | 40 | 0 | 0 | 5 | 50.0 | 1 | 10.0 | |

lvCbp: *Inula viscosa* and *Capsella bursa-pastoris*.

Table 3. Comparison of intensity of inflammation among groups

| Group | No inflammation | | Focal/minimal | | Mild | | Moderate | | p |
|----------|-----------------|----|---------------|------|------|------|----------|------|---|
| | n | % | n | % | n | % | n | % | |
| | Sponge | 0 | 0 | 1 | 11.1 | 6 | 66.7 | 2 | |
| Ankaferd | 0 | 0 | 1 | 10.0 | 2 | 20.0 | 7 | 70.0 | |
| lvCbp | 3 | 30 | 6 | 60.0 | 1 | 10.0 | 0 | 0 | |

lvCbp: *Inula viscosa* and *Capsella bursa-pastoris*.

served among the sponge and Ankaferd groups (Fig. 2a-c), (Table 2).

Intensity of Inflammation

A comparison of inflammation among treatment groups is shown in Table 3. Inflammation scores were recorded as no inflammation, focal/minimal, mild and moderate. There was no rat without inflammation in sponge and Ankaferd groups. However, there was no rat with moderate inflammation in the IvCbp group. In sponge group majority of rats were in mild 66.7% (n=6), for Ankaferd group majority of rats were in moderate 70% (n=7) and for IvCbp group majority of rats were 60% (n=6) in focal minimal category ($p<0.00.1$), (Fig. 2a-c).

DISCUSSION

This study is the first to investigate the hemostatic and histopathological effects of IvCbp on the liver parenchyma for bleeding control.

In the pig model applied by Bilgili et al.,^[12] ABS has been shown to provide hemostasis in skin abrasions, spleen. and liver lacerations. There are case reports that ABS stops bleeding during hepaticojunostomy and bleeding in rectal and duodenal ulcer, extremity laceration, coronary angiography, dental problem, epistaxis, and thyroidectomy adenoidectomy.^[13]

In Anatolia, various plants have been used as blood stoppers in traditional folk medicine (ethnomedicine) practices for centuries. Ankaferd's inspiration was also, a such traditional ethnomedicine herb blend. IvCbp, which we used in our study, are such plants that have been used as hemostatic and wound-healing agents in from Hatay to Palestine. They are widely used in the anthropological/ethnomedicinal medicine system called "Greco-Arab herbal medicine or Unani herbal medicine," which is active in this region. The Unani system of medicine, also known as Greco-Arabic medicine, is based on the doctrines of Ancient Greek and Roman doctors, Hippocrates, and Galen. This system of medicine was developed in the Middle East in the Middle Ages by Arab and Persian physicians such as Rhazes and Avicenna. These plants have been used for centuries in Hatay and its surroundings, where the Unani herbal medicine system is still in widespread use among the people, individually or as a mixture, to stop the bleeding of fresh wounds and to initiate and accelerate their healing.^[9] We could not find any literature on the hemostatic activity of *Inula viscosa* (Google Scholar, Web of Science, and PubMed). Our study would be the first on this subject. The wound healing effect of this plant was investigated by Khalil et al.^[14] and high wound healing activity was observed.

There is only one study on the hemostatic effect of *Capsella bursa-pastoris*. In the study conducted by Ghalandari et al.,^[15] it was determined that the amount of postpartum bleeding

was less in puerperal women, in which following removal of the placenta, *Capsella bursa-pastoris* extract was administered sublingually, compared to the control group. Compared with oxytocin application alone, sublingual *Capsella bursa-pastoris* drops were shown to be effective in reducing bleeding in this study.

Many topical hemostatic agents can be used during liver surgeries.^[16] Although undesirable, any topical hemostatic agent application may cause inflammation. The quality and duration of healing are the most important measures. An ideal hemostatic agent should cause minimal inflammation, minimal necrosis, no granulomatous reaction, no adhesions, abscesses, or fistulas in the healing tissue.^[17]

Kalayci et al.^[18] concluded that minimal necrosis and inflammation developed, fibrosis, abscess, or granulomatous reaction did not develop after ABS application in the rat liver resection model, and considering these findings, ABS can be used in intra-abdominal organ injuries. In our study, significantly lower inflammation and necrosis scores developed in the group in which we applied IvCbp. Although these findings suggest that IvCbp can be used in intraperitoneal injuries, more studies are needed on the subject.

As a result of the study by Satar et al.^[19] in which ABS was applied on the liver resection model, when the regeneration capacity, inflammatory changes, and adhesion scores in the ABS, Surgicel® and control groups were compared in the cytopathological examination, it was shown that both ABS and control groups tended to have more positive histopathological scores than the surgical group. In our study, regeneration and adhesion scoring were not applied after IvCbp application, and these features have the potential to be the subject of new studies.

Low Hb or hematocrit (Htc) values are used as indicators of severe bleeding and these assays are part of the basic diagnostic work-up for trauma patients.^[20] Thorson et al.^[21] analyzed Hb and Htc changes among trauma patients and concluded that the change in Hct is a reliable parameter to detect blood loss amount. In our study, significantly higher post-operative Hb values have been measured in the IvCbp group than the other groups. This indicates there is less blood loss in group IvCbp.

Conclusion

These results suggests that IvCbp mixture extract has the potential to be cheap and effective hemostatic agent. However, structural and morphological studies are needed to find the mechanism of action of plants and the most effective mixture doses. Furthermore, experimental studies are needed in terms of other clinical usages of IvCbp such as wound healing, anti-infective, and toxicity profile.

Author Note: This study was published as a medical specialization thesis of Ozan Utku Öztürk.

Ethics Committee Approval: This study was approved by the Hatay Mustafa Kemal University Animal Experiments Local Ethics Committee (Date: 19.02.2020, Decision No: 2020/02-10).

Peer-review: Internally peer-reviewed.

Authorship Contributions: Concept: O.U.Ö., M.U., M.A.Ö.; Design: O.U.Ö., M.U., S.D., D.G., MT; Supervision: M.U., Y.G., O.U.Ö.; Materials: S.D.; Data: O.U.Ö., D.G., S.D.; Analysis: D.G., S.D., O.U.Ö., M.U., M.A.Ö.; Literature search: M.T., O.U.Ö., M.A.Ö., M.U.; Writing: O.U.Ö., M.U., M.A.Ö.; Critical revision: M.U., M.A.Ö., M.T.

Conflict of Interest: None declared.

Financial Disclosure: The authors declared that this study has received no financial support.

REFERENCES

- Polanco P, Leon S, Pineda J, Puyana JC, Ochoa JB, Alarcon L, et al. Hepatic resection in the management of complex injury to the liver. *J Trauma* 2008;65:1264–70. [CrossRef]
- Velmahos GC, Toutouzas K, Radin R, Chan L, Rhee P, Tillou A, et al. High success with nonoperative management of blunt hepatic trauma: The liver is a sturdy organ. *Arch Surg* 2003;138:475–81. [CrossRef]
- Schwartz S. Hepatic resection. *Ann Surg* 1990;211:1. [CrossRef]
- Clark WR Jr., Leather RP. Hemostasis during liver resections. *Surgery* 1970;67:556–7.
- Estourgie SH, Van der Werken C, Leenen LP. The efficacy of gauze packing in liver trauma: An evaluation of the management and treatment of liver trauma. *Eur J Trauma* 2002;28:190–5. [CrossRef]
- Sakon M, Monden M, Gotoh M, Kobayashi K, Kambayashi J, Mori T, et al. Use of microcrystalline collagen powder and fibrinogen tissue adhesive for hemostasis and prevention of rebleeding in patients with hepatocellular carcinoma associated with cirrhosis of the liver. *Surg Gynecol Obstet* 1989;168:453–4. [CrossRef]
- Ebrahimi F, Torbati M, Mahmoudi J, Valizadeh H. Medicinal plants as potential hemostatic agents. *J Pharm Pharm Sci* 2020;23:10–23.
- Goker H, Haznedaroglu IC, Ercetin S, Kirazli S, Akman U, Ozturk Y, et al. Haemostatic actions of the folkloric medicinal plant extract ankaferd blood stopper®. *J Int Med Res* 2008;36:163–70. [CrossRef]
- Güzel Y, Güzelsemme M, Miski M. Ethnobotany of medicinal plants used in Antakya: A multicultural district in Hatay province of Turkey. *J Ethnopharmacol* 2015;174:118–52. [CrossRef]
- Aysan E, Bektas H, Ersoz F, Sari S, Kaygusuz A, Huq GE. Ability of the ankaferd blood stopper® to prevent parenchymal bleeding in an experimental hepatic trauma model. *Int J Clin Exp Med* 2010;3:186–91.
- Aysan E, Basak F, Kinaci E, Tutuncu H. Efficacy of local sclerosing agents on hemostasis of hepatic bleeding. *Hepatogastroenterology* 2007;54:1212–5.
- Bilgili H, Kosar A, Kurt M, Onal IK, Goker H, Captug O, et al. Hemostatic efficacy of ankaferd blood stopper® in a swine bleeding model. *Med Princ Pract* 2009;18:165–9. [CrossRef]
- Ciftciler R, Haznedaroglu IC. Ankaferd hemostat: From molecules to medicine. *Turk J Med Sci* 2020;50:1739–50. [CrossRef]
- Khalil EA, Afifi FU, Al-Hussaini M. Evaluation of the wound healing effect of some jordanian traditional medicinal plants formulated in pluronic F127 using mice (*Mus musculus*). *J Ethnopharmacol* 2007;109:104–12. [CrossRef]
- Ghalandari S, Kariman N, Sheikhan Z, Mojab F, Mirzaei M, Shahrahmani H. Effect of hydroalcoholic extract of capsella bursa pastoris on early postpartum hemorrhage: A clinical trial study. *J Altern Complement Med* 2017;23:794–9. [CrossRef]
- Berrevoet F, De Hemptinne B. Use of topical hemostatic agents during liver resection. *Dig Surg* 2007;24:288–93. [CrossRef]
- Tomizawa Y. Clinical benefits and risk analysis of topical hemostats: A review. *J Artif Organs* 2005;8:137–42. [CrossRef]
- Kalayci MU, Soylu A, Eroglu HE, Kubilay D, Sancak B, Ugurluoglu C, et al. Effect of ankaferd blood stopper on hemostasis and histopathological score in experimental liver injury. *Bratisl Lek Listy* 2010;111:183–8.
- Satar NY, Akkoc A, Oktay A, Topal A, Inan K. Evaluation of the hemostatic and histopathological effects of ankaferd blood stopper in experimental liver injury in rats. *Blood Coagul Fibrinolysis* 2013;24:518–24.
- Rossaint R, Bouillon B, Cerny V, Coats TJ, Duranteau J, Fernández-Mondéjar E, et al. The European guideline on management of major bleeding and coagulopathy following trauma. *Crit Care* 2016;20:100.
- Thorson CM, Ryan ML, Van Haren RM, Pereira R, Olloqui J, Otero CA, et al. Change in Htc during trauma assessment predicts bleeding even with ongoing fluid resuscitation. *Am Surg* 2013;79:398–406. [CrossRef]

DENEYSSEL ÇALIŞMA - ÖZ

Karaciğer parankim kanaması oluşturulan sıçanlarda *Inula viscosa* ve *Capsella bursa-pastoris* ekstre karışımının hemostatik etkisi

Dr. Ozan Utku Öztürk,¹ Dr. Mustafa Uğur,¹ Dr. Yelda Güzel,² Dr. Mehmet Ali Öztürk,³
Dr. Didar Gürsoy,⁴ Dr. Serdar Doğan,⁵ Dr. Muhyittin Temiz¹

¹Hatay Mustafa Kemal Üniversitesi Tıp Fakültesi, Genel Cerrahi Anabilim Dalı, Hatay

²Hatay Mustafa Kemal Üniversitesi Fen Edebiyat Fakültesi, Biyoloji Anabilim Dalı, Hatay

³Freiburg Üniversitesi, Biyoloji Enstitüsü, Freiburg-*Almanya*

⁴Hatay Mustafa Kemal Üniversitesi Tıp Fakültesi, Patoloji Anabilim Dalı, Hatay

⁵Hatay Mustafa Kemal Üniversitesi Tıp Fakültesi, Biyokimya Anabilim Dalı, Hatay

AMAÇ: Karaciğer cerrahisinde etkili bir kanama kontrolünün sağlanamaması ve transfüzyona bağlı problemler ameliyat sonrası mortalite ve morbiditenin en önemli nedenleridir. Bu amaçla topikal hemostatik ajanları da içeren birçok kanama durdurma yöntemi uygulanmaktadır. Bu çalışmada, sıçanlar üzerinde oluşturulan karaciğer laserasyon modeli üzerinde Hatay'da halk arasında geleneksel olarak kanama durdurucu ve antiseptik olarak kullanılan *Inula viscosa* ve *Capsella bursa-pastoris* bitkilerinin karışımının kanama durdurucu özelliğinin araştırması amaçlandı.

GEREÇ VE YÖNTEM: Çalışmada 30 sıçan, 10'arlı üç gruba ayrıldı ve bütün sıçanlardan ameliyat öncesi hemoglobin ölçümü için kan alındı. Daha sonra sıçanlara standart karaciğer rezeksiyon modeli uygulandı. Rezeksiyon bölgesine 1. grupta spanç, 2. grupta Ankaferd ve 3. grupta *Inula viscosa* ve *Capsella bursa-pastoris* bitkilerinin ekstre karışımı üç dakika süreyle uygulandı. Ameliyat sonrası beşinci gün bütün sıçanların karaciğer örnekleri enflamasyon ve nekroz yoğunluğu açısından değerlendirildi.

BULGULAR: Ameliyat sonrası Hb değerleri spanç grubunda 11.0 ± 1.1 g/dL, Ankaferd grubunda 11.9 ± 2.0 g/dL, *Inula* grubunda 14.1 ± 1.2 g/dL olarak saptanmıştır ($p < 0.001$). Yapılan histopatolojik incelemede *Inula* grubunda diğer gruplara göre daha az nekroz gözlenmiş ($p = 0.001$), spanç ve Ankaferd grupları arasında istatistiksel olarak anlamlı bir fark bulunamamıştır. *Inula* grubunda diğer gruplara göre daha az enflamasyon izlenirken Ankaferd grubunda diğer gruplara göre daha fazla enflamasyon izlenmiştir ($p < 0.001$).

TARTIŞMA: Bu çalışmada oluşturulan sıçan karaciğer rezeksiyon modelinde *Inula viscosa* ve *Capsella bursa-pastoris* ekstre karışımının Ankaferd ve spanç grubuna kıyasla daha az hemoglobin düşüşüne neden olduğu ve diğer gruplara kıyasla daha az enflamasyon ve nekroz oluşturduğu bulundu.

Anahtar sözcükler: *Capsella bursa-pastoris*; hemostaz; *Inula viscosa*; kanama; karaciğer.

Ulus Travma Acil Cerrahi Derg 2022;28(8):1059-1065 doi: 10.14744/tjtes.2022.90838