

# Effect of alpha-tocopherol and dose sensitivity on pancreatitis formation in rats with experimental pancreatitis

Deniz Tazeoğlu, M.D.,<sup>1</sup> Cüneyt Akyüz, M.D.,<sup>2</sup> Mehmet Gökçeimam, M.D.,<sup>3</sup>  
Gülçin Harman Kamalı, M.D.,<sup>4</sup> Ayhan Özsoy, M.D.,<sup>5</sup> Servet Rüştü Karahan, M.D.<sup>5</sup>

<sup>1</sup>Department of General Surgery, Mersin University Faculty of Medicine, Mersin-Turkey

<sup>2</sup>Department of General Surgery, Van Provincial Health Directorate, Başkale State Hospital, Van-Turkey

<sup>3</sup>Department of General Surgery, University of Health Sciences, Kartal Dr. Lütfi Kırdar Training and Research Hospital, İstanbul-Turkey

<sup>4</sup>Department of Pathology, University of Health Sciences, Okmeydanı Training and Research Hospital, İstanbul-Turkey

<sup>5</sup>Department of General Surgery, University of Health Sciences, Okmeydanı Training and Research Hospital, İstanbul-Turkey

## ABSTRACT

**BACKGROUND:** Acute pancreatitis is an inflammatory disease accompanied by pancreatic inflammation characterized by acinar cell damage and leukocyte infiltration in the tissue. At present, mortality and morbidity rates are high despite the current treatment of pancreatitis; therefore, new studies and treatment studies are needed. In this study, the effects of alpha-tocopherol on different doses of L-arginine-induced experimental acute pancreatitis model were investigated.

**METHODS:** Thirty adult male Sprague–Dawley albino rats were randomly divided into four groups; control (sham) group (n=6), acute pancreatitis group (n=8), low-dose alpha-tocopherol (200 mg/kg once intraperitoneal [IP]) group (n=8), and high dose alpha-tocopherol (400 mg/kg once ip) group (n=8). Experimental acute pancreatitis model was created by a single IP dose of 5 g/kg of L-arginine. Alpha-tocopherol was administered in a single dose intraperitoneally, 30 min before the creation of the experimental model of acute pancreatitis induced by L-arginine induction in Groups 3 and 4. Tissue and blood samples were taken under anesthesia 72 h after L-arginine injection; then the rats were sacrificed by decapitation. Serum amylase, lipase, interleukin (IL)-1 $\beta$ , IL-6, tumor necrosis factor (TNF)-alpha, and C-reactive protein (CRP) levels were examined. Pancreatic tissue samples were examined under a light microscope for histopathological examination.

**RESULTS:** When the acute pancreatitis group (Group 2) was compared to the control group (Group 1), serum amylase, lipase, IL-1 $\beta$ , IL-6, TNF-alpha, and CRP levels were all significantly increased (p<0.05 for all). Histopathological examination showed significant difference in edema (p<0.001) and inflammation (p=0.007) scores. When the low (Group 3) and high (Group 4) dose alpha-tocopherol groups were compared to Group 2, amylase, lipase, IL-1 $\beta$ , IL-6, TNF-alpha, and CRP parameters were statistically significantly lower (p<0.05 for all). In the histopathological comparison of Groups 2, 3, and 4, edema and inflammation scores were decreased in Groups 3 and 4 compared to Group 2. Comparing Group 4 to Group 3, lipase (p<0.01), IL-6 (p=0.038), and TNF-alpha (p=0.002) levels were significantly decreased; no significant difference was observed in the histopathological evaluation.

**CONCLUSION:** Alpha-tocopherol was found to reduce inflammation and pancreatic damage in acute pancreatitis and was more effective in high doses.

**Keywords:** Acute pancreatitis; alpha-tocopherol; interleukin-6; tumor necrosis factor-alpha.

Cite this article as: Tazeoğlu D, Akyüz C, Gökçeimam M, Harman Kamalı G, Özsoy A, Karahan SR. Effect of alpha-tocopherol and dose sensitivity on pancreatitis formation in rats with experimental pancreatitis. *Ulus Travma Acil Cerrahi Derg* 2021;27:605-612.

Address for correspondence: Mehmet Gökçeimam, M.D.

Kartal Dr. Lütfi Kırdar Şehir Hastanesi, Genel Cerrahi Kliniği, İstanbul, Turkey

Tel: +90 216 - 366 80 03 E-mail: mgokceimam@gmail.com

*Ulus Travma Acil Cerrahi Derg* 2021;27(6):605-612 DOI: 10.14744/tjtes.2020.89054 Submitted: 11.11.2019 Accepted: 10.08.2020

Copyright 2021 Turkish Association of Trauma and Emergency Surgery



## INTRODUCTION

Acute pancreatitis is a clinical presentation which is characterized by the activation of digestive enzymes, which are normally not active in the pancreas tissue, by any etiological factor and the subsequent digestion of the pancreas tissue, and the development of non-bacterial inflammation as a response. Its severity can vary from a mild edematous form to a serious necrotizing form, and it is a clinical presentation which can progress with high mortality and morbidity rates.<sup>[1]</sup>

Experimental studies to elucidate the pathophysiology of acute pancreatitis and to plan its treatment provide an opportunity to examine the efficacy of many agents. In the etiology, ischemia, alcohol, the factors causing stasis in the main pancreatic duct, and trauma are blamed. Free radicals are blamed as the most important factor in the pathogenesis. The balance between the free radicals and antioxidant substances, which is normally in balance, is disrupted in pancreatitis and inflammation occurs.<sup>[2]</sup>

Alpha-tocopherol is an anti-oxidative, anti-inflammatory, and anti-fibrotic agent. This effect is achieved by reducing the release of reactive oxygen types released from monocytes and pro-inflammatory cytokines such as interleukin (IL)-1 $\beta$ , IL-6, tumor necrotizing factor (TNF) -alpha, and suppressing inflammatory markers formed by cyclooxygenase-2 and 5-lipoxygenase.<sup>[3]</sup>

It is known that there are deficiencies in the treatment of pancreatitis, so there are still studies on effective agents in the treatment of pancreatitis. This study was planned because there is not enough research in the literature about the contribution of alpha-tocopherol to the treatment of acute pancreatitis.

Because of the advantages of alpha-tocopherol, which has antioxidant characteristics, such as being cheap and easily accessible, convenient to use and available to take with regular diet, it was planned to investigate its efficacy and dose sensitivity in the treatment of acute pancreatitis and its complications. For this purpose, we conducted this experimental study to investigate its efficacy in an experimental animal model in the treatment of acute pancreatitis.

## MATERIALS AND METHODS

The study was approved by the Animal Ethics Local Ethics Committee (No: 2018/78. HADYEK/Project 2018-29) of Health Sciences University Bağcılar Health Application and Research Center. The study was carried out at the Experimental Research and Skills Development Center within the Bağcılar Health Application and Research Center of the Health Sciences University.

## Preparation of Experiment Animals

Thirty Sprague–Dawley albino male rats weighing 285–320 g were used in this study. There was no statistically significant difference between the mean weight of the groups ( $p=0.241$ ). During the study, animals were kept under standard humidity, temperature (22°C), and light (12 h daylight/12 h dark) conditions. Standard rat feed and water were used without any restriction in feeding. All rats were kept in separate cages as groups.

## Experiment Model and Application

In this study, the acute pancreatitis model developed by Mizunuma et al.,<sup>[4]</sup> in which acute pancreatitis is formed after the intraperitoneal (IP) administration of high amounts of amino acids (arginine). In this study, laboratory and histopathological examination was performed 72 h after the experimental pancreatitis model was established.

## Experiment Protocol

Group I (Control/Sham group) (number of rats = 6): IP 5 cc saline (0.9% NaCl) was given. Group II (acute pancreatitis group [number of rats = 8]): 5 g/kg L-Arginine was injected IP to form an acute pancreatitis model.

Group III (Low-dose alpha-tocopherol group [number of rats = 8]): The low-dose alpha-tocopherol group was injected with 200 mg/kg alpha-tocopherol IP, 30 min before forming an experimental pancreatitis model, then 5 g/kg L-Arginine IP injection was administered to form an acute pancreatitis model. Group IV (High-dose alpha-tocopherol group [number of rats = 8]): The high-dose alpha-tocopherol group was administered IP 400 mg/kg alpha-tocopherol, 30 min before forming an experimental pancreatitis model with a 5 g/kg L-Arginine IP injection.

The number of rats in the control group was determined as 6 by the ethics committee. No animals died during the experimental follow-up period. After 72 h, the experiment was terminated and taken to the operating room. 90 mg/kg Ketamine and 10 mg/kg Xylazine were administered intraperitoneally. The duodenum and adjacent pancreatic tissue was found and all were removed. Pancreatic tissue taken for histopathological examination was placed in 10% formaldehyde. While the rat was on the operating table, 10 cc blood was collected by the intracardiac method. The rat was sacrificed by decapitation.

## Chemical Substances Used in the Experiment

L-arginine was obtained from Sigma–Aldrich, St. Louis, USA and Alpha-tocopherol from Farmalabs Medical Industry Ltd. Inc. İstanbul, Turkey. Xylazine used for anesthesia was obtained from Alfasan International B.V. Woerden, The Netherlands company and Ketamine from Pfizer Medications Ltd. Inc. İstanbul, Turkey company. Serum physiological (0.9% NaCl)

was obtained from Incpharma Medical Industry Ltd. Inc. İstanbul, Turkey.

### Laboratory Evaluation

Amylase, lipase, C-reactive protein (CRP), IL-1 $\beta$ , IL-6, and TNF-alpha parameters were studied on optical density 450 nm wavelength biotech ELX800.

### Histopathological Examination

Histopathological evaluations were performed by a single pathologist in the pathology laboratory according to the unilateral blanking method. Samples stained with Hematoxylin Eosin (HE) were examined under light microscope. Edema, acinar necrosis, hemorrhage, peripancreatic fat necrosis, fibrosis, vacuolization, and inflammatory cell rate for pancreatic tissue were evaluated according to the scoring defined by Schmidt et al.<sup>[5]</sup> The edema and hemorrhage were graded based on their localization, inflammatory cells (leukocyte infiltration), acinar necrosis, peripancreatic fat necrosis, acinar vacuolization, and fibrosis were graded according to the number of affected lobules. The criteria were rated between 0 and 4.

### Biostatistical Evaluation

Statistical Package for the Social Sciences for Windows 25.0 was used for statistical analysis. In addition to descriptive statistical methods (mean, standard deviation), Mann–Whitney U, Kruskal–Wallis, and Chi-square tests were used for comparison of the groups, and  $p < 0.05$  was considered significant.

## RESULTS

In this study, the presence of pancreatitis was determined by histopathological and laboratory parameters in all 24 rats (Groups 2, 3, and 4), in which pancreatitis was planned to be created by single dose IP injection of L-arginine 5 g/kg.

### Biochemical Evaluation Results

When amylase, lipase, IL-1 $\beta$ , IL-6, TNF-alpha, and CRP parameters were evaluated, a statistically significant difference was found between the groups ( $p < 0.001$ ) (Table 1). All parameters were increased between control and pancreatitis groups and decreased in alpha-tocopherol groups (Groups 3 and 4) and these changes were statistically significant. Among the low-dose and high-dose alpha-tocopherol groups only lipase, IL-6 and TNF-alpha were found to decrease at a statistically significant level (Table 2).

### Statistical Evaluation of Histopathological Results

Acinar necrosis, edema, hemorrhage, fat necrosis, inflammatory infiltration, and perivascular inflammation in the Schmidt criteria were evaluated during the histopathological examination. There was a statistically significant difference between the groups in the edema ( $p < 0.001$ ) and inflammation ( $p = 0.007$ ) scores (Table 3).

A statistically significant difference was observed between the edema scores of the groups ( $p < 0.001$ ) (Table 3). The edema scores of Group 1 were significantly lower than Group 2,

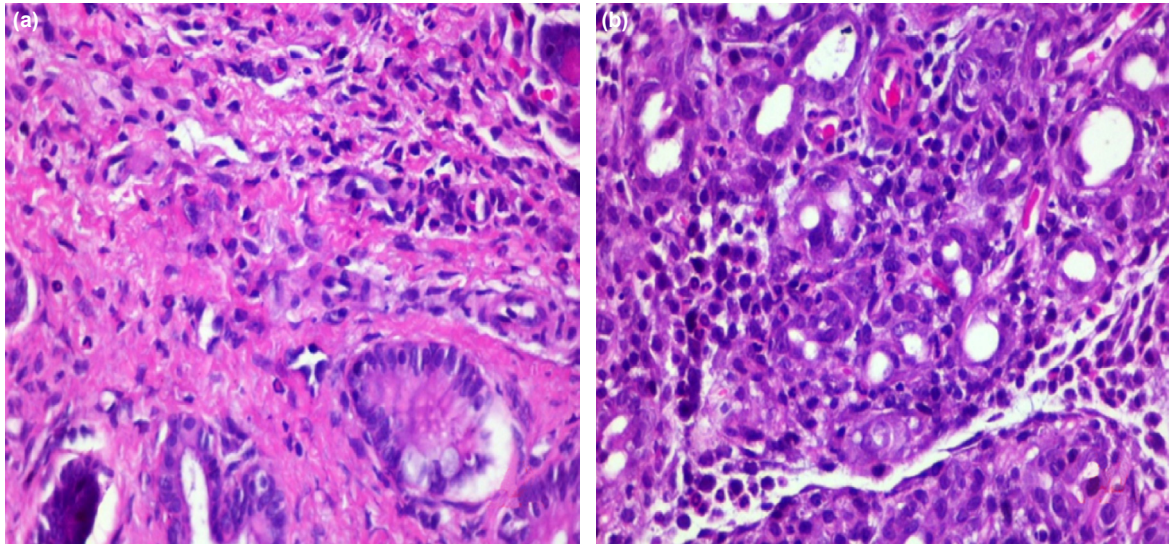
**Table 1.** Means of the blood parameters of the groups (p-value, Kruskal-Wallis test)

	Group 1	Group 2	Group 3	Group 4	p
Amylase	349.65 $\pm$ 30.90	2620.58 $\pm$ 102.11	2005.62 $\pm$ 77.51	2007.9 $\pm$ 59.62	0.01
Lipase	6.85 $\pm$ 1.80	192.38 $\pm$ 17.11	119.16 $\pm$ 13.51	88.79 $\pm$ 9.17	0.001
Interleukin -1 $\beta$	16.5067 $\pm$ 1.65	47.28 $\pm$ 4.03	41.18 $\pm$ 2.45	40.42 $\pm$ 2.22	0.001
Interleukin-6	12.15 $\pm$ 1.99	54.79 $\pm$ 6.31	36.09 $\pm$ 6.35	28.29 $\pm$ 7.06	0.001
Tumor necrotizing factor-alfa	6.51 $\pm$ 0.72	36.83 $\pm$ 3.31	23.20 $\pm$ 1.61	19.71 $\pm$ 1.49	0.001
C-reactive protein	73.23 $\pm$ 13.62	451.98 $\pm$ 61.10	311.81 $\pm$ 18.29	289.17 $\pm$ 31.02	0.001

**Table 2.** Mutual evaluation of laboratory results among groups

	Amylase	Lipase	Interleukin-1 $\beta$	Interleukin-6	TNF-alfa	CRP
Group 1 / Group 2	0.001	0.001	0.001	0.001	0.001	0.001
Group 1 / Group 3	0.001	0.001	0.01	0.001	0.001	0.01
Group 1 / Group 4	0.001	0.001	0.01	0.01	0.001	0.01
Group 2 / Group 3	0.001	0.001	0.007	0.001	0.001	0.001
Group 2 / Group 4	0.001	0.001	0.002	0.001	0.001	0.001
Group 3 / Group 4	0.93	0.01	0.798	0.038	0.002	0.161

TNF: Tumor necrotizing factor; CRP: C-reactive protein.



**Figure 1.** Interlobular infiltration (400× magnification, comparison of Group 3 [a] and Group 2 [b]).

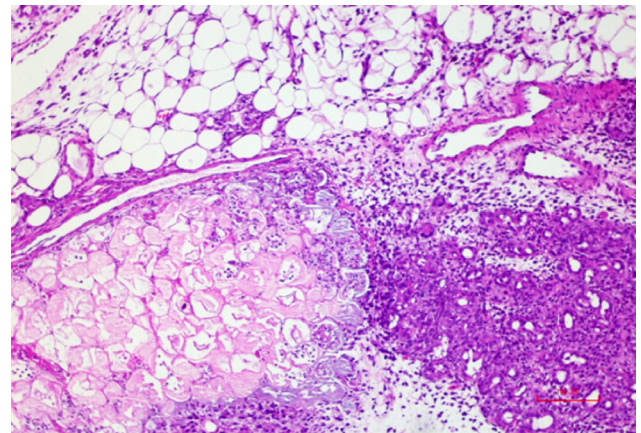
Group 3 and Group 4 ( $p=0.005$ ;  $p=0.019$ ;  $p=0.04$ ) (Table 4). The edema scores of Group 2 were significantly lower than those of Groups 3 and 4 ( $p<0.01$ ,  $p=0.005$ ). No statistical difference was observed between Groups 3 and 4 ( $p=0.264$ ) (Table 4).

No statistically significant difference was observed between the hemorrhage scores of the groups ( $p=0.317$ ) (Table 3). Hemorrhage score of Group 1 was found to be statistically significantly lower than Group 3 ( $p=0.049$ ) (Table 4). There was no statistically significant difference between the other

groups. There was a statistically significant difference between the mean inflammation and perivascular infiltration scores of the groups ( $p=0.007$ ) (Table 3). Inflammation and perivascular infiltration scores of Group 1 were significantly lower than Group 2 ( $p=0.005$ ). The mean inflammation and perivascular infiltration scores of Group 2 were significantly lower than Group 3 and Group 4 ( $p=0.025$ ,  $p=0.023$ ). No

**Table 3.** Differences between groups according to pathology score (p-value, Chi-Square test)

	p-value
Edema	0.001
Acinar necrosis	0.392
Hemorrhage	0.317
Fat necrosis	0.117
Inflammation and perivascular infiltration	0.007



**Figure 2.** Edema and fat necrosis (100× magnification, Group 2. Acute pancreatitis group).

**Table 4.** Mutual evaluation of groups according to pathology score (p-value, Chi-Square test)

	Edema	Acinar Necrosis	Hemorrhage	Fat Necrosis	Inflammation
Group 1 / Group 2	0.005	0.38	0.413	0.186	0.005
Group 1 / Group 3	0.019	A	0.049	B	0.241
Group 1 / Group 4	0.04	A	0.239	B	0.417
Group 2 / Group 3	0.01	0.255	0.454	0.131	0.025
Group 2 / Group 4	0.005	0.255	0.504	0.131	0.023
Group 3 / Group 4	0.264	A	0.241	B	0.355

A: As the acinar necrosis value was constant, no statistics were calculated. B: As the fat necrosis value was constant, no statistics were calculated.



statistical difference was observed between the other groups ( $p=0.355$ ) (Table 4 and Figs. 1 and 2).

No statistically significant difference was observed between the acinar necrosis score values of the groups ( $p=0.392$ ) and the mean fat necrosis score of the groups ( $p=0.117$ ) (Table 3). There was no difference in these parameters between the groups and/or it could not be calculated.

## DISCUSSION

Acute pancreatitis is an inflammatory process that affects the pancreas and peripancreatic tissues at different levels. Pancreatic involvement varies from mild parenchymal edema to severe hemorrhagic pancreatitis.<sup>[1]</sup> Although there are different reasons in the pathogenesis of acute pancreatitis, free oxygen radicals may cause lipid peroxidation as a result of oxidative stress and cause acute pancreatitis.<sup>[6]</sup> Free oxygen radicals are involved in both the initial and progression stages of the pathophysiology of acute pancreatitis.<sup>[7]</sup>

In the experimental pancreatitis model developed by Mizunuma et al.,<sup>[4]</sup> IP administration of high-dose amino acid (Arginine) has been shown to form a pancreatitis clinical presentation. In the experimental pancreatitis model after arginine IP administration, it was determined that changes in the pancreas tissue and laboratory values started within 24 h after arginine injection, and after 72 h, the laboratory and histopathological changes reflected the clinic of pancreatitis.<sup>[8]</sup> This experimental model was also used in our study, and it was understood from the statistical difference of the results of blood and histopathological examination between Group 1 and Group 2 that an active experimental pancreatitis developed in rats after L-arginine administration.

Vitamin E is a vitamin that can be taken and stored in sufficient amounts with a regular diet. Due to its ability to be stored, its deficiency is rare. Of the eight different forms of Vitamin E, alpha-tocopherol is the most active and functional. Alpha-tocopherol has an anti-inflammatory, antifibrotic, and antioxidant effect by affecting pro-inflammatory cytokine release.<sup>[9]</sup>

In the literature, there are studies showing that alpha-tocopherol has a preventive effect on lipid peroxidation.<sup>[10]</sup> In their experimental study, Sena et al.<sup>[11]</sup> showed that alpha-tocopherol supplementation decreases glycosylated hemoglobin level and lipid peroxidation in the pancreas in diabetic rats. In our study, the efficacy of alpha-tocopherol at different doses was examined. Lipase ( $p<0.01$ ), IL-6 ( $p=0.038$ ), and TNF-alpha ( $p=0.002$ ) parameters were significantly decreased in the high dose group compared to the low dose group.

In their study, Filipenko et al.<sup>[12]</sup> investigated the effect of antioxidant (alpha-tocopherol and ionol) agents on lipid peroxidation in the acute pancreatitis model in dogs and showed

that antioxidants interacted with membrane lipophilic components to protect the cell membranes against lipid peroxidation in the lipid bilayers.

There are studies in the literature about the reflection of alpha-tocopherol to the tissue level depending on age and daily intake. In the experimental model of chronic pancreatitis by Li et al.,<sup>[13]</sup> alpha-tocopherol activity and dose change were investigated. Alpha-tocopherol treatment prevented mortality, pancreatic inflammation, pseudocyst, and fibrosis formation. In our study, alpha-tocopherol had a positive effect on edema and inflammation at the tissue level. However, this beneficial effect increased with dose increase, it was found to be statistically insignificant. Takahashi et al.<sup>[14]</sup> found that alpha-tocopherol levels underwent tissue-specific and age-related changes.

There are studies investigating the effect of alpha-tocopherol on cytokine release in the inflammation stage. In the experimental study of Monteiro et al.,<sup>[15]</sup> it was shown that synthesis of some inflammatory biomarkers decreased, confirming the participation of Vitamin E in the inflammatory response in the pancreas. In our study, when comparing low and high dose alpha-tocopherol groups with acute pancreatitis group, alpha-tocopherol was found to statistically significantly decrease IL-1 $\beta$  ( $p=0.007$ ,  $p=0.002$ ), IL-6 ( $p<0.001$ ,  $p<0.001$ ), TNF-alpha ( $p<0.001$ ,  $p<0.001$ ), and CRP ( $p<0.001$ ,  $p<0.001$ ) levels. Histopathological examination revealed a statistically significant decrease in edema ( $p<0.01$ ,  $p=0.005$ ) and inflammation ( $p=0.025$ ,  $p=0.023$ ).

Amylase and lipase are the most commonly used enzymes in the diagnosis of acute pancreatitis. In the study of Treacy et al.,<sup>[16]</sup> the sensitivity and specificity of serum amylase were 45% and 97% in the diagnosis of acute pancreatitis, respectively, for urine amylase they were 63% and 85%, respectively, and for serum lipase they were 67% and 97%, respectively. In the low-dose (Group 3) and high-dose (Group 4) groups, the amylase value was unaffected by the dose increase ( $p=0.93$ ), whereas the lipase value was affected by showing a further decrease ( $p<0.01$ ). This result was interpreted as the sensitivity of lipase being higher than that of amylase.

In our study, alpha-tocopherol was found to be effective in reducing hyperamylasemia and hyperlipasemia in acute pancreatitis. Amylase and lipase levels were increased in all rats treated with L-arginine, but amylase and lipase levels were significantly lower in the alpha-tocopherol groups than in the non-treated group. We believe that the increase in amylase and lipase and the pancreatitis clinic was observed despite the presence alpha-tocopherol in all groups except the control group, but we think that suppression of the inflammatory process after experimental pancreatitis resulted in a decrease in cellular level damage and kept the level of amylase and lipase due to inflammatory destruction under a certain level. Alpha-tocopherol cannot prevent the formation of in-

flammation and edema that leads to the pancreatitis clinic, but it reduces the destructive inflammatory effects and severity when other parameters are evaluated. When the high and low dose effects were evaluated, between the low dose (Group 3) and high dose (Group 4) groups, it was observed that the amylase value was not affected by the increase in the dose ( $p=0.93$ ), but the lipase value was affected with a bigger degree of decrease ( $p<0.01$ ). This result was interpreted as the sensitivity of lipase being higher than that of amylase. Despite these evaluations, there is literature showing that amylase and lipase levels increased in the experimental acute pancreatitis model, but that it does not correlate with the clinical presence of pancreatitis.<sup>[17]</sup>

If the biochemical effects of alpha-tocopherol are evaluated, it is observed that serum TNF-alpha, IL-1 $\beta$  and IL-6 levels and associated pancreatic damage increased after L-arginine injection. When the low and high dose alpha-tocopherol groups were compared with the acute pancreatitis group, a significant decrease in the TNF-alpha ( $p<0.001$ ,  $p<0.001$ ), IL-1 $\beta$  ( $p=0.007$ ,  $p=0.002$ ), and IL-6 ( $p<0.001$ ,  $p<0.001$ ) levels was found. This effect was interpreted as alpha-tocopherol being effective against L-arginine-induced inflammation and oxidative stress, leading to pro-inflammatory cytokine synthesis, and pancreatic damage.

It was shown that alpha-tocopherol had a positive effect in the high-dose group compared to the low-dose group, with a statistically significant decrease in TNF-alpha ( $p=0.002$ ) and IL-6 ( $p=0.038$ ). This result was interpreted as alpha-tocopherol being effective in reducing inflammation in pancreatitis at high doses.

CRP and IL-1 $\beta$  are acute phase reactants and increase in accordance with the severity of inflammation. In this study, it was observed that alpha-tocopherol decreased CRP and IL-1 $\beta$  levels in rats with experimental pancreatitis, but there was no significant difference between high dose and low dose. This difference, especially in IL-1 $\beta$ , suggests that even low-dose alpha-tocopherol is sufficiently effective in IL-1 $\beta$ , a marker of inflammation. In addition, we think that IL-1 $\beta$  may have interactions with alpha-tocopherol at a molecular level. This should be evaluated in a separate study. In particular, IL-6 and TNF-alpha are significantly affected by the dose difference of alpha tocopherol, suggesting a higher probability that there may be an interaction at the molecular level we have mentioned.

NF- $\kappa$ B, TNF-alpha, IL-1 $\beta$ , IL-6, IL-8, platelet activating factor, monocyte chemoattractant cytokine, and intracellular adhesion molecules are released and the complement system is activated within hours as an inflammatory response to local tissue injury in acute pancreatitis.<sup>[18]</sup>

IL-6 regulates the synthesis of acute-phase proteins such as fibrinogen, serum amyloid A, and CRP. Although IL-6 is a

pro-inflammatory cytokine, it is considered to be an indicator of disease severity rather than a direct inflammatory mediator. In a prospective clinical study by Park et al.,<sup>[19]</sup> IL-6 was found to be a good predictor of acute pancreatitis severity and was associated with obesity and central fat distribution. Mayer et al.<sup>[20]</sup> reported that IL-6 is useful in predicting pulmonary complications due to acute pancreatitis.

There are studies investigating the effect of alpha-tocopherol on cytokine release in the inflammation stage. Jamal et al.<sup>[21]</sup> showed in their experimental study that ascorbic acid and alpha-tocopherol may cause significant anti-inflammatory effects by decreasing the level of inflammatory factors such as TNF-alpha, serum amyloid A, and CRP. In an experimental study by Shukla et al.,<sup>[22]</sup> alpha-tocopherol has been shown to reduce lipid peroxidation, TNF-alpha, IL-6, and CRP levels on myocardial cells.

When the pancreas tissue was evaluated histopathologically, L-arginine was seen to have caused edema, acinar necrosis, hemorrhage, fat necrosis, and inflammation in the pancreas tissue. It was observed that alpha-tocopherol had a decreasing effect on pancreatic injury and there was a statistically significant difference between the groups on edema and inflammation. Pancreatic damage was not affected histopathologically by the dose increase.

It is clear that alpha-tocopherol decreases edema and inflammation in rats with pancreatitis. Although this effect increases slightly with dose, this increase is not statistically significant. Higher doses of alpha-tocopherol than we used in the experiment may affect this effect significantly, but it may be misleading to comment before clarifying the reason why IL-1 $\beta$ , which we mentioned earlier, is statistically affected by the dose. The reasons why alpha tocopherol, which has been so effective on inflammation, do not statistically affect hemorrhage, fat necrosis, and acinar necrosis values could be because alpha-tocopherol affects the inflammatory process from the very beginning and no tissue damage can be seen, the experimental pancreatitis model does not form a severe enough pancreatitis to cause advanced hemorrhage and necrosis, the damage caused by L-arginine cannot be sustained and cause persistent damage, as seen in the normal clinical presentation (example: Damage in biliary pancreatitis continues until the biliary agent is removed), or the sampling group may be too narrow.

The development of acute pancreatitis is a complex process involving a sequence of reactions that begin in pancreatic acinar cells.<sup>[23]</sup> Pathological diagnosis is an important index to evaluate the severity of acute pancreatitis. Hegyi et al.<sup>[4]</sup> studied the early and late phases of L-arginine-induced pancreatitis model in rats. They showed that the early phase of acute pancreatitis is characterized by acute pancreatic inflammation with intercellular edema infiltration of leukocytes, capillary dilatation, and microfocal parenchymal necrosis. Several ex-

perimental studies have also shown that L-arginine causes histopathological changes resulting in edema, cell infiltration and necrosis.<sup>[24,25]</sup>

Gómez et al.<sup>[26]</sup> reported that Vitamin E reduces acinar atrophy, fibrosis, and inflammation in the pancreas in rats with experimental pancreatitis. In the experimental model of chronic pancreatitis, Jiang et al.<sup>[27]</sup> found that alpha-tocopherol and tocotrienol reduce inflammation and fibrosis and tocotrienol is more effective than alpha-tocopherol. In the study of Ayvaz<sup>[8]</sup> when the effect of amifostine, bortezomib, octreotide, Vitamin E, and Vitamin C in the prevention of L-arginine-induced acute pancreatitis was examined, no statistically significant effect of Vitamin E on histopathological improvement was observed.

In this study, when the pancreatic tissue was evaluated histopathologically, it was observed that L-arginine caused edema, acinar necrosis, hemorrhage, fat necrosis, and inflammation in the pancreatic tissue. It was observed that alpha-tocopherol had a decreasing effect on pancreatic injury and there was a statistically significant difference between the groups on edema and inflammation. Pancreatic damage was not affected histopathologically by a dose increase.

## Conclusion

In this study, the effect of alpha-tocopherol on pancreatitis was proved by laboratory and histopathological examination. Amylase, lipase, IL-1 $\beta$ , IL-6, TNF-alpha, and CRP parameters were decreased significantly with the effect of alpha-tocopherol. Histopathological examination showed a statistically significant difference in edema and inflammation scores, but no difference was observed in acinar necrosis, hemorrhage and fat necrosis scores.

In this study, low dose and high dose groups were compared to determine the effects of alpha-tocopherol at different doses. Lipase, IL-6 and TNF-alpha parameters were significantly different in the high dose group. No effect of dose change on a tissue level was observed. Alpha-tocopherol should be considered as a good option in the treatment of pancreatitis. Larger experimental and clinical trials are needed to evaluate the clinical effects of alpha-tocopherol on acute pancreatitis, as well as possible side effects.

**Ethics Committee Approval:** This study was approved by the Health Sciences University Istanbul Bağcılar Training and Research Hospital Animal Experimental Local Ethics Committee (Date: 03.07.2018, Decision No: 2018/78).

**Peer-review:** Internally peer-reviewed.

**Authorship Contributions:** Concept: D.T., C.A., A.Ö.; Design: D.T., C.A., A.Ö.; Supervision: D.T., C.A., A.Ö.; Resource: D.T., C.A.; Materials: D.T., C.A.; Data: D.T., C.A.; Analysis: D.T., M.G., G.H.K.; Literature search: D.T., M.G., G.H.K.; Writing: D.T., M.G.; Critical revision: M.G., A.Ö., S.R.K.

**Conflict of Interest:** None declared.

**Financial Disclosure:** The authors declared that this study has received no financial support.

## REFERENCES

1. Wang GJ, Gao CF, Wei D, Wang C, Ding SQ. Acute pancreatitis: Etiology and common pathogenesis. *World J Gastroenterol* 2009;15:1427–30.
2. Nordberg J, Arnér ES. Reactive oxygen species, antioxidants and the mammalian thioredoxin system. *Free Radic Biol Med* 2001;31:1287–312. [CrossRef]
3. Kirmizis D, Chatzidimitriou D. Antiatherogenic effects of Vitamin E: The search for the Holy Grail. *Vasc Health Risk Manag* 2009;5:767–74.
4. Mizunuma T, Kawamura S, Kishino Y. Effects of injecting excess arginine on rat pancreas. *J Nutr*. 1984;114:467–71. [CrossRef]
5. Schmidt J, Rattner DW, Lewandrowski K, Compton CC, Mandavilli U, Knoefel WT, et al. A better model of acute pancreatitis for evaluating therapy. *Ann Surg* 1992;215:44–56. [CrossRef]
6. Su KH, Cuthbertson C, Christophi C. Review of experimental animal models of acute pancreatitis. *HPB (Oxford)* 2006;8:264–86. [CrossRef]
7. Braganza JM, Scott P, Bilton D, Schofield D, Chaloner C, Shiel N, et al. Evidence for early oxidative stress in acute pancreatitis. Clues for correction. *Int J Pancreatol* 1995;17:69–81. [CrossRef]
8. Ayvaz O. L-argininin İndüklediği Deneysel akut Pankreatiti Önlemede Amifostin, Bortezomid, Oktreotid, E ve C Vitaminlerinin Etkinliği. Uzmanlık Tezi. Adnan Menderes Üniversitesi Tıp Fakültesi, İç Hastalıkları Anabilim Dalı, Aydın; 2010.
9. Singh U, Devaraj S, Jialal I. Vitamin E, oxidative stress, and inflammation. *Annu Rev Nutr* 2005;25:151–74. [CrossRef]
10. Fukuzawa K. Dynamics of lipid peroxidation and antioxidant of alpha-tocopherol in membranes. *J Nutr Sci Vitaminol (Tokyo)* 2008;54:273–85.
11. Sena CM, Nunes E, Gomes A, Santos MS, Proença T, Martins MI, et al. Supplementation of coenzyme Q10 and alpha-tocopherol lowers glycated hemoglobin level and lipid peroxidation in pancreas of diabetic rats. *Nutr Res (NY)* 2008;28:113–21. [CrossRef]
12. Filipenko PS, Salii IS, Potapov GV. Effects of ionol and alpha-tocopherol on lipid peroxidation in the liver of dogs with acute pancreatitis. *Patol Fiziol Eksp Ter*. 2008;3:29–31.
13. Li XC, Lu XL, Chen HH.  $\alpha$ -Tocopherol treatment ameliorates chronic pancreatitis in an experimental rat model induced by trinitrobenzene sulfonic acid. *Pancreatol* 2011;11:5–11. [CrossRef]
14. Takahashi K, Takisawa S, Shimokado K, Kono N, Arai H, Ishigami A. Age-related changes of vitamin E:  $\alpha$ -tocopherol levels in plasma and various tissues of mice and hepatic  $\alpha$  tocopherol transfer protein. *Eur J Nutr* 2017;56:1317–27. [CrossRef]
15. Monteiro TH, Silva CS, Ambrosio LM, Zucoloto S, Vannucchi H. Vitamin E alters inflammatory gene expression in alcoholic chronic pancreatitis. *J Nutrigenet Nutrigenomics* 2012;5:94–105. [CrossRef]
16. Treacy J, Williams A, Bais R, Willson K, Worthley C, Reece J, et al. Evaluation of amylase and lipase in the diagnosis of acute pancreatitis. *ANZ J Surg* 2001;71:577–82. [CrossRef]
17. Xenoulis PG. Diagnosis of pancreatitis in dogs and cats. *J Small Anim Pract* 2015;56:13–26. [CrossRef]
18. Matheus AS, Coelho AM, Sampietre S, Patzina R, Jukemura J, Cunha JE, et al. Effect of inhibition of prostaglandin E2 production on pancreatic infection in experimental acute pancreatitis. *HPB (Oxford)* 2007;9:392–7. [CrossRef]
19. Park J, Chang JH, Park SH, Lee HJ, Lim YS, Kim TH, et al. Interleukin-6 is associated with obesity, central fat distribution, and disease severity in patients with acute pancreatitis. *Pancreatol* 2015;15:59–63.
20. Mayer J, Rau B, Gansauge F, Beger HG. Inflammatory mediators in human acute pancreatitis: Clinical and pathophysiological implications. *Gut*

- 2000;47:546–52. [CrossRef]
21. Jamal M, Rezazadeh M, Zeinali M, Ghaffari MA. Effect of ascorbic acid and alpha-tocopherol supplementations on serum leptin, tumor necrosis factor alpha, and serum amyloid A levels in individuals with Type 2 diabetes mellitus. *Avicenna J Phytomed* 2015;5:531–9.
  22. Shukla SK, Sharma SB, Singh UR. Pre-treatment with  $\alpha$ -tocopherol and Terminalia arjuna ameliorates, pro-inflammatory cytokines, cardiac and apoptotic markers in myocardial infarcted rats. *Redox Rep* 2015;20:49–59. [CrossRef]
  23. Mole DJ, Webster SP, Uings I, Zheng X, Binnie M, Wilson K, et al. Ky-nurenine-3-monooxygenase inhibition prevents multiple organ failure in rodent models of acute pancreatitis. *Nat Med* 2016;22:202–9. [CrossRef]
  24. El-Ashrawy NE, Khedr NF, El-Bahrawy HA, Hamada OB. Anti-inflammatory and antioxidant effects of captopril compared to methylprednisolone in L-arginine-induced acute pancreatitis. *Dig Dis Sci* 2018;63:1497–505. [CrossRef]
  25. Hu N, Shen Y, Liu F, Wu J, Yuan F, Tian L, et al. Morphological and immunobiochemical analysis of the liver in L-arginine induced experimental chronic pancreatitis. *Pancreatol* 2017;17:247–54. [CrossRef]
  26. Gómez JA, Molero X, Vaquero E, Alonso A, Salas A, Malagelada JR. Vitamin E attenuates biochemical and morphological features associated with development of chronic pancreatitis. *A J Physiol Gastrointest Liver Physiol* 2004;287:162–9. [CrossRef]
  27. Jiang F, Liao Z, Hu LH, Du YQ, Man XH, Gu JJ, et al. Comparison of antioxidative and antifibrotic effects of  $\alpha$ -tocopherol with those of tocotrienol-rich fraction in a rat model of chronic pancreatitis. *Pancreas* 2011;40:1091–6. [CrossRef]

## DENEYSSEL ÇALIŞMA - ÖZ

## Deneysel pankreatit oluşturulan sıçanlarda alfa-tokoferol'ün pankreatit oluşumuna etkisi ve doz duyarlılığının incelenmesi

Dr. Deniz Tazeoğlu,<sup>1</sup> Dr. Cüneyt Akyüz,<sup>2</sup> Dr. Mehmet Gökçeimam,<sup>3</sup>  
Dr. Gülçin Harman Kamalı,<sup>4</sup> Dr. Ayhan Özsoy,<sup>5</sup> Dr. Servet Rüştü Karahan<sup>5</sup>

<sup>1</sup>Mersin Üniversitesi Tıp Fakültesi, Genel Cerrahi Anabilim Dalı, Mersin

<sup>2</sup>Van İl Sağlık Müdürlüğü, Başkale Devlet Hastanesi, Genel Cerrahi Kliniği, Van

<sup>3</sup>Sağlık Bilimleri Üniversitesi, Kartal Dr. Lütfi Kırdar Eğitim ve Araştırma Hastanesi, Genel Cerrahi Kliniği, İstanbul

<sup>4</sup>Sağlık Bilimleri Üniversitesi, Okmeydanı Eğitim ve Araştırma Hastanesi, Patoloji Kliniği, İstanbul

<sup>5</sup>Sağlık Bilimleri Üniversitesi, Okmeydanı Eğitim ve Araştırma Hastanesi, Genel Cerrahi Kliniği, İstanbul

**AMAÇ:** Akut pankreatit, asiner hücre hasarı ve lökosit infiltrasyonu ile karakterize pankreas enflamasyonun eşlik ettiği enflamatuvar hastalıktır. Günümüzde pankreatitin mevcut tedavisine rağmen mortalite ve morbidite yüksektir; bu nedenle yeni çalışmalara ve tedavi araştırmalarına ihtiyaç vardır. Bu çalışma, sıçanlarda L-arginin ile indüklenen deneysel akut pankreatit modelinde alfa-tokoferol'ün farklı dozlarda etkileri araştırıldı.

**GEREÇ VE YÖNTEM:** Otuz adet yetişkin erkek Sprague Dawley albino sıçan, rastgele dört gruba ayrıldı; kontrol (sham) grubu (n=6), akut pankreatit grubu (n=8), düşük doz alfa-tokoferol (200 mg/kg bir kez i.p.) grubu (n=8) ve yüksek doz alfa-tokoferol (400 mg/kg bir kez i.p.) grubu (n=8). Deneysel akut pankreatit modeli, tek doz i.p. 5 g/kg L-arginin verilmesiyle oluşturuldu. Alfa-tokoferol, Grup 3 ve 4'te L-arginin indüksiyonu ile oluşturulan deneysel akut pankreatit modelinden otuz dakika önce intraperitoneal olarak tek dozda uygulandı. L-arginin enjeksiyonundan 72 saat sonra anestezi altında doku ve kan örnekleri alındı; sonrasında sıçanlar dekapitasyon ile sakrifiye edildi. Serum amilaz, lipaz, IL-1 $\beta$ , IL-6, TNF-alfa, C-reaktif protein (CRP) düzeyleri incelendi. Pankreas doku örnekleri histopatolojik inceleme için ışık mikroskop altında incelendi.

**BULGULAR:** Akut pankreatit grubu (grup 2) ile kontrol grubu (grup 1) karşılaştırıldığında; serum amilaz, lipaz, IL-1 $\beta$ , IL-6, TNF-alfa, CRP düzeylerinin anlamlı derecede arttığı gözlemlendi (hepsi için p<0.05). Histopatolojik incelemede ödem (p<0,001) ve enflamasyon (p=0,007) skorlarında anlamlı farklılık saptandı. Düşük (grup 3) ve yüksek (grup 4) doz alfa-tokoferol grupları ile grup 2 karşılaştırıldığında; amilaz, lipaz, IL-1 $\beta$ , IL-6, TNF-alfa ve CRP parametreleri istatistiksel olarak anlamlı derecede düşük bulundu (hepsi için p<0.05). Grup 2, 3 ve 4'ün histopatolojik karşılaştırılmasında; grup 3 ve 4'te grup 2'ye göre ödem ve enflamasyon skorlarında azalma saptandı. Grup 4 ile grup 3 karşılaştırıldığında lipaz (p<0.01), IL-6 (p=0.038) ve TNF-alfa (p=0.002) değerlerinin anlamlı düzeyde düştüğü gözlemlendi; histopatolojik değerlendirmede ise anlamlı fark gözlemlenmedi.

**TARTIŞMA:** Alfa-tokoferol'ün, akut pankreatitte oluşan enflamasyonu ve pankreas hasarını azalttığı ve yüksek dozlarda daha etkili olduğu saptandı.

**Anahtar sözcükler:** Akut pankreatit; alfa-tokoferol; IL-6; TNF-alfa.

Ulus Travma Acil Cerrahi Derg 2021;27(6):605-612 doi: 10.14744/tjtes.2020.89054