

A different approach to simultaneously injured ulnar and radial arteries: Translocation of an arterial segment

Hamit Serdar Başbuğ, M.D., Macit Bitargil, M.D., Kanat Özışık, M.D.

Department of Cardiovascular Surgery, Kafkas University Faculty of Medicine, Kars-Turkey

ABSTRACT

Upper-extremity arterial injury is a common and serious condition that may lead to amputation if improperly treated. Ligation of the ulnar or radial artery is frequently performed by vascular surgeons as a method of treatment, which should be avoided, particularly if the radial and ulnar arteries were both injured. A different approach to reconstruction is described in the present report.

Keywords: Radial artery; ulnar artery; vascular injury.

INTRODUCTION

Upper-extremity vascular traumas comprise 30% of all peripheral vascular traumas, while vascular traumas comprise 1–3% of all injuries.^[1] Among vascular traumas, blunt traumas comprise 2–9%; penetrating traumas comprise the majority.^[2] Regarding the etiology of peripheral vascular injuries, traffic accidents, gunshot wounds, penetrating injuries, self-mutilation, and industrial injuries comprise most cases.^[3] Prompt diagnosis and treatment are essential to the reduction of further morbidity and mortality.^[4] In cases of upper-extremity vascular injury, hypovolemic shock, acute ischemia, and neurologic deficit may frequently be encountered as acute manifestations, potentially leading to permanent damage and amputation. Arteriovenous fistula and pseudoaneurism may develop as chronic complications.^[5] Distal pulses are palpable in 25% of brachial artery injuries and 50% of isolated radial or ulnar artery injuries, due to flow via collateral circulation.^[6] Thus, detailed inspection of the injury site and evaluation of arterial currents with Duplex ultrasound (DUS) are essential for precise diagnosis.^[5] Described in the present report is a different approach to surgical treatment in the rare circumstance that both the radial and ulnar arteries were injured.

CASE REPORT

A 62-year-old male was admitted to emergency services with a penetrating injury to his left forearm, sustained in an industrial accident in which a scroll saw cut to the left wrist caused massive trauma, with irregular laceration of the skin, muscles, and palmaris longus tendon. No neurologic motor deficit excluded median or radial nerve damage. Distal pulses, including those of the radial and ulnar arteries, were non-palpable, with no active hemorrhage due to vasospasm. DUS images revealed interrupted currents in both the radial and ulnar arteries, which are otherwise superiorly triphasic, at the site of trauma.

The patient was transferred to surgery with normal vital signs and normal complete blood count. Surgical exploration under regional anesthesia revealed a smooth cut of the ulnar artery, while the radial artery was torn, with a 2.5-cm segmental defect. An excessive portion of the ulnar artery was suitable for end-to-end anastomosis (Fig. 1a). However, the radial artery required the interposition of a conduit, as approximation was impossible due to long-segment loss. While preparing to harvest a piece of the saphenous vein to replace the defective portion of the radial artery, an excessive 2-cm portion of the ulnar artery was noted. This portion was resected and examined for intimal injury before being prepared as an autologous conduit for the deficient segment of the radial artery. The portion of the ulnar artery was then transferred to replace the deficient segment of the radial artery as an autologous conduit, and was successfully interposed and sutured end-to-end (Fig. 1b). The ends of the ulnar artery were then repaired, also with end-to-end anastomosis. Distal pulses became palpable in both arteries. In addition, DUS revealed triphasic patterns in both arterial segments distal to the reconstruction.

Address for correspondence: Hamit Serdar Başbuğ, M.D.
Kafkas Üniversitesi Tıp Fakültesi, Kalp ve Damar Cerrahisi Anabilim
Dalı, Paşaçayırı, 36100 Kars, Turkey
Tel: +90 474 - 225 11 49 E-mail: s_basbug@hotmail.com

Quick Response Code



Ulus Travma Acil Cerrahi Derg
2016;22(2):202–204
doi: 10.5505/tjtes.2015.87682

Copyright 2015
TJTES

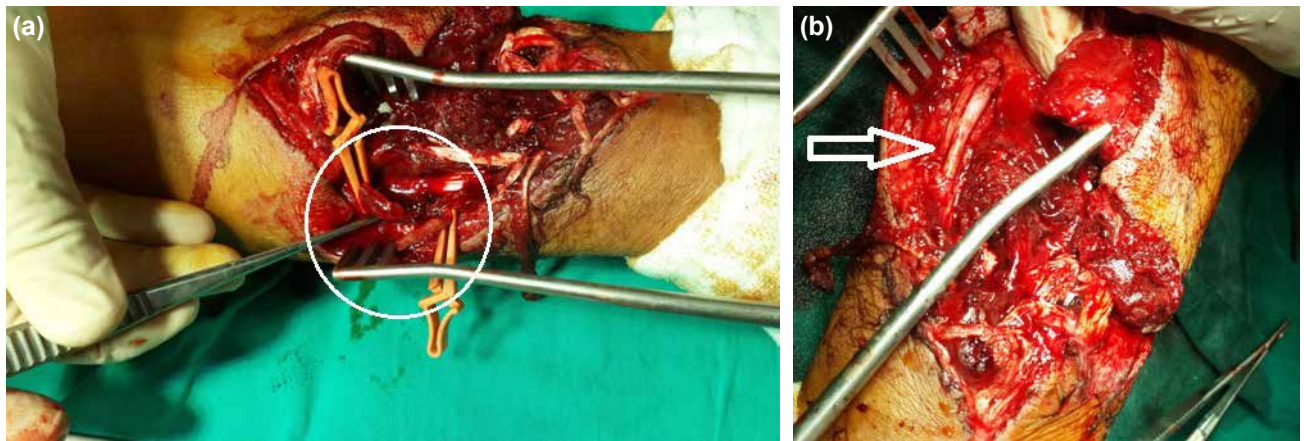


Figure 1. (a) Excess length of the clear-cut ulnar artery. (a) Repaired radial artery with ulnar segment interposition.

In anastomosis of both arterial repairs, 8–0 polypropylene sutures and 8-mm needles were used. Tendons and muscles were repaired with Vicryl sutures (Ethicon, Somerville, NJ, USA), and the skin was approximated as far as possible due to massive skin tissue loss. Surgery was concluded following complete revascularization and reconstitution of original circulation of the hand. First-generation cephalosporin (cefazolin sodium) and low-molecular-weight heparin (enoxaparin) were administered during the early postoperative period. The patient was discharged on the fifth postoperative day with patent radial and ulnar circulation verified by DUS imaging. No postoperative complication occurred. The patient was prescribed acetylsalicylic acid (100 mg/day) and scheduled for follow-up on the tenth day following discharge.

DISCUSSION

Early diagnosis and prompt surgical intervention in arterial injuries of the elbow play an important role in preventing serious complication. Detailed physical examination and DUS imaging are required for diagnosis. Palpation of the peripheral pulse may be specious, as the spasmed arteries often maintain pulsatility when interrupted. Moreover, when blood pressure is below 60 mmHg, no pulsation can be transmitted to the distal vasculature.^[7] Accordingly, massive arterial hemorrhage may not be apparent, as the cut end of the artery is typically spasmed. This may not exclude the possibility of vascular injury, and DUS imaging should be performed. DUS imaging has a specificity of 95% and a sensitivity of 99% in vascular injuries.^[8] If a further investigation is necessary, contrast-injected computerized tomography may be terminally performed.^[9]

Revascularization of the interrupted artery should be performed rapidly during the critical ischemic period (4 hours following the event for proximal injuries, 12 hours following the event for distal injuries).^[10] If this period is exceeded, amputation due to necrosis of the extremity should be taken into consideration.

Simultaneous interruption of both the radial and ulnar arteries occurs in only 4% of upper-extremity injuries; it is a very rare condition. Radial or ulnar artery damage occurs in 53% of upper-extremity injuries, damage to the brachial artery occurs in (36%), damage to the axillary artery in (5%) and damage to the subclavian artery in (4%).^[11] Surgical techniques for primary repair include ligation, approximation (end-to-end anastomosis), and primary suturing, while techniques for secondary repair include graft interposition (either autologous or prosthetic) and patch plasty.^[6]

Secondary repair to the radial artery and primary repair to the ulnar artery were performed in the present case. Under more typical circumstances, the radial artery could have been ligated or reconstructed using an autologous graft from the saphenous or cephalic veins, rather than that of an ulnar artery segment. However, harvesting the saphenous vein would have caused additional interventional trauma, and the cephalic vein was unsuitable, as it had also been injured. The clear-cut ulnar artery was elongated, possibly due to traumatic stripping from the surrounding tissue, and offered the necessary length. Fortunately, this excess segment revealed no intimal injury and could be used as an intact graft.

In conclusion, trauma to arteries in the elbow should be fully repaired, either by primary or secondary means, if possible. Ligation may be tolerated due to collateral circulation of the palmar arch, but should be reserved as a final option. Simultaneous radial and ulnar injuries are uncommon and require efficient, effective treatment.

Conflict of interest: None declared.

REFERENCES

1. Weaves FA, Hood DB, Yelkin AE. Vascular injuries of the extremities. In: Rutherford RB, editor. *Vascular surgery*. Philadelphia: Saunders Company; 2000. p. 862–72.
2. Taşdemir K, Oğuzkaya F, Kahraman C, Ceyran H, Emiroğulları Ö, Ö.

- Yasım A. Upper extremity artery injuries. *Turk Gogus Kalp Dama* 1997;5:218–22.
3. Tor F, Çakır H, Yıldız G, Özsöyler İ. Our Experience on Peripheral Vascular Trauma. *Çukurova Üniversitesi Tıp Fakültesi Dergisi* 2012;37:193–7.
 4. de Silva W, Ubayasiri R, Weerasinghe C, Wijeyaratne S. Challenges in the management of extremity vascular injuries: A wartime experience from a tertiary centre in Sri Lanka. *World J Emerg Surg* 2011;6:24.
 5. Tatar H, Öz BS, Şirin G, Akay HT, İyem H, Şarkışlalı K ve ark. Üst ekstremité damar yaralanmaları: cerrahi deneyimlerimiz. *Turkish J Vasc Surg* 2006;15:11–5.
 6. Lowrie AG, Berry MG, Kirkpatrick JJ, Lees VC, McGrouther DA. Arterial injuries at the elbow carry a high risk of muscle necrosis and warrant urgent revascularisation. *Ann R Coll Surg Engl* 2012;94:124–8. [CrossRef](#)
 7. Popescu GI, Lupescu O, Nagea M, Patru C. Diagnosis and treatment of limb fractures associated with acute peripheral ischemia. *Chirurgia (Bucur)* 2013;108:700–5.
 8. Gürbüz A, Ergüneş K, Yılık L, Özbek C, Karahan N, Bayatlı K ve ark. Travmatik üst ekstremité arteriyel yaralanmaları. *Turkish J Vasc Surg* 2006;15:39–44.
 9. Van Waes OJ, Navsaria PH, Verschuren RC, Vroon LC, Van Lieshout EM, Halm JA, et al. Management of penetrating injuries of the upper extremities. *Ulus Travma Acil Cerrahi Derg* 2013;19:405–10. [CrossRef](#)
 10. Topal AE, Eren MN. Gradually increasing predominance of self-mutilation in upper extremity arterial injuries: less morbidity but with high threat to society. *Ulus Travma Acil Cerrahi Derg* 2010;16:527–31.
 11. Ünü Y, Vural U, Özyazıcıoğlu A, Ceviz M, Karapolat S, Koçak H. Upper Extremity Vascular Injuries (The Evaluation of 98 Cases). *Turk Gogus Kalp Damar Cer Derg* 1998;6:318–22.

OLGU SUNUMU - ÖZET

Birlikte yaralanmış ulnar ve radial arter onarımına farklı bir yaklaşım: Arteriyel segment translokasyonu

Dr. Hamit Serdar Başbuğ, Dr. Macit Bitargil, Dr. Kanat Özışık

Kafkas Üniversitesi Tıp Fakültesi, Kalp ve Damar Cerrahisi Anabilim Dalı, Kars

Üst ekstremité arter yaralanmaları, yaygın görülen ve ciddi bir durumdur ve eğer doğru tedavi edilmezse ekstremitéyi amputasyona kadar götürebilir. Radial ya da ulnar arterin bağlanması, vasküler cerahlar tarafından sıkça uygulanan bir tedavi metotudur. Eğer radial ve ulnar arterler her ikisi birden yaralanmışsa, bundan özellikle kaçınmak gerekir. Bu olguda, birlikte yaralanmış radial ve ulnar arterin taminine yönelik farklı bir yaklaşım sunuldu. **Anahtar sözcükler:** Radial arter; ulnar arter; vasküler yaralanma.

Ulus Travma Acil Cerrahi Derg 2016;22(2):202–204 doi: 10.5505/tjtes.2015.87682