



Surgical treatment of a case with rapidly growing mass lesion after trauma: on the left forearm arteriovenous malformation

Travma sonrası hızlı büyüyen kitlesi olan bir olgunun cerrahi tedavisi:
Sol ön kolda arteriyovenöz malformasyon

Süreyya TALAY,¹ Bilgehan ERKUT,¹ Mehmet Eşref KABALAR²

In this case, we report a vascular malformation with high flow pattern complicated with trauma. A postoperative histopathology examination confirmed an arterio-venous malformation in specimens of surgical excision material. In our opinion, posttraumatic progression of a vascular malformation is an emergency and requires an urgent evaluation with surgery at any localization of the body.

Key Words: Arteriovenous malformation; trauma; surgical excision.

Biz bu olguda, travma sonrası yüksek flow paternine sahip bir vasküler malformasyon olgusunu sunduk. Cerrahi sonrası hastada histopatolojik olarak arteriyovenöz malformasyon tanısı kondu. Bizim düşüncemize göre vücudun herhangi bir yerinde travma sonrası gelişen progresif olarak gelişme gösteren vasküler malformasyonlarda acil ve hızlı bir cerrahi uygulanması gereklidir.

Anahtar Sözcükler: Arteriyovenöz malformasyon; travma; cerrahi eksizyon.

The vasculopathies may involve arteries, veins or lymphatic vessels, or a combination in the same patient in one or multiple localizations. Classifications are based mainly on the morphological structure of the lesions, cellular biology, hemodynamic features, and diagnostic evaluations. Based on a recent classification described by Mulliken, vascular anomalies are divided into two main areas, as hemangioma and other malformations.^[1,2] Malformations may be with low-flow pattern, high-flow pattern and complex-combined syndromes. Surgical evaluation and indication vary with the type and abnormality of the situation.

CASE REPORT

We report a case of progressively growing post-traumatic arteriovenous malformation on the left forearm. A 29-year-old male patient with a history of rap-

idly growing and painful bulky lesion on the posterior left forearm admitted to the emergency department. He described a stable mass lesion at the same localization presenting from his early childhood. The patient, who was a police officer, suffered a blunt trauma at the site of the mass lesion during an official criminal investigation. Following the blunt trauma, the mass size doubled in diameter in a few hours. Results of the physical examination were within normal limits excluding the growing pulsatile bulky mass lesion on the extensor side of the left forearm. There was no active bleeding. The lesion was sensitive and warm with palpation and measured 3x4 cm on observation (Fig. 1a). An emergent Doppler ultrasonography revealed normal compression response and normal diameters for the left arm veins. Artery diameters and blood flow patterns were in normal ranges. There was no evi-




Fig. 1. (a) Image of the dermal bulky lesion. (b) The preoperative ultrasonography image.

dence of intravascular thrombosis. On the forearm of the patient at the examined area posterolaterally, there was an arteriovenous malformation between the radial artery and cephalic vein measuring 4x5 cm (Fig. 1b). There were no images of active extravascular leakage of blood from the arteriovenous malformation. All arterial pulses were detectable. Afterwards, the patient was operated under general anesthesia. Surgical skin incision was made over and along the lesion. Following the subcutaneous tissue dissection, surgical exposure reached the mass lesion of the arteriovenous malformation. The lesion was observed to be approximately 3x4x4 cm, immobile and adherent to surrounding tissue. Vascular structure arose from the radial artery distally and drained to the cephalic vein after a plexus of vessels. Total mass excision was achieved with multiple ligations of the collateral vascularities and careful dissection. The operation was carried out free of any major vascular or neurological injuries or complications. Closure of the anatomical layers was carried out safely. We observed no damage to adjacent vital structures, and the resection could be completed. Early postoperative clinical follow-up was uneventful. The patient was discharged from the hospital on postoperative day 5. A pathological investigation of the specimen from the excision material was described as arteriovenous malformation by the pathology department (Fig. 2).

DISCUSSION

Vascular abnormalities are listed in two different groups according to Mulliken, as hemangioma and other malformations. Hemangioma is a congenital abnormality of endothelial hyperplasia with rapid cellular expression, which usually disappears following birth. These are the most common tumors of the neonatal period, known as birthmarks. Most of the cases, at a rate of 70% of lesions, vanish in seven years.^[1-3] A distinctive diagnosis between hemangioma and vascular malformation is mandatory. The findings for hemangioma are: no presentation during the early days of birth, tendency to grow rapidly, female to male ratio of 4 to 1, accumulation of endothelial and mast cells dominantly, thrombocytopenia in severe cases like

Kasabach-Merritt syndrome, and measurable margins.^[4,5] The group of other malformations including arteriovenous malformations usually exist at birth. Malformations grow slowly. Their growth is usually triggered by trauma, sepsis or hormonal situations. Histopathological features usually include normal endothelial cells, normal rate of mast cells and a thin layer of basal membrane.

Arteriovenous malformations tend to present a series of typical features, such as pulsation, trill, often murmurs, and angiographic proof of feeding artery or arteries.^[6] In our case, the expanding lesion was sensitive to touch and pulsation with trill was observed. A mild murmur was heard on auscultation. Surgery is not required in most cases. Classic surgical indications for a vascular arteriovenous malformation are described as ulcers resistant to medical therapy, extremity ischemia and congestive heart failure. Alternative treatment to surgery includes catheters or medical embolizations and laser administrations.^[7,8]

A post-traumatic case requires a rapid decision for surgery. Lee et al.^[9] reported a series of 797 patients treated with combined embolotherapy, sclerotherapy and surgical procedures to manage arteriovenous mal-

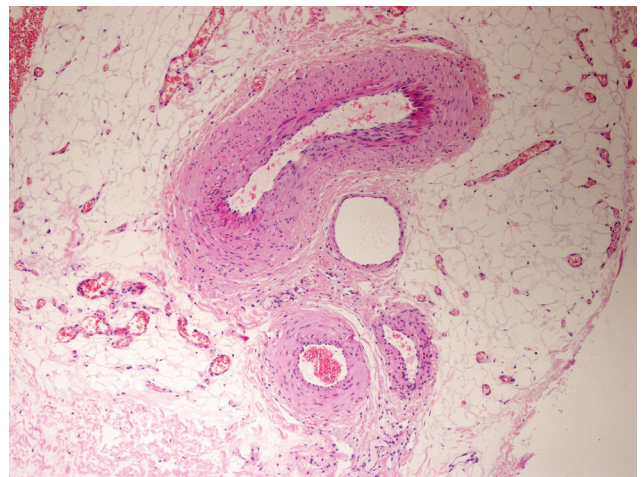


Fig. 2. Histopathological investigations of the excision material.

(Color figure can be viewed in the online issue, which is available at www.tjtes.org).

formations. They reported their results as excellent, and there was no evidence of recurrence within 24 months. Four major complications occurred, including facial nerve palsy, pulmonary embolism, deep vein thrombosis, and massive necrosis of ear cartilage in the surgery group.

In conclusion, a trauma may be the cause of a vascular emergency especially for a case involving an arteriovenous malformation. Surgical resection may be difficult, with the potential for exsanguinations, hemorrhage and damage to surrounding structures. Despite these factors, we strongly advocate that, in emergency cases with active bleeding or acute ischemia, a Doppler ultrasonography is sufficient for the decision to operate.

REFERENCES

1. Mulliken JB, Glowacki J. Hemangiomas and vascular malformations in infants and children: a classification based on endothelial characteristics. *Plast Reconstr Surg* 1982;69:412-22.
2. Mulliken JB. Cutaneous vascular anomalies. *Semin Vasc Surg* 1993;6:204-18.
3. Qing Y, Cen Y, Xu X, Duan W, Liu Y. Surgical treatment of hemangioma and vascular malformation in body surface. [Article in Chinese] *Zhongguo Xiu Fu Chong Jian Wai Ke Za Zhi* 2009;23:325-7. [Abstract]
4. Low DW. Hemangiomas and vascular malformations. *Semin Pediatr Surg* 1994;3:40-61.
5. Enjolras O, Mulliken JB. Vascular tumors and vascular malformations (new issues). *Adv Dermatol* 1997;13:375-423.
6. Coffin CM, Dehner LP, O'Shea PA. Vascular tumors. In: *Pediatric soft tissue tumors: a clinical, pathological, and therapeutic approach*. Baltimore, MD: Lippincott, Williams & Wilkins; 1997. p. 40-79.
7. Lee BB, Kim DI, Huh S, Kim HH, Choo IW, Byun HS, et al. New experiences with absolute ethanol sclerotherapy in the management of a complex form of congenital venous malformation. *J Vasc Surg* 2001;33:764-72.
8. Duran E. Kalp ve damar cerrahisi. İstanbul: Çapa Tıp Kitap Evi; 2004.
9. Lee BB, Do YS, Yakes W, Kim DI, Mattassi R, Hyon WS. Management of arteriovenous malformations: a multidisciplinary approach. *J Vasc Surg* 2004;39:590-600.