

ESIN and K-wire fixation have similar results in pediatric both-bone diaphyseal forearm fractures

Namık Şahin, M.D.,¹ Yavuz Akalın, M.D.,² Oğuz Türker, M.D.,² Güven Özkaya, M.D.³

¹Department of Orthopaedics and Traumatology, Medical Sciences University, Konya Training and Research Hospital, Konya-Turkey

²Department of Orthopaedics and Traumatology, Medical Sciences University, Bursa Yüksek İhtisas Health Application and Research Center, Bursa-Turkey

³Department of Biostatistics, Uludağ University Faculty of Medicine, Bursa-Turkey

ABSTRACT

BACKGROUND: The purpose of this study was to compare short-term radiographic and clinical results of pediatric both-bone diaphyseal forearm fractures treated with intramedullary nail fixation using titanium nails or K-wires.

METHODS: This was a prospective comparative trial. In total, 43 patients with both-bone open or closed forearm fractures who underwent surgical treatment with intramedullary fixation were randomly classified into two groups. Three patients did not return for the follow-up and were excluded from the study. Twenty of the 40 patients were assigned to the elastic stable intramedullary nail group and 20 were assigned to the K-wire group. Demographic data suggested no difference between the two groups except for the side of injury. Perioperative data and radiological and clinical outcomes were evaluated.

RESULTS: The cohort comprised 5 girls and 35 boys whose mean age was 11.60 ± 2.69 years. Except the proportion of patients who were conservatively followed up preoperatively, all perioperative data were similar between the groups. Radiographic and functional results were similar. There were two delayed unions; one pin track infection and one re-fracture.

CONCLUSION: Intramedullary fixation of forearm fractures in children with titanium nail or K-wire does not affect radiological and clinical results. Both elastic stable intramedullary nail and K-wire fixation were effective in stabilizing pediatric diaphyseal forearm fractures.

Keywords: Forearm; fracture; intramedullary nail; pediatrics.

INTRODUCTION

Forearm fractures are generally considered to be the most common injuries in children. Closed reduction and cast application are the gold standard treatment for minimally displaced and stable forearm fractures in the pediatric group.^[1-3] Most patients aged <8 years will remodel even bayonet apposition and angular deformity of at least 10° – 15° , but particularly in children older than 12 years of age, unstable diaphyseal fractures of the forearm treated conservatively remodel poorly

and may result in malunion.^[2,4] Malunion of the forearm could cause loss of motion, particularly in pronation and supination and lead to unsatisfactory functional outcomes.^[5,6] Therefore, particularly in children with irreducible and unstable forearm fractures, the rate of those who chose surgical treatment for pediatric forearm fractures has increased in the last decade.^[7,8] A nationwide study conducted in Finland showed that the annual incidence of operatively treated forearm fractures increased by 62% between 1997 and 2006.^[7]

Accepted surgical indications for pediatric both-bone diaphyseal forearm fractures include irreducible, unstable, high-energy, or open fractures.^[9] Intramedullary (IM) fixation is currently the commonly preferred technique for diaphyseal forearm fracture treatment in children.^[9,10] The other approved and preferred procedures are plate and screw fixation, a combination of plate-screw and IM fixation, and single bone osteosynthesis.^[11-13] Although there are some studies, the type of implant to be preferred for IM nailing is not well studied. The aim of this study was to compare functional and radiographic outcomes of elastic stable IM nailing (ESIN) and

Address for correspondence: Namık Şahin, M.D.

Sağlık Bilimleri Üniversitesi, Konya Eğitim ve Araştırma Hastanesi, Ortopedi ve Travmatoloji Anabilim Dalı, Konya, Turkey
Tel: +90 332 - 221 00 00 E-mail: sahinnamik@yahoo.com

Submitted: 08.07.2016
Accepted: 12.01.2017

Ulus Travma Acil Cerrahi Derg
2017;23(5):415–420
doi: 10.5505/tjtes.2017.85891



Copyright 2017
TJTES

K-wire fixation for treating both-bone diaphyseal forearm fractures in children.

MATERIALS AND METHODS

This was a prospective, randomized, and comparative trial. Between April 2014 and May 2015, 43 patients with both-bone open or closed forearm fracture who underwent surgical treatment with IM fixation were randomly allocated into two groups. Three patients did not return for the follow-up and were excluded from the study. Twenty of the remaining 40 patients were assigned to the ESIN group (ESIN fixation for both the radius and ulna) and 20 were assigned to the K-wire group (K-wire fixation for both the radius and ulna). The inclusion criteria were (1) patients aged 8–16 years, (2) both-bone forearm fractures be included in 22-D4 and 22-D5 according to the AO Pediatric Comprehensive Classification of Long Bone Fractures,^[14] (3) failure to obtain or maintain adequate closed reduction^[15] ($>10^\circ$ angulation in the AP or lateral plane, any rotation of both bones, and translation of bone fragments $>$ half of the bone diameter), (4) no previous forearm injuries, (5) no pathologic fractures, and (6) no Gustilo–Anderson type 3B or 3C open fractures.^[16] Informed consent was obtained from all parents and from all children aged ≥ 12 years. Approval for this investigation was obtained from the local ethical committee.

Demographic data suggested no difference between the two groups except for the side of injury (Table 1). Perioperative

data included duration from injury to surgery, duration of surgery, type of reduction (open or closed), duration of immobilization postoperatively, and duration from primary surgery to implant removal.

Surgical Technique

All patients were operated under general anesthesia. The standard operative technique as described by Lascombes et al.^[17] was used in all cases. Closed reduction was first tried under fluoroscopy. After closed or open reduction, the radial fracture was fixed retrograde using a titanium elastic nail in the ESIN group and using a K-wire in the K-wire group and advanced through a drill hole just proximal to the distal radial epiphysis. The ulnar fracture was fixed IM with a lateral approach through the posterolateral part of the olecranon. Titanium nails have pre-bent tips. The tip of the K-wires was bent by the surgeon with an angulation of 20° – 30° . All titanium nails and K-wires curved to approximately 20° at the fracture level. Implants were chosen with a diameter of 2 mm for those aged ≤ 10 years and with a diameter of 2.5 mm for those older. A 3.2-mm drill size was chosen for all children (Figs. 1 and 2).

Both groups followed the same postoperative procedure, which was above elbow cast immobilization until callus formation was observed on plain radiographs or maximum at 6 weeks. Sutures were removed 14 days postoperatively. All patients returned for evaluation after postoperative 1st, 2nd,

Table 1. Patients demographics and fracture characteristics

	ESIN Group (n=20)	K-wire Group (n=20)	p
Age ¹ (years)	12.05 (± 2.52)	11.15 (± 2.83)	0.324
Height ¹ (cm)	139.8 (± 11.88)	135.25 (± 14.11)	0.277
Weight ¹ (kg)	40.9 (± 8.66)	36.5 (± 9.13)	0.126
Sex ²			0.342
Boy	19 (95%)	16 (80%)	
Girl	1 (5%)	4 (20%)	
Side of injury ²			0.011
Right	14 (70%)	6 (30%)	
Left	6 (30%)	14 (70%)	
Mechanism of injury ²			0.407
Simple fall	15 (75%)	18 (90%)	
High-energy trauma	5 (25%)	2 (10%)	
Fracture classification ²			0.490
22D4	13 (65%)	15 (75%)	
22D5	7 (35%)	5 (25%)	
Conservative treatment history ²			0.022
No	16 (80%)	9 (45%)	
Yes	4 (20%)	11 (55%)	

¹Data are presented as (mean \pm SD). ²Data are presented as frequency (%). SD: Standard deviation.

3rd, 4th and 6th weeks, and 3rd, 6th and 12th months, respectively. Wrist and elbow mobility exercises were initiated 3–4 weeks postoperatively.

Radiologic evaluation was performed in the 3rd and 6th weeks and in the 3rd, 6th, and 12th months. Fracture union was defined by bridging callous across at least three cortices of the bone on anteroposterior and lateral radiographic views based on the description by Schmittenebecher et al.,^[18] which defined fracture union beyond 3 months as “delayed union” and that beyond 6 months as “nonunion.”

Functional outcomes were evaluated at the end of the postoperative 1st year according to the criteria developed by Price et al.^[2] The pronation and supination ranges of the fractured forearm were measured using a conventional goniometer.^[5] The outcomes were graded as follows: excellent, if no complaints with strenuous physical activity or a loss of pronation-supination of <10°; good, if mild complaints with strenuous activity and/or 11°–30° loss of forearm rotation; fair, if subjective complaints during daily activities and/or 31°–90° loss of forearm rotation; and all other results were considered to be poor. The loss of forearm motion on the affected side was compared with that on the unaffected forearm.

Complications were classified as “minor” (recover with observation or minimal intervention) and “major” (requiring a return to the operating room or resulting in significant long-term sequelae).

Statistics

All statistical analyses were performed using IBM SPSS ver. 23.0. The Shapiro–Wilk test was used to test normality. Continuous variables were compared using Mann–Whitney U test and t-test. Categorical variables were compared using Pearson’s chi-squared test, Fisher’s exact test, and Fisher–Freeman–Halton test. A p-value of <0.05 was considered to be significant.

RESULTS

The cohort comprised 5 girls and 35 boys. The mean age was 11.60±2.69 years. The mean height was 137.5±13.08 cm and the mean weight was 38.7±9.06 kg. Except the proportion of patients who were conservatively followed preoperatively, all perioperative data were similar between the groups (Table 2). Furthermore, both radiographic and functional results were similar (Table 3).

There were three open fractures in total. Two of them were Gustilo–Anderson type 2 open fractures in the ESIN group and one was type 1 in the K-wire group (p>0.05). There were two patients with delayed union, and they had open fractures (each in both groups). One child in the ESIN group developed pin-tract infection in the radius because of skin irritation. This

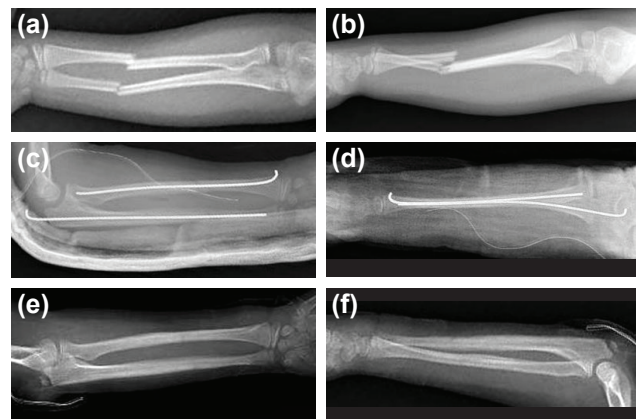


Figure 1. (a) Anteroposterior and (b) lateral radiographs showing displaced and angulated diaphyseal both-bone right forearm fractures in an 8-year-old girl. (c) Early anteroposterior and (d) lateral radiographs showing IM K-wire fixation of ulna and radial fractures in the same patient. (e) Anteroposterior and (f) lateral radiographs of the forearm after hardware removal.

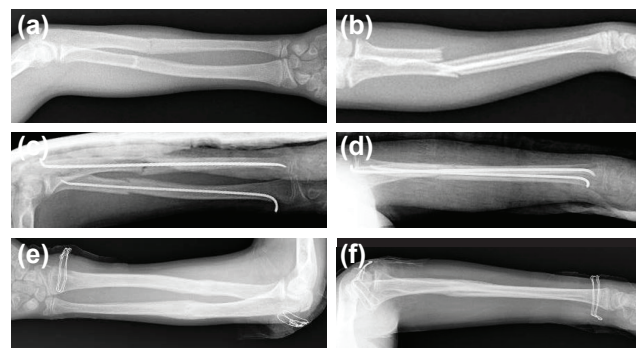


Figure 2. (a) Anteroposterior and (b) lateral radiographs showing displaced and angulated diaphyseal both-bone right forearm fractures in a 13-year-old boy. (c) Early anteroposterior and (d) lateral radiographs showing IM titanium nail fixation of ulna and radial fractures in the same patient. (e) Anteroposterior and (f) lateral radiographs of the forearm after hardware removal.

was successfully treated with oral antibiotics and wound care. In the K-wire group, one patient had a re-fracture 4 months postoperatively following the removal of the pins. This was also successfully treated with open reduction and IM fixation.

DISCUSSION

The main finding of our study was that IM fixation of forearm fractures with ESIN or K-wire in children does not affect radiological and clinical results. There was no significant difference in the union time of fractures, rate of postoperative complications, range of motion of the elbow and wrist, and postoperative symptoms. When all patients were evaluated together, IM fixation of forearm fractures in children has successful results and lower complication rate than those reported in other studies.^[1,10,19]

Although closed reduction and cast immobilization remains the gold standard treatment for minimally displaced and

Table 2. Perioperative data

	ESIN Group (n=20)	K-wire Group (n=20)	p
Duration from injury to surgery (days) ¹	4 (1–15)	6.5 (1–22)	0.405
Duration of surgery (min) ¹	43.5 (30–65)	45 (30–65)	0.283
Type of reduction (Radius) ²			0.527
Closed	11 (55%)	9 (45%)	
Open	9 (45%)	11 (55%)	
Type of reduction (Ulna) ²			
Closed	15 (75%)	15 (75%)	
Open	5 (25%)	5 (25%)	1.000
Implant removal time (weeks) ¹	16 (10–52)	16 (10–26)	0.753
Duration of immobilization postoperatively (weeks) ¹	4 (3–6)	4 (3–6)	0.839

¹Data are presented as median (min-max). ²Data are presented as frequency (%).

Table 3. Radiologic and clinical results

	ESIN Group (n=20)	K-wire Group (n=20)	p
Delayed union ²	1 (5%)	1 (5%)	1.000
Union time (weeks) ¹	6.5 (5–24)	6 (5–13)	0.383
Clinical result ²			0.695
Excellent	14 (70%)	17 (85%)	
Good	5 (25%)	2 (10%)	
Fair	1 (5%)	1 (5%)	
Poor	–	–	

¹Data are presented as median (min-max). ²Data are presented as frequency (%).

stable pediatric forearm fractures,^[1,2] the rate of operative treatment of pediatric forearm fractures has substantially increased in the last decade.^[7,8] However, the optimal method for surgical fixation of pediatric forearm fractures is still controversial. Well-established surgical options include IM nailing,^[1,10,20] open reduction and internal fixation with plates and screws, and hybrid fixation.^[10,12,21] In a systematic review, Patel et al.^[10] reported similar functional and radiographic outcomes and complications with IM nails and plates used in the treatment of both-bone diaphyseal forearm fractures in children. But they stated that IM nailing was an effective treatment option for these fractures with shorter operating times, improved cosmesis, and easier hardware removal. In another study, Feng et al.^[12] compared clinical outcomes of hybrid fixation using ESIN for radius and plate-screw fixation for the ulna with dual ESIN fixation for both-bone forearm fractures in children. They reported that hybrid fixation has some advantages in terms of the times of fluoroscopy during surgery, duration of immobilization postoperatively, delayed union of the ulna, and the average time of bone union.

Although IM nailing is well-accepted and generally preferred technique for diaphyseal forearm fracture treatment in young children, the type of implant was not well-established. Several advantages of ESIN fixation have been described for pediatric both-bone forearm fractures.^[10,22] Antabak et al.^[22] reported that ESIN osteosynthesis for diaphyseal forearm fractures remains a valid technique with good functional results. However, some complications of ESIN, including delayed union and nonunion of the ulna, infection and skin irritation, implant migration or failure, loss of reduction, nerve and tendon injury, and compartment syndrome, have been reported.^[1,12,22] Yung et al.^[23] also concluded that percutaneous IM K-wiring with immobilization in a cast is an easy, minimally invasive, and safe method with a good functional outcome. He stated that only 5 of 57 patients had angulation from 10° to 15° and none had nonunion, premature epiphyseal closure, or deep infection. Calder et al.^[24] assessed the outcome of K-wires or ESIN as the method for fracture stabilization in such diaphyseal forearm fractures and demonstrated no difference in outcome between K-wires and ESIN as our study, although the nails do offer some theoretical advantages.

Despite theoretical advantages of ESIN fixation, like more elastic properties of titanium nails than K-wires achieving better three-point fixation and stabilization,^[17] it is unclear whether this property provides some clinical advantages in both-bone forearm fractures. In this study, both K-wires and titanium nails were less bent than in the original technique, regardless of whether they provided three-point fixation or not. But because of this modification, all patients underwent plaster immobilization to ensure rotational stability. The advantages of three-point fixation may be rotational stability in addition to providing radioulnar spacing, and some patients do not need plaster immobilization. On the other hand, there are known cost implications between the two kind of implants. K-wires are less expensive at 12 TL per wire compared with 322 TL per nails for titanium nails. This price difference could be important, particularly in developing countries.

Removal of implants remains a controversial issue. Removing plates is usually harder than removing nails. When removing metalwork, the risk of re-fracture must be considered. In some studies, nails were routinely removed in all patients^[19,25] and in others, none or some were removed.^[1] Furthermore, re-fractures were reported in both ESIN and plating groups. Implant removal times were also variable. Although early removal of implants may result in re-fractures, delayed removal may reveal surgical difficulties. We removed all implants postoperatively at a relatively early period and re-fracture occurred in only one patient.

Although the children were blinded for the implant, the orthopedic surgeon was not blinded during clinical follow-up, which might have influenced clinical measurements. Obviously, blinding of the surgeon was impossible because of radiologic evidence of the implant type. Postoperative immobilization was used in all patients in both groups. But this study did not evaluate whether all of the patients needed immobilization or not. In this study, we treated patients aged between 8 and 16 years with IM fixation. However, particularly in older adolescents, there may possibly be a threshold in terms of age, which would make plate and screw fixation more effective. This could be determined in a future study.

Conclusion

In conclusion, in our study, fewer complications were observed in pediatric both-bone forearm fractures with IM nailing compared with the results of other studies. Both ESIN and K-wire fixation were effective in stabilizing pediatric diaphyseal forearm fractures. There was no significant difference between the two techniques in terms of union time of fractures, rate of postoperative complications, range of motion of the elbow, and postoperative symptoms.

Conflict of interest: None declared.

REFERENCES

1. Flynn JM, Jones KJ, Garner MR, Goebel J. Eleven years experience in the operative management of pediatric forearm fractures. *J Pediatr Orthop* 2010;30:313–9. [\[CrossRef\]](#)
2. Price CT, Scott DS, Kurzner ME, Flynn JC. Malunited forearm fractures in children. *J Pediatr Orthop* 1990;10:705–12. [\[CrossRef\]](#)
3. Seyfettinoglu F, Duygun F, Kovalak E, Ersan O, Ates B, Ates Y. Assessment of surgical and conservative treatment of forearm fractures: results in juveniles. *Ulus Travma Acil Cerrahi Derg* 2009;15:371–6.
4. Kay S, Smith C, Oppenheim WL. Both-bone midshaft forearm fractures in children. *J Pediatr Orthop* 1986;6:306–10. [\[CrossRef\]](#)
5. Colaris J, Reijman M, Allema JH, de Vries M, Biter U, Bloem R, et al. Angular malalignment as cause of limitation of forearm rotation: an analysis of prospectively collected data of both-bone forearm fractures in children. *Injury* 2014;45:955–9. [\[CrossRef\]](#)
6. Daruwalla JS. A study of radioulnar movements following fractures of the forearm in children. *Clin Orthop Relat Res* 1979;114–20. [\[CrossRef\]](#)
7. Helenius I, Lamberg TS, Kaariainen S, Impinen A, Pakarinen MP. Operative treatment of fractures in children is increasing. A population-based study from Finland. *J Bone Joint Surg Am* 2009;91:2612–6. [\[CrossRef\]](#)
8. Sinikumpu JJ, Lautamo A, Pokka T, Serlo W. The increasing incidence of paediatric diaphyseal both-bone forearm fractures and their internal fixation during the last decade. *Injury* 2012;43:362–6. [\[CrossRef\]](#)
9. Bae DS. Pediatric distal radius and forearm fractures. *J Hand Surg Am* 2008;33:1911–23. [\[CrossRef\]](#)
10. Patel A, Li L, Anand A. Systematic review: functional outcomes and complications of intramedullary nailing versus plate fixation for both-bone diaphyseal forearm fractures in children. *Injury* 2014;45:1135–43. [\[CrossRef\]](#)
11. Baldwin K, Morrison MJ, Tomlinson LA, Ramirez R, Flynn JM. Both bone forearm fractures in children and adolescents, which fixation strategy is superior - plates or nails? A systematic review and meta-analysis of observational studies. *J Orthop Trauma* 2014;28:8–14. [\[CrossRef\]](#)
12. Feng Y, Shui X, Wang J, Cai L, Wang G, Hong J. Comparison of hybrid fixation versus dual intramedullary nailing fixation for forearm fractures in older children: Case-control study. *Int J Surg* 2016;30:7–12.
13. Truntzer J, Vopat ML, Kane PM, Christino MA, Katarincic J, Vopat BG. Forearm diaphyseal fractures in the adolescent population: treatment and management. *Eur J Orthop Surg Traumatol* 2015;25:201–9. [\[CrossRef\]](#)
14. Slongo TF, Audige L. Fracture and dislocation classification compendium for children: the AO pediatric comprehensive classification of long bone fractures (PCCF). *J Orthop Trauma* 2007;21(10 Suppl):S135–60.
15. Colaris JW, Allema JH, Reijman M, de Vries MR, Ulas Biter L, Bloem RM, et al. Which factors affect limitation of pronation/supination after forearm fractures in children? A prospective multicentre study. *Injury* 2014;45:696–700. [\[CrossRef\]](#)
16. Gustilo RB, Simpson L, Nixon R, Ruiz A, Indeck W. Analysis of 511 open fractures. *Clin Orthop Relat Res* 1969;66:148–54. [\[CrossRef\]](#)
17. Lascombes P, Haumont T, Journeau P. Use and abuse of flexible intramedullary nailing in children and adolescents. *J Pediatr Orthop* 2006;26:827–34. [\[CrossRef\]](#)
18. Schmittenbecher PP, Fitze G, Godeke J, Kraus R, Schneidmuller D. Delayed healing of forearm shaft fractures in children after intramedullary nailing. *J Pediatr Orthop* 2008;28:303–6. [\[CrossRef\]](#)
19. Fernandez FF, Egenolf M, Carsten C, Holz F, Schneider S, Wentzensen A. Unstable diaphyseal fractures of both bones of the forearm in children: plate fixation versus intramedullary nailing. *Injury* 2005;36:1210–6.
20. Luhmann SJ, Gordon JE, Schoenecker PL. Intramedullary fixation of

- unstable both-bone forearm fractures in children. J Pediatr Orthop 1998;18:451–6. [CrossRef]
21. Wyrsch B, Mencia GA, Green NE. Open reduction and internal fixation of pediatric forearm fractures. J Pediatr Orthop 1996;16:644–50.
22. Antabak A, Luetic T, Ivo S, Karlo R, Cavar S, Bogovic M, et al. Treatment outcomes of both-bone diaphyseal paediatric forearm fractures. Injury 2013;44 Suppl 3:11–5. [CrossRef]
23. Yung SH, Lam CY, Choi KY, Ng KW, Maffulli N, Cheng JC. Percutaneous intramedullary Kirschner wiring for displaced diaphyseal forearm fractures in children. J Bone Joint Surg Br 1998;80:91–4. [CrossRef]
24. Calder PR, Achan P, Barry M. Diaphyseal forearm fractures in children treated with intramedullary fixation: outcome of K-wire versus elastic stable intramedullary nail. Injury 2003;34:278–82. [CrossRef]
25. Teoh KH, Chee YH, Shortt N, Wilkinson G, Porter DE. An age- and sex-matched comparative study on both-bone diaphyseal paediatric forearm fracture. J Child Orthop 2009;3:367–73. [CrossRef]

ORİJİNAL ÇALIŞMA - ÖZET

Çocuk önkol çift kırıklarında ESIN ve K-teli tespiti benzer sonuçlara sahiptir

Dr. Namık Şahin,¹ Dr. Yavuz Akalın,² Dr. Oğuz Türker,² Dr. Güven Özkaya³

¹Sağlık Bilimleri Üniversitesi, Konya Eğitim ve Araştırma Hastanesi, Ortopedi ve Travmatoloji Anabilim Dalı, Konya

²Sağlık Bilimleri Üniversitesi, Bursa Yüksek İhtisas Sağlık Uygulama ve Araştırma Merkezi, Ortopedi ve Travmatoloji Anabilim Dalı, Bursa

³Uludağ Üniversitesi Tıp Fakültesi, Biyoistatistik Anabilim Dalı, Bursa

AMAÇ: Bu çalışmanın amacı titanium çivi ya da K-telleri kullanılarak intramedüller çivileme ile tedavi edilen çocuk önkol kırıklarının kısa dönem radyolojik ve klinik sonuçlarının karşılaştırılmasıdır.

GEREÇ VE YÖNTEM: Bu çalışma ileriye yönelik karşılaştırmalıdır. İntramedüller tespit ile cerrahi olarak tedavi edilen açık ya da kapalı önkol çift kırıklı 43 hasta randomize olarak iki gruba ayrıldı. Takibi yapılamayan üç hasta çalışmadan çıkarıldı. Kırk hastadan 20'si elastik stabil intramedüller çivi grubuna ve 20'si de K-teli grubuna dahil edildi. Demografik veriler yaralanmanın tarafı dışında benzerdi. Perioperatif veriler, radyolojik ve klinik sonuçlar değerlendirildi.

BULGULAR: Kohort yaş ortalaması 11.60 (±2.69) olan 5 kız ve 35 erkek çocuktan oluşuyordu. Ameliyattan önce konservatif olarak takip edilen hastaların oranı dışında tüm perioperatif veriler gruplar arasında benzerdi. Radyolojik ve klinik sonuçlar da benzer idi. Toplamda iki kaynama gecikmesi, bir tel dibi enfeksiyonu ve bir refraktür gözlemlendi.

TARTIŞMA: Çocuklarda önkol kırıklarının titanium çivi ya da K-teli ile intramedüller tespitinin radyolojik ve klinik sonuçları benzerdir. Hem elastik stabil intramedüller çivi hem de K-teli tespiti pediatrik diafizal önkol kırıklarının tedavisinde etkindir.

Anahtar sözcükler: Çocuk; intramedüller çivi; kırık; önkol.

Ulus Travma Acil Cerrahi Derg 2017;23(5):415–420 doi: 10.5505/tjtes.2017.85891