

Spiked railing penetration that causes injuries in the upper extremities of children

Egemen Ayhan, M.D.,¹ Kadir Çevik, M.D.,² Melih Bağır, M.D.,³ Mehmet Çolak, M.D.,⁴
Metin Manouchehr Eskandari, M.D.⁴

¹Department of Orthopaedics and Traumatology & Hand Surgery, Dışkapı Yıldırım Beyazıt Training and Research Hospital, Ankara-Turkey

²Department of Orthopaedics and Traumatology, Mersin University Faculty of Medicine, Mersin-Turkey

³Department of Orthopaedics and Traumatology & Division of Hand Surgery, Çukurova University Faculty of Medicine, Adana-Turkey

⁴Department of Orthopaedics and Traumatology & Hand Surgery, Mersin University Faculty of Medicine, Mersin-Turkey

ABSTRACT

BACKGROUND: Children have a curiosity for climbing walls, stairs, and railings and have an increased risk of falling. Here, we report our experience with railings causing injuries by penetrating the upper extremities, and aim to call attention to spiked railing injuries in children.

METHODS: We report on five children with a mean age of 8.8. All of the children were male. The penetrating railing parts were removed in a surgical room.

RESULTS: The injured structures repaired immediately were as follows: flexor digitorum profundus tendon, A4 pulley, volar plate of the distal interphalangeal joint, radial digital nerve, ulnar digital artery, and radial digital artery.

CONCLUSION: Spiked railings can lead to significant injury that requires further exploration. Boys particularly are at risk, and parents should be alert regarding these type of injuries. We recommend a standard regulation for fence erection, and we wish to warn owners of this type of fence regarding probable legal sanctions.

Keywords: children; penetrating injury; spiked railings; upper extremity.

INTRODUCTION

Preschoolers and school-going children have a curiosity for climbing walls, stairs, and railings. This may seem advantageous for the physical and emotional growth of a child; however, it may bring about a risk for penetrating injuries caused by the sharp ends of railings. Because this type of upper extremity injury is rare, it can be a thrilling challenge for surgeons. In the present study, our objectives are to report our experience with railings causing injuries by penetrating the upper extremities, and to call attention to the risk of spiked railing injuries in children. To the best of our knowledge, this case series is the first in the Turkish literature.

MATERIALS AND METHODS

Six injured children admitted to our institute between the 1st July of 2010 and 1st July of 2015 were included in the present study. We excluded one patient because we were unable to contact him; therefore, we present five patients here. Written informed consent from the patient's legal representatives was obtained, and the study was approved by Mersin University Clinical Researches Ethical board. In all the cases, the railing parts were cut on the spot to free and transport the patients. The patients were admitted to the emergency department with parts of the railings penetrating their upper extremities. The penetrating railing parts were removed un-

Cite this article as: Ayhan E, Çevik K, Bağır M, Çolak M, Eskandari MM. Spiked railing penetration that causes injuries in the upper extremities of children. *Ulus Travma Acil Cerrahi Derg* 2018;24:145–148

Address for correspondence: Egemen Ayhan, M.D.

Dışkapı Yıldırım Beyazıt Eğitim ve Araştırma Hastanesi, Ortopedi ve Travmatoloji & El Cerrahisi Kliniği, Ankara, Turkey

Tel: +90 312 - 596 20 00 E-mail: egemenay@yahoo.com

Ulus Travma Acil Cerrahi Derg 2018;24(2):145–148 DOI: 10.5505/tjtes.2017.85349 Submitted: 10.04.2017 Accepted: 21.08.2017 Online: 12.02.2018
Copyright 2018 Turkish Association of Trauma and Emergency Surgery



der general anesthesia in the surgical room. All the patients were called for follow-up.

Case 1

A 13-year-old boy was admitted with a spiked railing that pierced his left index finger. He was injured after falling down from a horizontal bar. The spiked railing penetrated the second web space, passed through the volar side of the index finger, and finally emerged from the radial side of the distal interphalangeal joint. The finger was ischemic at presentation (Fig. 1). Following the removal of the railing, circulation in the finger was immediately restored. We repaired the flexor digitorum profundus tendon, A4 pulley, and volar plate of the distal interphalangeal joint.

Case 2

A 9-year-old boy was admitted with a spiked railing that penetrated the ulnar side of the left wrist flexor crease, passed through the Guyon canal and palm, and finally emerged from the fourth web space (Fig. 2). During the exploration, the neurovascular structures were found to be intact.

Case 3

A 5-year-old boy was admitted with a spiked railing that penetrated the right wrist flexor crease, passed through the carpal tunnel, and finally emerged from the third web space (Fig. 3). He was injured while climbing over a garden wall in pursuit of another child. During the exploration, we found that the radial digital nerve of the fourth finger and the ulnar digital artery of the third finger were transected. Circulation was normal, and only the digital nerve was repaired.

Case 4

An 8-year-old boy was injured after falling down from a plum tree. He was admitted with a spiked railing that penetrated the distal palmar crease of the right hand and emerged from the third web space (Fig. 4). During the exploration, injury to the radial digital artery of the fourth finger was observed. Circulation was normal, and the digital artery was not treated.

Case 5

A 9-year-old boy was admitted with a spiked railing that penetrated the right arm from the medial side, passed through the posterior proximal humerus, and finally emerged from the lateral side (Fig. 5). He was injured after falling from a wall whilst being chased by his friend. The preoperative neurovascular examination was normal. During the surgery, we extended the entry and exit points and then carefully extracted the object. We performed a limited exploration of neurovascular structures and found no active bleeding with palpable pulses.

RESULTS

All the patients were male with a mean age of 8.8 (5–13). All the patients had only soft tissue injuries without any fracture. There were no early preoperative complications, and all the patients were discharged a day after the surgery. The mean follow-up was 32.4 (12–70) months. All the patients were symptom-free at the last follow-up. The patient in Case 1 was symptom-free with full restoration of the range of motion. In Case 3, the two-point discrimination value in the injured finger was the same as that in the contralateral normal finger (4 mm).

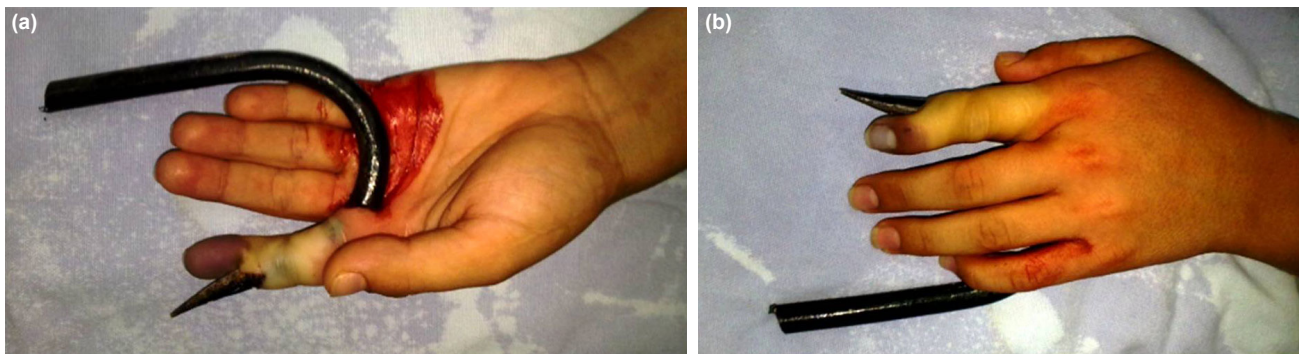


Figure 1. (a, b) Ischemia of the index finger after a spiked railing penetration through the second web space.

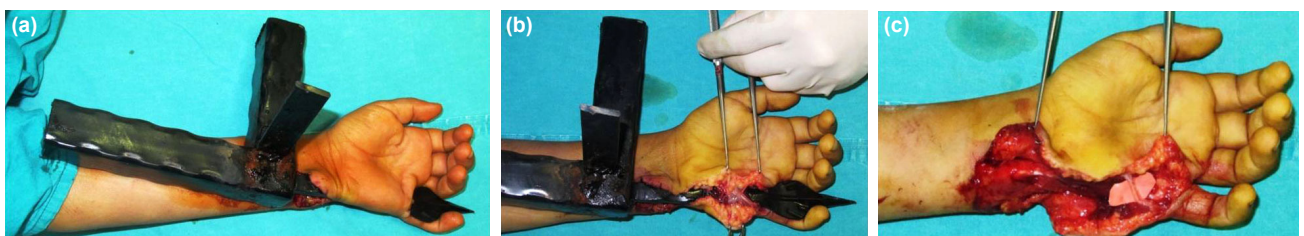

Figure 2. Spiked railing penetration through the Guyon canal and palm (a, b); intact small finger ulnar digital nerve after careful extraction of the object (c).

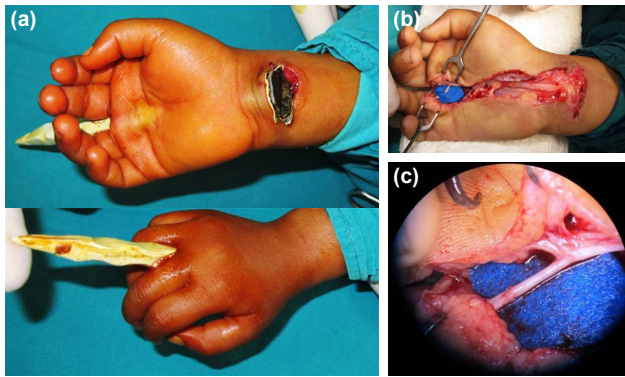


Figure 3. Spiked railing penetration through the carpal tunnel (a); intact median nerve but transected radial digital nerve of the fourth finger (b); and repaired radial digital nerve of the fourth finger (c).

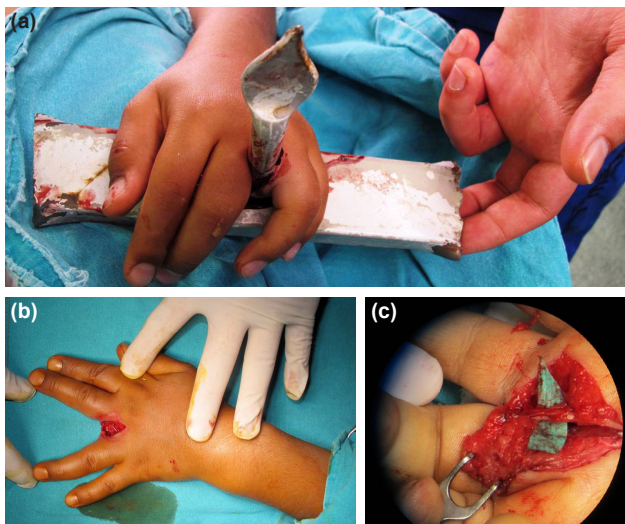


Figure 4. Spiked railing penetration from the distal palmar crease to the dorsal third web space (a); exit site of the railing after safe extraction (b); and intact third common digital nerve (c).

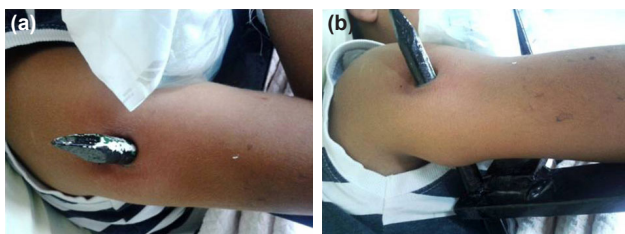


Figure 5. (a, b) Spiked railing penetration of the right arm.

DISCUSSION

Unintentional injury is the most common cause of mortality and morbidity in preschoolers and school-going children.^[1] The patients in the present study had striking presentations and clearly indicate the possibility of serious damage after falling over the sharp ends of railings.

In most spiked railing penetrations, the upper extremity, particularly the hand, is injured. This is due to the body-shielding function of the hand and upper extremity. These sharp, pointed objects cause significant injury independent of the wound size

because of the delicate anatomy of the hand.^[2-5] Supporting this, in our four patients with hand injuries, we explored deep structure lacerations in three. We recommend a thorough exploration of the entire track of the hand injury in the surgical room. However, as in Case 5, if the preoperative neurovascular examination is normal with obvious patient cooperation, we think that there may be no need to comprehensively expose the entire track in upper limb penetrating injuries that do not involve the hand. Anyway, the approach is based on the surgeons' preference, and some surgeons support the exploration of the entire tract to clear all doubts. Finally, although we did not encounter any fracture, a roentgenographic examination is mandatory for such serious injuries.

The tips of the railings presented in the present study were arrow-type. The wide base of these tips creates a buttonhole effect; thus, safe extraction of the object is impossible without extending the wound size at the entry and exit points. Therefore, we recommend extraction of any penetrating material in the surgical room, even if the penetrated object tip is suitable for simple withdrawal.

Similar to the study conducted by Rasheed et al.,^[5] all the patients in our study were male. The explanation for this has been reported in several studies; boys tend to take more risks than girls, exhibit more risky attitudes, and be more confident in dealing with danger.^[6-8] So, parents should be more alert concerning male children.

Spiked railings are a significant danger to preschoolers and school-going children who bear the spirit of adventure. Some children run after a ball, or climb a tree to pick fruits, or have curiosity for empty houses. Likewise, our patients share similar characteristics. In fact, even warning signs do not show promise as a deterrent for this fearless population.^[4] Therefore, other precautions must be considered. To prevent these injuries, the reasons and sequences of the accidents must be analyzed.^[5,9] Is it possible to change the nature of children? Is it possible to forbid children from climbing? These precautions do not make sense and are not beneficial for their growth and development.^[4] Some precautions may include the prohibition of spiked railings in places where children play.

Such railings are extensively used in Turkey, both in public places and private residences. Lawyers have pointed out that there is no standard regulation for fence erection in Turkey.^[10] They insisted that excessive prevention of private property which causes someone's injury is punished according to the Turkish Criminal Law. It appears that the owners are prone to legal sanctions. We believe that in countries with no standard regulations for fence erection (as in Turkey), institutions regarding public health (e.g., Turkish Public Health Association) may play an important role in alerting the society and legal system. Legislations against the manufacture of this type of railing need to be considered.

Although we tried to restrict the penetrating injuries to the upper extremities in the patients, the injuries were not homogenous; this was a major limitation of this study. However, it is hard to establish a more homogenous group with documentation in this rare type of injury. Moreover, we did not try to emphasize the treatment or outcome but tried to highlight the significance of the injuries and possible legal actions.

In conclusion, spiked railings can lead to significant injury that must be explored in the surgical room only. Boys are particularly at risk due to gender characteristics. We recommend the removal of these types of railings around play areas of children and the preparation of standard regulations for fence erection. Also, we wish to warn owners of this type of fence regarding probable legal sanctions.

Conflict of interest: None declared.

REFERENCES

1. Committee on Child Abuse and Neglect; Committee on Injury, Violence,

and Poison Prevention; Council on Community Pediatrics. American Academy of Pediatrics. Policy statement-child fatality review. *Pediatrics* 2010;126:592–6. [CrossRef]

- Amjadi M, Harries R. Corrugated-iron fence injury to the hand. *J Hand Surg Eur Vol* 2009;34:809–10. [CrossRef]
- Griffin PA, Robinson DN. Paediatric hand injuries and the galvanized-iron fence. *Med J Aust* 1989;150:644–5.
- Murphy SM, Cronin KJ. Paediatric hand injuries caused by palisade railings. *J Hand Surg Eur Vol* 2010;35:70–1. [CrossRef]
- Rasheed T, Hill C, Khan K, Brennan M. Paediatric hand injuries caused by spiked railings. *J Hand Surg Br* 1999;24:615–6. [CrossRef]
- Byrnes JP, Miller DC, Schafer WD. Gender differences in risk taking: a meta-analysis. *Psychol Bull* 1999;125:367–83. [CrossRef]
- Morrongiello BA, Dawber T. Parental influences on toddlers' injury-risk behaviors: are sons and daughters socialized differently? *J Appl Dev Psychol* 1999;20:227–51. [CrossRef]
- Peterson L, Brazeal T, Oliver K, Bull C. Gender and developmental patterns of affect, belief, and behavior in simulated injury events. *J Appl Dev Psychol* 1997;18:531–46. [CrossRef]
- Evans DM. The prevention of hand injuries. *J Hand Surg Br* 1991;16:239.
- <http://www.hurriyet.com.tr/dut-faciasina-hukukcu-tepkisi-26385299>. Accessed Mar 11, 2017.

ORJİNAL ÇALIŞMA - ÖZET

Çocuklarda korkuluk demiri ile üst ekstremitte penetran yaralanmaları

Dr. Egemen Ayhan,¹ Dr. Kadir Çevik,² Dr. Melih Bağır,³ Dr. Mehmet Çolak,⁴ Dr. Metin Manouchehr Eskandari⁴

¹Dışkapı Yıldırım Beyazıt Eğitim ve Araştırma Hastanesi, Ortopedi ve Travmatoloji ve El Cerrahisi Kliniği, Ankara

²Mersin Üniversitesi Tıp Fakültesi, Ortopedi ve Travmatoloji Anabilim Dalı, Mersin

³Çukurova Üniversitesi Tıp Fakültesi, Ortopedi ve Travmatoloji ve El Cerrahisi Kliniği, Adana

⁴Mersin Üniversitesi Tıp Fakültesi, Ortopedi ve Travmatoloji ve El Cerrahisi Anabilim Dalı, Mersin

AMAÇ: Çocuklar duvarlara, merdivenlere ve korkuluklara tırmanmaya meraklıdır. Bu durum düşme sonucu travmaları da artırmaktadır. Çalışmamızda korkuluk demiri ile üst ekstremitte penetran yaralanması olan çocuk hastalarımızdaki tecrübelerimizi paylaşmayı ve çocuklardaki bu tip yaralanma riskine dikkat çekmeyi amaçladık.

GEREÇ VE YÖNTEM: Çalışmamızda ortalama yaşı 8.8 olan beş erkek çocuk dâhil edildi. Saplanmış olan korkuluk demirleri ameliyathanede çıkarıldı.

BULGULAR: Eksplozasyon sonucu yaralandığı tespit edilen yapılar (fleksör digitorum profundus tendonu, A4 pulleyi, distal interfalangeal eklem volar plak, radial dijital sinir, ulnar dijital sinir ve radial dijital arter) hemen onarıldı.

TARTIŞMA: Korkuluk demiri yaralanmaları, ameliyathanede eksplozasyon gerektirmekte ve önemli yapıların yaralanmasına neden olabilmektedir. Özellikle erkek çocukları risk altındadır ve ebeveynler bu açıdan dikkatli olmalıdır. Korkuluk demirlerinin kullanımında standart bir hukuki düzenleme olması gerektiğini düşünmekteyiz. Bu çalışmayı, olası yaralanmalar açısından toplumun, olası hukuki sonuçları açısından da kullanan kurumların ve kişilerin dikkatine sunuyoruz.

Anahtar sözcükler: Çocuklar; korkuluk demiri; penetran yaralanmalar; üst ekstremitte.

Ulus Travma Acil Cerrahi Derg 2018;24(2):145–148 doi: 10.5505/tjtes.2017.85349