





# Is combined topical-local anesthesia technique adequate for visual internal urethrotomy in the treatment of traumatic posterior urethral strictures and prostatic urethral stenoses?

 Kubilay Sarıkaya, M.D.,  Çağrı Şenocak, M.D.,  Fahri Erkan Sadioğlu, M.D.,  
 Ömer Faruk Bozkurt, M.D.

Department of Urology, Health Sciences University, Keçiören Training and Research Hospital, Ankara-Turkey

## ABSTRACT

**BACKGROUND:** To compare the effectiveness of spinal anesthesia (SA) and the combination of intraurethral topical instillation of 2% lidocaine + intraurethral local visual injection anesthesia (T + LIA) for visual internal urethrotomy (VIU) in the treatment of traumatic posterior urethral strictures and prostatic urethral stenoses.

**METHODS:** In this study, the results of 178 patients who underwent visual internal urethrotomy for posterior urethral strictures and prostatic urethral stenoses secondary to trauma in our clinic between October 2018 and January 2020 were analyzed retrospectively. Patients were divided into two groups as combined T + LIA (n=146, 82.08%) group and SA (n=32, 17.97%) group according to the type of anesthesia used. The preoperative clinical data and postoperative results of the patients were analyzed and compared between the groups.

**RESULTS:** The mean age of the patients was  $67.99 \pm 10.87$  years and the mean follow-up was  $5.32 \pm 3.27$  months. The median age of the patients in the T + LIA group was significantly higher than that of the patients in the SA group ( $p=0.033$ ). There was no statistically significant difference between the groups regarding preoperative Q-max value ( $p=0.931$ ). Similarly, the rate of postoperative improvement in the Q-max values of the patients was similar between the groups ( $p=0.572$ ). The presence of postoperative complications and recurrence rates were similar between the groups ( $p=0.879$  and  $p=0.904$ , respectively).

**CONCLUSION:** Compared to spinal anesthesia, T + LIA anesthesia is a safe and effective technique for visual internal urethrotomy in treating traumatic posterior urethral strictures and prostatic urethral stenoses, with a high rate of success and acceptable rate of complications.

**Keywords:** Local anesthesia; urethral obstruction; urethral stricture.

## INTRODUCTION

Due to the increase in the number of endoscopic interventions that causes iatrogenic trauma in urology practice, the prevalence of urethral strictures has also significantly increased.<sup>[1]</sup> The prevalence of urethral stricture in men in the general population is reported as 229–627 per 100,000 people.<sup>[2]</sup> Either due to iatrogenic trauma or secondary to

external urethral trauma, urethral stricture causes serious treatment costs and morbidity in addition to its negative effects on patients' quality of life.<sup>[3]</sup>

Urethral dilatation and visual internal urethrotomy (VIU) are recommended as the primary option for the treatment of urethral strictures.<sup>[4,5]</sup> Especially in anterior-bulbar urethral strictures shorter than 2 cm, VIU is an effective and primary

Cite this article as: Sarıkaya K, Şenocak Ç, Sadioğlu FE, Bozkurt ÖF. Is combined topical-local anesthesia technique adequate for visual internal urethrotomy in the treatment of traumatic posterior urethral strictures and prostatic urethral stenoses?. *Ulus Travma Acil Cerrahi Derg* 2021;27:139-145.

Address for correspondence: Kubilay Sarıkaya, M.D.

Sağlık Bilimleri Üniversitesi, Keçiören Eğitim ve Araştırma Hastanesi Üroloji Kliniği, Ankara, Turkey

Tel: +90 312 - 356 90 00 E-mail: drkubilay.sarikaya76@outlook.com

*Ulus Travma Acil Cerrahi Derg* 2021;27(1):139-145 DOI: 10.14744/tjtes.2020.84426 Submitted: 15.09.2020 Accepted: 23.12.2020 Online: 29.12.2020  
Copyright 2021 Turkish Association of Trauma and Emergency Surgery



treatment option.<sup>[6,7]</sup> The advantages of VIU include its easy applicability, cost-effectiveness with minimal requirement of equipment, shorter length of hospital stay, minimal postoperative pain, and low complication rate.<sup>[8]</sup> However, the option of open urethroplasty comes to the fore in frequently recurring urethral strictures longer than 2 cm.<sup>[9,10]</sup> Although VIU is conventionally performed under general or regional anesthesia, it has recently been shown to be easily performed under various topical and local anesthesia techniques.<sup>[3,11]</sup>

As with anterior bulbous urethral strictures, VIU is the first-line treatment option for bulbomembranous and membranous traumatic urethral strictures and prostatic urethral stenoses and it is classically performed under general or regional anesthesia.<sup>[12]</sup> Although VIU can be performed using the local-topical anesthesia techniques for short anterior urethral strictures, there is insufficient data in the literature to show that VIU can be performed under local or topical anesthesia for the treatment of posterior urethral strictures and prostatic urethral stenoses.<sup>[9–12]</sup>

In this study, we aimed to show that VIU can be performed effectively and safely with combined topical + local visual injection anesthesia (T + LIA), as well as spinal anesthesia (SA) in the treatment of bulbomembranous, membranous urethral strictures and prostatic urethral stenoses caused by iatrogenic or external urethral trauma. For this purpose, we compared the preoperative data and postoperative results of patients who underwent VIU under SA and T + LIA anesthesia.

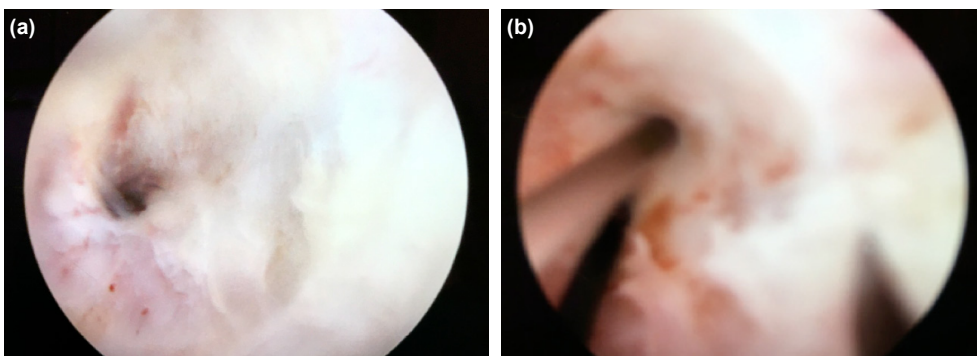
## MATERIALS AND METHODS

The data of 178 patients who underwent VIU for posterior urethral stricture and prostatic urethral stenosis between October 2018 and January 2020 were analyzed retrospectively. Patients with anterior (penile, penobulbar, bulbous) urethral stricture or additional diseases, such as benign prostatic hyperplasia, bladder stones requiring surgery in addition to stricture, and those with additional lower urinary tract diseases, such as neurogenic bladder, were not included in this study. In addition, patients with urethral strictures not secondary to iatrogenic trauma or external trauma, such as infectious or idiopathic strictures, were not included in this

study. Patients with primary or recurrent posterior or prostatic urethral stenosis and stenosis segment length of 0.5–3.5 cm were included in this study.

Patients with recurrent urethral stenosis and with >2 cm segment stenoses included in this study were those who had stricture recurrence only once and high-risk patients with high comorbidity for general or spinal anesthesia. Candidates for open urethroplasty with two or more urethral stricture recurrences and suitable for general or spinal anesthesia were excluded from the present study. Similarly, patients with prostatic urethral stenosis included in this study were those with a high number of comorbidity factors and who could not undergo transurethral resection due to the high risk of general or spinal anesthesia. Patients in those the hydrophilic guidewire could be advanced into the bladder were included in this study. Patients with cystostomy who might require open urethroplasty without any passage to the bladder were excluded from the present study.

Before the operation, complete urinalysis, urine culture, routine blood tests were performed in all patients, urethrograms were taken and the location and approximate length of the stenosis segment were determined. The preoperative uroflowmetry results of the patients were recorded by measuring the Q-max values and post-void residual urine volumes (PVR). Patients in the T + LIA group were given 2% lidocaine gel by intraurethral instillation following the lithotomy position and proper site sterilization and draping. We waited for two to three minutes for lidocaine to reach the posterior urethra. Following the instillation, the urethra was entered by a 12-degree telescope and 21 F urethrotome sheath and advancing to the posterior urethra, the stenosis area was visualized and a 0.035-inch hydrophilic guidewire was advanced from the stenosis area into the bladder (Fig. 1). Under the optical vision, 3–4 cc prilocaine was injected with a 3.7 F thick and 8 mm long cystoscopic injection needle to the twelve clock position of the urethrotomy (Fig. 2). Under the guidance of guidewire, cold knife urethrotomy was performed at a twelve clock position. The second and third prilocaine injections were administered depending on the length of the stenosis segment and the amount of pain felt by the patient. Preoperative routine 1 gr of ceftriaxone was administered



**Figure 1.** (a) Posterior urethral stricture. (b) T-LIA anesthesia to 12 o'clock position.

intravenously to the patients in both groups, and routine VIU operation was performed under the guidance of guidewire. After the procedure, 16 or 18 F silicone catheters were inserted into the bladder of all patients. All patients in the T + LIA group were followed up in the outpatient clinic in the recovery room for two hours and were discharged after the prescription of an oral third-generation cephalosporin. The patients in the SA group were discharged on the postoperative 1st day by prescribing oral third-generation cephalosporin. While the urethral catheter was kept for a short period of 4–7 days in primary stenosis patients with a stenosis segment of 0.5–1 cm, the catheter was kept in the interval 7–14 days in patients with a stenosis segment of 1–3.5 and recurrent urethral stenosis. One week after the urethral catheter was removed; a follow-up uroflowmetry was performed on the patients to measure Q-max values and PVR values. Intraoperative and postoperative complications were recorded. Clean intermittent catheterization (self-dilation) once per day for 1–3 months was recommended. In the long-term follow-up, the patients were invited to the outpatient clinical follow-up on the postoperative 3<sup>rd</sup> and 6<sup>th</sup> months, and they were questioned for possible complications and the presence of recurrence.

The patients were divided into two groups as topical-local anesthesia group (T + LIA) and spinal anesthesia group (SA) according to the anesthesia technique used. The preoperative and postoperative data of the patients in both groups were statistically compared.

## Statistical Analysis

All statistical analyses were performed using the SPSS 24.0 (IBM Corp., Chicago) software for Windows. In the univariate analysis, the Chi-Square Test was used for nominal data, while the Mann-Whitney U test was used for nonparametric variables. Median, minimum, and maximum were used to define the variables. A p-value of <0.05 was considered statistically significant.

## RESULTS

Of the patients included in this study, 146 (82.08%) patients were in the T + LIA group, while 32 (17.97%) patients were in the SA group, with a mean age of  $67.99 \pm 10.87$  years and a mean follow-up time of  $5.32 \pm 3.27$  months. The general characteristics of the patients included in this study and the traumatic factors causing urethral stenosis are shown in Table 1.

The median age of the patients in the T + LIA group was 70.00 (range 32–90) years, while the median age of the SA group was 65.00 (range 30–82) years, and the mean age of the T + LIA group was significantly higher than that of the SA group ( $p=0.033$ ). While the preoperative median Q-max value of the T + LIA group was 7.0 (range 2–9) ml/s, the median of the SA group was 7.0 (range 2–12) ml/s, and there was no

**Table 1.** Characteristic of the patients

	Mean±SD	n	%
Age (years)	67.99±10.87		
Follow-up (months)	5.32±3.27		
Stricture type			
Primary		84	47.2
Recurrent		94	52.8
Stricture location			
Bulbomembranous		97	54.5
Membranous		35	19.7
Prostatic		46	25.8
Stricture etiology			
TUR-P		102	57.3
Open prostatectomy		12	6.7
RRP		3	1.7
TUR-BT		15	8.4
Urethral catheterization		18	10.1
External trauma		13	7.3
Ureterorenoscopy–Retrograde intrarenal surgery		7	3.9
Percutaneous nephrolithotomy		4	2.2
Penile fracture		4	2.2

TUR-P: Transurethral prostate resection; TUR-BT: Transurethral bladder tumor resection; RRP: Radical retropubic prostatectomy; SD: Standard deviation

significant difference between the two groups ( $p=0.931$ ). Similarly, the preoperative median PVR was 160.0 (range 30–450) ml in the T + LIA group, while the median PVR was 155.0 (range 40–550) ml in the SA group, and there was no significant difference between the groups ( $p=0.630$ ). While the median length of the preoperative stenosis segment was 2.0 (range 0.5–3.5) cm in the T + LIA group, the median length of the preoperative stenosis segment was 2.0 (1–2) cm in the SA group, and there was no significant difference between the groups ( $p=0.713$ ). While 60 (41.1%) of the patients in the TA group had primary stenosis, 24 (75.0%) patients in the SA group had primary stenosis. On the other hand, 86 (58.9%) of the patients in the T + LIA group had recurrent stenosis, while 8 (25.0%) patients in the SA group had recurrent stenosis, and there was a significant difference between the groups regarding stenosis type ( $p=0.001$ ). There was no difference between groups regarding stenosis localization and etiology ( $p=0.475$  and  $p=0.130$ , respectively). The preoperative results of the groups and data of the etiological factors are shown in Table 2.

A median of 11 (range 2–21) ml/s improvement in the Q-max measurements was achieved in the T + LIA group and a median of 10 (range 3–21) ml/s improvement in the Q-max measurements was achieved in the SA group in the follow-up

uroflowmetry one week after the urethral catheter was removed and there was no significant difference between the groups ( $p=0.572$ ). In the postoperative period, the PVR measurements taken after uroflowmetry revealed a median of 0 (range 0–80) ml PVR in the T + LIA group and a median of 20 (range 0–80) ml PVR in the SA group, and the PVR value of the SA group was significantly higher ( $p=0.020$ ). On the other hand, different postoperative complications were observed in a total of 15 (10.3%) patients in the T + LIA group, including 8 (5.47%) infection, four (2.27%) urinary retention and three (2.05%) bleeding, while the infection was detected in three (9.4%) patients in the SA group. There was no significant difference between the groups regarding the presence of com-

plications ( $p=0.879$ ). In addition, in the follow-up at the end of the postoperative 6th month, 38 (26%) patients in the T + LIA group had stricture or stenosis recurrence, while eight (25%) patients in the SA group had a recurrence, and there was no significant difference between the groups ( $p=0.904$ ). The postoperative results of the groups are shown in Table 3.

## DISCUSSION

Although urethral stricture is common in the middle to advanced age group among men due to iatrogenic traumas or external urethral traumas in urology practice, it can be seen in all age groups and negatively affects patients' quality of life.<sup>[13]</sup> Although urethroplasty is considered the gold standard

**Table 2.** Comparison of perioperative features according to the anesthesia type

	Topical (n=146)	Spinal (n=32)	p
Age, years, median (range)	70.00 (32–90)	65.00 (30–82)	0.033
Preoperative Q-max, ml/s, median (range)	7.0 (2–9)	7.0 (2–12)	0.931
Preoperative PVR, ml, median (range)	160.0 (30–450)	155.0 (40–550)	0.630
Stricture length, cm, median (range)	2.0 (0.5–3.5)	2.0 (1–2)	0.713
Stricture type, n (%)			0.001
Primary	60 (41.1)	24 (75)	
Recurrent	86 (58.9)	8 (25)	
Stricture location, n (%)			0.472
Bulbomembranous	77 (52.7)	20 (62.5)	
Membranous	31 (21.2)	4 (12.5)	
Prostatic	38 (26.0)	8 (25.0)	
Stricture etiology, n (%)			0.130
Endoscopic surgery	105 (71.9)	23 (71.9)	
Prostate surgery	12 (8.2)	3 (9.4)	
Urethral catheterization	17 (11.6)	1 (3.1)	
External trauma	8 (5.5)	5 (15.6)	
Penile fracture	4 (2.7)	0 (0)	

Q-max: Maximum urine flow rate; PVR: Postvoiding residual urine volume.

**Table 3.** Comparison of postoperative features according to the anesthesia type

	Topical (n=146)	Spinal (n=32)	p
Postoperative Q-max, ml/s, median (range)	18.0 (10–26)	17.5 (11–24)	0.712
Postoperative PVR, ml, median (range)	0 (0–80)	20 (0–80)	0.020
Postoperative Q-max improvement, ml/s, median (range)	11 (2–21)	10 (3–21)	0.572
Postoperative complications, n (%)	15 (10.3)	3 (9.4)	0.879
Infection	8 (5.47)	3 (9.4)	
Glob vesicale	4 (2.27)	0 (0)	
Bleeding	3 (2.05)	0 (0)	
Postoperative stricture recurrence, n (%)	38 (26)	8 (25)	0.904

Q-max: Maximum urine flow rate; PVR: Postvoiding residual urine volume.

for the treatment of urethral strictures, VIU is commonly performed as the first-line treatment option due to its easy applicability, cost-effectiveness, high success rate, and minimally invasiveness.<sup>[14]</sup> The incidence of urethral stricture has increased significantly with the increase in the number of endoscopic urological procedures and operations, especially among men in the middle and older age groups, and the need for performing VIU in a more practical, non-invasive way in the clinic has emerged.<sup>[1]</sup> Although VIU has been performed under regional or general anesthesia by many authors, it has been shown in several studies that intraurethral lidocaine gel instillation may be adequate for the operation, especially in <2 cm short-segment anterior urethral strictures, and that topical anesthesia is easily tolerated in approximately 80% of these patients.<sup>[15-17]</sup> For this purpose, different local or topical anesthesia techniques have been defined to perform VUI in clinical and office conditions.<sup>[8,17-19]</sup>

In the literature, there are data on internal urethrotomy performed for anterior urethral strictures under topical anesthesia. Kreder et al.<sup>[20]</sup> published the results of VIU performed under intraurethral topical anesthesia in 18 patients with a mean anterior stricture segment of <2 cm and below. According to this study, 15 of 18 patients tolerated topical anesthesia well, and 12 (80%) patients reported only some discomfort. Clinical and radiological success was achieved in 12 (80%) of 15 patients and no complications were reported. In another study, Yüçeturk et al.<sup>[15]</sup> published VIU results of 157 patients operated under topical anesthesia with intraurethral lidocaine gel. According to this study, the procedure was successfully performed on 151 of 157 patients and the recovery rate was reported as 96.1%. A total of 125 patients had mild pain, 26 patients had moderate pain, and six patients required general anesthesia due to severe pain. In the same study, stenosis recurrence was reported in 18 (11.4%) patients in the follow-up period of at least six months. In another study conducted by Altinova et al.<sup>[21]</sup> involving 32 patients who underwent VIU with intraurethral lidocaine gel, a success rate of 92.9% was reported in the follow-up period of at least six months, while stenosis recurrence was reported in only four patients and bleeding in one patient. Kumar Das et al.<sup>[3]</sup> compared the effectiveness of local anesthesia with spinal anesthesia for VIU in 120 patients with short-segment anterior urethral stricture. According to this study, the postoperative VAS score was significantly lower in patients who underwent VIU under spinal anesthesia compared to the local anesthesia group ( $p<0.05$ ). In the same study, the postoperative Q-max changes of patients were similar in spinal anesthesia and local anesthesia groups (a mean of  $20.75\pm 4.31$  vs.  $19.04\pm 4.88$ , respectively). In addition, postoperative recurrence developed in 14 (23%) patients in the spinal anesthesia group, while it developed in 15 (25%) patients in the local anesthesia group. There was no significant difference between the groups regarding stricture recurrence ( $p=0.416$ ). In our study, in line with the literature, Q-max of T + LIA and SA groups improved significantly in the postoperative period, and there

was no significant difference between the groups regarding improvement in Q-max. Similarly, in line with the literature data, there was no significant difference between stenosis recurrence and complication development rates in the post-operative period. In our study, the median age of the T + LIA group was significantly higher than that of the SA group. This indicates that the elderly group with posterior urethral stricture who cannot receive spinal or general anesthesia is operated more with T + LIA anesthesia. This result supports the view that T + LIA anesthesia can be a simple and inexpensive saving method in elderly patients at high risk for general anesthesia.

In addition to intraurethral lidocaine gel instillation in anterior short segment urethral strictures, some other local anesthesia techniques have also been used for VIU, and successful results have been reported.<sup>[8,11,22]</sup> Ye et al.<sup>[19]</sup> used intracorporeal spongiosum anesthesia in VIU in 23 patients with anterior urethral stricture. In this technique, they provided local anesthesia by slowly injecting 3 ml of 1% lidocaine from the glans penis to the corpus spongiosum. In this study, VIU was reported to be performed successfully on all patients, and 22 (95.7%) patients did not experience any pain or discomfort during the procedure, and only one patient had tolerable minimal pain sensation during urethrotomy. In another study, Biswal et al.<sup>[8]</sup> compared the results of intraurethral topical instillation anesthesia (TA) and intracorporeal spongiosum block anesthesia (ICSB) in 60 patients undergoing VIU. According to this study, the mean VAS score of the ICSB group was  $2.8\pm 1.1$ , while the mean VAS score of the TA group was  $5.6\pm 1.7$ , and it was emphasized that ICSB significantly decreased the VAS score ( $p<0.05$ ). On the other hand, the stricture-free patient rate was 88.5% in the ICSB group at the end of the 6-month follow-up, while this rate was reported as 89.6% in the TA group, and it was reported that there was no significant difference between the groups ( $p=0.416$ ). In another recent study, Darlington reported performing a new local anesthesia technique for VIU in 55 patients with anterior urethral stricture.<sup>[11]</sup> In this technique, under cystoscopic direct vision, VIU was performed by entering the urethra from the outside of the penis with a small-bore needle from the six o'clock position and injecting a local anesthetic to the twelve clock position. In this way, the findings suggest that VIU was successfully performed on all patients and there was no requirement for conversion to another anesthesia technique. Similarly, in our study, no patient in the T + LIA group required procedure termination due to pain and conversion to general or spinal anesthesia.

Although all of the abovementioned studies included patients with short-segment anterior stricture, VIU is also considered as the first-line treatment option for posterior traumatic urethral strictures and prostatic urethral stenoses, and its effectiveness is widely known. Hemal et al.<sup>[23]</sup> reported core-through internal urethrotomy results of four patients who developed obliterated posterior urethral stricture after pelvic

fracture. Accordingly, three of four patients were followed up as stable for one year with three months of self-dilatation following urethrotomy, and one patient required bladder neck resection due to recurrent stricture. In another study, Goel et al.<sup>[24]</sup> reported that 13 patients with posterior urethral stricture of <2 cm underwent core-through internal urethrotomy and the operation failed in five (39%) patients, and while three of them underwent open surgery, two patients were lost to follow-up. In the same study, the recurrence rate at the end of three months was 69% in patients followed by self-dilatation, while the recurrence rate was 25% at the end of 12 months. In another study, Gupta et al.<sup>[25]</sup> reported the results of internal urethrotomy performed on 10 patients with obliterated posterior prostatic urethral stenosis under spinal or general anesthesia. Accordingly, in the follow-up period of 6 to-24 months, six patients had a Q-max value higher than 15 ml/s, while two patients had 8–15 ml/s, and one patient was reported to have successfully undergone scrotal flap urethroplasty. In our study, hydrophilic guidewire could be advanced from the urethra to the bladder in all patients included in the study, and urethrotomy was performed under optical vision under the guidance of guidewire. The postoperative Q-max values of the patients in both groups increased significantly, and there was no significant difference between the groups regarding postoperative Q-max values. This indicates that T + LIA anesthesia can be an effective and safe option when properly performed by experienced physicians in cases of posterior urethral strictures and prostatic urethral stenoses caused by iatrogenic or external urethral trauma where there is a passage for the guidewire to advance to the bladder in the preoperative evaluation. However, according to these results, even if T + LIA anesthesia is considered effective and adequate for VIU in posterior urethral strictures, the necessity of spinal or general anesthesia should be considered, especially in completely obstructed cases where guidewire cannot be advanced into the bladder. To our knowledge, there are not sufficient data in the literature showing the effectiveness of local-topical anesthesia for VIU in traumatic posterior urethral strictures or prostatic urethral stenoses. Therefore, we think that our study will significantly contribute to the literature.

### Limitations

Our study has some limitations. The most important of these is the retrospective design of our study. Another important limitation is that patients selected for the procedure were included in this study, whereas patients who had previously undergone urethroplasty or who had complete obstruction were not included in this study. In addition, the low number of patients in the SA group and the fact that perioperative VAS pain scores of the patients were not recorded were other important limitations.

### Conclusion

As with the anterior urethral strictures, the combination of local-topical anesthesia for VIU is a simple, cost-effective,

and well-tolerated technique for VIU in traumatic posterior urethral strictures and prostatic urethral stenoses. It can be easily performed by experienced physicians in an outpatient clinic setting or office conditions, especially in elderly patients at high risk for spinal or general anesthesia. The efficacy and complication rates of local-topical anesthesia are comparable to spinal anesthesia.

**Ethics Committee Approval:** Approved by the local ethics committee.

**Peer-review:** Internally peer-reviewed.

**Authorship Contributions:** Concept: K.S., Ç.Ş., F.E.S.; Design: K.S., O.F.B.; Supervision: Ç.Ş., O.F.B.; Resource: K.S.; Materials: K.S.; Data: K.S., F.E.S.; Analysis: K.S., Ç.Ş.; Literature search: K.S., F.E.S.; Writing: K.S.; Critical revision: Ç.Ş., O.F.B.

**Conflict of Interest:** None declared.

**Financial Disclosure:** The authors declared that this study has received no financial support.

### REFERENCES

1. Wang JW, Man LB. Transurethral resection of the prostate stricture management. *Asian J Androl* 2020;22:140–4. [CrossRef]
2. Santucci RA, Joyce GF, Wise M. Male urethral stricture disease. *J Urol* 2007;177:1667–74. [CrossRef]
3. Das SK, Jana D, Ghosh B, Pal DK. A comparative study between the outcomes of visual internal urethrotomy for short segment anterior urethral strictures done under spinal anesthesia and local anesthesia. *Turk J Urol* 2019;45:431–6. [CrossRef]
4. Devine CJ, and Jordan GH. Surgery of anterior urethral strictures, In: Marshall FF, editor. *Operative Urology*. Philadelphia: Saunders Publishing; 1991.p.307–21.
5. Chapple C. Anterior urethral surgery: Current concepts and future directions. *Eur Urol* 2010;58:42–5. [CrossRef]
6. Kreder KJ, Stack R, Thrasher JB, Donatucci CF. Direct vision internal urethrotomy using topical anesthesia. *Urology* 1993;42:548–50. [CrossRef]
7. Dubey D. The current role of direct vision internal urethrotomy and self-catheterization for anterior urethral strictures. *Indian J Urol* 2011;27:392–6. [CrossRef]
8. Biswal DK, Ghosh B, Bera MK, Pal DK. A randomized clinical trial comparing intracorporeal spongiosum block versus intraurethral lignocaine in visual internal urethrotomy for short segment anterior urethral strictures. *Urol Ann* 2016;8:317–24. [CrossRef]
9. Buckley JC, Heyns C, Gilling P, Carney J. SIU/ICUD Consultation on Urethral Strictures: Dilation, internal urethrotomy, and stenting of male anterior urethral strictures. *Urology* 2014;83:S18–22. [CrossRef]
10. Wright JL, Wessells H, Nathens AB, Hollingworth W. What is the most cost-effective treatment for 1 to 2-cm bulbar urethral strictures: societal approach using decision analysis. *Urology* 2006;67:889–93. [CrossRef]
11. Darlington D. A Novel Method of Local Anesthesia for Optical Internal Urethrotomy. *Cureus* 2019;11:e6043. [CrossRef]
12. Borboroglu PG, Sands JP, Roberts JL, Amling CL. Risk factors for vesicourethral anastomotic stricture after radical prostatectomy. *Urology* 2000;56:96–100. [CrossRef]
13. Mundy AR. Management of urethral strictures. *Postgrad Med J* 2006;82:489–93. [CrossRef]
14. Djordjevic ML, Martins FE, Kojovic V, Kurbatov D. Urethral Stric-

- ture Disease: Challenges and Ongoing Controversies. *Adv Urol* 2016;2016:1238369. [CrossRef]
15. Yüçetürk CN, Yıldız Y, Özgür BC, Sunay MM, Doluoğlu ÖG, Hasçıev AM, et al. The efficacy of intraurethral lidocaine in optical internal urethrotomy for anterior urethral stricture: a multicenter study. *Minerva Urol Nefrol* 2017;69:619–25.
  16. Greenland JE, Lynch TH, Wallace DM. Optical urethrotomy under local urethral anaesthesia. *Br J Urol* 1991;67:385–8. [CrossRef]
  17. Mensah J, Quartey J, Yehoah E, Klufio G. The efficacy of intracorporeal spongiosum anesthesia in internal urethrotomy for anterior urethral strictures. *Afr J Urol* 2005;11:111–4.
  18. Ather MH, Zehri AA, Soomro K, Nazir I. The safety and efficacy of optical urethrotomy using a spongiosum block with sedation: a comparative nonrandomized study. *J Urol* 2009;181:2134–38. [CrossRef]
  19. Ye G, Rong-gui Z. Optical urethrotomy for anterior urethral stricture under a new local anesthesia: intracorporeal spongiosum anesthesia. *Urology* 2002;60:245–7. [CrossRef]
  20. Kreder KJ, Stack R, Thrasher JB, Donatucci CF. Direct vision internal urethrotomy using topical anesthesia. *Urology* 1993;42:548–50. [CrossRef]
  21. Altinova S, Turkan S. Optical urethrotomy using topical anesthesia. *Int Urol Nephrol* 2007;39:511–2. [CrossRef]
  22. Nicholson HL, Al-Hakeem Y, Maldonado JJ, Tse V. Management of bladder neck stenosis and urethral stricture and stenosis following treatment for prostate cancer. *Transl Androl Urol* 2017;6:S92–102. [CrossRef]
  23. Hemal AK, Singh I, Chahal R, Gupta NP. Core Through Internal Urethrotomy in the Management of Post-Traumatic Isolated Bladder Neck and Prostatic Urethral Strictures in Adults. A report of 4 cases. *Int Urol and Nephrol* 1999;31:703–8.
  24. Goel MC, Kumar M, Kapoor R. Endoscopic management of traumatic posterior urethral stricture: early results and followup. *J Urol* 1997;157:95–7. [CrossRef]
  25. Gupta NP, Gill IS. Core-through optical internal urethrotomy in management of impassable traumatic posterior urethral strictures. *J Urol* 1986;136:1018–21. [CrossRef]

## ORJİNAL ÇALIŞMA - ÖZET

### Kombine topikal-lokal anestezi tekniği travmatik posterior segment üretral darlıkların ve prostatik üretral stenozların tedavisinde visual internal üretrotomi için yeterli midir?

Dr. Kubilay Sarıkaya, Dr. Çağrı Şenocak, Dr. Fahri Erkan Sadioğlu, Dr. Ömer Faruk Bozkurt

Sağlık Bilimleri Üniversitesi, Keçiören Eğitim ve Araştırma Hastanesi, Üroloji Kliniği, Ankara

**AMAÇ:** Travmatik posterior segment üretral darlıkların ve prostatik üretral stenozların tedavisinde visual internal üretrotomi (VIU) için spinal anestezi (SA) ile %2 lidokainli intraüretral topikal instilasyon+vizüel intraüretral lokal anestezi (T+LIA) kombinasyonunun etkinliğini karşılaştırmak.

**GEREÇ VE YÖNTEM:** Kliniğimizde Ekim 2018 ve Ocak 2020 tarihleri arasında travmaya ikincil gelişen posterior segment üretral darlık ve prostatik üretral stenoz nedeniyle VIU operasyonu yaptığımız toplam 178 hastanın sonuçları geriye dönük olarak incelendi. Hastalar uygulanan anestezi tipine göre kombine T+LIA (n=146, %82.08) grubu ve SA (n= 32, %17.97) grubu olarak iki gruba ayrıldı. Hastaların ameliyat öncesi klinik verileri ve ameliyat sonrası sonuçları incelenerek gruplar arasında karşılaştırıldı.

**BULGULAR:** Hastaların ortalama yaşı  $67.99 \pm 10.87$  yıl ve ortalama takip süreleri  $5.32 \pm 3.27$  aydı. T+LIA grubundaki hastaların median yaşının SA grubuna göre anlamlı olarak yüksek olduğu görüldü ( $p=0.033$ ). Gruplar arasında ameliyat öncesi Q-max değeri açısından istatistiksel olarak anlamlı fark saptanmadı ( $p=0.931$ ). Benzer şekilde, ameliyat sonrası dönemde hastaların Q-max değerlerinde düzelme oranının gruplar arasında benzer düzeyde olduğu görüldü ( $p=0.572$ ). Ameliyat öncesi komplikasyon varlığı ve nüks oranları da gruplar arasında benzer bulundu (sırasıyla,  $p=0.879$ ,  $p=0.904$ ).

**TARTIŞMA:** Travmatik posterior segment üretral darlıkların ve prostatik üretral stenozların tedavisinde VIU için T+LIA anestezi spinal anestezi ile kıyaslandığında yüksek başarı oranı ve kabul edilebilir komplikasyon oranı ile güvenle uygulanabilir ve etkin bir yöntemdir.

**Anahtar sözcükler:** Lokal anestezi; üretral darlık; üretral obstrüksiyon.

*Ulus Travma Acil Cerrahi Derg* 2021;27(1):139-145 doi: 10.14744/tjtes.2020.84426