

# Role of digital infrared thermal imaging in diagnosis of acute appendicitis

Uğur Aydemir, M.D.,<sup>1</sup> Talha Sarıgöz, M.D.,<sup>2</sup> Tamer Ertan, M.D.,<sup>3</sup> Ömer Topuz, M.D.<sup>3</sup>

<sup>1</sup>Department of General Surgery, Aksaray State Hospital, Aksaray-Turkey

<sup>2</sup>Department of General Surgery, Kayseri City Hospital, Kayseri-Turkey

<sup>3</sup>Department of General Surgery, Health Sciences University, Kayseri-Turkey

## ABSTRACT

**BACKGROUND:** Acute appendicitis (AA) is one of the most common diseases requiring emergency surgery. Today, diagnosis of AA is made through anamnesis, physical examination along with advanced imaging methods. Thermal imaging confers advantages over conventional techniques for being portable, non-invasive, easily conducted, ionization radiation-free, and inexpensive. Digital infrared thermal imaging (DITI) has been the subject of research in various clinical scenarios. In this prospective randomized controlled study, diagnostic potential of DITI in AA was investigated.

**METHODS:** Totally, 224 volunteers (112 healthy volunteers and 112 patient volunteers) were enrolled and divided into two groups; control group and patient group. All subjects were assessed by DITI. Steady-state images of both lower quadrants and sternum were taken. Thermal images were transferred to computer software and analyzed. Potential of thermal imaging as a diagnostic method was evaluated.

**RESULTS:** Regarding temperature differences between the quadrants, statistical analysis delivered significant difference between the both groups ( $p < 0.001$ ). As a result of the analysis, the cutoff value for the diagnosis of AA was found to be 0.4°C difference between the average lower quadrant temperatures.

**CONCLUSION:** This study has enlarged the application of DITI to abdominal pain, especially within context of AA. Thermal evaluation of patients with abdominal pain seems promising.

**Keywords:** Acute abdomen; appendicitis; thermal imaging.

## INTRODUCTION

Acute appendicitis (AA) is one of the most common diseases requiring emergency surgery.<sup>[1]</sup> Estimated life time risk is thought to be 7–8%.<sup>[2]</sup> AA is usually an inflammatory event that occurs in some part of appendix due to blockage in the lumen.<sup>[3]</sup> Following occlusion, intraluminal pressure increases, congestion, and distension occur. This inflammatory response can be reflected to the clinic as right abdominal discomfort.

Nowadays, the diagnosis of AA is made through anamnesis, physical examination along with advanced imaging methods.<sup>[4]</sup> The correct diagnosis rate is nearly 80% when relied on anamnesis and physical examination only and in one of three

patients with AA suspicion, there may be atypical clinical course, symptoms and laboratory values.<sup>[5]</sup> Abdomen ultrasonography (US), computed tomography (CT), and magnetic resonance imaging (MRI) are helpful tests when clinical findings are equivocal.<sup>[6]</sup> For abdomen US, sensitivity ranges from 59% to 78% and for CT, from 87% to 100% in the literature.<sup>[6,7]</sup> MRI is usually used to refrain from radiation exposure especially in pregnant patients when US is inadequate.

On the other hand, evaluation of human body temperature as a sign of ailment is as old as medicine itself. Over the years, different tools have been proposed to determine body temperature. Infrared thermal imaging was one of them which was introduced to medicine in 1940s. In line with advances in

Cite this article as: Aydemir U, Sarıgöz T, Ertan T, Topuz Ö. Role of digital infrared thermal imaging in diagnosis of acute appendicitis. *Ulus Travma Acil Cerrahi Derg* 2021;27:647-653.

Address for correspondence: Talha Sarıgöz, M.D.

Kayseri Şehir Hastanesi, Genel Cerrahi Kliniği, Kayseri, Turkey

Tel: +90 352 - 315 77 00 E-mail: sarigozt.md@gmail.com

*Ulus Travma Acil Cerrahi Derg* 2021;27(6):647-653 DOI: 10.14744/tjtes.2020.80843 Submitted: 07.07.2020 Accepted: 12.08.2020

Copyright 2021 Turkish Association of Trauma and Emergency Surgery



sensor technology and analysis tools, digital infrared thermal imaging (DITI) was born in the past decades.<sup>[8]</sup> For the DITI process, usually a thermal camera is used to observe and record heat signals as a thermal image. These images can be assessed on software programs. This procedure is non-invasive and radiation free. It is also financially attractive compared to US, CT, and MRI. However, there is lack of available data in the literature regarding if there is some degree of symmetry between homologous quadrants of abdomen and we can use this symmetry to diagnose underlying pathology.

This study was carried out to investigate the practical role of DITI in diagnosis of AA. It was postulated that inflammatory process caused by AA alters surrounding tissue temperature and we may detect that change on the overlying skin by DITI. Furthermore, we aimed to describe a reference cut-off as a measure of symmetry for evaluation of intra-abdominal pathology. In this regard, first degree of thermal symmetry was established by calculating temperature differences between the right lower quadrant (RLQ) and the left lower quadrant (LLQ) of healthy volunteers. Afterwards, the same protocol was followed for patient volunteers with AA before surgery. Finally, two groups were compared in terms of temperature differences between the lower quadrants and potential of DITI has been examined in detail.

## MATERIALS AND METHODS

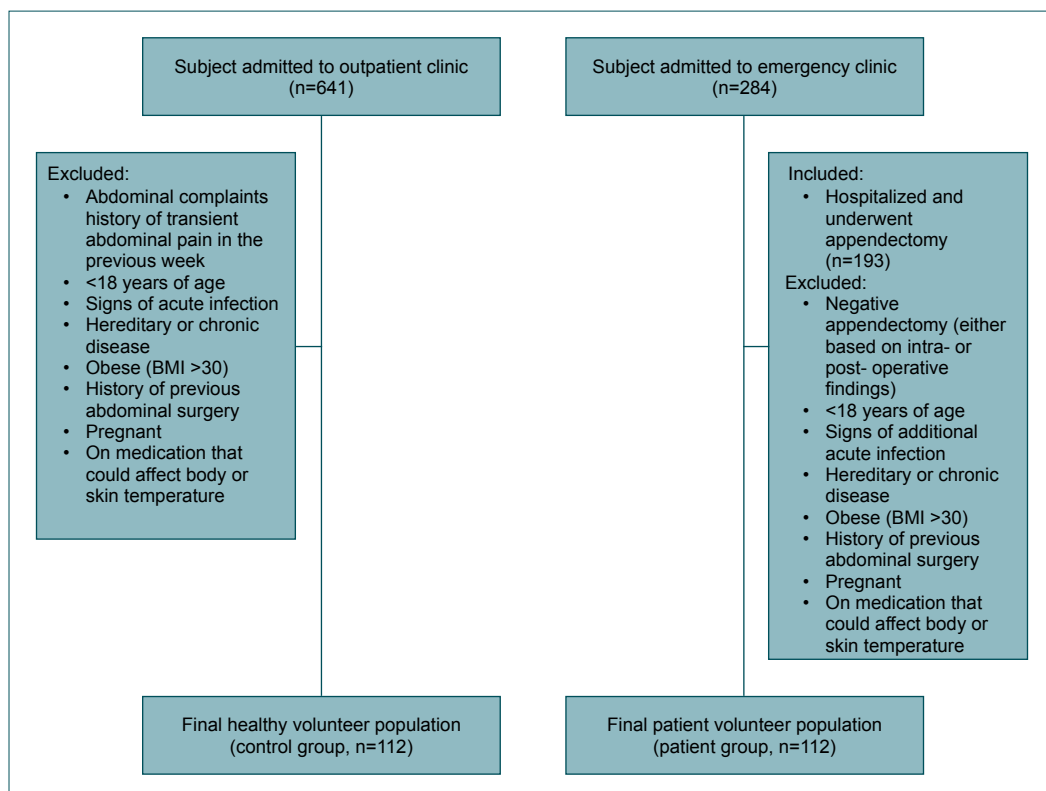
Volunteer enrollment was initiated following the approval of

the study protocol by Erciyes University Scientific Research Ethics Committee (Registration number: 598).

This study was conducted at Kayseri Training and Research Hospital between January 2018 and April 2018. During 4 months period, 284 patients with abdominal pain admitted to the emergency department. Following initial examination, 193 patients were hospitalized with the diagnosis of AA and underwent surgery. From those, 155 patients volunteered to take part in the study. Furthermore, during the 4 months period, healthy subjects (controls) admitted to outpatient clinic for complaints other than abdominal pain were included in the study. All subjects were informed about the study and their consent was taken to take part in this research.

All of the volunteers were older than 18 years of age. Volunteers with signs of acute infection, those had hereditary disease or chronic disease, those were obese (body mass index >30), those with history of previous abdominal surgery, those were pregnant, who were on medication (non-steroid/steroid anti-inflammatory drugs, herbal remedies, topical creams, etc.) that could affect body or skin temperature were excluded from the study. In addition, patient volunteers with normal surgical signs and normal pathological results; and healthy volunteers with a history of transient abdominal pain in the previous week were kept out of the study (Fig. 1).

In patient volunteers, DITI was performed prior to shaving and invasive intervention on the operation table to avoid

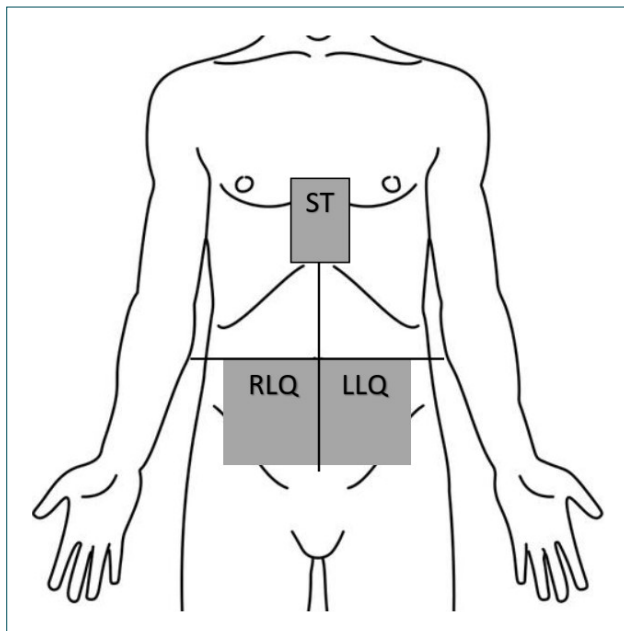


**Figure 1.** Flow diagram showing volunteer selection.

changes on the body surface temperature. In healthy volunteers, it was performed in an outpatient clinic office which was used only for this purpose. Utmost attention was paid to hold ambient temperature at around 22–25°C and the volunteers were not exposed to direct sunlight. For the DITI protocol, Fluke® Ti9 (Fluke Corporation, Everett, WA, U.S.A.) was used. This infra-red camera has spatial resolution of 2.5 mRad and image resolution of 640×480 pixels. Its operating temperature range is from -10°C to +50°C with thermal sensitivity  $\leq 0.2^\circ\text{C}$  at 30°C target temperature.

The surgeon, who took the thermal images, was unaware of the volunteers' complaints, examination findings, and imaging results such as detailed abdomen US and CT. After their consent was taken, study subjects were told to take top clothes off and they were kept in the room for 15 minutes to let them get used to the ambient temperature. Steady-state images of both lower quadrants and sternum (ST) were taken at a distance of 1 m above the subjects while they were lying on the operation table. Image of the RLQ was taken from the area with highest tenderness on palpation. Furthermore, image of LLQ was mirror sight of the area with the highest tenderness in the RLQ. A total of three images were taken in 90° coronal plane. The images on the ST were used as a control to prevent the error caused by additional inflammatory processes in the LLQ (Fig. 2).

After the DITI process, images were transferred to computer software and analyzed by a different operator who was unaware of the subjects. For the evaluation of images, SmartView™ Desktop Software program v4.3 (Fluke Thermography, Plymouth, MN, U.S.A.) was used. This software can calculate temperature at a specific area or point on ther-



**Figure 2.** Schematic representation of the digital infrared thermal imaging zone.

mal images. The area with the highest tenderness in the RLQ and corresponding area in the LLQ was determined using area tool on the software. Maximum, minimum, and average temperature values of the participants' RLQ, LLQ, and ST were calculated. A comparison was made between the groups. If RLQ temperature was 0.5°C warmer than LLQ, it was considered as an indicator of disorder and patients with those results were interpreted as AA. The temperature differences between the two quadrants were defined as follows; SSMin for the difference of minimum temperatures, SSAve for the average temperature differences, and SSMax for the maximum temperature differences. Subjects with the higher left quadrant temperatures than ST were also excluded from the study. Sensitivity, specificity, positive predictive value, and negative predictive value of DITI were calculated.

Totally, 224 volunteers (112 healthy volunteers and 112 patient volunteers) who fulfilled the criteria were enrolled and divided into two groups; control group and patient group. Post-operative pathology was used as a reference standard for AA diagnosis. All of the 112 patients were diagnosed with AA by pathological examination.

Normal distribution of data was evaluated by histogram, q-q graphs, and Shapiro-Wilk test. The homogeneity of variance was tested by the Levene test. Mann-Whitney U test and two independent samples t-test were used for quantitative variables between binary groups. Pearson  $\chi^2$  analysis was used to compare categorical data. Along with maximum, minimum and average temperature variables, receiver operating characteristics (ROC) analysis was used to investigate the status of DITI in diagnosis of appendicitis. The areas under the ROC curve were calculated with 95% confidence interval. The cut-off values for each variable were calculated with Youden index. Sensitivity, specificity, positive predictive value, and negative predictive value for optimal cutoff values were calculated with 95% confidence interval. The data were analyzed by Turcosa Cloud (Turcosa Ltd. Co, Kayseri, Turkey) statistical software. Significance level was accepted at 0.05.

## RESULTS

There were 73 (65.2%) male healthy volunteers, 77 (68.8%) male patients, 39 (34.8%) female healthy volunteers, and 35 (31.3%) female patients. The median age of the healthy subjects was 27 (min 22, max 41) and for patient volunteers, it was 26 (min 19, max 38) ( $p=0.171$ ) (Table 1).

All patient volunteers underwent abdomen US ( $n=112$ ). US revealed AA in 84 (75%) patients and it was unsatisfactory in 28 (25%) patients. Intravenous contrast-enhanced abdomen CT was performed in those. The total number of patients diagnosed with AA on abdomen CT scan was 30 (88.2%). The median diameter of appendix measured on US was 8 mm and it was 8.95 mm on CT scans. The median Alvarado score of the patients was 7 (Table 2).

**Table 1.** Clinical characteristics of volunteers

Variable	Control group (n=112)	Patient group (n=112)	p-value
Age, years, median (min-max)	27.5 (22–41)	26.5 (19–38.75)	0.171
Gender, n (%)			
Male	73 (65.2)	77 (68.8)	0.570
Female	39 (34.8)	35 (31.3)	
Ultrasonography, n (%)			
Supportive of acute appendicitis	–	28 (25)	–
Normal	–	84 (75)	
Computed tomography, n (%)			
Supportive of acute appendicitis	–	4 (11.8)	–
Normal	–	30 (88.2)	
Alvarado score, median (min-max)	–	7 (6–8.8)	–

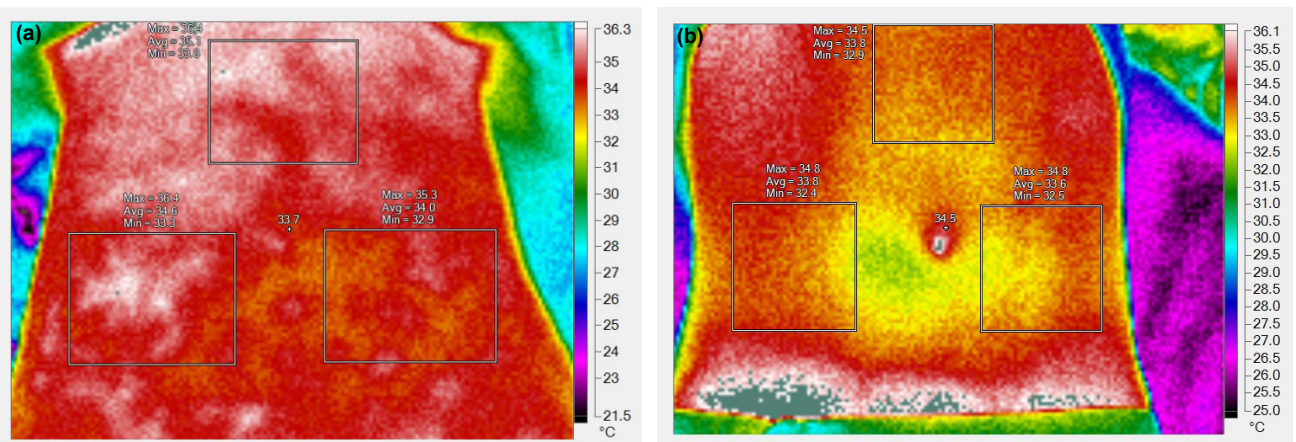
**Table 2.** Comparison of temperature values between the groups

Temperature values	Control group (n=112)	Patient group (n=112)	p-value
Right lower quadrant minimum	33.23±1.54	34.25±1.45	<0.001
Right lower quadrant average	34.19±1.37	35.41±1.27	<0.001
Right lower quadrant maximum	35.18±1.27	36.60±1.17	<0.001
Left lower quadrant minimum	33.16±1.52	33.67±1.50	0.012
Left lower quadrant average	34.12±1.35	34.86±1.32	<0.001
Left lower quadrant maximum	35.17±1.20	36.15±1.22	<0.001
Sternum minimum	33.40±1.48	34.49±1.41	<0.001
Sternum average	34.6 (33.4–35.6)	35.7 (34.7–36.5)	<0.001
Sternum maximum	35.8 (34.9–36.3)	36.6 (35.8–37.3)	<0.001

Values were expressed as either mean±SD or median (IQR 25–75).

When the RLQ, LLQ, and sternal temperature values of the two groups were compared, statistically significant differences were found ( $p<0.001$ ). Regarding temperature differences

between the quadrants, statistical analysis delivered significant difference between the both groups ( $p<0.001$ ) (Fig. 3a and b; Table 3).



**Figure 3.** (a) A thermal image of a patient with acute appendicitis. Square areas on the both lower quadrants show maximum, average and minimum temperatures of the corresponding area. It is clearly seen that there is at least 0.4°C difference between the lower quadrant temperatures. (b) A thermal image of a healthy volunteer showing unremarkable temperature distribution between the lower quadrants.

**Table 3.** Comparison of temperature differences between the groups

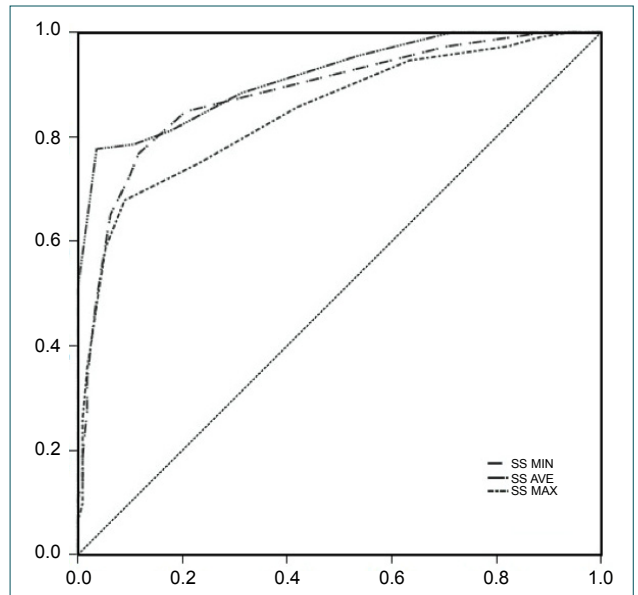
Temperature differences	Control group (n=112)	Patient group (n=112)	p-value
SSMin	0 (-0.1–0.1)	0.5 (0.3–0.8)	<0.001
SSAve	0.1 (-0.1–0.2)	0.6 (0.5–0.7)	<0.001
SSMax	0 (-0.1–0.1)	0.5 (0.1–0.7)	<0.001

Values were expressed as median (IQR 25–75). SSMin: The difference of minimum temperatures between the quadrants, SSAve: The difference of average temperatures between the quadrants, SSMax: The difference of maximum temperatures between the quadrants.

Diagnostic potential of DITI was evaluated by ROC analysis using temperature differences between the quadrants. As a result of the analysis, the cutoff value for the diagnosis of AA was found to be 0.4°C difference for SSAve, 0.2 for SSMax and SSMin (Table 4 and Fig. 4).

### DISCUSSION

Since human body is homoeothermic, there is thought to be thermal symmetry to some degree between both sides of the body.<sup>[9,10]</sup> Because of that, asymmetric temperature changes have attracted many researchers as far back as Hippocrates.<sup>[11]</sup> In this study, we hypothesized that in patients with AA, accompanying inflammation in appendiceal region and peritoneum may be reflected to overlying RLQ skin as locoregional temperature rise and we could detect that change by using a thermal camera. LLQ was taken as a control reference to measure imbalance and to find a reference cutoff value to interpret abdominal thermography appropriately. This study showed clearly that there is alteration in heat signals which was detectable by DITI between RLQ and LLQ of patients with AA. In patients with AA, at least 0.4°C difference between average



**Figure 4.** Graphical demonstration of area under the curve.

temperature values of the lower quadrants delivered highest diagnostic potential with a sensitivity of 77.7% and a specificity of 96.4%. On the other hand, considering calculations in healthy subjects, up to 0.1°C thermal symmetry between the lower quadrants was observed. The data can be used in various clinical scenarios to define abnormal thermal symmetry.

AA is a prevalent disease requiring urgent surgical intervention. The incidence of appendicitis or appendectomy is stabilized in Western Countries but in the newly industrialized countries, it is high.<sup>[12]</sup> For instance, the pooled incidence is 160 (in per 100,000 person-years) in Turkey. Anamnesis and physical examination findings are crucial in the diagnosis. However, these parameters can be unsatisfactory in some cases. Over the years, to help clinicians in suspicious scenarios, more

**Table 4.** Results of receiver operating characteristic and diagnostic potential of DITI

Variable	ROC analysis			Diagnostic statistics	
	AUC	Sensitivity (%)	Specificity (%)	Positive predictive value (%)	Negative predictive value (%)
SSAve>0.4	91.5 (87.1–94.8)	77.7 (68.8–85)	96.4 (91.1–99)	95.6 (89.2–97.3)	81.2 (73.3–94.2)
p-value	<0.001				
SSMax>0.2	84.6 (79.2–89.1)	67.9 (58.4–76.4)	91.1 (84.2–95.6)	88.4 (79.9–92.1)	73.9 (65.3–85.9)
p value	<0.001				
SSMin>0.2	88.3 (83.4–92.2)	76.8 (67.9–84.2)	88.4 (81–93.7)	86.9 (78.7–91.4)	79.2 (70.9–88.1)
p-value	<0.001				

DITI: Digital infrared thermal imaging; ROC: Receiver operating characteristic; AUC: Area under curve. SSMin: The difference of minimum temperatures between the quadrants; SSAve: The difference of average temperatures between the quadrants; SSMax: The difference of maximum temperatures between the quadrants. Statistics were given with 95% confidence interval.

reliable, more practical and less costly methods for the diagnosis of appendicitis have been the subject of research. Today, US and CT are the most common imaging methods used in clinical decision-making process. According to The European Association of Endoscopic Surgery 2015 consensus development conference report, sensitivity, and specificity of US for AA range between 71–94% and 81–98%; and for CT scan, it is 76–100% and 83–100%, respectively.<sup>[13]</sup> In pediatric population and pregnant patients, MRI is an alternative to those. In a meta-analysis, summary sensitivity of MRI was reported to be 97%, specificity 95%, positive likelihood ratio (PLR) 16.3, and negative likelihood ratio (NLR) 0.09.<sup>[14]</sup> Moreover, in an effort to categorize patients and to reduce negative appendectomy rates, clinical scores have been proposed such as Alvarado score.<sup>[6,15]</sup> In the systematic review by Ohle et al.,<sup>[16]</sup> it was shown that Alvarado score has a sensitivity of 96% and specificity of 81%.

Considering the pathophysiology of AA, few studies have been performed based on the idea that there may be increase in skin temperature due to intra-abdominal inflammation. The first example of abdominal thermography in AA was performed by R.J.C. Steele<sup>[17]</sup> in 1986. Forty patients with appendicitis were evaluated by AGA thermovision apparatus (AGA AB, Lidingö, Sweden) using RLQ and LLQ temperatures. RLQ temperature at least 0.5°C warmer than LLQ was considered significant for appendicitis diagnosis. Sensitivity and specificity for abdominal thermography were 62% and 61%, respectively. Several years later, Hambidge evaluated the temperature of RLQ and LLQ skin with thermometer in a prospective controlled study.<sup>[18]</sup> In total, 50 volunteers (25 patients and 25 controls) were enrolled. A difference of 1°C or more was observed in 14 patients. However, in the control group, there was <1°C difference. Hambidge reported sensitivity as 64%, specificity 100%, positive predictive value 100%, and negative predictive value 27%. In another study, Emery and friends examined 86 patients with infrared digital thermometer who admitted to emergency room with RLQ pain.<sup>[19]</sup> They noted the highest temperature of RLQ and LLQ by scanning an area of 6 cm, 1 cm above the skin. They took 1°C difference as a reference cutoff for appendicitis diagnosis. However, only three patients with appendicitis met the criteria.

However, all of those early samples were conducted in the 1980s. In parallel to technological advances, considerable improvement has been made in the capacity of infrared thermal imaging. Furthermore, physiological mechanisms behind thermoregulation are now well understood.<sup>[8]</sup> As a result, DITI has been the focus of many researchers in various clinical scenarios in the last decades. The model in this study was designed in line with Emery et al.'s<sup>[19]</sup> research. RLQ and LLQ temperature values were used to calculate degree of thermal asymmetry. ST served as the control of LLQ peritonitis. RLQ temperatures if at least 0.5°C warmer than LLQ were considered significant for peritonitis due to AA. According to the statistical analysis, this DITI model is highly specific with a PLR of 21.58 and NLR of 0.23 in the AA diagnosis compared to US and

various clinical scoring systems.<sup>[6,7]</sup> MRI seems more valuable with a small difference when NLRs are compared. However, MRI is not cost-effective, widely available and the evaluation require experience.<sup>[13]</sup> One of the most common used imaging techniques in clinical suspicion of AA is CT. Since the introduction of multidetector CT in the late 1990s, the rate of pre-operative application in AA suspicion has increased from 20% to around 90%.<sup>[20,21]</sup> In the large adult cohort of Pickhardt et al.,<sup>[22]</sup> sensitivity, specificity, PLR, and NLR values of multidetector CT were 98.5%, 98%, 51.3, and 0.015, respectively. In spite of highly sensitive and specific detection of AA, radiation exposure of CT is still a concern particularly in children and pregnant patients. Considering advantages and shown potential of DITI, thermal analysis of patients with abdominal pain may serve as an adjunct method to anamnesis and physical examination before advanced imaging methods. Thermal imaging can be performed easily by either surgeons or emergency department physicians. This method can also be useful in emergency departments where ultrasound or CT are not available.

However, some limitations should be noted. There is lack of the previous studies on the topic so that we had to develop a new research protocol. Using area tool on the software, we calculated maximum, average, and minimum temperatures of both lower quadrants and compared among themselves for each patient. Although it is technically difficult to draw an area fulfilling real-time equivalent, we believe alterations caused by two-dimensional calculations are minor and negligible. Another limitation of the study is that healthy volunteers did not undergo laboratory or radiological assessment. Despite they may be at the onset of AA which is not symptomatic, we think this is very unlikely. Even if they were, it is controversial whether laboratory and radiological assessment would give valuable information.

On the other hand, the technique may also raise questions about intra- and inter-observer variability. Whereas measurement of thermal symmetry, which constituted the base for the diagnosis of AA, depends on simple calculations made on thermal software. We believe the procedure is not prone to variability such as US, CT, and MRI since operators will use thermal images to arrive at a simple answer whether there is more than 0.4°C difference between average temperatures of both lower quadrants. In addition, results of thermal analysis in patient volunteers were validated by a gold standard method; pathological examination of operation specimens. Nevertheless, the variability will be clarified in the light of future trials.

## Conclusion

Recent advances in thermal sensors and analysis tools make DITI cameras of today lightweight and user-friendly systems. This study has enlarged the application of DITI to abdominal pain, especially within context of AA. Taking into account high incidence of AA in industrialized countries, DITI evaluation of patients with abdominal pain seems promising. This study is also valuable at providing measures of thermal symmetry for

healthy subjects. The proposed method and the calculated reference values can be re-evaluated using multicenter studies and using high resolution thermal cameras for diagnosis of abdominal pathology.

**Ethics Committee Approval:** This study was approved by the Erciyes University Research Ethics Committee (Date: 22.12.2017, Decision No: 2017/598).

**Peer-review:** Internally peer-reviewed.

**Authorship Contributions:** Concept: T.S., T.E.; Design: T.S., T.E.; Supervision: T.S., T.E.; Resource: T.S., T.E.; Materials: T.S., T.E.; Data: U.A., Ö.T.; Analysis: U.A.; Literature search: U.A., T.S., T.E.; Writing: U.A., T.S., T.E.; Critical revision: T.S., T.E., Ö.T.

**Conflict of Interest:** None declared.

**Financial Disclosure:** The authors declared that this study has received no financial support.

## REFERENCES

1. Stewart B, Khanduri P, McCord C, Ohene-Yeboah M, Uranues S, Vega Rivera F, et al. Global disease burden of conditions requiring emergency surgery. *Br J Surg* 2014;101:e9–22. [CrossRef]
2. Bhangu A, Soreide K, Di Saverio S, Assarsson JH, Drake FT. Acute appendicitis: Modern understanding of pathogenesis, diagnosis, and management. *Lancet* 2015;386:1278–87. [CrossRef]
3. Carr NJ. The pathology of acute appendicitis. *Ann Diagn Pathol* 2000;4:46–58. [CrossRef]
4. Drake FT, Flum DR. Improvement in the diagnosis of appendicitis. *Adv Surg* 2013;47:299–328. [CrossRef]
5. Neumayer L, Kennedy A. Imaging in appendicitis: A review with special emphasis on the treatment of women. *Obstet Gynecol* 2003;102:1404–9.
6. Yu YR, Shah SR. Can the diagnosis of appendicitis be made without a computed tomography scan? *Adv Surg* 2017;51:11–28. [CrossRef]
7. Giljaca V, Nadarevic T, Poropat G, Nadarevic VS, Stimac D. Diagnostic accuracy of abdominal ultrasound for diagnosis of acute appendicitis: Systematic review and meta-analysis. *World J Surg* 2017;41:693–700.
8. Ring EF, Ammer K. Infrared thermal imaging in medicine. *Physiol Meas* 2012;33:R33–46. [CrossRef]
9. Mercer JB, de Weerd L. Thermography and Thermal Symmetry. United States: IEEE International Symposium on Medical Measurements and Applications (eMeA); 2014. p. 1–3. [CrossRef]
10. Zaproudina N, Varmavuo V, Airaksinen O, Narhi M. Reproducibility of infrared thermography measurements in healthy individuals. *Physiol Meas* 2008;29:515–24. [CrossRef]
11. Uematsu S, Edwin DH, Jankel WR, Kozikowski J, Trattner M. Quantification of thermal asymmetry. Part 1: Normal values and reproducibility. *J Neurosurg* 1988;69:552–5. [CrossRef]
12. Ferris M, Quan S, Kaplan BS, Molodecky N, Ball CG, Chernoff GW, et al. The global incidence of appendicitis: A systematic review of population-based studies. *Ann Surg* 2017;266:237–41. [CrossRef]
13. Gorter RR, Eker HH, Gorter-Stam MA, Abis GS, Acharya A, Ankersmit M, et al. Diagnosis and management of acute appendicitis. EAES consensus development conference 2015. *Surg Endosc* 2016;30:4668–90. [CrossRef]
14. Barger RL Jr., Nandalur KR. Diagnostic performance of magnetic resonance imaging in the detection of appendicitis in adults: A meta-analysis. *Acad Radiol* 2010;17:1211–6. [CrossRef]
15. Alvarado A. A practical score for the early diagnosis of acute appendicitis. *Ann Emerg Med* 1986;15:557–64. [CrossRef]
16. Ohle R, O'Reilly F, O'Brien KK, Fahey T, Dimitrov BD. The alvarado score for predicting acute appendicitis: A systematic review. *BMC Med* 2011;9:139. [CrossRef]
17. Steele RJ. Abdominal thermography in acute appendicitis. *Scott Med J* 1986;31:229–30. [CrossRef]
18. Hambidge JE. Use of skin thermometer to diagnose acute appendicitis. *BMJ* 1990;300:722. [CrossRef]
19. Emery M, Jones J, Brown M. Clinical application of infrared thermography in the diagnosis of appendicitis. *Am J Emerg Med* 1994;12:48–50.
20. Raman SS, Osuagwu FC, Kadell B, Cryer H, Sayre J, Lu DS. Effect of CT on false positive diagnosis of appendicitis and perforation. *N Engl J Med* 2008;358:972–3. [CrossRef]
21. Coursey CA, Nelson RC, Patel MB, Cochran C, Dodd LG, DeLong DM, et al. Making the diagnosis of acute appendicitis: Do more preoperative CT scans mean fewer negative appendectomies? A 10-year study. *Radiology* 2010;254:460–8. [CrossRef]
22. Pickhardt PJ, Lawrence EM, Pooler BD, Bruce RJ. Diagnostic performance of multidetector computed tomography for suspected acute appendicitis. *Ann Intern Med* 2011;154:789–96. [CrossRef]

## ORJİNAL ÇALIŞMA - ÖZ

### Akut apandisit tanısında dijital kızılötesi termal görüntülemenin rolü

Dr. Uğur Aydemir,<sup>1</sup> Dr. Talha Sarıgöz,<sup>2</sup> Dr. Tamer Ertan,<sup>3</sup> Dr. Ömer Topuz<sup>3</sup>

<sup>1</sup>Aksaray Devlet Hastanesi, Genel Cerrahi Kliniği, Aksaray

<sup>2</sup>Kayseri Şehir Hastanesi, Genel Cerrahi Kliniği, Kayseri

<sup>3</sup>Sağlık Bilimleri Üniversitesi, Genel Cerrahi Anabilim Dalı, Kayseri

**AMAÇ:** Akut apandisit, acil cerrahi gerektiren en yaygın hastalıklardan biridir. Günümüzde akut apandisit tanısı öykü, fizik muayene ve ileri görüntüleme yöntemleri ile konmaktadır. Termal görüntüleme geleneksel tekniklerine göre, taşınabilir olması, invaziv olmaması, kolayca yapılabilir olması, iyonizasyon radyasyon içermemesi ve ucuz olması gibi avantajlar sağlar. Dijital kızılötesi termal görüntüleme çeşitli klinik çalışmalara araştırma konusu olmuştur. Bu ileriye yönelik randomize kontrollü çalışmada, akut apandisitte dijital kızılötesi termal görüntülemenin tanısal potansiyeli araştırıldı.

**GEREÇ VE YÖNTEM:** Toplam 224 gönüllü (112 sağlıklı gönüllü, 112 hasta gönüllü) kontrol grubu ve hasta grubu olmak üzere iki gruba ayrıldı. Tüm olgular dijital kızılötesi termal görüntüleme ile değerlendirildi. Hem alt kadrانların hem de sternumun görüntüleri alındı. Termal görüntüler bilgisayar yazılımına aktarıldı ve analiz edildi. Tanısal yöntem olarak termal görüntülemenin potansiyeli değerlendirildi.

**BULGULAR:** Kadrانlar arasındaki sıcaklık farklarına ilişkin olarak, istatistiksel analiz, her iki grup arasında anlamlı farklılık göstermiştir ( $p < 0.001$ ). Analiz sonucunda, akut apandisit tanısı için kesim değerinin, ortalama alt kadrان sıcaklıkları arasında  $0.4^{\circ}\text{C}$  fark olduğu bulunmuştur.

**TARTIŞMA:** Bu çalışma, özellikle akut apandisit bağlamında, karın ağrısında dijital kızılötesi termal görüntülemenin uygulanmasını genişletmiştir.

**Anahtar sözcükler:** Akut karın; apandisit; termal görüntüleme.

Ulus Travma Acil Cerrahi Derg 2021;27(6):647-653 doi: 10.14744/tjtes.2020.80843