



Delayed diagnosis of traumatic diaphragmatic rupture with herniation of the liver: a case report

Travmatik diyafragma rüptürüne eşlik eden karaciğer fitiklaşmasında gecikmiş tanı: Olgu sunumu

**Anand KUPPUSAMY, Gayathri RAMANATHAN, Jayakar GURUSAMY,
Balaji RAMAMOORTHY, Karunanithi PARASAKTHI**

Diaphragmatic rupture is a potentially life-threatening clinical situation. It occurs as a result of high-velocity blunt or penetrating injury to the abdomen and thorax. Acute traumatic rupture of the diaphragm may go undetected, and there is often a delay between the injury and diagnosis. Right-sided rupture is less common due to hepatic protection and increased strength of the right hemidiaphragm. We report the case of a 28-year-old man who was admitted with breathlessness to our hospital, 72 hours after trauma. Since clinical signs and symptoms were non-specific, helical computed tomography was done, which revealed diaphragmatic rupture with hepatothorax. Emergency thoracotomy was done to repair diaphragmatic rent. The postoperative period was uneventful, and the patient was discharged three weeks later.

Key Words: Acquired diaphragmatic hernia; diaphragmatic rupture; trauma.

Diyafram yırtığı potansiyel olarak yaşamı tehdit eden bir klinik durumdur. Karın ve göğüse yönelik yüksek basınçlı künt veya penetran yaralanmanın bir sonucu olarak oluşmaktadır. Diyaframın akut travmatik yırtığı, gözden kaçırılabilir ve yaralanma ile tanı arasında sıklıkla gecikme bulunur. Hepatik koruma ve sağ hemidiyafragmaya ilişkin artmış direnç nedeniyle, sağ taraflı yırtık daha az yaygındır. Bu yazıda, travmadan 72 saat sonra nefes darlığı yakınması ile hastanemize yatırılan 28 yaşındaki bir erkek olgu sunuldu. Klinik bulgu ve semptomların spesifik olmaması nedeniyle, hastanın helikal bilgisayarlı tomografisi çekildi; görüntüleme hepatotoraksla birlikte diyafram yırtığı bulunduğunu gösterdi. Diyafram yırtığını onarmak üzere acil torakotomi yapıldı. Ameliyat sonrası sorunsuz geçti ve hasta üç hafta sonra taburcu edildi.

Anahtar Sözcükler: Edinsel diyaframatik fitik; diyafram yırtığı; travma.

The incidence of diaphragmatic rupture after thoraco-abdominal traumas is 0.8-5%.^[1] Trauma can cause sudden increase in the intra-abdominal pressure, resulting in diaphragmatic tear and visceral herniation. Due to coexisting injuries and the silent nature of diaphragmatic ruptures, the diagnosis can sometimes be missed in the acute phase, and may present later with obstructive symptoms due to incarcerated organs in the diaphragmatic defect. A systematic review of the literature by Rashid et al.^[1] revealed 13 cases of right-sided diaphragmatic rupture, while herniation of the liver occurred in only six cases.^[2-7]

This case report discusses an adult patient who was diagnosed to have right-sided diaphragmatic rupture and hepatothorax three days after the trauma.

CASE REPORT

A 28-year-old male was admitted to our hospital three days following a motor vehicle accident. He was initially admitted to another hospital, and the trauma survey revealed no abnormality other than a fractured left tibia. After routine preoperative investigations, he was operated and external fixators were applied. He was clinically normal for the first two days postopera-

tively, after which he developed breathlessness. He was then referred to our hospital for further management.

On admission, the patient had dyspnea and tachypnea (respiratory rate 30/minute) and saturation in room air was 92%. The clinical examination revealed no obvious external injury to the abdomen or thorax. The trachea was found to be in midline, and air entry was diminished in the right lower zone on auscultation. Repeat chest radiograph showed grossly elevated right hemidiaphragm (Fig. 1) compared to the chest radiograph taken immediately after the trauma, which showed only a slight elevation. Arterial blood analysis revealed respiratory alkalosis with mild hypoxemia. Differential diagnosis of hemothorax, pulmonary thromboembolism, pulmonary contusion, basal atelectasis, and collapse of the right lower lobe were considered. A computed tomographic (CT) scan was done, which showed discontinuity of the right diaphragm, presence of the liver in the right paracardiac

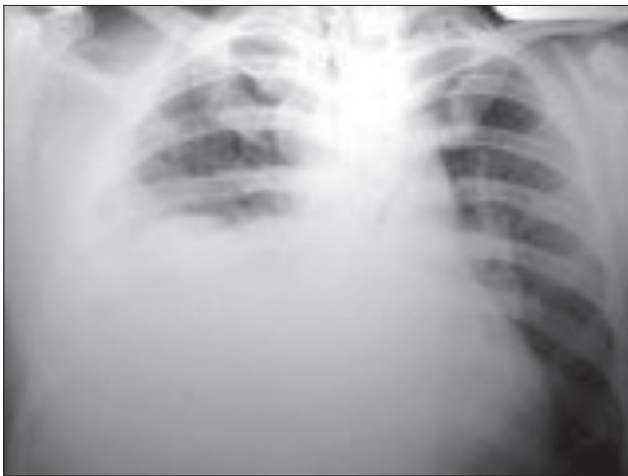

Fig. 1. Chest radiograph showing gross elevation of the right hemidiaphragm.

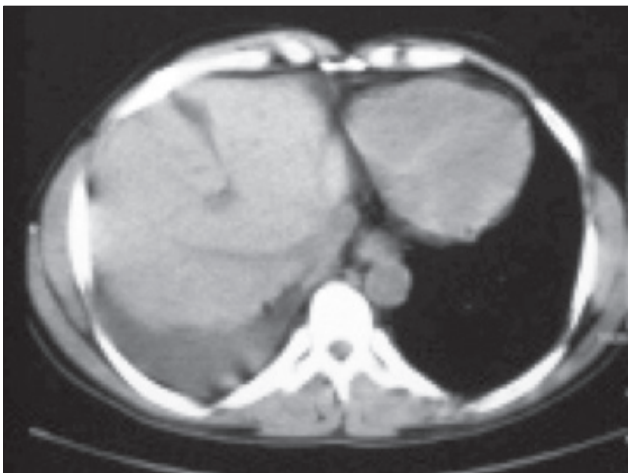


Fig. 2. Computed tomogram showing discontinuity of the right hemidiaphragm, minimal liver laceration and presence of the liver in the paracardiac region.

region, a highly placed liver-hilar level, elevated right diaphragmatic crus, and minimal fluid in the pleural cavity (Fig. 2). Hence, the diagnosis of diaphragmatic rupture with herniation of the liver was made, and emergency thoracotomy with repair of diaphragm was planned.

The patient was premedicated with ranitidine 50 mg injection and metoclopramide 10 mg injection. After placement of standard minimum monitoring devices [ECG, SpO₂, noninvasive blood pressure [NIBP], capnography] and administration of fentanyl 150 mcg injection, rapid sequence induction was done with thiopentone sodium 5 mg/kg and rocuronium 0.9 mg/kg. The airway was secured with a single lumen endotracheal tube, the patient was positioned in the left lateral position, and right thoracotomy was done through the fifth intercostal space. Anesthesia was maintained with N₂O, O₂ and propofol infusion. Intraoperatively, the patient's right lung was retracted for 30 minutes, during which N₂O, O₂ ratio was adjusted to maintain oxygen saturation above 95%. The liver was replaced in the abdominal cavity and diaphragmatic rent was repaired. The patient was electively ventilated for 12 hours postoperatively and extubated. Postoperative chest radiograph did not reveal any residual abnormality. The postoperative stay was uneventful, and the patient was discharged after three weeks.

DISCUSSION

The diaphragm is the major muscle of respiration and separates the thorax from the abdominal cavity. Diaphragmatic hernias can be divided into two categories, namely congenital and acquired. Congenital diaphragmatic hernia occurs due to embryological defects in the diaphragm. Blunt injury accounts for 74% of acquired hernias, and penetrating injury for the rest. Blunt trauma to the abdomen increases the trans-diaphragmatic pressure gradient between the abdominal compartment and the thorax. This causes shearing of a stretched membrane and avulsion of the diaphragm from its points of attachments due to sudden increase in intra-abdominal pressure. The liver, stomach, colon, and spleen are the commonly herniated organs. Due to coexisting injuries and the silent nature of diaphragmatic ruptures, the diagnosis can sometimes be missed in the acute phase, and may present later with obstructive symptoms due to incarcerated organs in the diaphragmatic defect or eventual strangulation. The common clinical presentations of diaphragmatic rupture include breathlessness, vague chest pain and bowel obstruction. Conventional imaging modalities may miss the diagnosis, especially on the right side, in up to 40% of cases. Although chest radiograph is recommended for all patients after major trauma, chest radiograph is insensitive in depicting diaphragmatic rupture, with a sensitivity of 46% for

left-sided ruptures and 17% for right-sided ruptures.^[8] CT of the chest is the imaging modality of choice in the evaluation of severe blunt abdominal trauma. Helical CT has been described as a more sensitive diagnostic technique than routine axial CT slices.^[9] The signs of diaphragmatic rupture on CT of the chest include discontinuity of the diaphragm, visceral herniation, waist-like constriction of the bowel (collar sign), a highly placed liver-hilar level, elevation of the right diaphragmatic crus, and dependent viscera sign.^[10]

Diaphragmatic rupture is often associated with other solid organ injuries and fracture of bones. Due to these coexisting injuries, diagnosis can sometimes be missed in the acute phase and may present later with obstructive symptoms due to incarcerated organs in the diaphragmatic defect. The duration of delay in the diagnosis of diaphragmatic rupture after trauma varies from a few days to as long as 50 years. The surgical treatment usually performed includes hernia reduction, pleural drainage and repair of the diaphragmatic defect. This may be performed either through an open laparotomy/thoracotomy or through laparoscopy/thoracoscopy. Conventionally, delayed cases are approached through the thorax because of the presence of adhesions between the abdominal viscera and thoracic structures.

To conclude, even though diaphragmatic rupture is difficult to diagnose in trauma patients, a high index of suspicion with appropriate use of radiological modalities helps in reaching a correct diagnosis. Surgical repair should be done as quickly as possible to reduce morbidity and mortality.

REFERENCES

1. Rashid F, Chakrabarty MM, Singh R, Iftikhar SY. A review on delayed presentation of diaphragmatic rupture. *World J Emerg Surg* 2009;4:32. [CrossRef](#)
2. Kozak O, Menten O, Harlak A, Yigit T, Kilbas Z, Aslan I, et al. Late presentation of blunt right diaphragmatic rupture (hepatic hernia). *Am J Emerg Med* 2008;26:638.e3-5.
3. Igai H, Yokomise H, Kumagai K, Yamashita S, Kawakita K, Kuroda Y. Delayed hepatothorax due to right-sided traumatic diaphragmatic rupture. *Gen Thorac Cardiovasc Surg* 2007;55:434-6. [CrossRef](#)
4. Launey Y, Geeraerts T, Martin L, Duranteau J. Delayed traumatic right diaphragmatic rupture. *Anesth Analg* 2007;104:224-5. [CrossRef](#)
5. Jabłoński S, Wcisło ES, Wawrzycki M, Misiak P, Kordiak J. Posttraumatic rupture of diaphragm with projection of the liver into the right pleural cavity-the case description. *Pol Merkur Lekarski* 2009;26:478-82.
6. Disler DG, Deluca SA. Traumatic rupture of the diaphragm and herniation of the liver. *Am Fam Physician* 1992;46:453-6.
7. Petrakis IE, Prokopakis G, Raissaki M, Zacharioudakis G, Kogerakis N, Chalkiadakis G. Delayed diagnosis of a blunt rupture of the right hemidiaphragm with complete dislocation of the right hepatic lobe and the small bowel in the chest. *J Trauma* 2003;55:180. [CrossRef](#)
8. Gelman R, Mirvis SE, Gens D. Diaphragmatic rupture due to blunt trauma: sensitivity of plain chest radiographs. *AJR Am J Roentgenol* 1991;156:51-7.
9. Killeen KL, Mirvis SE, Shanmuganathan K. Helical CT of diaphragmatic rupture caused by blunt trauma. *AJR Am J Roentgenol* 1999;173:1611-6.
10. Bergin D, Ennis R, Keogh C, Fenlon HM, Murray JG. The "dependent viscera" sign in CT diagnosis of blunt traumatic diaphragmatic rupture. *AJR Am J Roentgenol* 2001;177:1137-40.