

# Rare cecum pathologies as a cause of acute abdomen in children

Ali İhsan Anadoluğlu, M.D.,<sup>1</sup> Gonca Gerçel, M.D.,<sup>2</sup> Osman Hakan Kocaman, M.D.<sup>3</sup>

<sup>1</sup>Department of Pediatric Surgery, Mehmet Akif İnan Training and Research Hospital, Şanlıurfa-Turkey

<sup>2</sup>Department of Pediatric Surgery, Şanlıurfa Training and Research Hospital, Şanlıurfa-Turkey

<sup>3</sup>Department of Pediatric Surgery, Harran University Faculty of Medicine, Şanlıurfa-Turkey

## ABSTRACT

**BACKGROUND:** We aimed to present cecum pathologies which are the cause of acute abdomen.

**METHODS:** Between January 2015 and June 2019, patients that were operated with the diagnosis of acute abdomen and patients with the primary cecum pathologies were evaluated retrospectively.

**RESULTS:** There were eight patients, five males and three females. The mean age was  $7.2 \pm 2.9$  years. Complaints were abdominal pain and vomiting in all patients. Physical examination was consistent with acute abdomen. In the imaging studies, the preliminary diagnosis was considered as two patients had acute appendicitis, two had invagination (one due to Meckel diverticulum and one with mesenteric cyst), two had ileus, one had perforated appendicitis, and one had cecum diverticulum. In surgery, five patients had cecum mass, one had cecum diverticulitis, one had cecum volvulus, and one had inflamed necrotic cecum. All patients underwent cecum resection and ileocolonic anastomosis. Histopathologic examination was resulted as Burkitt's lymphoma in three patients, cecum diverticulum in two, duplication of cecum in one, tuberculosis of cecum in one, and gangrenous necrosis due to volvulus in one patient. The mean follow-up period was 25 months (2 months–4 years). Follow-up was uneventful.

**CONCLUSION:** Primary cecum pathologies are very rare. This leads to lack of standardization in treatment planning. Considering the patients with malignancy in the series, ileocolonic anastomosis with cecum resection is an adequate and appropriate treatment option in children with primary cecum pathology.

**Keywords:** Acute abdomen; cecum pathologies; children; rare.

## INTRODUCTION

Acute abdominal pain is one of the most frequent causes of emergency service applications in children. However, the diagnostics and treatment can be challenging. Although appendicitis, intussusception, and Meckel diverticulum are frequent, there are also some rare causes of abdominal pain that requires surgical intervention.

Primary cecum pathologies such as cecal duplications, diverticulitis, volvulus, and malignancies of cecum are very rare in children. Their incidence is unknown and existing literature only consists of case reports and small case series.<sup>[1-3]</sup> For this

reason, the correct pre-operative diagnosis is rarely made, and the surgeon is often confronted with this condition at the time of laparotomy.

In this study, we aimed to analyze patients with primary cecum pathologies that were incidentally encountered intraoperatively in the differential diagnosis of acute abdomen.

## MATERIALS AND METHODS

The medical records of patients with primary cecum pathologies operated for pre-operative diagnosis of acute abdomen between January 2015 and June 2019 were evaluated

Cite this article as: Anadoluğlu AI, Gerçel G, Kocaman OH. Rare cecum pathologies as a cause of acute abdomen in children. *Ulus Travma Acil Cerrahi Derg* 2022;28:249-253.

Address for correspondence: Gonca Gerçel, M.D.

Şanlıurfa Eğitim ve Araştırma Hastanesi, Çocuk Cerrahisi Kliniği, Şanlıurfa, Turkey

Tel: +90 414 - 317 17 17 E-mail: goncagercel@gmail.com

*Ulus Travma Acil Cerrahi Derg* 2022;28(3):249-253 DOI: 10.14744/tjtes.2020.79357 Submitted: 17.07.2020 Accepted: 01.12.2020

Copyright 2022 Turkish Association of Trauma and Emergency Surgery



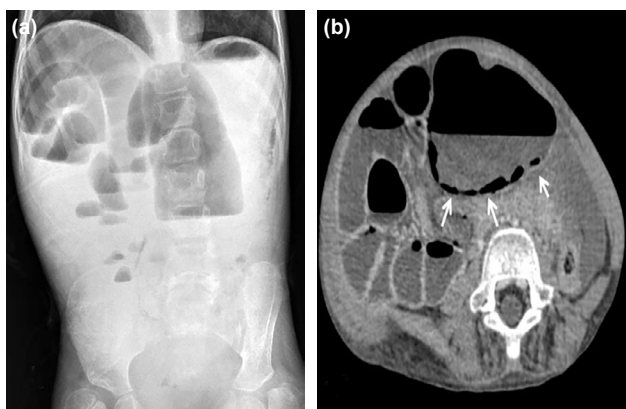
retrospectively. The demographic information, pre-operative assessments, operative details, pathology results, and outcomes were extracted from the electronic medical records and analyzed.

All procedures performed were in accordance with the ethical standards of the responsible committee on human experimentation (institutional and national) and with the Helsinki Declaration of 1964 and later versions. This study was approved by the Institutional Review Board of Harran University (approval number 2019/E51854) and written informed consent for surgery was obtained from all patients.

**RESULTS**

There were eight patients, five males and three females. The mean age was 7.2±2.9 years. Complaints were abdominal pain and vomiting in all patients. Physical examination was consistent with acute abdomen. Direct abdominal X-ray was performed in all patients, ultrasonography (USG) was done in three patients, computed tomography (CT) was performed in three patients, and USG and CT in two patients. In the imaging studies, the preliminary diagnosis was considered as acute appendicitis in two patients, intussusception in two patients (one due to Meckel’s diverticulum and one with mesenteric cyst), ileus in two patients (Fig. 1), perforated appendicitis in one, and cecum diverticulum in one patient.

In surgery, five patients had cecum mass. In one of the two patients with a pre-diagnosis of intussusception, ultrasonographic examination revealed a 5×3 cm cystic lesion in the left lower quadrant and intussusception was detected in the neighborhood of the cystic lesion. Abdominal CT was performed due to the unusual localization of the lesion. Mesenteric cyst and associated long-segment intussusception was thought on CT (Fig. 2). The intussusception could not be reduced by the hydrostatic method. On laparotomy, it was seen that the cecum was replaced to the left quadrant and there was ileocolonic intussusception. Treitz was in a nor-

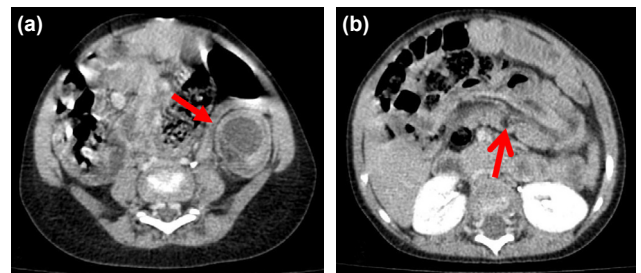


**Figure 1.** View of air-fluid levels on direct X-ray (a) and dilated bowel loops and intramural air (arrows) on CT (b), in the patient with cecum volvulus. CT: Computed tomography.

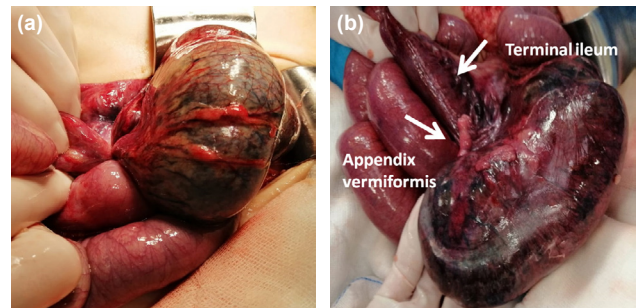
mal position. After manual reduction of the intussusception, a globe-shaped mass was palpable in the cecum.

In one of the other three patients had cecum diverticulitis, one had cecum volvulus and one had inflamed lytic cecum (Table 1, Figs. 3 and 4). All patients underwent cecum resection and ileocolonic anastomosis.

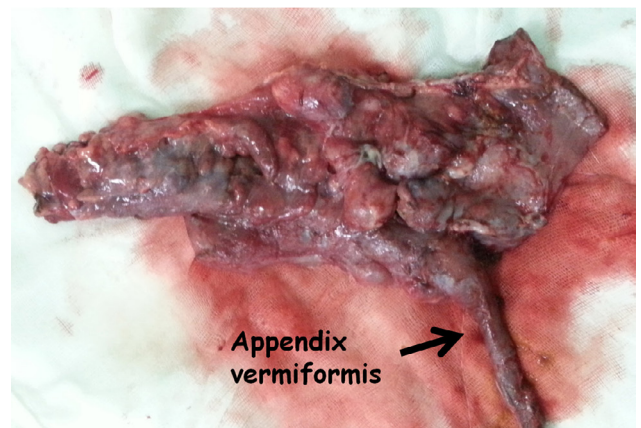
Histopathologic examination was resulted as Burkitt’s lymphoma in three patients, cecum diverticulum in two patients, duplication of cecum in one patient, tuberculosis of cecum in one, and gangrenous necrosis due to volvulus in one patient (Fig. 5). The mean follow-up period was 25 months (2 months–4 years). Follow-up was uneventful. No recurrence was detected in the patients with lymphoma in the follow-up period.



**Figure 2.** The patient was pre-diagnosed with intussusception due to mesenteric cyst; left lower quadrant cystic lesion (arrow) (a), adjacent to long-segment intussusception (arrow) (b).



**Figure 3.** Cecum in gangrenous appearance; torsion (a), detorsion (b) cecum.



**Figure 4.** Inflamed lytic cecum due to tuberculosis.

**Table 1.** Demographics, clinical presentation, intraoperative and final diagnosis

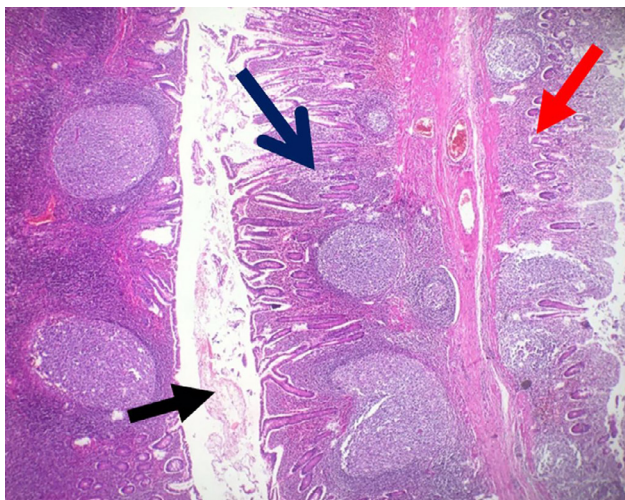
Case	Gender	Age at diagnosis (year)	Clinical presentation	US and/or CT findings	Intraoperative finding	Histopathological finding
1	Female	1	Abdominal pain, vomiting	Intussusception (due to mesenteric cyst)	Mobile cecum, ileocolonic intussusception, cecum mass	Cecum duplication
2	Male	6	Abdominal pain, vomiting	Acute appendicitis	Cecum mass	Burkitt's lymphoma
3	Male	7	Abdominal pain, vomiting	Ileus	Cecum mass	Burkitt's lymphoma
4	Male	8	Abdominal pain, vomiting	Acute appendicitis	Cecum mass	Burkitt's lymphoma
5	Female	8	Abdominal pain, vomiting	Cecum diverticulitis	Cecum diverticulitis	Cecum diverticulitis
6	Male	8	Abdominal pain, vomiting	Intussusception (due to Meckel's diverticulum)	Cecum mass	Cecum diverticulitis
7	Male	9	Abdominal pain, vomiting	Perforated appendicitis	Inflamed lytic cecum	Cecum tuberculosis
8	Female	11	Abdominal pain, vomiting	Ileus	Cecal volvulus	Gangrenous necrosis (due to volvulus)

CT: Computed tomography; US: Ultrasonography.

## DISCUSSION

Primary cecal pathologies presenting as acute abdomen often pose a challenge to their optimal management due to the requirement of urgent intervention mostly with misdiagnosis.<sup>[4]</sup> These pathologies are commonly misdiagnosed as they often mimic acute appendicitis. Surgeons may encounter unexpected pathologies during surgery due to pre-operative misdiagnosis and that may increase mortality and morbidity, and sometimes lead to unnecessary surgical procedures as there is no standard treatment. Hence, accurate identification of a primary cecal pathology is required so that it can be optimally managed and patient outcome can be improved.

The incidence of cecal diverticulitis is approximately 0.8% in adult population with a pre-operative diagnosis of ap-



**Figure 5.** Diverticular formation in cecum, cecum wall structure (blue arrow), cecum lumen (black arrow), and diverticular wall structure (red arrow).

pendicitis.<sup>[5]</sup> However, the incidence in pediatric patients is unknown since there is no reported pediatric series. In this study, we present two cases of cecal diverticulitis. Both of the patients presented to the emergency department with acute abdomen. In one of the patients, an experienced radiologist evaluated the appendix vermiformis as normal and with a preliminary diagnosis of cecum diverticulitis. Abdominal CT of the other patient revealed a target sign consistent with intussusception which was thought to be due to Meckel's diverticulum in the right quadrant. The patient underwent surgery with the diagnosis of acute abdomen. There was no intussusception in exploration. No pathology was detected in small bowel segments. The appendix vermiformis was normal. Mesentery had extensive enlarged lymph nodes. On palpation of a mass lesion on the cecum wall, the cecum was excised with a preliminary diagnosis of malignancy. Histopathological examination was consistent with solitary diverticulum in the cecum. Seventeen benign lymph nodes were detected in the pathology specimen.

The treatment of cecal diverticulum is controversial. The treatment options of cecum diverticulum vary from conservative treatment to simple diverticulectomy or cecum resection to right hemicolectomy.<sup>[6-8]</sup> The diagnosis of cecal diverticulitis is even difficult during operative exploration. Cecal diverticulitis is correctly identified intraoperatively at a rate of only 60–85%.<sup>[9-11]</sup> This is due to the presence of a surrounding phlegmon and cecal wall thickening, which leads to suspicion of malignancy. As in the present case, cecum resection was performed due to cecal wall thickening and a palpable inflammatory mass.

Cecal volvulus is a life-threatening, surgical emergency. It is mostly seen in the elderly and rarely reported in the pediatric age group.<sup>[1,12,13]</sup> It is known to be seen more frequently in



patients with mental disabilities.<sup>[14,15]</sup> Abdominal pain, nausea, and distention are the most common presenting complaints. Unfortunately, in younger or in neurologically impaired children, it is challenging to determine these subtle symptoms. The physical examination finding of abdominal tenderness by palpation is seen in advanced volvulus complicated by intestinal ischemia or perforation. In this study, we present an 11-year-old girl with cerebral palsy with severe developmental delay whom had vomiting, abdominal distention, and severe tenderness.

Both plain films and CT were the most commonly employed diagnostic modalities in cecal volvulus. CT is superior to plain graphics in diagnosis. However, while CT is commonly utilized and sensitive in diagnosing adult volvulus, the same efficacy has not been shown in children previously.<sup>[13]</sup> In the present case, USG and abdominal CT were unremarkable except the extensive free fluid in the abdomen, dilated bowel loops, and presence of intramural free air in intestinal segments. The patient was taken into operation with the diagnosis of acute abdomen. It was found that the cecum had torsion around itself and gangrenous appearance. The cecum was resected and ileocolonic anastomosis was performed.

Detorsion with cecopexy or resection and an end-to-end anastomosis are the suggested treatment options in cecal volvulus.<sup>[16]</sup> As the present patient, cecum resected as the cecum was gangrenous. The rarity of the condition frequently leads to diagnostic delays and complications. Therefore, keeping the cecal volvulus in mind in patients with cerebral palsy presenting with bowel obstruction and without previous surgical history may allow early diagnosis and reduce mortality and morbidity.

Duplications of the alimentary tract are relatively rare developmental anomalies that can occur anywhere from the mouth to the anus. However, cecal duplication is extremely rare with a reported incidence of 0.4%.<sup>[17]</sup> In the literature, there are reports that cecum duplication may mimic intussusception.<sup>[18,19]</sup> In this study, we present a case of a 1-year-old female child with duplication of cecum who presented to our institution with the left side intussusception. When the patient was operated with a preliminary diagnosis of intussusception due to mesenteric cyst, in laparotomy, it was seen that cecum was located on the left side and a mass lesion on the cecum wall caused intussusception. We thought that this is the first report of cecal duplication-induced ileocolonic intussusception in mobile cecum syndrome in the literature. Although it is seen very rarely, ileocecal duplication cysts should be kept in mind in patients who admitted with intussusception and intra-abdominal cystic lesion.

Childhood cancer is rare. Lymphoma is the third most common childhood malignancy after leukemia and central nervous system tumors.<sup>[20]</sup> Although mostly children can have the classical symptoms of fevers, night sweats, and weight

loss, patients with gastrointestinal involvement of lymphoma may present with different clinical manifestations. In this report, we present three cases of Burkitt's lymphoma who underwent surgery with the preliminary diagnosis of acute appendicitis in two of them and one with the diagnosis of ileus. During surgery, there was palpable mass lesion in the cecum in all three patients and underwent resection and anastomosis with a preliminary diagnosis of malignancy. Chemotherapy was administered following resection in all of patients. No recurrence was detected in any of the patients in the follow-up period. We recommend that patients with colorectal lymphoma be treated with surgical resection with clean surgical margins and adjuvant chemotherapy.

Tuberculosis remains a serious problem in the developing countries and among immigrant communities.<sup>[21]</sup> However, the diagnosis of extrapulmonary tuberculosis is quite difficult and can be missed in differential diagnosis. Surgical treatment in abdominal tuberculosis can often be used to alleviate the persistent intestinal symptoms or in acute situations during medical treatment.<sup>[22]</sup> Sometimes, the first presentation may present with signs of peritonitis mimicking appendicitis as in our patient. The patient presented in this study was operated with a pre-diagnosis of perforated appendicitis and a lytic cecum was encountered in the operation. Although the diagnosis of tuberculosis was considered during surgery, inflammatory bowel disease could not be ruled out. Because the cecum was very fragile, the cecum was excised and ileocolonic anastomosis was performed from the normal bowel tissue borders. Although early diagnosis and medical treatment of tuberculosis is possible, abdominal tuberculosis can be seen in many different presentations in regions with low socioeconomic status and surgical treatment may be needed more.

## Conclusion

Primary cecum pathologies are very rare. However, as in this presented series, pre-operative diagnostic difficulties may cause the surgeon to encounter unexpected pathologies during surgery. This leads to lack of standardization in treatment planning. Considering the patients with malignancy in the series, ileocolonic anastomosis with cecum resection is an adequate and appropriate treatment option in children with primary cecum pathology.

**Ethics Committee Approval:** This study was approved by the Harran University Faculty of Medicine Ethics Committee (Date: 18.11.2019, Decision No: 2019/E51854).

**Peer-review:** Internally peer-reviewed.

**Authorship Contributions:** Concept: A.İ.A.; Design: A.İ.A.; Supervision: A.İ.A.; Resource: A.İ.A., G.G., O.H.K.; Data: A.İ.A., G.G., O.H.K.; Analysis: A.İ.A., G.G., O.H.K.; Literature search: A.İ.A., G.G., O.H.K.; Writing: A.İ.A., G.G., O.H.K.; Critical revision: A.İ.A., G.G., O.H.K.

**Conflict of Interest:** None declared.

**Financial Disclosure:** The authors declared that this study has received no financial support.

## REFERENCES

1. Samuel M, Boddy SA, Nicholls E, Capps S. Large bowel volvulus in childhood. *Aust N Z J Surg* 2000;70:258–62. [CrossRef]
2. Verma S, Bawa M, Rao KL, Sodhi KS. Caecal duplication cyst mimicking intussusception. *BMJ Case Rep* 2013;2013:bcr2012008056. [CrossRef]
3. Martens T, Fierens K. Giant cecal diverticulum in a child. *J Pediatr Surg* 2011;46:23–5. [CrossRef]
4. Bassiouny RH, El Maati AA. Acute right lower quadrant pain beyond acute appendicitis: MDCT in evaluation of benign and malignant gastrointestinal causes. *Egypt J Radiol Nucl Med* 2014;45:627–40. [CrossRef]
5. Poon RT, Chu KW. Inflammatory cecal masses in patients presenting with appendicitis. *World J Surg* 1999;23:713–16. [CrossRef]
6. Huntington JT, Brigode W, Thakkar RK, Raval MV, Teich S. A case of pediatric cecal diverticulitis mimicking acute appendicitis. *Int J Colorectal Dis* 2016;31:147–8. [CrossRef]
7. Kalcan S, Başak F, Hasbahçeci M, Kiliç A, Canbak T, Kudaş İ, et al. Intraoperative diagnosis of cecal diverticulitis during surgery for acute appendicitis: Case series. *Ulus Cerrahi Derg* 2016;32:54–7. [CrossRef]
8. Shaikh S, Krukowski ZH. Outcome of a conservative policy for managing acute sigmoid diverticulitis. *Br J Surg* 2007;94:876–9. [CrossRef]
9. Sardi A, Gokli A, Singer JA. Diverticular disease of the cecum and ascending colon: A review of 881 cases. *Am Surg* 1986;53:41–5.
10. Cheng E, Cohen L, Gasinu S, Sy C, Beneck D, Spigland N. Cecal diverticulitis as a continuing diagnostic and management dilemma: A report of two cases in children. *Pediatr Surg Int* 2012;28:99–102. [CrossRef]
11. Ruiz-Tovar J, Reguero-Callejas ME, Palacios FG. Inflammation and perforation of a solitary diverticulum of the cecum: A report of 5 cases and literature review. *Rev Esp Enferm Dig* 2006;98:875–80. [CrossRef]
12. Housni B, Khatouf M, Chater L, Bouabdellah Y, Elomari N, Harandou M, et al. Cecal volvulus: A case report in a child. *Arch Pediatr* 2005;12:1241–3. [CrossRef]
13. Tannouri S, Hendi A, Gilje E, Grissom L, Katz D. Pediatric colonic volvulus: A single-institution experience and review. *J Pediatr Surg* 2017;52:1062–6. [CrossRef]
14. Mboyo A, Flurin V, Bah AG, Emam N, Fenni T, Weil D. Caecal volvulus in the Marden-Walker syndrome: An uncommon association of two rare diseases in a 4-year old child. Case report. *Acta Chir Belg* 2004;104:101–3. [CrossRef]
15. Takada K, Hamada Y, Sato M, Fujii Y, Teraguchi M, Kaneko K, et al. Cecal volvulus in children with mental disability. *Pediatr Surg Int* 2007;23:1011–4. [CrossRef]
16. Gupta S, Gupta SK. Acute caecal volvulus: Report of 22 cases and review of literature. *Ital J Gastroenterol* 1993;25:380–4.
17. Boleken ME, Kaya M, Ozardali I, Kanmaz T, Yücesan S. Neonatal cecal cystic duplication mimicking intussusception. *Pediatr Int* 2006;48:172–3. [CrossRef]
18. Radhakrishna V, Rijhwani A, Jadhav B. Cecal duplication: A mimicker of intussusception: A case report and review. *Ann Med Surg* 2018;31:17–9.
19. Karaca L, Pirimoğlu B, Bayraktutan Ü, Oral A, Oğul H, Kantarcı M. Cecocolic intussusception in a patient with a cecal duplication cyst. *Turk J Gastroenterol* 2015;26:281–2. [CrossRef]
20. Institute of Medicine (US) and National Research Council (US) National Cancer Policy Board, Hewitt M, Weiner SL, Simone JV, editors. *Childhood Cancer Survivorship: Improving Care and Quality of Life*. Washington, DC, US: National Academies Press; 2003.
21. Singh H, Krishnamurthy G, Rajendran J, Sharma V, Mandavdhare H, Kumar H, et al. Surgery for abdominal tuberculosis in the present era: Experience from a tertiary-care center. *Surg Infect (Larchmt)* 2018;19:640–5. [CrossRef]
22. Saczek KB, Schaaf HS, Voss M, Cotton MF, Moore SW. Diagnostic dilemmas in abdominal tuberculosis in children. *Pediatr Surg Int* 2001;17:111–5. [CrossRef]

## ORİJİNAL ÇALIŞMA - ÖZ

### Çocukta akut karın nedeni olarak nadir görülen çekum patolojileri

Dr. Ali İhsan Anadolu<sup>1</sup>, Dr. Gonca Gerçel<sup>2</sup>, Dr. Osman Hakan Kocaman<sup>3</sup>

<sup>1</sup>Mehmet Akif İnan Eğitim ve Araştırma Hastanesi, Çocuk Cerrahisi Kliniği, Şanlıurfa

<sup>2</sup>Şanlıurfa Eğitim ve Araştırma Hastanesi, Çocuk Cerrahisi Kliniği, Şanlıurfa

<sup>3</sup>Harran Üniversitesi Tıp Fakültesi, Çocuk Cerrahisi Kliniği, Şanlıurfa

**AMAÇ:** Bu çalışmada, akut karın nedeni olarak görülen çekum patolojilerinin sunulması amaçlandı.

**GEREK VE YÖNTEM:** Ocak 2015–Haziran 2019 tarihleri arası akut karın ön tanısı ile ameliyat edilen ve primer çekum patolojisi saptanan hastalar geriye dönük olarak incelendi.

**BULGULAR:** Üçü kız, beşi erkek olan toplam sekiz hastanın yaş ortalaması 7.2±3.4'tü. Yakınmalar hastaların tümünde karın ağrısı ve kusmaydı. Fizik muayeneleri akut karın ile uyumluydu. Üç hastada ultrasonografi (USG), üçünde bilgisayarlı tomografi (BT) ve ikisinde de USG ve BT ile değerlendirme yapıldı. Görüntüleme tetkiklerinde iki hastada akut apandisit, ikisinde invajinasyon (1 Meckel divertikülüne bağlı, 1 mezenter kistine bağlı), ikisinde ileus, birinde perforate apandisit ve birinde çekum divertikülü ön tanısı düşünüldü. Ameliyatta beş hastada çekumda kitle, birinde çekum divertikülü, birinde çekum volvulusu ve bir hastada da inflame nekrotik çekum saptandı. Hastaların tümünde çekum rezeksiyonu ve ilekolonik anastomoz yapıldı. Histopatolojik inceleme üç hastada Burkitt lenfoma, ikisinde çekum divertikülü, birinde çekum duplikasyonu, birinde çekum tüberkülozu ve bir hastada da volvulusa bağlı gangrenöz nekroz olarak sonuçlandı. Hastaların ortalama takip süresi 25 aydı (dağılım, 2 ay-4 yıl). Takipleri sorunsuz seyretti, lenfoma tanılı hastalarda takip sürecinde nüks saptanmadı.

**TARTIŞMA:** Primer çekum patolojileri oldukça nadirdir. Bununla birlikte sunulan çalışmada da olduğu gibi ameliyat öncesi tanı güçlüğü, cerrahi ameliyat esnasında beklenmedik patolojiler ile karşı karşıya bırakabilmektedir. Bu da tedavi planlamasında standardizasyon yetersizliğine yol açmaktadır. Çalışmadaki malignite tanılı hastalar da göz önünde bulundurulduğunda çekum rezeksiyonu ile ilekolonik anastomoz yapılması primer çekum patolojisi olan çocuklarda yeterli ve uygun bir tedavi seçeneğidir.

**Anahtar sözcükler:** Akut abdomen; çekum patolojileri; çocuk; nadir.

Ulus Travma Acil Cerrahi Derg 2022;28(3):249-253 doi: 10.14744/tjtes.2020.79357