



Effect of pentoxifylline and vinpocetine on the healing of ischemic colon anastomosis: an experimental study

İskemik kolon anastomozunun iyileşmesi üzerine pentoksifilin ve vinposetinin etkisi: Deneysel çalışma

Aziz SÜMER,¹ Ediz ALTINLI,² Serkan SENGER,² Neşet KÖKSAL,²
Ender ONUR,³ Ersan EROĞLU,² Pembegül GÜNEŞ⁴

BACKGROUND

In the current study, we aimed to investigate the influences of pentoxifylline, which increases the flexibility, deformability and viscosity of the erythrocytes while reducing the aggregation abilities of the platelets, and vinpocetine, which has neuroprotective and antioxidant effects, on healing of colonic anastomoses.

METHODS

We used 30 Albino Wistar rats. Subjects were divided into three groups of 10 rats each. Colonic ischemia was established in all the groups. Following colonic transection, anastomosis was performed. Group A received intraperitoneal saline, whereas Group B and Group C received pentoxifylline and vinpocetine, respectively. The subjects were sacrificed on the postoperative 5th day by ether anesthesia, and their colonic bursting pressures were measured. The anastomotic area was excised for hydroxyproline assay and histopathologic examination.

RESULTS

According to intergroup comparisons, colonic bursting pressure was found to be higher in the treatment groups than in the control group; however, the difference was not statistically significant. Intergroup comparisons regarding tissue hydroxyproline levels showed statistically significant differences between Groups A and B, Groups A and C and Groups B and C.

CONCLUSION

Similar to pentoxifylline, vinpocetine was also shown to have a beneficial effect over ischemic colon anastomoses.

Key Words: Colon anastomoses; ischemia; pentoxifylline; vinpocetine.

AMAÇ

Bu çalışmada, eritrositlerin fleksibilitesini, deformabilitesini ve akışkanlığını arttıran, aynı zamanda trombositlerin agregasyon yeteneklerini azaltan pentoksifilin ile nöroprotektif, antioksidan etkisi olan vinposetinin kolon anastomozlarında iyileşme üzerine olan etkileri araştırıldı.

GEREÇ VE YÖNTEM

Çalışmamızda 30 adet Albino Wistar cinsi sıçan kullanıldı. Denekler herbiri 10 adet sıçandan oluşan 3 gruba ayrıldı. Tüm gruplarda kolon iskemisi oluşturuldu. Kolon transeksiyonu sonrası anastomoz yapıldı. Grup A'ya intraperitoneal olarak serum fizyolojik, Grup B'ye pentoksifilin ve Grup C'ye ise vinposetin verildi. Cerrahi işlem sonrası 5. günde eter anestezisi ile sakrifiye edilen sıçanların kolon patlama basınçları ölçüldü. Anastomoz bölgesi hidroksiprolin ölçümü ve histopatolojik inceleme için çıkartıldı.

BULGULAR

Gruplararası kolon patlama basınçları kontrol grubuna göre daha yüksek ölçülmekle birlikte, istatistiksel olarak anlamlı değildi. Gruplararası doku hidroksiprolin düzeyleri açısından Grup A ile Grup B, Grup A ile Grup C ve Grup B ile Grup C arasında istatistiksel olarak anlamlı fark vardı.

SONUÇ

Vinpocetinin de pentoksifilin gibi iskemik kolon anastomozlarına olumlu etkisi olduğu gösterilmiştir.

Anahtar Sözcükler: Kolon anastomozu; iskemik; pentoksifilin; vinpocetin.

¹Department of General Surgery, Yüzüncü Yıl University, Faculty of Medicine, Van; Departments of ²General Surgery, ³Pathology, Haydarpaşa Numune Training and Research Hospital, Istanbul;

³Department of General Surgery, Fatih Sultan Mehmet Training and Research Hospital, Istanbul, Turkey.

¹Yüzüncü Yıl Üniversitesi, Tıp Fakültesi, Genel Cerrahi Anabilim Dalı, Van; Haydarpaşa Numune Eğitim ve Araştırma Hastanesi,

²Genel Cerrahi Kliniği, ³Patoloji Bölümü, İstanbul; ³Fatih Sultan Mehmet Eğitim ve Araştırma Hastanesi, Genel Cerrahi Kliniği, İstanbul.

Colonic leaks arising from inadequate healing of the anastomosis are still deemed an important problem in colorectal surgery.^[1,2] Anastomotic leak in colorectal surgery increases the morbidity and mortality rates.^[3,4] Tissue blood flow and oxygenation are very significant factors contributing to the healing of colonic anastomosis, whereas ischemia and infection are known to be the most important factors interrupting the healing process.^[5,6]

Ischemia is one of the most influential causes leading to impaired wound healing.^[7,8] The ischemic wound is known to be easily infected and to have a difficult healing process.^[8,9] Prevention or reduction of ischemic damage is among the objectives of surgery.

The most important elements that have an effect over organ and tissue perfusions are erythrocyte deformability and plasma viscosity. In order to remove metabolic wastes, while transporting oxygen and vital molecules to the end-organ capillaries, erythrocytes should be able to deform themselves so as to move and squeeze through narrow and sinuous areas. This ability is termed as 'deformability'. Vasoactive drugs are known to increase tissue blood flow and oxygenation.^[10]

The aim of this study was to compare the effects of pentoxifylline, a xanthene derivative that reduces blood viscosity by increasing cell deformability and decreasing plasma fibrinogen concentration, while elevating blood viscosity by inhibiting platelet adhesion and aggregation, and pentoxifylline, which has antioxidant, vasodilator and neuroprotective effects, over anastomotic healing.

MATERIALS AND METHODS

After gaining the approval of the ethics committee of the Haydarpasa Numune Training and Research Hospital, the study was conducted at the hospital's animal laboratory. Our experimental study included 30 adult male and female Albino Wistar rats, weighing between 200-240 g. The rats were split into three groups in a randomized manner so as to include 10 rats in each.

Group A: Anastomosis in ischemic colon model

Group B: Anastomosis in ischemic colon model + Intraperitoneal pentoxifylline delivery

Group C: Anastomosis in ischemic colon model + Intraperitoneal vinpocetine delivery

Preoperatively, each subject from all groups was fed with water and standard laboratory diet under fixed environmental conditions. Anesthesia was performed by intramuscular (IM) injection of ketamine 50 mg/kg (Ketalar vial, Pfizer, Turkey) supported by ether inhalation, without applying any colon cleansing. Fol-

lowing anesthesia, rats were weighed by an analytic balance and the weight of each rat was noted. Then, the rats were fixed on the operating table in the supine position before clipping their abdominal hair and applying povidone iodine solution.

A median laparotomy was applied to all the groups. As described by Altinli et al.,^[6] all the marginal arteries and vasa recti within 2 cm proximal and 2 cm distal range of the colonic segment located 3 cm proximal to the peritoneal reflection were ligated by 4/0 atraumatic silk sutures. End-to-end anastomosis was performed with polypropylene 6/0 (Fig. 1). The rats were allowed to feed at the end of 24 hours.

Group A was the control group and received intraperitoneal 1 cc saline once daily for 5 days at 24-hour intervals. Group B received pentoxifylline 50 mg/kg (Vasoplan ampoule, Mustafa Nevzat İlaclari, Turkey) once daily for 5 days at 24-hour intervals. Group C received intraperitoneal vinpocetine 1 mg/kg (Cavinton ampoule, RG, Bulgaria) once daily for 5 days at 24-hour intervals. All subjects were sacrificed postoperatively on day 5 by high-dose ether anesthesia. Assessment of anastomotic healing was carried out by evaluation of bursting pressure, tissue hydroxyproline measurement, and histopathologic examination.

Evaluation of Bursting Pressure

The abdomen was entered through the same abdominal incision on the postoperative 5th day. Since management of adhesions formed in the anastomotic area and identified by the polypropylene sutures could lead to different measurement results, the peripheral adhesions were left untouched. Colonic content was removed from the anastomotic area. A ligature was applied 2 cm proximal to the anastomosis by 3/0 silk. An infusion pump was placed through the rectum to reach the anastomosis line and ligated by a 3/0 silk

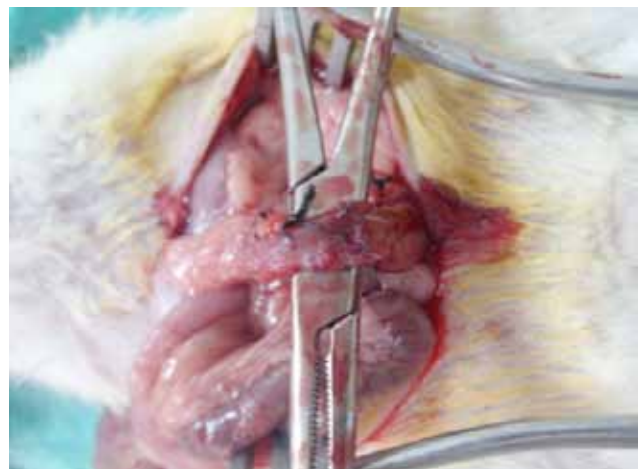


Fig. 1. The view of the completed anastomosis.

(Color figure can be viewed in the online issue, which is available at www.tjtes.org)

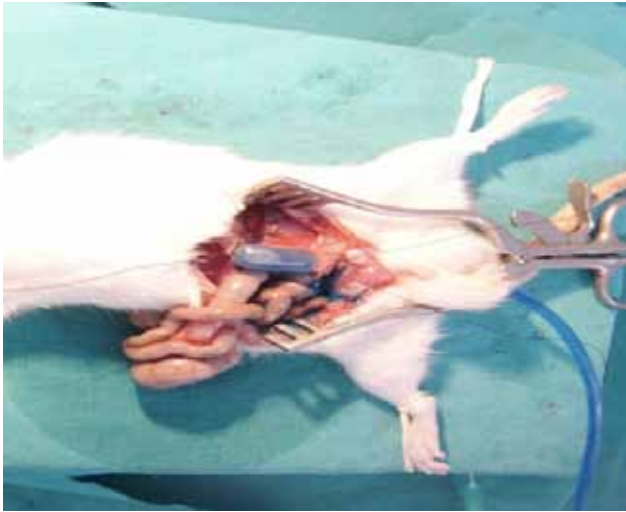

Fig. 2. Bursting pressure measurement.

(Color figures can be viewed in the online issue, which is available at www.tjtes.org)

so as to avoid leaks. Isotonic solution with methylene blue was administered by a syringe driver at a rate of 1 ml/min and the area of the anastomosis was monitored. The pressure value read at the first observation of methylene blue outside the anastomosis area was recognized and noted as the bursting pressure (Fig. 2).

Hydroxyproline Measurement

Following measurement of bursting pressure, the colon was resected longitudinally, comprising both 2 cm distal and proximal of the anastomosis. The resection segment was reduced to include 0.5 cm of both proximal and distal portions before removing one half for hydroxyproline measurement and the other half for histopathologic examination. One gram of the resected tissue was hydrolyzed for 5 hours at 121°C in an acidic buffer solution. After the hydrolysis, the samples were centrifuged at 5000 rpm for 20 minutes, which yielded the final study material. The absorbance of the final material was evaluated by colorimetric method at 560 nm and 121°C, and tissue hydroxyproline level was calculated as mg/L/g tissue by a commercially available kit (Kit: Hydroxyproline Extra [Colorimetric Determination], Lot #: 41100, Brand: Far/Italy).

Histopathologic Examination

Perianastomotic colonic segments were evaluated by a pathologist blindly. Preparations were evaluated in light of the parameters developed by Garcia et al.^[11] Tissue samples prepared as paraffin blocks were stained with hematoxylin-eosin and examined under an Olympus CX 41 light microscope by a pathologist for presence of inflammatory cells, neovascularization, fibroblast presence, fibrosis, ischemic necrosis, continuity of the muscular layer, inflammatory infiltration in the muscular layer, and local inflammatory re-

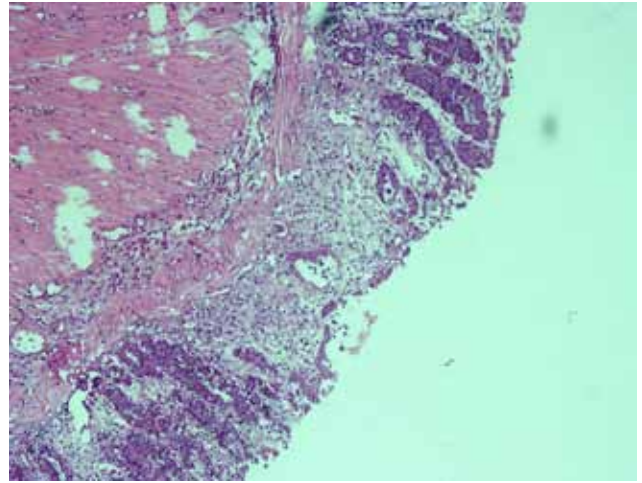


Fig. 3. Intense re-epithelization on colonic mucosa in the vinpocetine group.

sponse (neutrophil, lymphocyte, histiocyte, and giant cell) over the anastomotic area.

Statistical Analysis

The results of our study were evaluated by the Statistical Package for the Social Sciences (SPSS) for Windows 11.0 program. Intergroup comparison of the classified data was carried out by chi-square test, while Fisher's exact test was used for unsuited data (a frequency ≤ 4 in the cells). Considering the small scale of the sample included in the study, nonparametric methods (Kruskal-Wallis analysis and Mann-Whitney U test) were applied. A p value below 0.05 at 0.95 significance level was recognized as statistically significant.

RESULTS

No deaths were observed due to anesthesia or surgery. Two rats died in Group B at 3 and 4 days after the anastomosis. Necropsies revealed strong anastomoses. However, dilatation was observed in the intestinal loops over the proximal portion of anastomoses and these were evaluated to be consistent with ileus. The subjects that died were excluded from the study and replaced with new subjects in order to complete the study.

Bursting Pressure

In all subjects, the bursting was observed at the anastomotic line. Average anastomotic bursting pressures were 73.5 ± 14.15 mmHg in Group A, 77.2 ± 11.97 mmHg in Group B, and 87.4 ± 15.66 mmHg in Group C. While colonic bursting pressures were higher in Groups B and C in comparison to Group A, the differences between groups were statistically insignificant ($p=0.86$). The anastomotic bursting pressures and standard deviations are shown in Table 1.

Table 1. Colon bursting pressure of the groups and standard deviation

Colon bursting pressure	Group A (mmHg)	Group B (mmHg)	Group C (mmHg)
	160	88	147
	106	82	55
	91	77	74
	13	89	26
	60	86	32
	15	21	43
	64	73	137
	41	149	161
	79	82	112
	88	98	87
Mean±SD	73.5±14.15	77.2±11.97	87.4±15.66

Table 2. Tissue hydroxyproline level of the groups and standard deviation

Hydroxyproline level	Group A (mg/L/g tissue)	Group B (mg/L/g tissue)	Group C (mg/L/g tissue)
	130.0	549.0	1016.0
	139.0	263.0	480.0
	136.0	226.0	488.0
	72.0	156.0	923.0
	34.0	347.0	827.0
	146.0	311.0	695.0
	58.0	464.0	462.0
	162.0	272.0	464.0
	154.0	317.0	330.0
	252.0	371.0	536.0
Mean±SD	128.3±19.61	327.6±36.1	622.1±72.61

Tissue Hydroxyproline Level

Average hydroxyproline levels were 128.3±19.61 mg/L/g tissue in Group A, 327.6±36.1 mg/L/g tissue in Group B, and 622.1±72.61 mg/L/g tissue in Group C. Intergroup difference was statistically significant ($p=0.00001$). Paired comparisons of the groups revealed statistically significant differences ($pA-B=0.00001$; $pA-C=0.00001$; $pB-C=0.001$). Distribution and statistical analysis results are shown in Table 2.

Histopathologic Examination

Wound healing, granulation tissue formation, and histological changes in local inflammatory responses in anastomoses were evaluated according to the parameters modified by Garcia et al.^[11] The intergroup differences between the subjects with regard to mucosal re-epithelization grading were statistically significant ($p=0.009$). The vinpocetine group demonstrated a good degree of re-epithelization in the colonic mucosa (Fig. 3).

There was no statistically significant intergroup difference among the study subjects with regard to neovascularization, fibroblasts, continuity of the mus-

cular layer, inflammation of the muscular layer, polymorphonuclear leukocytes (PNL) at the anastomotic site, lymphocyte infiltration, and grading of histiocyte and giant cells ($p=0.422$, $p=0.42$, $p=0.105$, $p=0.274$, $p=0.171$, $p=0.059$, $p=0.19$, $p=0.538$, respectively). The difference between the groups in terms of fibrosis grading was statistically significant ($p=0.023$).

DISCUSSION

The most common complication of gastrointestinal operations, which are performed frequently, is anastomotic leaks, with high morbidity and mortality. In colorectal anastomoses, the anastomotic leak rate is reported to be 10-20%. Although the incidence of this complication has been significantly reduced with the application of modern surgical techniques, it is still an important complication.^[4,9,12-14]

As with all anastomoses, tissue blood flow and oxygenation are considerable factors in colonic anastomoses.^[5,12] In comparison with other gastrointestinal components, the colon is known to present higher anastomotic leak rates due to its certain anatomical

and biological characteristics, such as low collagen content, high collagenase activity, reduced collateral circulation, and absence of a serosa in the extraperitoneal rectum.^[15]

There have been numerous experimental studies regarding colonic anastomotic healing. In those studies, many agents have been used, such as hyperbaric oxygen, glucan, erythropoietin, bosentan, growth hormone, and H₂-receptor antagonists like famotidine. The common denominator of all those studies was the effort to reduce ischemia.^[4,5,12,14,16,17] Benacerraf et al.^[18] reported 100% anastomotic leak in cases where perianastomotic oxygen pressure was below 20 mmHg, while denoting that the anastomotic leak rate was reduced by elevation of oxygen pressure. In the current study, we used pentoxifylline and vinpocetine to reduce ischemia. Consistent with previous studies in the literature, hydroxyproline levels and bursting pressures were determined to be higher in groups in which such agents were used when compared with the control group.

Bursting pressure and hydroxyproline determinations are measures that offer insight into the anastomosis healing process. Bursting pressure reveals the mechanical parameters of a colonic anastomosis and reflects growing anastomotic strength. Biochemical parameters of anastomotic healing are reflected by the collagen content in perianastomotic tissues, as determined by hydroxyproline content.^[4] In this study, comparison of the control and treatment groups with regard to bursting pressure revealed a high, but not statistically significant, difference. Hydroxyproline levels were found to be higher in the treatment groups than in the control group. The elevated levels of bursting pressure and hydroxyproline were associated with the reduction of collagenase activity induced by vinpocetine and pentoxifylline.

In the study of Parra-Membrives et al.^[9] focusing on the effects of pentoxifylline over ischemic colorectal anastomoses, pentoxifylline and control groups showed similar mucosal re-epithelization; presence of inflammatory cells in the granulation tissue; and lymphocyte, histiocyte, and fibroblast infiltration. No significant alteration was observed with regard to destruction of the muscular layer. The control group demonstrated a significantly high amount of neutrophils over the anastomosis line. The underlying reason for the reduction in grading of perianastomotic fibrosis was claimed to be ischemia and neovascularization. In the current study, unlike the investigation of Parra-Membrives et al.,^[9] we determined a higher level of mucosal re-epithelization in the vinpocetine and pentoxifylline groups. However, despite higher values for inflammatory cells, neovascularization, muscular layer continuity, and PNL presence, the differences

were not statistically significant. This difference was thought to be associated with the fact that the number of subjects in our study was one-third of the above-mentioned study.

In the study of Abdel Salam et al.,^[19,20] vinpocetine and pentoxifylline were shown to have positive effects over ischemic hepatic tissue induced by carbon tetrachloride. The result of this study can be deemed as supportive of a likely positive influence of pentoxifylline and vinpocetine over colonic anastomosis because of their evident positive effects in organ ischemia.

In conclusion, we observed a positive influence of vinpocetine, similar to that of pentoxifylline, over healing of ischemic colonic anastomosis.

REFERENCES

- Schilling JA. Wound healing. *Surg Clin North Am* 1976;56:859-74.
- Carrico TJ, Mehrhof AI Jr, Cohen IK. Biology of wound healing. *Surg Clin North Am* 1984;64:721-33.
- Kirsner RS, Eaglstein WH. The wound healing process. *Dermatol Clin* 1993;11:629-40.
- Inan A, Sen M, Sürgit O, Ergin M, Bozer M. Effects of the histamine H₂ receptor antagonist famotidine on the healing of colonic anastomosis in rats. *Clinics (Sao Paulo)* 2009;64:567-70.
- Guzel S, Sunamak O, AS A, Celik V, Ferahman M, Nuri MM, et al. Effects of hyperbaric oxygen and Pgg-glucan on ischemic colon anastomosis. *World J Gastroenterol* 2006;12:1421-5.
- Altinli E, Saribeyoğlu K, Karahasanoğlu T, Hamzaoğlu I, Aydoğan F, Karabiçak I, et al. Are clips useful in the surgical repair of colonic perforations? *Acta Chir Belg* 2005;105:410-2.
- Stoop MJ, Dirksen R, Hendriks T. Advanced age alone does not suppress anastomotic healing in the intestine. *Surgery* 1996;119:15-9.
- Uluocak K. Kolon anastomoz yetmezliklerinin sebepleri ve önlenmesi. *Dirim* 1992;67:34-42.
- Parra-Membrives P, Ruiz-Luque V, Escudero-Severin C, Aguilar-Luque J, Méndez-García V. Effect of pentoxifylline on the healing of ischemic colorectal anastomoses. *Dis Colon Rectum* 2007;50:369-75.
- Erdoğan C, Erdem A, Akıncı S.B, Dikmeoğlu N, Başgül E, Balkancı, Aypar Ü. Midazolamın sıçanlarda eritrosit deformabilitesi ve plazma viskozitesi üzerine etkisi. *Anestezi Der-gisi* 2005;13:205-8.
- Garcia JC, Arias C, Garcia C, Vara E, Balibrea JL. Modificacio'n de los mediadores inflamatorios en isquemia-reperfusio'n intestinal en un modelo de diabetes tipo II. *Cir Esp* 2002;71:276-86. [Abstract]
- Moran M, Ozmen MM, Duzgun AP, Gok R, Renda N, Seckin S, et al. The effect of erythropoietin on healing of obstructive vs nonobstructive left colonic anastomosis: an experimental study. *World J Emerg Surg* 2007;2:13. doi:10.1186/1749-7922-2-13.
- Thornton FJ, Barbul A. Healing in the gastrointestinal tract. *Surg Clin North Am* 1997;77:549-73.
- Cetinkaya Z, Esen K, Ozercan IH, Ustundag B, Ayten R, Aygen E. The effect of Bosentan on healing of colonic anasto-

- mosis. *World J Emerg Surg* 2006;1:37.
15. Kılıç Y, Avar B, Kamalı S, Güven H, Sungur F. Kolon anastomozlarında stapler ve el dikiştekniklerinin kısa süreli komplikasyonlar açısından karşılaştırılması. *Kolon Rektum Hast Derg* 1991;1:45-50.
 16. Çağlıküleççi M, Özçay N, Oruç T, Aydoğ G, Renda N, Atalay F. The effect of recombinant growth hormone on intestinal anastomotic wound healing in rats with obstructive jaundice. *Turk J Gastroenterol* 2002;13:17-23.
 17. Karahasanoglu T, Altinli E, Hamzaoglu I, Paksoy M, Yeşildere T, Alemdaroglu K. Effect of growth hormone treatment on the healing of left colonic anastomoses in protein-malnourished rats. *Br J Surg* 1998;85:931-3.
 18. Benacerraf B, Sebestyen MM. Effect of bacterial endotoxins on the reticuloendothelial system. *Fed Proc* 1957;16:860-7.
 19. Abdel Salam OM, Oraby FH, Hassan NS. Vinpocetine ameliorates acute hepatic damage caused by administration of carbon tetrachloride in rats. *Acta Biol Hung* 2007;58:411-9.
 20. Abdel Salam OM, Baiuomy AR, El-Shenawy SM, Hassan NS. Effect of pentoxifylline on hepatic injury caused in the rat by the administration of carbon tetrachloride or acetaminophen. *Pharmacol Rep* 2005;57:596-603.