



Pneumomediastinum and subcutaneous emphysema caused by sigmoid diverticulum perforation secondary to blunt abdominal trauma: report of a case

Künt batın travmasına sekonder gelişen sigmoid divertikül perforasyonu nedeniyle oluşan pnömomediastinum ve subkutanöz amfizem: Olgu sunumu

Necdet Fatih YAŞAR,¹ Mahmut KEBAPÇI,² Enver İHTİYAR¹

Pneumomediastinum and subcutaneous emphysema are very rare reported signs of colonic perforation most often associated with diverticulitis, toxic megacolon and colonoscopy. We report a case of a 60-year-old man with subcutaneous emphysema and pneumomediastinum, which developed three days after a car accident without pneumothorax. A computed tomography scan demonstrated perforation of a sigmoid diverticulum in conjunction with air. A laparotomy was performed and revealed a perforated sigmoid diverticulum, fistulized into the retroperitoneal cavity. We suspect that this diverticular perforation was caused by the deterioration of the sigmoid mesocolon secondary to the blunt abdominal trauma. To our knowledge, this is the first report in the literature about pneumomediastinum and subcutaneous emphysema caused by sigmoid diverticular rupture following mesosigmoid trauma.

Key Words: Perforation; pneumomediastinum; sigmoid diverticulum; trauma.

Pnömomediastinum ve subkutanöz amfizem divertikülit, toksik megakolon ve kolonoskopi sonrası görülebilen kolon perforasyonunun çok nadir bir komplikasyonu olarak meydana gelebilir. Burada, geçirdiği trafik kazasından sonra ilk muayenesinde yokken, 3 gün sonra pnömotoraks olmaksızın pnömomediastinum ve subkutanöz amfizem gelişen 60 yaşında erkek hasta sunuldu. Çekilen bilgisayarlı tomografide sigmoid divertikül perforasyonu ile devamlılık gösteren serbest hava gözlemlendi. Laparotomide retroperitoneal kaviteye fistülize olmuş perforasyonlu sigmoid divertikülü saptandı. Bu divertiküler perforasyonun künt karın travmasına sekonder gelişen sigmoid mezokolon yaralanmasından kaynaklandığını düşünmekteyiz. Tüm literatür taramamızda mezosigmoid travması sonrası sigmoid divertikül perforasyonu nedeniyle ortaya çıkmış pnömomediastinum ve subkutanöz amfizem olgusuna rastlayamadık. Bu nedenle bu olgu bu konuda literatürdeki ilk olacaktır.

Anahtar Sözcükler: Perforasyon; pnömomediastinum; sigmoid divertikülü; travma.

Pneumomediastinum and subcutaneous emphysema are uncommon clinical entities that occur when air leaks from the lungs or any of the luminal organs, such as the bronchial tube, larynx, trachea, esophagus, and very rarely, the colon, with subsequent dissection into the mediastinum. The continuum of fascial planes connecting cervical soft tissues with the mediastinum and retroperitoneum permits this dissection.^[1] We describe herein a patient presenting with subcutaneous emphysema and pneumomediastinum caused by sigmoid diverticulum perforation three days after a blunt abdominal trauma.

CASE REPORT

A 60-year-old man presented to the Emergency Department with severe pain in his left groin and left forearm after a car accident. On admission, his blood pressure was 110/70 mmHg with a regular heart rate of 80/min. The initial clinical evaluation revealed a deformity on the left forearm and tenderness to palpation of the left groin accompanied by restricted motion of the left hip. He had minimal abdominal tenderness on palpation and no signs of respiratory distress. His vital signs and hemoglobin level remained stable during the follow-up in the Emergency Department. Fractures of

Departments of ¹General Surgery, ²Radiology, Eskisehir Osmangazi University, Faculty of Medicine, Eskisehir, Turkey.

Eskişehir Osmangazi Üniversitesi Tıp Fakültesi, ¹Genel Cerrahi Anabilim Dalı, ²Radyoloji Anabilim Dalı, Eskişehir.

Correspondence (İletişim): Necdet Fatih Yaşar, M.D. Eskişehir Osmangazi Üniversitesi, Tıp Fakültesi, Genel Cerrahi Anabilim Dalı, Meşelik Kampüsü 26480 Eskişehir, Turkey.

Tel: +90 - 222 - 239 29 79 / 2600 e-mail (e-posta): fatih_yasar@yahoo.com

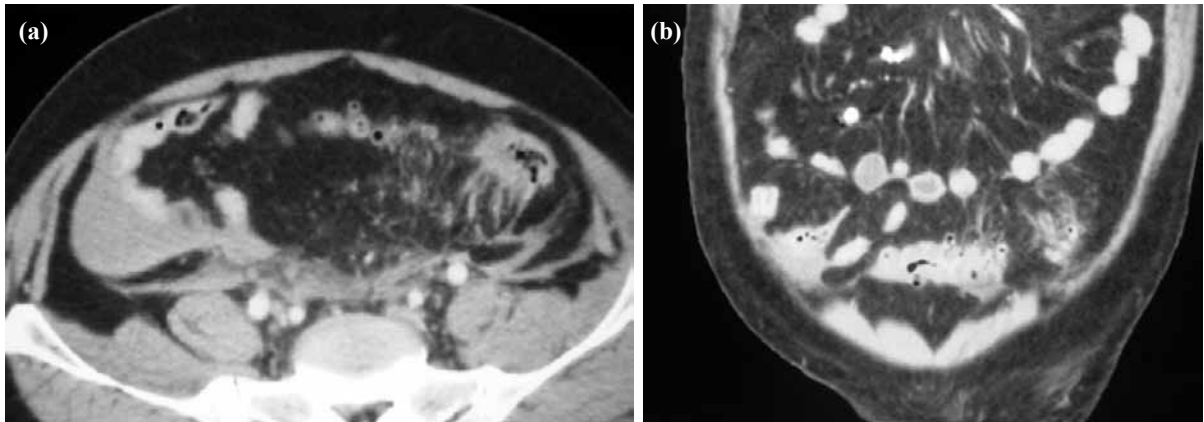


Fig. 1. (a) (axial) and (b) (coronal). The first tomography after the trauma: mesenteric fibrofatty changes in the sigmoid mesocolon and multiple sigmoid diverticula are observed.

the left acetabulum and fracture of both bones of the left forearm were documented on the radiography. Bilateral anterior fractures of the 8th rib, which involved the costochondral junction, and bilateral minimal pleural effusions were identified by a thoracic tomographic scan. Neither pneumothorax nor pneumomediastinum was observed. An abdominal tomographic scan revealed mesenteric and mural thickening of the sigmoid colon, multiple sigmoid diverticula (Fig. 1a, b) and minimal perihepatic and perisplenic fluid collection. After traction was applied to the left leg and the left arm was immobilized in a cast, the patient was transferred to the Department of Orthopedics. On the third day of the hospitalization, subcutaneous emphysema developed in the right upper quadrant of the abdomen and disseminated up to the level of the 7th rib on the right side and down to the scrotum within 10 hours. He had no abdominal tenderness on palpation but he became febrile and confused. The initial total leukocyte count of $17300/\text{mm}^3$ on admission was increased to $19600/\text{mm}^3$. A new chest radiograph showed a left-sided pneumomediastinum without pneumothorax. A second thoracoabdominopelvic computed to-

mography scan revealed extraperitoneal free air in the mediastinum, retroperitoneal space and subcutaneous tissue. In addition to these findings, perforation of a sigmoid diverticulum was identified (Fig. 2a, b). During the tomography scan, contrast medium was applied orally to visualize any possible perforation site of the esophagus. Images of lower parts of the pelvis were also taken to examine the rectum. No other possible cause of the extraperitoneal air except the diverticular perforation was found. After the tomography, laparotomy was performed. The abdominal exploration revealed that the sigmoid mesocolon and sigmoid colon were edematous and fragile, possibly due to the trauma. The sigmoid diverticulum perforation was confirmed, forming an abscess that was fistulized into the retroperitoneal space without any leakage into the peritoneum. After aspirating the pus and irrigating the area with saline, the necrotic tissue around the abscess was debrided and Hartmann's procedure was performed. On the 5th postoperative day, he was able to be extubated and enteral feeding was begun. In spite of medical management and noninvasive respiratory support, respiratory distress syndrome developed two

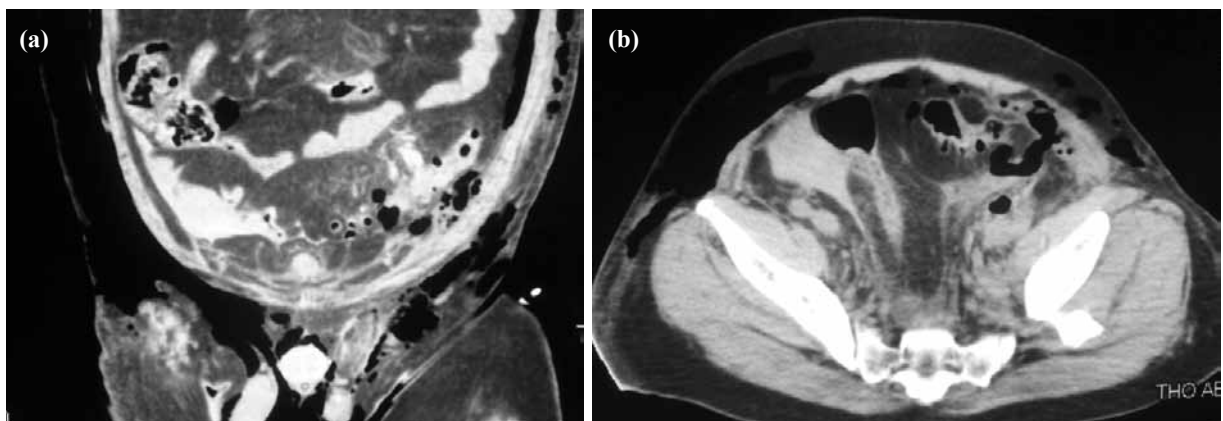


Fig. 2. (a) (Axial) and (b) (coronal): The second computed tomography on the 3rd day of the hospitalization, free air in the retroperitoneal space and subcutaneous tissue with perforation of a sigmoid diverticulum are identified.

weeks after the extubation and the patient was reintubated and died on the 24th postoperative day.

DISCUSSION

Pneumomediastinum and subcutaneous emphysema may be observed after intrathoracic pressure changes, leading to alveolar rupture and dissection of air along the tracheobronchial tree due to emesis or asthma flare-ups and sometimes spontaneously without any specific reason.^[2,3] Emesis may also cause esophageal rupture, which may lead to pneumomediastinum and subcutaneous emphysema.^[4] Aspiration of a foreign body is also described in the possible etiology by puncturing the airway or by increasing the pressure.^[5] Our patient did not have any of these in his history. Blunt chest trauma may also be a cause of pneumomediastinum by tearing the tracheobronchial and esophageal structures.^[6-8] Pneumothorax usually accompanies these findings depending on the type of the injury. In our case, pneumothorax was not observed in the early and late radiography and computed tomography scan. The tracheobronchial tree was intact and no contrast medium leakage from the esophagus was observed on the tomography scan. Pneumomediastinum and subcutaneous emphysema are also very rare signs of colonic perforation, which is usually secondary to diverticulitis,^[9,10] toxic megacolon in ulcerative colitis,^[11] colonoscopy,^[12] endoscopic polypectomy,^[13] and very rarely, spontaneously.^[14] In our case, it was thought that the pneumomediastinum, pneumoretroperitoneum and subcutaneous emphysema were due to the perforation of a sigmoid diverticulum, which was documented by both tomography scans and abdominal exploration. However, it is interesting that in the first tomography images, there was no sign of perforation but multiple sigmoid diverticula and mesenteric and mural thickening of the sigmoid colon secondary to the injury. The second tomography identified the diverticulum perforation on the third day of his hospitalization. During the laparotomy, we noticed that the sigmoid colon and mesocolon were edematous and fragile, walled off by an abscess that was fistulized into the retroperitoneal space. We concluded that this diverticulum perforation resulted in subcutaneous emphysema and pneumomediastinum. To our knowledge, this is the first report in the literature about pneumomediastinum and subcutaneous emphysema caused by

sigmoid diverticulum perforation secondary to blunt abdominal trauma.

REFERENCES

1. Maunder RJ, Pierson DJ, Hudson LD. Subcutaneous and mediastinal emphysema. Pathophysiology, diagnosis, and management. *Arch Intern Med* 1984;144:1447-53.
2. Caceres M, Ali SZ, Braud R, Weiman D, Garrett HE Jr. Spontaneous pneumomediastinum: a comparative study and review of the literature. *Ann Thorac Surg* 2008;86:962-6.
3. Macia I, Moya J, Ramos R, Morera R, Escobar I, Saumench J. Spontaneous pneumomediastinum: 41 cases. *Eur J Cardiothorac Surg* 2007;31:1110-4.
4. Forshaw MJ, Khan AZ, Strauss DC, Botha AJ, Mason RC. Vomiting-induced pneumomediastinum and subcutaneous emphysema does not always indicate Boerhaave's syndrome: report of six cases. *Surg Today* 2007;37:888-92.
5. Ramadan HH, Bu-Saba N, Baraka A, Mroueh S. Management of an unusual presentation of foreign body aspiration. *J Laryngol Otol* 1992;106:751-2.
6. Nugteren P, Paul MA, Plötz FB. Rupture of the right main bronchus: a case of a 4-year-old girl. *Eur J Emerg Med* 2007;14:97-9.
7. Martel G, Al-Sabti H, Mulder DS, Sirois C, Evans DC. Acute tracheoesophageal burst injury after blunt chest trauma: case report and review of the literature. *J Trauma* 2007;62:236-42.
8. Okutani D, Aoe M, Yamane M, Hatoh S, Toyooka S, Sano Y, et al. Extensive traumatic pneumomediastinum. without injuries of organs in the thorax: report of a case. *Kyobu Geka* 2007;60:942-5. [Abstract]
9. Besic N, Zgajnar J, Kocijancic I. Pneumomediastinum, pneumopericardium, and pneumoperitoneum caused by peridiverticulitis of the colon: report of a case. *Dis Colon Rectum* 2004;47:766-8.
10. Soliani G, Dominici M, Bergossi L, Basaglia E, Pauli S, Carcoforo P. Acute colon diverticulitis in multiple myeloma patient: an unusual presentation of a colonic perforation. Case report. *Ann Ital Chir* 2002;73:643-6.
11. Mogan GR, Sachar DB, Bauer J, Salky B, Janowitz HD. Toxic megacolon in ulcerative colitis complicated by pneumomediastinum: report of two cases. *Gastroenterology* 1980;79:559-62.
12. Goerg KJ, Düber C. Retroperitoneal, mediastinal and subcutaneous emphysema with pneumothorax after colonoscopy. *Dtsch Med Wochenschr* 1996;121:693-6. [Abstract]
13. Ho HC, Burchell S, Morris P, Yu M. Colon perforation, bilateral pneumothoraces, pneumopericardium, pneumomediastinum, and subcutaneous emphysema complicating endoscopic polypectomy: anatomic and management considerations. *Am Surg* 1996;62:770-4.
14. Prêtre R, Rohner A. Pneumomediastinum and subcutaneous cervical emphysema as signs of rectosigmoid perforation. *Gastroenterol Clin Biol* 1992;16:460-2. [Abstract]