

Unraveling the complexity of acute subdural hematoma in elderly patients: The impact of anticoagulant therapy and the pursuit of better outcomes

✉ Soner Yasar,¹ ✉ Mehmet Can Ezgu,¹ ✉ Gardashkhan Karırmzada,² ✉ Demet Evleksiz Karırmzada¹

¹Department of Neurosurgery, Gulhane School of Medicine, University of Health Sciences, Ankara-Türkiye

²Department of Neurosurgery, Central Military Hospital of the Armed Forces, Baku-Azerbaijan

ABSTRACT

BACKGROUND: Acute subdural hematoma (ASDH) is a critical and often fatal condition, particularly in elderly patients receiving anticoagulant therapy. With a growing global aging population, the incidence of traumatic brain injuries, including ASDH, is projected to rise, presenting significant challenges in clinical management. This study evaluates the outcomes of surgically treated ASDH in patients aged 65 years and older, comparing those who received anticoagulant therapy with those who did not. It also aims to identify the main risk factors for poor outcomes and explore preventive strategies in this vulnerable population.

METHODS: A retrospective analysis was conducted on 90 patients aged 65 years and older who underwent surgery for ASDH at our institution between 2018 and 2023. Patients were categorized into two groups based on anticoagulant therapy use. Demographic data, mechanisms of injury, clinical presentations, and outcomes, including mortality and reoperation rates, were analyzed. Radiological assessments included hematoma thickness, midline shift, and the presence of residual hematoma.

RESULTS: No significant differences were observed in hematoma thickness, midline shift, or mortality between patients receiving anticoagulant therapy and those not on anticoagulants. However, a significant association was found between anticoagulant use and the mechanism of injury; patients on anticoagulants were more likely to sustain ASDH from low-energy trauma, such as a fall from the same level ($p=0.005$). Despite the high mortality rates associated with ASDH in elderly patients, the multidisciplinary approach employed, including the prompt reversal of coagulopathy, likely contributed to the observed outcomes.

CONCLUSION: Acute subdural hematoma in elderly patients, particularly those receiving anticoagulant therapy, remains a challenging problem with a high rate of poor outcomes. This study highlights the urgent need for preventive measures to mitigate the risks associated with even minor trauma, especially in patients on anticoagulants. Our findings underscore the importance of appropriate management protocols, including the timely reversal of coagulopathy, in improving survival rates within this high-risk population. Further research is needed to develop and validate comprehensive preventive strategies and to investigate long-term outcomes in these patients.

Keywords: Acute subdural hematoma; anticoagulant therapy; elderly patients; traumatic brain injury; geriatric trauma.

INTRODUCTION

In 2019, it was estimated that one in eleven people (9%) worldwide were over the age of 65, and by 2050, this proportion is projected to increase to one in six people (16%), mak-

ing this age group the fastest-growing segment of the global population.^[1] This demographic shift is associated with a rising incidence of traumatic brain injury (TBI), which peaks during childhood, adolescence, and older adulthood, with the high-

Cite this article as: Yasar S, Ezgu MC, Karırmzada G, Evleksiz Karırmzada D. Unraveling the complexity of acute subdural hematoma in elderly patients: the impact of anticoagulant therapy and the pursuit of better outcomes. *Ulus Travma Acil Cerrahi Derg* 2025;31:32-39.

Address for correspondence: Soner Yasar

Department of Neurosurgery, Gulhane School of Medicine, University of Health Sciences, Ankara, Türkiye

E-mail: dr.soneryasar@gmail.com

Ulus Travma Acil Cerrahi Derg 2025;31(1):32-39 DOI: 10.14744/tjtes.2024.63489

Submitted: 26.08.2024 Revised: 27.08.2024 Accepted: 11.11.2024 Published: 03.01.2025

OPEN ACCESS This is an open access article under the CC BY-NC license (<http://creativecommons.org/licenses/by-nc/4.0/>).



est rates observed in older adults.^[2] As the elderly population continues to grow, the incidence of TBI in this group is expected to rise correspondingly. Acute subdural hematoma (ASDH), identified on computed tomography (CT) as an extraaxial hyperdense crescent-shaped lesion located between the dura mater and brain parenchyma, is one of the most severe and common forms of traumatic intracranial lesions in the elderly.^[3,4] Elderly individuals are particularly susceptible to ASDH due to several factors, including falls, an increased subdural space resulting from age-related brain atrophy, fragile bridging veins, and pre-existing chronic medical conditions such as kidney disease, diabetes, and heart disease.^[5,6] The use of anticoagulant medications, increasingly common with advancing age and the presence of comorbidities, significantly elevates the risk of developing and expanding ASDH following TBI, potentially leading to higher mortality rates and poorer functional outcomes.^[7]

Anticoagulant-associated traumatic ASDH in elderly patients represents a devastating injury with high morbidity and mortality. Despite the clinical challenge posed by this growing patient population, there is limited evidence to inform effective management strategies. This study aims to quantify the mortality rate associated with the surgical treatment of ASDH in patients over 65 years of age on anticoagulants, compare it to outcomes in patients not receiving anticoagulants, identify potential risk factors for poor outcomes in this group, and assess the preventability of these outcomes.

MATERIALS AND METHODS

Patient Population

Data from patients over 65 years of age who underwent surgery for ASDH at our clinic between 2018 and 2023 were analyzed retrospectively. Patients were divided into two groups: those receiving anticoagulant therapy and those not on anticoagulant therapy. Patients under 65 years of age, those managed non-surgically for ASDH, and those with intracranial pathologies other than ASDH were excluded from the study.

A total of 90 patients met the inclusion criteria. Demographic data (age and gender) and injury-related variables (mechanism of trauma, initial Glasgow Coma Scale [GCS] score, pupillary reaction, presence of seizures, reoperation rate, and mortality) were collected. The clinical severity of TBI was classified using the GCS score as follows: mild TBI (GCS score 13-15), moderate TBI (GCS score 9-12), and severe TBI (GCS score 3-8) 8.

The study protocol was approved by the Gülhane Training and Research Hospital ethics committee (2024-169).

Radiological Evaluation

Preoperative and postoperative CT scans were used to evaluate hemorrhage localization (right, left, or bilateral), intensity, maximal hematoma thickness, midline shift, and the presence

of residual hematoma. The thickness of initial and residual hematomas was determined using axial sections. Computed tomography scans were performed 3-4 weeks after the traumatic event and subsequently every month for surveillance (Figures 1 and 2). Additionally, any new neurological symptoms prompted an immediate CT scan.

Anticoagulant Therapy

Elderly trauma patients often present with significant comorbid medical conditions and are frequently on medications that can complicate both the injury and subsequent resuscitation efforts. Anticoagulants are commonly used in this population for various indications, including atrial fibrillation, cardiac valve replacement, previous deep vein thrombosis or pulmonary embolism, chronic heart failure, pacemaker placement, coronary artery disease, and peripheral vascular disease.

The study population was divided into two groups: anticoagulant drug users and non-users. Specific anticoagulant agents

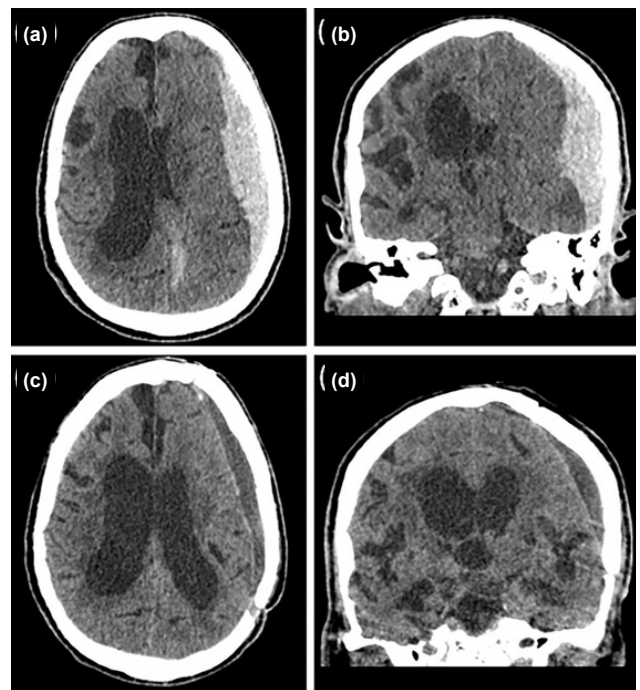


Figure 1. Axial (a) and coronal (b) computed tomography (CT) scans of an 80-year-old man on anticoagulant therapy for coronary artery disease, with an international normalized ratio (INR) within the normal range, who developed confusion after a same-level fall at home. The scans show a left temporoparietal subdural hematoma (SDH). Preoperative neurological examination revealed a Glasgow Coma Scale (GCS) score of 6 and anisocoria in the pupils. The patient underwent urgent surgery, and the SDH was evacuated via open craniotomy. Postoperatively, the patient was monitored under standard conditions in the intensive care unit for the first two days and then transitioned to the inpatient clinic for three days before being discharged home. Axial (c) and coronal (d) CT scans performed four weeks after the traumatic event show minimal subdural effusion and a reduction in brain compression.

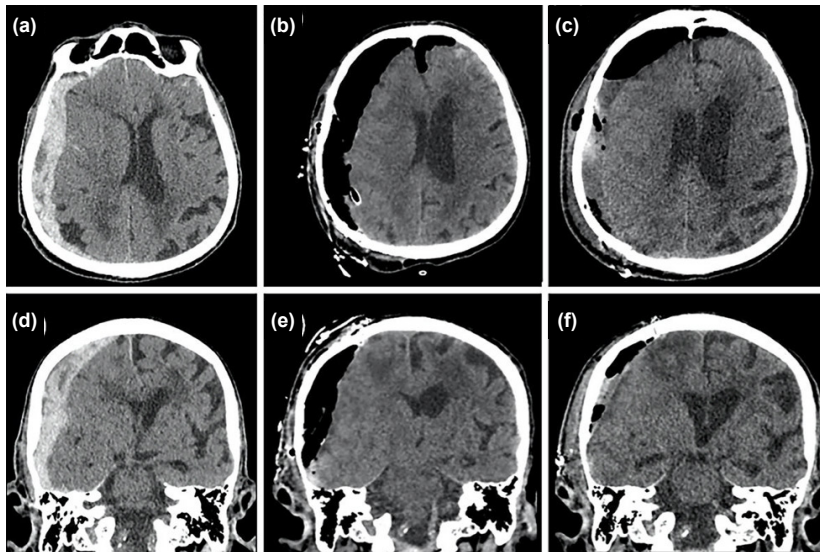


Figure 2. Axial (a) and coronal (d) CT scans of an 87-year-old man not on anticoagulant therapy, who developed confusion following a traffic accident, reveal a right frontoparietal SDH. Preoperative neurological examination indicated a GCS score of 9. The patient underwent an urgent surgery, and the SDH was evacuated via open craniotomy. Early postoperative axial (b) and coronal (e) CT scans demonstrate regression of the midline shift caused by the hematoma and pneumocephalus. Axial (c) and coronal (f) CT scans performed one week after the traumatic event show the resolution of the pneumocephalus, and no reoperation or additional intervention was required as there was no evidence of a compression effect.

and the medical indications for their use were recorded. Blood tests, including the determination of International Normalized Ratio (INR), were performed for all patients upon hospital admission. Patients with INR values above 1.4 received prothrombin complex to reverse the effects of warfarin. Prophylactic anticoagulation was initiated in non-ambulatory patients 48 to 72 hours after the traumatic event, provided the hemorrhagic findings remained stable on two consecutive CT scans.

For patients without residual subdural hematoma (SDH), warfarin was restarted with bridging using low-molecular-weight heparin until a therapeutic INR level was achieved. Patients with cardiac valve replacements were bridged using intravenous unfractionated heparin instead. For patients with residual SDH, intravenous unfractionated heparin was administered at a lower Partial Thromboplastin Time (PTT) target without a bolus injection. A follow-up head CT scan was performed 48 to 72 hours later to confirm the absence of new hematoma. If no new hematoma was detected, the patient was started on warfarin and transitioned to low-molecular-weight heparin as bridging therapy, except for cardiac valve replacement patients, who continued intravenous unfractionated heparin while warfarin was introduced until a therapeutic INR was achieved.

Surgical Procedure

Subdural hematoma was drained using either open craniot-

omy or burr hole techniques in all cases. Postoperative CT scans were performed in the early postoperative period to evaluate possible residual hematomas in all cases. Patients were monitored in the intensive care unit under standard conditions for the first two days following surgery and were then transferred to the inpatient clinic.

Statistical Analysis

IBM SPSS Statistics software version 29.0.2.0 (20) (IBM, SPSS, Chicago, Illinois, USA) was used for statistical analysis of the study data. The collected data are expressed as mean \pm standard deviation. The Shapiro-Wilk test was utilized to assess the normality of parameter distribution. The Mann-Whitney U test was applied to compare data without normal distribution between groups. Spearman's rank correlation test was employed to determine the direction and degree of relationships between variables. All tests were two-sided, and a p value of ≤ 0.05 was considered statistically significant.

RESULTS

A retrospective review identified 216 patients who underwent surgery for "traumatic SDH" in our department during the specified period. Of these, 126 patients were excluded due to failure to meet age criteria, absence of acute SDH, or insufficient data. A total of 90 patients met the inclusion criteria, comprising 54 patients (60%) who were on anticoagulants before the traumatic event and 36 patients (40%)

Table 1. Demographic and clinical characteristics of elderly patients with acute subdural hematoma

Age Mean (SD): 74.600 ± 7.658 Range: 66-92	Sex Female: 36 (40%) Male: 54 (60%)
Hematoma Location Right: 45 (50%) Left: 36 (40%) Bilateral: 9 (10%)	Hematoma Thickness : 21.216 ± 8.252 Midline shift: 10.266 ± 8.037
Etiology Fall from own height : 51 (56.7%) Fall from height: 24 (26.7) Motor vehicle accident: 9 (10%) Pedestrians hit by car: 6 (6.7%)	Anticoagulant use Yes: 54 (60%) No: 36 (40%)
GCS score Severe 3–8: 39 (43.3%) Moderate 9–12: 12 (14.4%) Mild 13–15: 39 (43.3%)	Pupil Normal: 51 (56.7) Anisocoria: 18 (20%) Fix: 21 (23.3)
Surgical technique Burr-hole: 3 (3.3%) Craniotomy: 57 (63.3) Craniectomy: 30 (33.3)	Reoperation Yes: 12 (13.3%) No: 78 (86.7)
Anticoagulant use Yes: 54 (60%) No: 36 (40%)	Mortality Alive: 21 (23.3%) Ex: 69 (76.7%)

Table 2. Comparison of radiological parameters in elderly ASDH patients with and without anticoagulant therapy

Parameters	Under anticoagulant therapy	Not under anticoagulant therapy	P value
	Mean±SD	Mean±SD	
Age	76.083±7.868	72.375±6.901	0.082
Hematoma thickness	20.027±7.012	23.000±9.713	0.250
Midline shift	10.500±7.835	9.916±8.489	0.650

Mann-Whitney U test, p<0.05

who were not. The demographic and clinical characteristics of the patients are summarized in Table 1.

Comparison between patients with and without anticoagulant therapy revealed no significant differences in age, maximum thickness of SDH, or midline shift (p>0.005) (Table 2).

Spearman’s rank correlation test indicated no significant relationship between anticoagulant therapy use and the occurrence of seizures, reoperation, or mortality. However, a significant correlation was observed between anticoagulant use

and etiology (p=0.005) (Table 3). The most common etiology of ASDH in patients on anticoagulants was a fall from their own height, while in patients not on anticoagulants, it was a fall from a height.

DISCUSSION

The incidence of TBI in individuals aged 65 years and older has noticeably increased in recent years.^[9] Recent studies conducted among the working-age population in Finland

Table 3. Outcomes and etiology of acute subdural hematoma: impact of anticoagulant therapy in elderly patients

	Yes (n:54)	No (n:36)	P value
Seizure			
Yes (n:15)	9	6	1.000
No (n:75)	45	30	
Reoperation			
Yes (n:12)	9	3	0.361
No (n:78)	45	33	
Mortality			
Alive (n:21)	9 (16.6%)	12 (33.3%)	0.139
Ex (n:69)	45 (83.4%)	24 (66.7%)	
Etiology			
Fall from own height : 51	39 (72.2%)	12 (33.3%)	0.005*
Fall from height: 24	9 (16.7%)	15 (41.7%)	
Motor vehicle accident: 9	3 (5.6%)	6 (16.7%)	
Pedestrians hit by car: 6	3 (5.6%)	3 (8.3%)	

Spearman's rank correlation test.

highlight a changing epidemiology of TBI, showing an increase in TBI-related hospitalizations in the 60-69 age group and the lowest incidence in the 30-39 age group.^[10] In the United States, children aged 0-4 years, adolescents aged 15-19 years, and adults aged 75 years and older are the most likely to have TBI-related emergency department visits or hospitalizations. Among all age groups, adults aged 65 years and older have the highest rates of TBI-related hospitalization and mortality.^[11]

Acute subdural hematoma is the most common type of injury in elderly patients admitted to the hospital following TBI. Due to cerebral atrophy associated with aging, the blood vessels between the brain and dura mater are stretched and are more prone to rupture. Therefore, older individuals are at a greater risk for developing subdural hematoma.^[12] Acute subdural hematomas are highly lethal injuries across all age groups. Historical reports from the pre-CT era cite mortality rates of 65% to 90%. However, more recently, mortality rates have decreased, likely due to advancements in the rapid diagnosis and treatment of patients with head injuries.^[13]

The Surgical Management of Traumatic Brain Injury Author Group recommends surgical evacuation for acute SDH with a thickness greater than 10 mm or a midline shift exceeding 5 mm, regardless of the GCS score at presentation. Additionally, in comatose patients (GCS score less than 9) with an SDH less than 10 mm in thickness and a midline shift less than 5 mm, surgical evacuation of the lesion is advised if the GCS score has decreased by 2 or more points between injury and admission and/or the patient exhibits asymmetric or fixed and dilated pupils and/or intracranial pressure (ICP) exceeds 20 mmHg.^[14] In patients with acute SDH and indications for surgery, surgical evacuation should be performed as soon as

possible.^[15] We adhered to these criteria when making surgical decisions and operated promptly on patients for whom surgery was indicated.

Mortality following acute subdural surgical evacuation increases sharply with advanced age, with rates estimated to reach as high as 90% in elderly patients with ASDH requiring neurosurgical intervention.^[16,17] In our study, the mortality rate was 76.7%, consistent with the literature (Table 1).

Anticoagulants are commonly prescribed for elderly patients with conditions such as mechanical heart valves or atrial fibrillation, which are associated with an elevated risk of falls and TBI. While these medications are beneficial in preventing thromboembolic events, they unfortunately complicate the management of these patients.^[18,19] Sreerama et al.^[20] highlighted that anticoagulant drug use plays a significant role in the development of SDH and recommended that patients using anticoagulants, even after minor trauma, should be evaluated for the potential of bleeding into the subdural space. Hematoma enlargement is a well-known, life-threatening risk factor in ASDH, and coagulopathy is one of the most critical risk factors for ASDH enlargement.^[21] The risk of SDH increases 4-15 times in patients receiving oral anticoagulation, as the hematoma can easily enlarge, thereby increasing the risk of death and leading to worse outcomes.^[22] Appropriate reversal of coagulopathy is the cornerstone of medical management to improve outcomes in ASDH.^[23] In our study, no significant differences were observed in hematoma thickness ($p=0.250$) or midline shift ($p=0.650$) in ASDH patients over 65 years of age, regardless of anticoagulant therapy status (Table 2). We believe this is because we administered prothrombin complex to reverse the effects of warfarin in all

patients with INR values above 1.4.

While patients receiving anticoagulant therapy face an increased risk of SDH development and enlargement, they are also at a higher risk of rebleeding after intracranial hematoma drainage, which can result in fatal outcomes. Thus, strict management of their overall condition is important.^[24] However, oral anticoagulant therapy may not increase the risk of postoperative hematoma reaccumulation if patients receive reversal agents or platelet transfusion.^[25] Our study found no significant difference in reoperation rates or mortality between patients on anticoagulant therapy and those not on anticoagulant therapy (Table 3). This aligns with some existing literature and highlights the importance of a multidisciplinary approach and timely reversal of coagulopathy in improving outcomes for these patients. However, these findings contrast with certain previous studies that reported higher mortality rates in anticoagulated patients with traumatic brain injury. The discrepancy may be attributed to the rigorous management protocols we employed, including the prompt reversal of anticoagulant effects.

Wojcik et al.^[26] compared warfarin-treated patients with a control cohort of patients who did not use anticoagulation before injury and found no significant difference in mortality. Unfortunately, this study did not evaluate the degree of anticoagulation as measured by blood product transfusions and INR. In a retrospective cohort analysis by Rozzelle et al.,^[27] the mortality rate was 27.8% in patients with SDH who underwent anticoagulation compared to 30% in those who did not, with no significant difference. Karni et al.,^[28] Mina et al.,^[29] Lavoie et al.,^[30] Franko et al.,^[31] Cohen et al.,^[32] and Pieracci et al.^[33] found a direct positive correlation between warfarin use before traumatic head injury and mortality compared to control patients. In these studies, the absolute difference in mortality rates between control and warfarin-treated patients ranged from 19% to 30%. Although previous studies have predominantly established a clear link between anticoagulant use and an increased incidence of ASDH and mortality, our results show no significant difference in critical radiological parameters such as haematoma thickness and midline shift between patients with and without anticoagulant therapy (Table 2). These findings suggest that appropriate reversal of coagulopathy may mitigate the adverse effects of anticoagulant use in this population.

Falls are the most common mechanism of injury causing ASDH, which aligns with our observations.^[11] However, our study highlights a significant difference in the mechanism of injury between the anticoagulated and non-anticoagulated groups ($p=0.005$). While a fall from the same level was the most common cause of ASDH in anticoagulated patients, a fall from a height was more common in non-anticoagulated patients ($p=0.005$) (Table 3). This suggests that anticoagulant use increases susceptibility to ASDH even with lower-energy traumas. Although it is already known that even minor trauma can lead to ASDH in elderly patients on anticoagulants,

our study provides a focused analysis of patients requiring surgical intervention, detailing mortality, reoperation rates, and neurological outcomes. We believe it may be possible to prevent the occurrence of ASDH with such high mortality and morbidity, particularly by protecting elderly patients on anticoagulants from trauma.

The results of our study have important clinical implications for the management and prevention of ASDH in elderly patients on anticoagulants. The fact that even low-energy trauma can result in significant neurological injury in this population underscores the need for preventive strategies. Protecting these at-risk patients from trauma is critical, and clinicians should remain vigilant in assessing the potential for ASDH even after minor injuries. Additionally, our findings suggest that careful management of anticoagulation, including timely reversal and multidisciplinary care, can mitigate some of the risks associated with surgical intervention in these patients.

The limitations of this study include its retrospective nature and the focus solely on patients requiring surgical intervention. The single-center design may also limit the generalizability of the findings to other hospitals that do not have the same resources and ancillary services available in a Level I Tertiary Referral Center. The complexity of interdisciplinary teams may not be replicable in smaller hospitals, and consequently, the results of this study may not be universally applicable. However, it is important to note that the multidisciplinary approach and protocols for reversing coagulopathy likely contributed to the outcomes observed in our study. Future research should include non-surgical cases and expand to multiple centers to validate these findings.

CONCLUSION

Our study highlights the challenges associated with managing ASDH, particularly in elderly patients on anticoagulant therapy. While mortality and reoperation rates did not differ significantly between anticoagulated and non-anticoagulated patients, the etiology of injury differed significantly, with minor falls causing serious consequences in anticoagulated patients. These findings demonstrate that even minor trauma can result in life-threatening ASDH in this vulnerable population, underscoring the importance of preventive measures. Our study's comprehensive approach to managing anticoagulated patients, including the prompt reversal of coagulopathy, likely contributed to the observed outcomes and offers a potential protocol to improve survival in this high-risk group. Future research should aim to expand the patient population to include non-surgical cases and validate these findings in multiple centers.

Ethics Committee Approval: This study was approved by the Gülhane Training and Research Hospital Ethics Committee (Date: 24.04.2024, Decision No: 2024-169).

Peer-review: Externally peer-reviewed.

Authorship Contributions: Concept: S.Y., D.E.K.; Design:

M.C.E., G.K.; Supervision: S.Y., M.C.E.; Resource: S.Y., M.C.E.; Materials: D.E.K., G.K.; Data collection and/or processing: D.E.K., G.K.; Analysis and/or interpretation: D.E.K., G.K.; Literature review: D.E.K., G.K.; Writing: S.Y., D.E.K., G.K.; Critical review: S.Y.

Conflict of Interest: None declared.

Financial Disclosure: The author declared that this study has received no financial support.

REFERENCES

1. The world population prospects 2019: Highlights. Available from: https://population.un.org/wpp/Publications/Files/wpp2019_10KeyFindings.pdf. Accessed: Nov 25, 2024.
2. Gardner RC, Dams-O'Connor K, Morrissey MR, Manley GT. Geriatric traumatic brain injury: Epidemiology, outcomes, knowledge gaps, and future directions. *J Neurotrauma* 2018;35:889–906.
3. Karibe H, Hayashi T, Hirano T, Kameyama M, Nakagawa A, Tominaga T. Surgical management of traumatic acute subdural hematoma in adults: A review. *Neurol Med Chir (Tokyo)* 2014;54:887–94.
4. Evans LR, Jones J, Lee HQ, Gantner D, Jaison A, Matthew J, et al. Prognosis of acute subdural hematoma in the elderly: A systematic review. *J Neurotrauma* 2019;36:517–22.
5. Manivannan S, Spencer R, Marei O, Mayo I, Elalfy O, Martin et al. Acute subdural haematoma in the elderly: To operate or not to operate? A systematic review and meta-analysis of outcomes following surgery. *BMJ Open* 2021;11:e050786.
6. McGwin G Jr, MacLennan PA, Fife JB, Davis GG, Rue LW 3rd. Pre-existing conditions and mortality in older trauma patients. *J Trauma* 2004;56:1291–6.
7. Laic RAG, Verhamme P, Vander Sloten J, Depreitere B. Long-term outcomes after traumatic brain injury in elderly patients on antithrombotic therapy. *Acta Neurochir (Wien)* 2023;165:1297–307.
8. Khellaf A, Khan DZ, Helmy A. Recent advances in traumatic brain injury. *J Neurol* 2019;266:2878–89.
9. Maas AIR, Menon DK, Adelson PD, Andelic N, Bell MJ, Belli A, et al; InTBIR Participants and Investigators. Traumatic brain injury: Integrated approaches to improve prevention, clinical care, and research. *Lancet Neurol* 2017;16:987–1048.
10. Posti JP, Luoto TM, Sipilä JOT, Rautava P, Kytö V. Changing epidemiology of traumatic brain injury among the working-aged in Finland: Admissions and neurosurgical operations. *Acta Neurol Scand* 2022;146:34–41.
11. Faul M, Coronado V. Epidemiology of traumatic brain injury. *Handb Clin Neurol* 2015;127:3–13.
12. Harvey LA, Close JC. Traumatic brain injury in older adults: Characteristics, causes and consequences. *Injury* 2012;43:1821–6. Erratum in: *Injury* 2013;44:277.
13. Howard MA 3rd, Gross AS, Dacey RG Jr, Winn HR. Acute subdural hematomas: An age-dependent clinical entity. *J Neurosurg* 1989;71:858–63.
14. Sharma R, Rocha E, Pasi M, Lee H, Patel A, Singhal AB. Subdural hematoma: Predictors of outcome and a score to guide surgical decision-making. *J Stroke Cerebrovasc Dis* 2020;29:105180.
15. Bullock MR, Chesnut R, Ghajar J, Gordon D, Hartl R, Newell DW, et al; Surgical Management of Traumatic Brain Injury Author Group. Surgical management of acute subdural hematomas. *Neurosurgery* 2006;58(3 Suppl):S16–24; discussion S1–iv.
16. Cagetti B, Cossu M, Pau A, Rivano C, Viale G. The outcome from acute subdural and epidural intracranial haematomas in very elderly patients. *Br J Neurosurg* 1992;6:227–31.
17. Monsivais D, Choi HA, Kitagawa R, Franch M, Cai C. A retrospective analysis of surgical outcomes for acute subdural hematoma in an elderly cohort. *Interdisciplinary Neurosurgery* 2018;14:130–4.
18. Patients with nonvalvular atrial fibrillation at low risk of stroke during treatment with aspirin: Stroke prevention in atrial fibrillation III study. The SPAF III Writing Committee for the stroke prevention in atrial fibrillation investigators. *JAMA* 1998
19. Cannegieter SC, Rosendaal FR, Briët E. Thromboembolic and bleeding complications in patients with mechanical heart valve prostheses. *Circulation* 1994;89:635–41.
20. Sreerama V, Ivan LP, Dennery JM, Richard MT. Neurosurgical complications of anticoagulant therapy. *Can Med Assoc J* 1973;108:305–7.
21. Bershady EM, Farhadi S, Suri MF, Feen ES, Hernandez OH, Selman WR, et al. Coagulopathy and inhospital deaths in patients with acute subdural hematoma. *J Neurosurg* 2008;109:664–9.
22. Wintzen AR, Tijssen JG. Subdural hematoma and oral anticoagulant therapy. *Arch Neurol* 1982;39:69–72.
23. Frontera JA, Lewin JJ 3rd, Rabinstein AA, Aisiku IP, Alexandrov AW, Cook AM, et al. Guideline for reversal of antithrombotics in intracranial hemorrhage: A statement for healthcare professionals from the Neurocritical Care Society and Society of Critical Care Medicine. *Neurocrit Care* 2016;24:6–46.
24. Kawamata T, Takeshita M, Kubo O, Izawa M, Kagawa M, Takakura K. Management of intracranial hemorrhage associated with anticoagulant therapy. *Surg Neurol* 1995;44:438–42; discussion 443.
25. Pancyzkowski DM, Okonkwo DO. Premorbid oral antithrombotic therapy and risk for reaccumulation, reoperation, and mortality in acute subdural hematomas. *J Neurosurg* 2011;114:47–52.
26. Wojcik R, Cipolle MD, Seislove E, Wasser TE, Pasquale MD. Preinjury warfarin does not impact outcome in trauma patients. *J Trauma* 2001;51:1147–51; discussion 1151–2.
27. Rozzelle CJ, Wofford JL, Branch CL. Predictors of hospital mortality in older patients with subdural hematoma. *J Am Geriatr Soc* 1995;43:240–4.
28. Karni A, Holtzman R, Bass T, Zorman G, Carter L, Rodriguez L, et al. Traumatic head injury in the anticoagulated elderly patient: A lethal combination. *Am Surg* 2001;67:1098–100.
29. Mina AA, Knipfer JF, Park DY, Bair HA, Howells GA, Bendick PJ. Intracranial complications of preinjury anticoagulation in trauma patients with head injury. *J Trauma* 2002;53:668–72.
30. Lavoie A, Ratte S, Clas D, Demers J, Moore L, Martin M, et al. Preinjury warfarin use among elderly patients with closed head injuries in a trauma center. *J Trauma* 2004;56:802–7.
31. Franko J, Kish KJ, O'Connell BG, Subramanian S, Yuschak JV. Advanced age and preinjury warfarin anticoagulation increase the risk of mortality after head trauma. *J Trauma* 2006;61:107–10.
32. Cohen DB, Rinker C, Wilberger JE. Traumatic brain injury in anticoagulated patients. *J Trauma* 2006;60:553–7.
33. Pieracci FM, Eachempati SR, Shou J, Hydo LJ, Barie PS. Degree of anticoagulation, but not warfarin use itself, predicts adverse outcomes after traumatic brain injury in elderly trauma patients. *J Trauma* 2007;63:525–30.

ORİJİNAL ÇALIŞMA - ÖZ

Yaşlı hastalarda akut subdural hematomun karmaşıklığını çözmek: Antikoagülan tedavinin etkisi ve daha iyi sonuçların peşinde

AMAÇ: Akut subdural hematom (ASDH), özellikle antikoagülan tedavi gören yaşlı hastalarda kritik ve sıklıkla ölümcül bir durumdur. Yaşlanan küresel nüfusla birlikte, ASDH dahil olmak üzere travmatik beyin yaralanmalarının görülme sıklığının artması ve klinik yönetimde önemli bir zorluk oluşturması beklenmektedir. Cerrahi olarak tedavi edilen 65 yaş üstü ASDH hastalarının sonuçlarını değerlendirmeyi amaçlayan bu çalışmada, antikoagülan tedavi alanlar almayanlarla karşılaştırılmıştır. Ayrıca, kötü sonuçlar için ana risk faktörlerinin belirlenmesi ve bu hassas popülasyonda önleyici stratejilerin potansiyelinin araştırılması amaçlanmıştır.

GEREÇ VE YÖNTEM: 2018-2023 yılları arasında kurumumuzda ASDH nedeniyle ameliyat edilen 65 yaş ve üzeri 90 hasta üzerinde retrospektif bir analiz yapıldı. Hastalar antikoagülan tedavi kullanımına göre iki gruba ayrılmıştır. Demografik veriler, yaralanma mekanizmaları, klinik tablolar ve mortalite ve reoperasyon oranları dahil olmak üzere sonuçlar analiz edilmiştir. Radyolojik değerlendirmeler hematom kalınlığı, orta hat kayması ve rezidüel hematom varlığını içeriyordu.

BULGULAR: Antikoagülan kullanan ve kullanmayan hastalar arasında hematom kalınlığı, orta hat kayması veya mortalite açısından anlamlı bir fark bulunmamıştır. Bununla birlikte, antikoagülan kullanımı ile yaralanma mekanizması arasında anlamlı bir ilişki gözlenmiştir; antikoagülan kullanan hastalarda aynı seviyeden düşme gibi düşük enerjili travma sonucu ASDH gelişme olasılığı daha yüksektir ($p=0.005$). Yaşlılarda ASDH ile ilişkili yüksek mortalite oranına rağmen, koagülopatinin derhal tersine çevrilmesini de içeren multidisipliner yaklaşımımız muhtemelen gözlemlenen sonuçlara katkıda bulunmuştur.

SONUÇ: Yaşlı hastalarda, özellikle de antikoagülan kullananlarda ASDH, yüksek oranda kötü sonuçlara yol açan zorlu bir sorun olmaya devam etmektedir. Bu çalışma, özellikle antikoagülan kullanan hastalarda küçük travmalarla bile ilişkili riskleri azaltmak için dikkatli önleyici tedbirlere duyulan ihtiyacı altını çizmektedir. Bulgularımız, koagülopatinin zamanında tersine çevrilmesi de dahil olmak üzere uygun yönetim protokollerinin bu yüksek riskli popülasyonda sağ kalımı iyileştirmek için kritik öneme sahip olduğunu göstermektedir. Kapsamlı önleyici stratejiler geliştirmek ve doğrulamak ve bu hastalarda uzun vadeli sonuçları araştırmak için daha fazla araştırmaya ihtiyaç vardır.

Anahtar sözcükler: Akut subdural hematom; antikoagülan tedavi; geriatrik travma; travmatik beyin hasarı; yaşlı hastalar.

Ulus Travma Acil Cerrahi Derg 2025;31(1):32-39 DOI: 10.14744/tjtes.2024.63489