

## An evaluation of individual plain abdominal radiography findings in pediatric appendicitis: results from a series of 424 children

Çocuk apandisitlerinde düz karın radyografisi bulgularına yönelik bir değerlendirme:  
424 çocuk içeren bir serinin sonuçları

Çiğdem Ulukaya DURAKBAŞA,<sup>1</sup> İnkılap TAŞBAŞI,<sup>2</sup> Ahmet Nadir TOSYALI,<sup>1</sup> Murat MUTUS,<sup>1</sup>  
Varol ŞEHİRALTI,<sup>1</sup> Ebru ZEMHERİ<sup>3</sup>

### BACKGROUND

This study was conducted to collect the results of the plain abdominal radiography (PAR) signs, to determine their individual diagnostic values, and to discuss them under a brief literature review.

### METHODS

Eight predetermined PAR signs were individually interpreted in a series of 424 consecutive children (278 males; 146 females; median age 10 years; range 11 months to 17 years) who underwent an operation for appendicitis. The sensitivity, specificity, and positive and negative predictive values for the signs were determined.

### RESULTS

Appendicitis was confirmed in 378 (89%) patients. Among the remaining 46 (11%) patients with a normal appendix, 20 (5%) had other intraabdominal pathologies. Calcified fecalith, mass image in right-lower-quadrant (RLQ), psoas obscuration, and localized extraluminal air signs were all highly specific and therefore, unlikely to be present if the appendix is normal. On the other hand, the sensitivity values were low, in general, for all the PAR signs investigated. Yet, presence of dilated transverse colon and/or single air fluid level in the RLQ has the highest percentage occurrence with appendicitis.

### CONCLUSION

Although there is no single PAR finding capable of ruling the diagnosis of appendicitis out, basic knowledge on PAR findings could have an impact on decision making process for clinicians dealing with pediatric acute abdominal pain.

**Key Words:** Appendectomy; appendicitis/diagnosis/radiography/surgery; child; diagnosis, differential; pediatrics; tomography, X-ray computed/methods.

### AMAÇ

Akut apandisiti olan çocukların düz karın radyografisi (DKG) bulgularının derlenmesi ve bu bulguların her birinin tanısal değerini ortaya koyarak; konuyla ilgili yayımlanmış çalışmalar ışığında yorumlanması amaçlandı.

### GEREÇ VE YÖNTEM

Apandisit öntanısı ile ameliyat edilen 424 çocuğu içeren grup (278 erkek; 146 kız; ortanca yaş 10; dağılım 11 ay - 17 yıl) önceden belirlenmiş sekiz DKG bulgusu ile değerlendirmeye alındı. Her bir bulgu için duyarlılık, seçicilik, pozitif ve negatif sonucu belirleme değerleri ayrı ayrı hesaplandı.

### BULGULAR

Ameliyat bulguları ve patolojik değerlendirme ile hastaların 378'inde (%89) apandisit mevcuttu, 46 (%11) hastada ise apandiks normaldi. Bunların 20'sinde (%5) başka karın içi patolojik bulgu saptandı. DKG bulguları içinde, kalsifiye fekalit, sağ alt kadranda kitle görünümü, psoas silinmesi ve lokalize lümen dışı hava bulgularının seçiciliği çok yüksekti; apandiks normale bu bulguların görülme olasılığı çok zayıftır. Değerlendirilen DKG bulgularının hepsinin duyarlılığı düşük bulunmakla beraber, apandisiti olan olgularda genişlemiş transvers kolon ve/veya sağ alt kadranda tek hava-sıvı seviyesi bulgularının görülme olasılığı diğerlerinden daha yüksekti.

### SONUÇ

Ayrırcı tanıda apandisit olasılığını tamamen ortadan kaldıracak tek bir DKG bulgusu olmamakla beraber, olası DKG bulgularına yönelik temel bilgilere sahip olmak, çocuklarda akut karın ağrısı ile ilgilenen hekimlerin karar mekanizmasında etkide bulunabilir.

**Anahtar Sözcükler:** Apendektomi; apandisit/tanı/radyografi/cerrahi; çocuk; tanı, ayrırcı; pediatri; tomografi, X-ışını kompüterize/yöntem.

Departments of <sup>1</sup>Pediatric Surgery, <sup>2</sup>Radiology and <sup>3</sup>Pathology SSK Göztepe Training and Research Hospital, İstanbul, Turkey.

SSK Göztepe Eğitim ve Araştırma Hastanesi, <sup>1</sup>Çocuk Cerrahisi Kliniği, <sup>2</sup>Radyoloji Kliniği, <sup>3</sup>Patoloji Kliniği, İstanbul.

Acute appendicitis is the most common abdominal surgical emergency.<sup>[1]</sup> It is generally agreed that physical examination may be sufficient for diagnosis in cases with classical symptoms and signs, but unfortunately such a clinical diagnosis is not always straightforward, especially when the children are concerned. Although plain abdominal radiography (PAR) is the conventional first-line radiological imaging modality, novel methods like ultrasound, computerized tomography (CT) and magnetic resonance imaging (MRI) have been employed in the initial evaluation of children with acute abdominal pain in order to obtain an accurate diagnosis.<sup>[2-4]</sup> As the tendency to use these new and modern radiological tools is increasing, the place of PAR in initial evaluation of children with abdominal pain has been questioned extensively by some authors.<sup>[5,6]</sup> However, independent of the debate on its use, PAR is still very commonly employed at surprisingly high rates in those children in very many recently reported series as a simple, cheap, easily accessible, and reproducible radiological aid.<sup>[5,7,8]</sup> Despite the continuing use of PAR in initial stages of evaluation of acute abdominal pain in children, there is no contemporary study evaluating the diagnostic sensitivity, specificity, and predictive values of all probable PAR findings in pediatric acute appendicitis.

The goals of this study are to collect the probable PAR signs in a single large series of pediatric patients and to determine their individual diagnostic values by means of their sensitivity, specificity, and positive and negative predictive value rates. The significance of these PAR findings in acute appendicitis is discussed under a brief review of available literature.

## MATERIALS AND METHODS

Children who underwent surgery with a presumed diagnosis of appendicitis at the department of pediatric surgery between January 2001 and December 2003 were included in the study. They were referred either from affiliated medical centers or from the hospital's own emergency department. Some children had already undergone diagnostic work up which might include PAR, whereas, some did not have any work up upon admission to the pediatric surgical clinic. There is no local policy to require PAR and no attempt was made to alter the

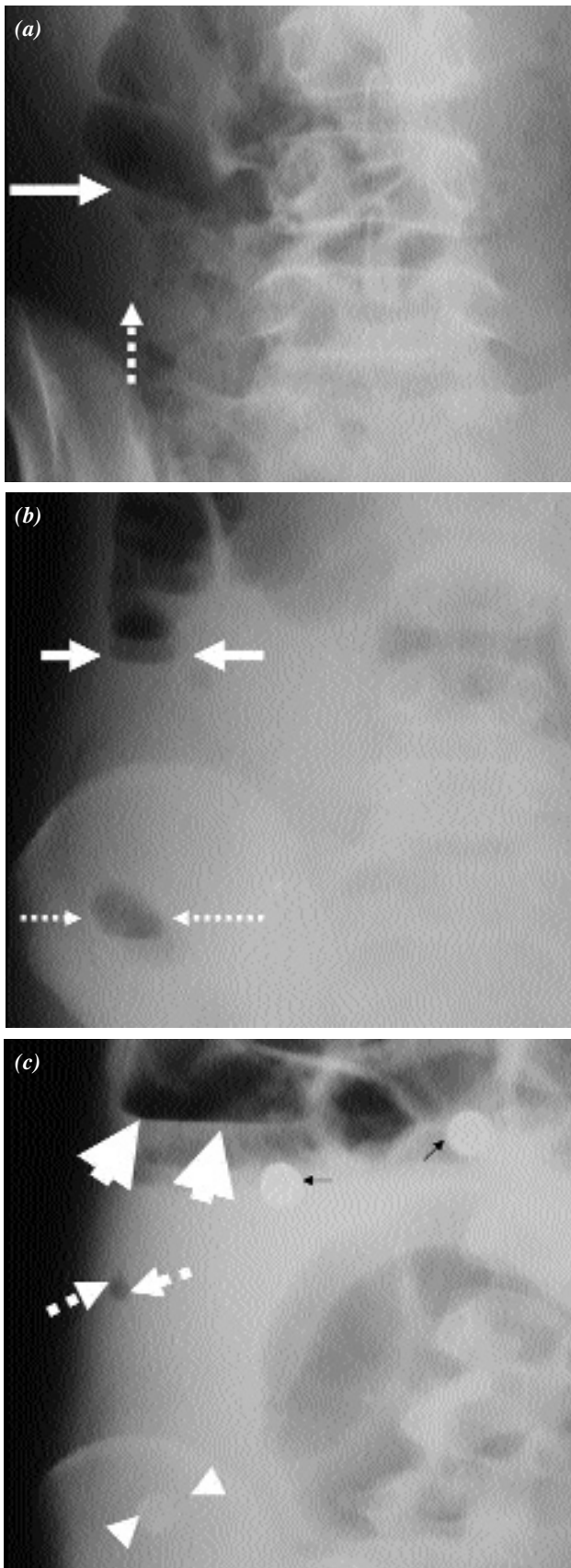
clinicians' behavior in ordering the X-rays. After a clinical evaluation, all surgeries were performed by one of the four consultant pediatric surgeons. The operating surgeon filled out a form including the demographic data and operative findings right after each operation. For each patient, a single radiologist, blind to the clinical findings and other radiological investigations which might have been performed, made retrospective PAR evaluation by taking notes about the presence or absence of each of the eight predetermined criteria as follows: dilated transverse colon (DTC) sign (a cut off on colonic gas shadow at the level of hepatic flexure) (Figs. 1a-c), single air-fluid level in right lower quadrant (RLQ), i.e. cecal ileus, (Fig. 1b), multiple air-fluid levels (more than three air-fluid levels in the small intestine) (Figs. 1d, e), lumbar scoliosis concave to the right (Fig. 2), calcified fecalith (Figs. 1a, c, d), mass image (increased density) in the RLQ (Fig. 3), psoas obscuration (Fig. 2), and localized extraluminal air (Fig. 1c).

Pathology reports of all patients were reviewed to check the final discharge diagnosis which was classified into one of the following three categories: acute (nonperforated) appendicitis, perforated appendicitis (with localized or generalized peritonitis), and no appendiceal pathologic diagnosis ("negative appendectomy"). The pathological diagnosis was considered as the correct final diagnosis.

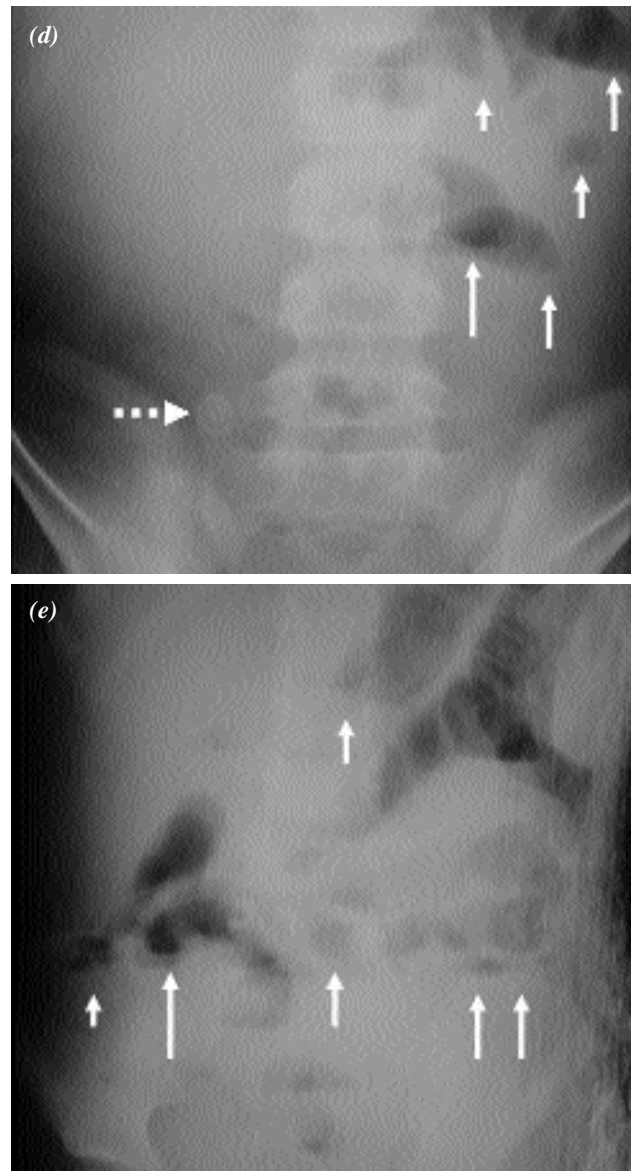
Data were analyzed to determine the sensitivity (the percentage that each sign was present on PAR in patients with appendicitis), specificity (the percentage that each sign was not present on PAR in patients with normal appendix), positive predictive value (the percentage probability for each sign that a patient has appendicitis when the sign was present on PAR), and negative predictive value (the percentage probability for each sign that a patient has not appendicitis when the sign is not present on PAR) of the aforementioned radiological criteria according to the discharge diagnosis.

## RESULTS

There were 627 children who underwent surgery with a presumed diagnosis of appendicitis during the study period, 424 (68%) of whom received one or more plain erect abdominal radiograph as part of their initial evaluation. PAR was ordered in only 39 (9%) children by the operating pediatric surgeon



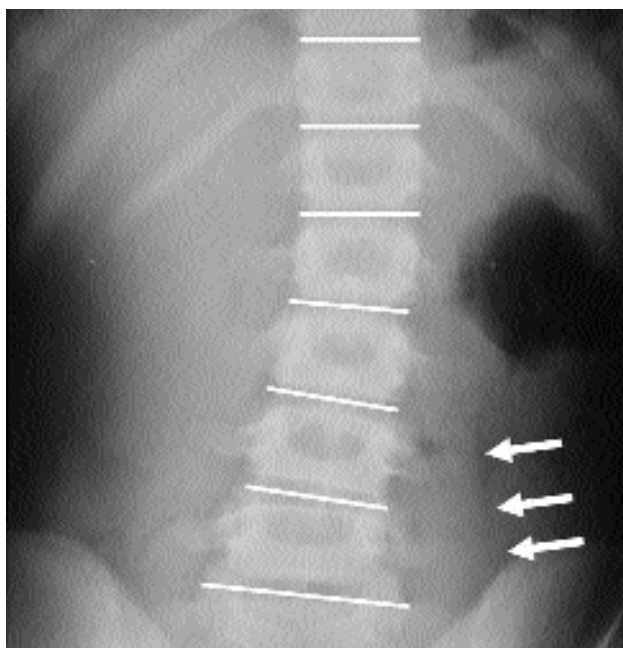
and the remaining 385 (91%) had already PAR taken when they were first seen by the operating surgeon. These 424 children who had preoperative PAR constituted the study population. There were 278 (66%) male and 146 (34%) female patients with median age of 10 years (range: 11 months to 17 years). Acute non-perforated appendicitis was



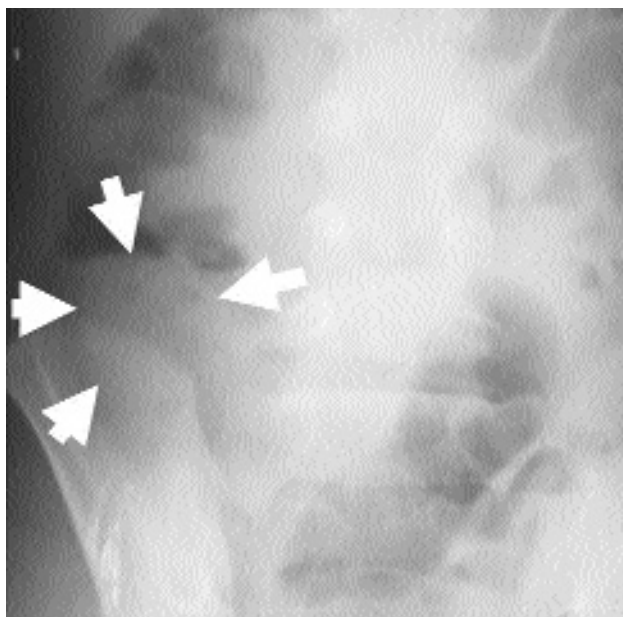
**Fig. 1.** (a) Plain abdominal radiography (PAR) view of DTC (arrow) sign and a calcified fecalith (dashed arrow); (b) DTC sign (arrows) and RLQ single air fluid level (dashed arrows); (c) DTC sign (arrows), localized extraluminal air (dashed arrows), and a calcified fecalith (arrow heads). Black arrows indicate two artifacts; (d) a calcified lamellated fecalith (dashed arrow) and multiple air fluid levels (arrows); (e) multiple air fluid levels (arrows).



diagnosed clinically and confirmed pathologically in 199 of 424 (47%) patients. Perforated appendicitis was diagnosed in 179 (42%) patients and a normal appendix was identified intra-operatively and confirmed pathologically in 46 (11%). On the other hand, 20 of the 46 patients ending up with a negative appendectomy had intraabdominal pathologies



**Fig. 2.** Lumbar scoliosis concave to the right (intervertebral spaces delineated) and obscuration of psoas shadow on the right side (left psoas shadow is indicated by arrows) on PAR.



**Fig. 3.** PAR view of the RLQ mass image (arrows).

other than appendicitis: primary peritonitis (9), ovarian pathology (4), complicated Meckel's diverticulum (4), cecal perforation (1), tuberculosis (1), and carcinoid tumor (1).

Sensitivity, specificity, and positive and negative predictive values of individual PAR findings together with true and false positivity and the false negativity figures are given in Table 1.

#### *Dilated transverse colon (DTC) sign:*

DTC sign was present in 212 (50%) patients. Among these, 96 (45%) had acute and 103 (49%) had perforated appendicitis. This sign has the highest sensitivity rate (53%) in the present study. It was falsely positive in 13 patients and the specificity rate, thus calculated, was 72% and the positive predictive value 94%. There was a slight difference between sensitivity rates of the acute (48%) and the perforated cases (58%), when considered separately.

#### *Single air-fluid level in the RLQ (cecal ileus):*

A single air-fluid level in the RLQ was regarded as positive in PAR of 193 (46%) patients: 182 had either acute (105, 54%) or perforated (77, 40%) appendicitis, whereas the appendices were normal in 11 (6%) patients. The sensitivity rates were quite similar in the acute and the perforated cases if calculated separately (47% vs. 43%, respectively).

Because the individual probabilities that the DTC and the cecal ileus signs to be present on PAR in patients with appendicitis were higher than the remaining six PAR signs, the sensitivity and negative predictive values for the presence of either one or both of them were also calculated. There were 378 patients who had either acute or perforated appendicitis. Of these, 289 had either DTC and/or cecal ileus sign detected on PAR (true positives) and 89 had neither of them (false negatives). Additionally, among the 46 patients in the negative appendectomy group, 19 had either one or both of these signs on PAR (false positives) and the remaining 27 had neither of them (true negatives). Thus, the presence of either or both of DTC and cecal ileus signs increased the sensitivity to 76% and the negative predictive value to 23%.

#### *Multiple air-fluid levels:*

Multiple air-fluid levels were seen on PAR of 114 (51%) patients. Among these, 25 (22%) had

**Table 1.** Sensitivity, specificity, and positive and negative predictive value rates of individual PAR findings

	TP	TN	FN	Sensitivity	Specificity	PPV	NPV
Dilated transverse colon	199	33	179	53	72	94	15
Single air-fluid level in RLQ	182	35	196	48	76	94	15
Multiple air fluid levels	109	41	269	29	89	96	13
Lumbar scoliosis	58	40	320	15	87	90	11
Calcified fecalith	32	46	346	8	100	100	12
Mass image in RLQ	18	45	360	5	98	95	11
Psoas obscuration	11	45	367	3	98	92	11
Localized extraluminal air	6	46	372	2	100	100	11

TP: True positives; TN: True negatives; FN: False negatives; PPV: Positive predictive value; NPV: Negative predictive value.

acute and 84 (74%) had perforated appendicitis. Multiple air-fluid levels sign was falsely regarded as positive only in five cases in the whole group, and thus, had a specificity of 89%, and positive predictive value 96%.

In order to test whether perforation causes multiple air-fluid levels more often than the rest of the group, some additional calculations were done. Among the 179 patients with perforated appendicitis, 95 did not have multiple air-fluid levels on PAR and regarded as false negatives. The sensitivity rate for presence of multiple air-fluid levels on PAR to diagnose perforated appendicitis was thus calculated to be 47% and the negative predictive value 70%.

*Lumbar scoliosis:*

PAR of 64 (15%) patients showed evidence of lumbar scoliosis concave to the right. Among them, 58 had either acute or perforated appendicitis (15% sensitivity). The sensitivity rate was almost equal in the acute and the perforated cases when considered separately (15% and 16%, respectively). PAR of six patients in normal appendectomy group were positive for lumbar scoliosis and thus, the specificity, that is the likelihood that scoliosis was not present in normal appendix cases, was 87%.

*Calcified fecalith:*

According to the operation forms and/or pathology reports, a fecalith was present in 76 (18%) patients. Among them, 27 (36%) had acute and 44 (58%) had perforated appendicitis. There were 5 (6%) patients who proved to have normal appendices despite the presence of fecaliths by histopathological examination. A calcified fecalith was visualized by PAR in 32 (42%) of these 76

patients: 17 with acute and 15 with perforated appendicitis. None of the five fecaliths in histopathologically normal appendices could be seen on PAR. The definitive diagnosis was either acute or perforated appendicitis in all patients with a fecalith visualized on PAR. Therefore, although the sensitivity of detecting a fecalith on PAR was only 8%, the specificity was 100% with a positive predictive value of 100%.

If the figures were calculated in regard to the ability of PAR to detect the presence of a fecalith in those who actually proved to have one, the results would be somewhat different. PAR could not detect a fecalith in 44 patients among the 76 patients who actually had one, whereas, it did not detect a fecalith in any case of normal appendectomy group. Therefore, PAR was 42% sensitive and 100% specific for the detecting presence of a fecalith in those who have it. The relevant positive and negative predictive values for the probability of PAR in detecting a fecalith on PAR were 62% and 88%, respectively.

*Mass image in the RLQ, psoas obscuration and extraluminal air:*

Mass image was present in 19 (4%) patients, right psoas obscuration in 12 (3%), and localized extraluminal air in 6 (1%). Among these, mass image in the RLQ and psoas obscuration signs were falsely positive each in one patient in the normal appendectomy group, and extraluminal air sign was not positive in any patient of that group. Therefore, although these three signs had the lowest sensitivity and negative predictive value rates, they all were highly specific for appendicitis in the present series.

## DISCUSSION

Despite the vertiginous development of technology in radiology during the last two decades and the increasing use of novel modalities in ascertaining the diagnosis of acute appendicitis, in many reported series, PAR is still the first-line radiological employment in evaluating the children with acute abdominal pain.<sup>[9-12]</sup> This fact holds true even in reported series in which the authors recommend against the use of PAR for diagnosis of acute appendicitis. In one such report, 78% of 821 consecutive patients hospitalized for suspected appendicitis had preoperative PAR evaluation despite the authors' statement that "PAR should not be routinely employed on patients with suspected appendicitis".<sup>[5]</sup>

In 2003, Newman et al.<sup>[7]</sup> examined the current practice and outcomes of 30 pediatric hospitals in the care of appendicitis in 3393 children. They found out that the use of PAR varied from 6% to 78% (median, 41%) for nonperforated appendicitis and from 24% to 100% (median, 56%) for perforated appendicitis.<sup>[7]</sup> In another study reviewing 120 children who were aged 5 years or less and underwent operation for appendicitis it was found out that an abdominal radiograph was obtained in 87%.<sup>[8]</sup> It is clear from these published data that considerable number of children with suspected appendicitis still undergoes PAR examination in this "modern era".

In the present series, among 627 children with clinical findings suggestive of appendicitis, 424 (68%) had a preoperative PAR taken. This rate is in accordance with the previously published series.<sup>[5-8, 12]</sup> This continuing use of PAR may be due to the facts that abdominal pain is a common nominator in many pediatric diseases whether the cause is surgical or not and also the initial evaluation of children with abdominal pain may be performed by a primary care physician or a specialist.<sup>[7]</sup> This theory is supported by the present series in which only 9% of PAR was ordered by the operating pediatric surgeon and the rest was ordered by the physicians who had taken care of these children in the initial stages of evaluation. Given the above data, with such high numbers of children having PAR examination in reported series, we believe that PAR still deserves to be taken into account by surgeons in decision making process for a child with symptoms suggestive of appendicitis. The present study did not aim to rec-

ommend either against or in favor of use of PAR in suspected pediatric appendicitis, but instead, aimed to gather the probable PAR signs and discuss their individual sensitivity, specificity, and predictive values because it was supposed that gathering the data and figuring out the precise diagnostic accuracies of all probable individual PAR findings in children could be of some help in that manner.

All children in this series were examined and operated on by a pediatric surgeon with the presumptive diagnosis of acute or perforated appendicitis and therefore, the results obtained herein are applicable only to those children who bear the physical signs and symptoms suggestive of appendicitis. The present study showed that the reliability of a negative test result was not high for any single one of the eight signs tested as denoted by the low negative predictive values obtained for each. In other words, the absence of any of the tested signs did not mean the absence of the disease most of the time. However, the individual positive predictive values of these signs were all above or equal to 90%. That brings the conclusion that a positive test result, which is the presence of that specific sign on PAR was more reliable in terms of presence of appendiceal pathology in a pediatric patient with associated suggestive clinical findings.

Among the radiological signs investigated, DTC sign together with the single air-fluid level in the RLQ had the highest percentage occurrences with appendicitis. DTC sign, first described by Swischuk and Hayden<sup>[13]</sup> in 1980, was thought to be an early radiological predictor of perforation by the authors, because all 10 of their patients having this sign were perforated. They believed that DTC sign resulted from a combination of paralytic ileus of the transverse colon and spasm of the ascending colon. The value of this sign as an indicator of perforation was further validated by another study including the PAR of 37 patients under the age of 18 years.<sup>[14]</sup> Although the sensitivity of DTC sign was slightly higher for perforated appendicitis cases in the present series (58% vs. 48%) as well, it is clearly evident that it is not a unique sign for perforation. Nevertheless, we agree with Swischuk and Hayden<sup>[13]</sup> that once appreciated, DTC sign can be regarded as a valuable asset in the plain film assessment of appendicitis. Although first described in 1958,<sup>[14]</sup> the published data about single air-fluid



level in the RLQ (cecal ileus sign) as a radiological diagnostic tool in appendicitis is surprisingly scarce. One study including 30 pediatric and adult patients with PAR found RLQ ileus in 21 (70%).<sup>[15]</sup> The present study showed that it could be detected in roughly half of the children with appendicitis and the sensitivity of this sign for appendicitis is almost equal to that of DTC sign. If the presence of either DTC sign and/or single air-fluid level in RLQ is considered as positive, the sensitivity rate increases up to 76% which practically means most of the children who has appendicitis will have at least one of these two signs on PAR. This result contradicts with a previous statement which is “plain films are often normal in cases with appendicitis, particularly if the appendix is not perforated”.<sup>[10]</sup> On the contrary, plain films are not usually normal in children, whether it is an acute or a perforated appendicitis case.

PAR showing more than three small intestinal air-fluid levels, no matter whether localized or generalized, were considered positive for “multiple” air-fluid levels in this study. Among the 114 patients with multiple air-fluid levels 84 (74%) were perforated. Both the sensitivity (47%) and the negative predictive value (70%) results for detecting multiple air-fluid levels in those cases with perforated appendicitis were higher than the whole group which yields the conclusion that the presence of multiple air-fluid levels can be useful as a PAR indicator of perforation as an adjunct to clinical findings. Lumbar scoliosis was not a commonly observed sign in the present series of children being positive only in 58 (15%) cases with proven acute or perforated appendicitis. This is a contradicting finding with the previous impression that scoliosis is more common in children with appendicitis.<sup>[19]</sup> Scoliosis has been proposed to be a reflector of the extent of the disease by some authors.<sup>[16]</sup> In order to test whether it actually does so, the sensitivity was calculated for acute and perforated cases separately which resulted in almost equal ratios (15% and 16%, respectively). Therefore, it can be concluded that lumbar scoliosis has not much to say about the extent of the disease. However, with a specificity rate of 87% and a positive predictive value of 90%, it may be considered as one of the relatively good PAR indicators of appendicitis once it is present in a child with clinical signs and symptoms. Fecaliths result from the inspissation of fecal material and inorganic salts within the appendiceal lumen with

resultant obstruction. Appendiceal fecaliths that are hard and noncrushable are calcified contradicting the more common crushable forms which are noncalcified.<sup>[1]</sup> Calcified fecaliths are frequently oval and lamellated, but may be subtle or obscured by bone or bowel gas.<sup>[10]</sup> Fecaliths have traditionally drawn much attention in the diagnosis of appendicitis in children,<sup>[20]</sup> and are reported to be present in 7% to 33% of children with appendicitis.<sup>[8,17,18]</sup> In the present series, 76 (18%) children had fecaliths as indicated by the operating surgeon and/or pathology report.

Presence of a fecalith in a patient with RLQ pain and fever is generally considered diagnostic no matter whether visualized by traditional plain radiographies<sup>[18]</sup> or by novel methods like helical CT scanning.<sup>[21]</sup> In the present series, PAR could detect a fecalith in only 32 (42%) of children and the remaining 44 were either noncalcified or simply could not be visualized. Interestingly, there were five patients who had “normal appendices” despite the presence of fecaliths. It is known that inspissation of fecal material within appendiceal lumen may cause intermittent obstruction and distension of appendix resulting in a condition called as “appendiceal colic”.<sup>[22]</sup> It is also known that, patients with appendiceal colic may have histopathologically normal appendices despite the presence of fecalith.<sup>[22,23]</sup> Accordingly, although the five children presented herein had normal appendices by histopathological examination, they all had had classical signs and symptoms denoting appendicitis before surgery. Additionally, three of them had history of previous hospital admissions because of abdominal pain. Fecaliths could not be observed in any five of these children by PAR most probably because they were not calcified. Although we believe these children had appendiceal colic, they were included in the negative appendectomy group because of their negative histopathology results. The present study showed that the overall sensitivity regarding the presence of a fecalith on PAR to diagnose appendicitis was quite low (8%) but both the specificity and the positive predictive value rates of 100% indicate that its presence on PAR can be of great help in diagnosis implying the continuing value of PAR in that matter.

Other even less commonly observed findings, namely, mass image in the RLQ, psoas obscuration

and localized extraluminal air deserve attention with their high specificity figures. Although psoas obscuration was once stated to be present in about one-fifth of normal people in one study,<sup>[24]</sup> it was positive in only one case with proven negative appendectomy in the present series. Despite being encountered seldom, their low false positivity figures make these three signs quite valuable diagnostic aids once visualized on PAR of a child evaluated for presumptive appendicitis diagnosis.

In conclusion, there is considerable number of children with acute abdominal pain undergoing PAR examination in different reported series and, this study was designed with the thought that it could be worthwhile to evaluate the diagnostic values of individual PAR findings for any operating surgeon who ever has a look at these radiographies. The results showed that, although the diagnostic values of individual PAR findings in appendicitis vary, there is no single PAR finding capable of ruling out the diagnosis of appendicitis. It is also found out that presence of DTC sign and/or single air fluid level in the RLQ in a child with clinical suggestive findings has the highest percentage occurrence with appendicitis. On the other hand, despite their low rates of occurrence, calcified fecalith, mass image in the RLQ, psoas obscuration, and localized extraluminal air are all quite unlikely to be present in a child with normal appendix.

### Acknowledgement

The authors wish to thank Rasim Gençosmanoğlu, M.D. and Ayşegül Akgün, M.D. for their help in preparing the manuscript.

### REFERENCES

- Birnbaum BA, Wilson SR. Appendicitis at the millennium. *Radiology* 2000;215:337-48.
- van Breda Vriesman AC, Kole BJ, Puylaert JB. Effect of ultrasonography and optional computed tomography on the outcome of appendectomy. *Eur Radiol* 2003;13:2278-82.
- Pena BM, Taylor GA, Lund DP, Mandl KD. Effect of computed tomography on patient management and costs in children with suspected appendicitis. *Pediatrics* 1999;104(3 Pt 1):440-6.
- Hormann M, Paya K, Eibenberger K, Dorffner R, Lang S, Kreuzer S, et al. MR imaging in children with nonperforated acute appendicitis: value of unenhanced MR imaging in sonographically selected cases. *AJR Am J Roentgenol* 1998;171:467-70.
- Rao PM, Rhea JT, Rao JA, Conn AK. Plain abdominal radiography in clinically suspected appendicitis: diagnostic yield, resource use, and comparison with CT. *Am J Emerg Med* 1999;17:325-8.
- Rothrock SG, Green SM, Hummel CB. Plain abdominal radiography in the detection of major disease in children: a prospective analysis. *Ann Emerg Med* 1992;21:1423-9.
- Newman K, Ponsky T, Kittle K, Dyk L, Throop C, Giesecker K, et al. Appendicitis 2000: variability in practice, outcomes, and resource utilization at thirty pediatric hospitals. *J Pediatr Surg* 2003;38:372-9; discussion 372-9.
- Nance ML, Adamson WT, Hedrick HL. Appendicitis in the young child: a continuing diagnostic challenge. *Pediatr Emerg Care* 2000;16:160-2.
- Gupta H, Dupuy DE. Advances in imaging of the acute abdomen. *Surg Clin North Am* 1997;77:1245-63.
- Strouse PJ. Imaging and the child with abdominal pain. *Singapore Med J* 2003;44:312-22.
- Marincek B. Nontraumatic abdominal emergencies: acute abdominal pain: diagnostic strategies. *Eur Radiol* 2002;12:2136-50.
- Mollitt DL, Mitchum D, Tepas JJ 3rd. Pediatric appendicitis: efficacy of laboratory and radiologic evaluation. *South Med J* 1988;81:1477-9.
- Swischuk LE, Hayden CK Jr. Appendicitis with perforation: the dilated transverse colon sign. *AJR Am J Roentgenol* 1980;135:687-9.
- Johnson JF, Coughlin WF, Stark P. The sensitivity of plain films for detecting perforation in children with appendicitis. *Rofo* 1988;149:619-23.
- May LM, O'Neill FE, Allen SW. Cecal ileus; an undescribed and helpful sign in acute appendicitis. *Tex State J Med* 1958;54:92-5.
- Olutola PS. Plain film radiographic diagnosis of acute appendicitis: an evaluation of the signs. *Can Assoc Radiol J* 1988;39:254-6.
- Hatten LE, Miller RC, Hester CL Jr, Moynihan PC. Appendicitis and the abdominal roentgenogram in children. *South Med J* 1973;66:803-6.
- Gill B, Cudmore RE. Significance of faecoliths in the diagnosis of acute appendicitis. *Br J Surg* 1975;62:535-6.
- Deluca SA, Rhea JT. Appendicitis. *Am Fam Physician* 1982;26:127-8.
- Ducharme JC, Hurtubise M, Anouty I. Calcified appendiceal fecalith in children: incidence and significance. *J Can Assoc Radiol* 1966;17:155-7.
- Rao PM, Rhea JT, Novelline RA. Appendiceal and peri-appendiceal air at CT: prevalence, appearance and clinical significance. *Clin Radiol* 1997;52:750-4.
- Schisgall RM. Appendiceal colic in childhood: the role of inspissated casts of stool within the appendix. *Ann Surg* 1980;192:687-93.
- Lee AW, Bell RM, Griffen WO Jr, Hagihara PF. Recurrent appendiceal colic. *Surg Gynecol Obstet* 1985;161:21-4.
- Graham AD, Johnson HF. The incidence of radiographic findings in acute appendicitis compared to 200 normal abdomens. *Mil Med* 1966;131:272-6.