

A rare cause of acute abdominal pain: Actinomyces infection of colon mimicking a malignant neoplasm due to intrauterine device

 Bahar Canbay Torun, M.D.,¹  Ali Fuat Kaan Gök, M.D.,²  Mehmet İlhan, M.D.,²
 Gülçin Yegen, M.D.,³  Seniha Başaran, M.D.,⁴  Cemalettin Ertekin, M.D.,²
 Mustafa Kayıhan Günay, M.D.,²  Hakan Yanar, M.D.²

¹Department of General Surgery, Sultangazi Haseki Training and Research Hospital, İstanbul-Turkey

²Department of General Surgery, İstanbul University İstanbul Faculty of Medicine, İstanbul-Turkey

³Department of Pathology, İstanbul University İstanbul Faculty of Medicine, İstanbul-Turkey

⁴Department of Infectious Diseases and Clinical Microbiology, İstanbul University İstanbul Faculty of Medicine, İstanbul-Turkey

ABSTRACT

Actinomycosis is a rare, chronic granulomatous disease that is challenging to diagnose because the clinical symptoms and signs are nonspecific. Usage of intrauterine device (IUD) or being immunocompromised is facilitating factors. Clinical and radiological findings can mimic malignant neoplasm, inflammatory bowel disorder, or acute diverticulitis. We report a case of actinomyces infection of the colon secondary to IUD, which is a rare cause of acute abdominal pain and can mimic a malignant neoplasm. We also provide a review of the literature. Unnecessary surgery can be avoided with the correct diagnosis of granulomatous infectious diseases that can be treated with antibiotics.

Keywords: Actinomyces infection; acute abdominal pain; colonic actinomycosis; intrauterine device.

INTRODUCTION

Actinomycosis is an uncommon, progressive granulomatous disease, caused by Actinomyces species especially Actinomyces israelii, which is an anaerobic gram-positive bacteria.^[1-3] It is normally colonized in the mouth, gastrointestinal tract, female genital tract, and bronchi.^[2] The infection by this bacteria is usually associated with disruption of the mucosal barrier.^[4] Although actinomycosis can be seen in every part of the gastrointestinal tract, it is mostly seen in the appendix, cecum, and colon.^[5] Colonic actinomycosis may present as a mass, also invading surrounding structures, forming an abscess, fistula, or sinus and can cause perforation or obstruction.^[1] Clinical symptoms, signs, and radiological manifesta-

tions of actinomyces infection are not specific. In differential diagnosis, malignant neoplasm, inflammatory bowel disorder, acute appendicitis, acute diverticulitis, intestinal tuberculosis, amebiasis, tuba ovarian abscess should be considered.^[3,6,7] It mimics tumor in most cases.^[8] For this reason, it is hard to diagnose preoperatively.

CASE REPORT

A 47-years-old woman was admitted to the emergency unit with abdominal pain and fever. Informed consent was obtained from the patient. She complained of abdominal pain for 4 days. She has been with an intrauterine device (IUD) for 10 years. On her physical examination, her abdomen was

Cite this article as: Torun BC, Gök AFK, İlhan M, Yegen G, Başaran S, Ertekin C, et al. A rare cause of acute abdominal pain: Actinomyces infection of colon mimicking a malignant neoplasm due to intrauterine device. *Ulus Travma Acil Cerrahi Derg* 2022;28:537-540.

Address for correspondence: Bahar Canbay Torun, M.D.

Sultangazi Haseki Eğitim ve Araştırma Hastanesi, Genel Cerrahi Kliniği, İstanbul, Turkey

Tel: +90 212 - 453 20 00 E-mail: baharcanbay@gmail.com

Ulus Travma Acil Cerrahi Derg 2022;28(4):537-540 DOI: 10.14744/tjtes.2020.45672 Submitted: 08.06.2020 Accepted: 12.07.2020

Copyright 2022 Turkish Association of Trauma and Emergency Surgery



distended and tenderness was found on the right upper quadrant. She had no other remarkable findings in her history. A computerized tomography (CT) revealed the following findings: A 17 mm wall thickness compatible with tumor growth in a 6 cm segment of the proximal part of the transverse colon and two nodular lesions which are compatible with implants (Figs. 1a and b). Colonoscopy revealed mucosal irregularity at hepatic flexure (Fig. 2a and b). Microscopic examination of the biopsies taken at colonoscopy demonstrated sulfur granules that were consistent with actinomycosis within the granulation tissue which is rich in polymorphonuclear leukocytes (Fig. 3a and b). On receiving the pathology report, she was treated with systemic intravenous penicillin for 14 days. IUD was removed. She was saved from the non-therapeutic laparotomy. She was discharged on the 24th day with a complementary treatment of oral antibiotics. Three months after the treatment, lesions totally disappeared in the control CT.

DISCUSSION

As in our case, the use of IUD was detected in 60–80% of patients with pelvic actinomycoses in the literature.^[2,9]

However our patient had no additional systemic diseases and no usage of immunosuppressive medications. Although IUD-related actinomycosis infection is not frequent, it has been clearly determined that it is related with the prolonged use of IUD. Therefore, it is recommended to be changed every 5 years.^[5]

A broad spectrum of clinical signs and symptoms of colonic actinomycosis may be lower abdominal pain, fever, palpable mass, weight loss, fatigue, change in bowel habits, nausea, vomiting, and abdominal discomfort.^[9-11]

On the other hand, many patients may not have any symptoms.^[12]

Although radiological findings are also non-specific, CT is a more reliable diagnostic tool. CT is useful to show the extent of the disease. Actinomycosis should be considered in the differential diagnosis when an infiltrative mass with unusual aggressiveness and dense inhomogeneous contrast enhancement is detected on CT.^[11]

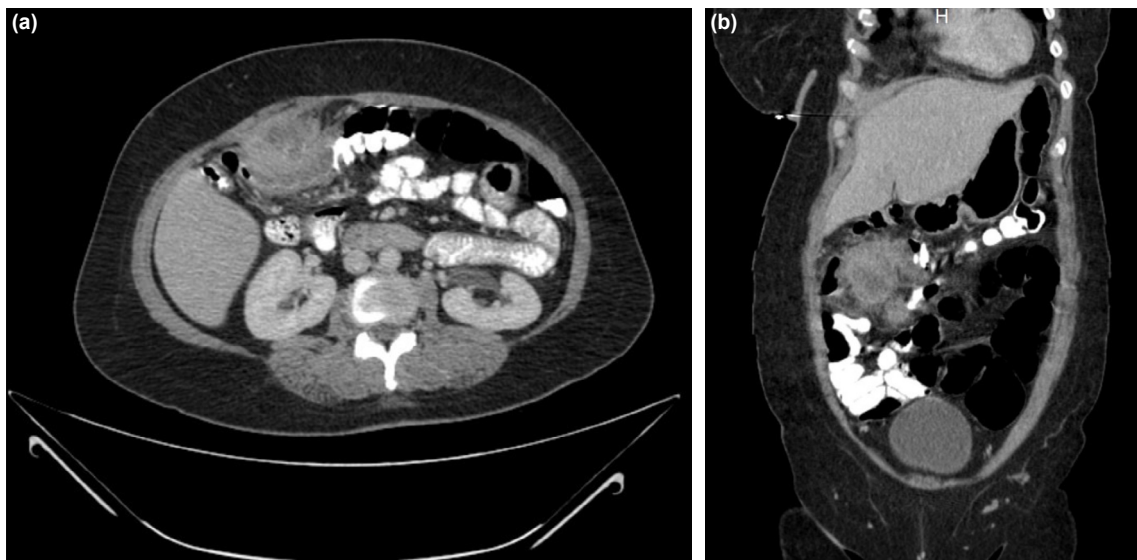


Figure 1. (a, b) CT scan showing wall thickness of the proximal transverse colon.

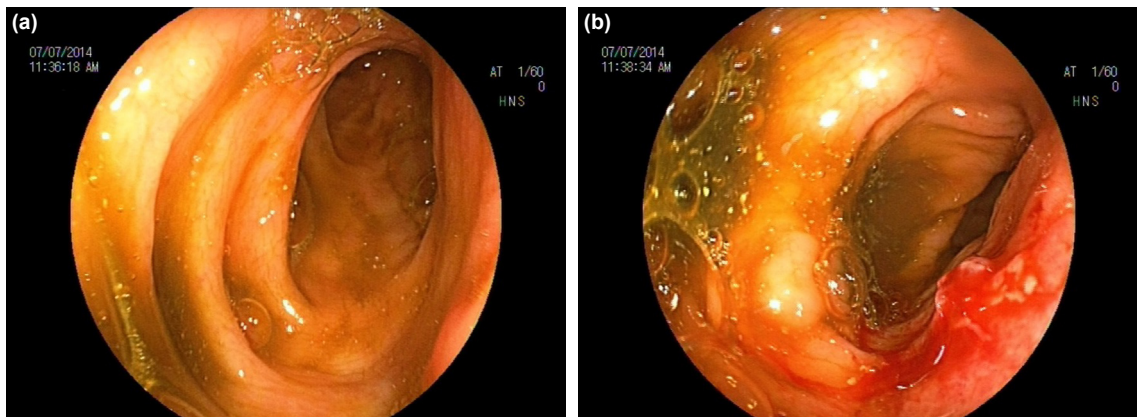


Figure 2. (a, b) Colonoscopy revealed mucosal irregularity at hepatic flexura.

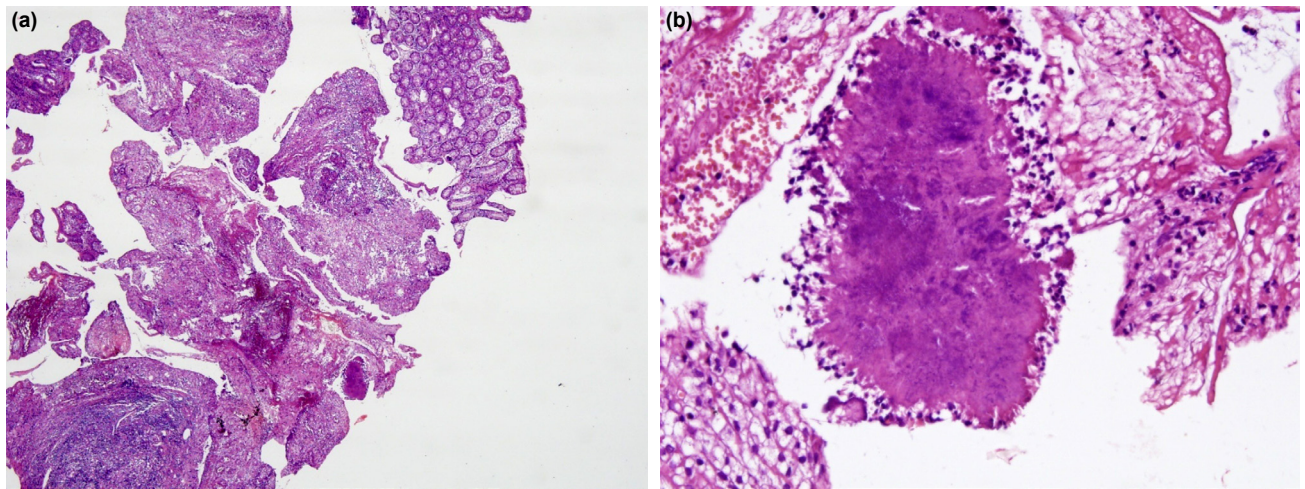


Figure 3. (a) Microscopic examination of the colonoscopic biopsy revealed granulation tissue rich in polymorphonuclear leukocytes (H&E stain, 4X magnification). (b) Within the granulation tissue sulphur granule is seen (H&E stain, 40X magnification).

Clinical, radiological manifestations are non-specific in abdominal actinomycosis, herewith <10% of patients can be diagnosed preoperatively.^[8]

Hayashi et al.^[13] reported two cases who had undergone appendectomy for acute appendicitis and after surgery presented with intra-abdominal tumor-like lesions which were diagnosed to be actinomycosis mimicking malignancy.

A case of actinomycosis, mimicking advanced stage colon tumor with liver metastases and with colon perforation is also reported.^[14]

Also in literature, there is one case of abdominal actinomycosis secondary to the bile spillage during laparoscopic cholecystectomy for acute cholecystitis. The patient also had a history of choledocholithiasis and cholangitis 4 years before this episode of acute cholecystitis. Two years after laparoscopic cholecystectomy, invasive actinomycosis developed in the right upper quadrant. However, there are not sufficient data to confirm that actinomycosis was secondary to the procedure.^[12]

In a retrospective study, 13 abdominal actinomycosis cases were analyzed. Seven of them were admitted for abdominal tumor and six of them for pelvic inflammatory disease. Authors identified IUD in six cases, foreign bodies in two cases, diabetes in three cases, and immunosuppression as predisposing factors. All cases underwent surgery.^[10]

In a report of twenty cases, 50% of patients underwent emergency surgery and only one patient (4.5%) was diagnosed pre-operatively.^[9]

Definitive diagnosis is based on isolation and identification of the bacteria from a clinical sample,^[15] therefore a pre-operative biopsy should be taken.

There are cases where biopsy is not performed, to avoid needle tract metastases^[12] or because the colon lumen is obstructed.^[16]

Antibiotherapy, intravenous penicillin G, should be given as initial therapy and continued orally. It is extremely effective for cure, however, it should be given long term and high dose, because antibiotic hardly penetrates due to desmoplastic reaction.^[1,3] If symptoms persist for more than 1 month despite penicillin treatment, additional antibiotics should be started by considering superinfection.^[3] Erythromycin, tetracycline, and clindamycin should be preferred as alternative treatments in patients with penicillin allergy.^[3,8]

In cases with large abscess, into which antibiotics cannot penetrate, percutaneous abscess drainage along with antibiotherapy should be preferred.^[8]

Surgery should be performed when malignancy can not be excluded, in relapse cases that do not respond to antibiotherapy and in situations that require urgent intervention, such as colonic obstruction.^[1,3] Surgical resection can be extensive, due to the infiltrative nature of the disease and its tendency to invade normal anatomic barriers.^[11] Since most patients undergo surgery without diagnosis,^[9,10] if surgery is indicated, it is recommended to perform preoperative frozen section biopsy, because it will prevent unnecessary extensive surgery.^[14]

Starting antibiotherapy at least 2 weeks before the surgery reduces both the extension of the surgery and the postoperative complications.^[14]

In our case, antibiotherapy was sufficient to control the disease and unnecessary resection was prevented.

Conclusion

Granulomatous infectious diseases need to be considered

in differential diagnosis of tumor in patients presenting with abdominal mass, especially colonic mass, in the presence of fever, leukocytosis, and a history of IUD usage. Diagnostic workup is essential and diagnostic biopsy should be considered prior to surgical visceral resections. Unnecessary surgical visceral resections could be prevented with appropriate antibiotherapy.

Informed Consent: Written informed consent was obtained from the patient for the publication of the case report and the accompanying images.

Peer-review: Internally peer-reviewed.

Authorship Contributions: Concept: B.C.T., A.F.K.G., M.K.G., H.Y.; Design: B.C.T., A.F.K.G., M.K.G., H.Y.; Supervision: B.C.T., A.F.K.G., M.K.G., H.Y.; Resource: B.C.T., A.F.K.G.; Materials: B.C.T., A.F.K.G.; Data: B.C.T., A.F.K.G.; Analysis: M.İ., S.B., M.K.G.; Literature search: M.İ., S.B., M.K.G.; Writing: B.C.T., M.İ.; Critical revision: A.F.K.G., G.Y., S.B., C.E., H.Y.

Conflict of Interest: None declared.

Financial Disclosure: The authors declared that this study has received no financial support.

REFERENCES

1. Laish I, Benjaminov O, Morgenstern S, Greif F, Ben-Ari Z. Abdominal actinomycosis masquerading as colon cancer in a liver transplant recipient. *Transpl Infect Dis* 2012;14:86–90. [CrossRef]
2. Pusiol T, Morichetti D, Pedrazzani C, Ricci, F. Abdominal-pelvic actinomycosis mimicking malignant neoplasm. *Infect Dis Obstet Gynecol* 2011;2011:747059. [CrossRef]
3. Garner JP, Macdonald M, Kumar PK. Abdominal actinomycosis. *Int J Surg* 2007;5:441–8. [CrossRef]
4. Castro LL, Cabral MM, Andrade RF, Buzatti KC, Silva RG. Actinomycosis mimicking colonic neoplasia. *J Coloproctol* 2012;32:312–5. [CrossRef]
5. Valour F, Sénéchal A, Dupieux C, Karsenty J, Lustig S, Breton P et al. Actinomycosis: Etiology, clinical features, diagnosis, treatment, and management. *Infect Drug Resist* 2014;7:183–97. [CrossRef]
6. Thanos L, Mylona S, Kalioras V, Pomoni M, Batakis N. Ileocecal actinomycosis: A case report. *Abdom Imaging* 2004;29:36–8. [CrossRef]
7. Kaya E, Yilmazlar T, Emiroğlu Z, Zorluoğlu A, Bayer A. Colonic actinomycosis: Report of a case and review of the literature. *Surg Today* 1995;25:923–6. [CrossRef]
8. Yang SH, Li AF, Lin JK. Colonoscopy in abdominal actinomycosis. *Gastrointest Endosc* 2000;51:236–8. [CrossRef]
9. Choi MM, Baek JH, Lee JN, Park S, Lee WS. Clinical features of abdominopelvic actinomycosis: Report of twenty cases and literature review. *Yonsei Med J* 2009;50:555–9. [CrossRef]
10. Tărcoveanu E, Vasilescu A, Andronic D, Lupaşcu C, Ciobanu D, Vlad N, et al. Abdominal actinomycosis mimicking colon cancer. *Chirurgia (Bucur)* 2019;114:251–8. [CrossRef]
11. Ha HK, Lee HJ, Kim H, Ro HJ, Park YH, Cha SJ, et al. Abdominal actinomycosis: CT findings in 10 patients. *AJR Am J Roentgenol* 1993;161:791–4. [CrossRef]
12. Ozgediz D, Zheng J, Smith EB, Corvera CU. Abdominal actinomycosis after laparoscopic cholecystectomy: A rare complication of bile spillage. *Surg Infect (Larchmt)* 2009;10:297–300. [CrossRef]
13. Hayashi M, Asakuma M, Tsunemi S, Inoue Y, Shimizu T, Komeda K, et al. Surgical treatment for abdominal actinomycosis: A report of two cases. *World J Gastrointest Surg* 2010;2:405–8. [CrossRef]
14. Yang SS, Im YC. Severe abdominopelvic actinomycosis with colon perforation and hepatic involvement mimicking advanced sigmoid colon cancer with hepatic metastasis: A case study. *BMC Surg* 2018;18:51. [CrossRef]
15. Sullivan DC, Chapman SW. Bacteria that masquerade as fungi: Actinomycosis/nocardia. *Proc Am Thorac Soc* 2010;7:216–21. [CrossRef]
16. Filippou D, Psimitis I, Zizi D, Rizos S. A rare case of ascending colon actinomycosis mimicking cancer. *BMC Gastroenterol* 2005;5:1. [CrossRef]

OLGU SUNUMU - ÖZ

Akut karın ağrısının nadir görülen bir nedeni: Rahim içi araç kullanımına bağlı malign tümörü taklit eden kolonun aktinomiçes enfeksiyonu

Dr. Bahar Canbay Torun,¹ Dr. Ali Fuat Kaan Gök,² Dr. Mehmet İlhan,² Dr. Gülçin Yegen,³ Dr. Seniha Başaran,⁴ Dr. Cemalettin Ertekin,² Dr. Mustafa Kayıhan Günay,² Dr. Hakan Yanar²

¹Sultangazi Haseki Eğitim ve Araştırma Hastanesi, Genel Cerrahi Kliniği, İstanbul

²İstanbul Üniversitesi İstanbul Tıp Fakültesi, Genel Cerrahi Anabilim Dalı, İstanbul

³İstanbul Üniversitesi İstanbul Tıp Fakültesi, Tıbbi Patoloji Anabilim Dalı, İstanbul

⁴İstanbul Üniversitesi İstanbul Tıp Fakültesi, Enfeksiyon Hastalıkları ve Klinik Mikrobiyoloji Anabilim Dalı, İstanbul

Aktinomikoz nadir görülen, zor tanı konulan, semptomları ve bulguları spesifik olmayan kronik granümatöz bir hastalıktır. Rahim içi araç ve immünespresif ilaç kullanımı kolaylaştırıcı etmenler arasında yer alır. Klinik ve radyolojik bulguları; tümör, enflamatuvar bağırsak hastalıkları veya akut divertikülit ile karışabilmektedir. Bu yazıda nadir bir akut karın nedeni olan ve kolon tümörünü taklit eden rahim içi araç kullanımına sekonder gelişen kolonik aktinomiçes enfeksiyonu olgusunu ve literatür derlemesini sunmayı amaçladık. Antibiyotik ile tedavi edilebilecek granümatöz enfeksiyöz hastalıklara doğru tanı konulması ile gereksiz cerrahiden kaçınılabılır.

Anahtar sözcükler: Aktinomiçes enfeksiyonu; akut karın ağrısı; kolonik aktinomikoz; rahim içi araç.

Ulus Travma Acil Cerrahi Derg 2022;28(4):537–540 doi: 10.14744/ıttes.2020.45672