

Effects of polyurethane membrane on septic colon anastomosis and intra-abdominal adhesions

İD Gökhan Yılmaz, M.D.,¹ İD Yaşar Özdenkaya, M.D.,¹ İD Oğuzhan Karatepe, M.D.,²
İD Yusuf Tanrikulu, M.D.,³ İD Gülçin Kamalı, M.D.,⁴ İD Orhan Yalçın, M.D.⁵

¹Department of General Surgery, Medipol University Faculty of Medicine, İstanbul-Turkey

²Department of General Surgery, Memorial Hospital, İstanbul-Turkey

³Department of General Surgery, KTO Karatay University Faculty of Medicine, Konya-Turkey

⁴Department of Pathology, Okmeydanı Training and Research Hospital, İstanbul-Turkey

⁵Department of General Surgery, Okmeydanı Training and Research Hospital, İstanbul-Turkey

ABSTRACT

BACKGROUND: Anastomotic leakages and adhesions after gastrointestinal tract surgery are still a significant cause of morbidity and mortality. The rate of anastomotic leakage is 3%–8%, whereas the mortality from leakage is over 30%. Intra-abdominal sepsis is a well-known cause of anastomotic leakage. In addition, intra-abdominal adhesion is a major cause of hospital admissions and reoperations and is associated with morbidity and mortality. In this study, we aimed to investigate the effects of a polyurethane membrane on anastomotic healing and intra-abdominal adhesions.

METHODS: This study used 32 Wistar albino rats divided into four groups. Standard resection of left colon 2 cm above the peritoneal reflection and colonic anastomosis were performed after causing abdominal sepsis through caecal ligation and perforation. The control groups (1 and 3) received no further treatment. The experimental groups (2 and 4) received the polyurethane membrane around the colonic anastomosis. Burst pressure, hydroxyproline, interleukin-6 (IL-6), nitric oxide (NO), tissue plasminogen activator (tPA), and tumor necrosis factor-alpha (TNF- α) levels were measured, and histopathological characteristics of the anastomosis were analyzed after re-laparotomy. Moreover, adhesion scores were measured.

RESULTS: No statistically significant differences were found in the mean burst pressure levels between sacrificed animals on days three and five ($p=0.259$, $p=0.177$). When all the groups were compared, no significant difference was observed in the hydroxyproline, NO, and IL-6 levels ($p=0.916$, $p=0.429$, $p=0.793$, $p=0.332$, $p=0.400$, $p=0.317$). However, in groups 2 and 4, the tPA levels were significantly increased by Opsite therapy ($p=0.001$, $p=0.003$), and a statistically significant difference was observed in the adhesion scores ($p<0.035$). Groups 2 and 4 had significantly lower adhesion scores than groups 1 and 3.

CONCLUSION: We found that Opsite therapy had no positive or negative effects on histopathological and biochemical healing in the experimental septic colon anastomosis model. However, the perianastomotic application of polyurethane membrane effectively decreased the intra-abdominal adhesions.

Keywords: Adhesion; colonic anastomosis; intra-abdominal sepsis; polyurethane membrane.

INTRODUCTION

Colon resections and anastomosis are the most frequently performed procedures in general surgery. Despite improve-

ments and innovations in technology and surgical techniques, postoperative complications and reoperations are frequently observed after colonic anastomosis.^[1,2]

Cite this article as: Yılmaz G, Özdenkaya Y, Karatepe O, Tanrikulu Y, Kamalı G, Yalçın O. Effects of polyurethane membrane on septic colon anastomosis and intra-abdominal adhesions. *Ulus Travma Acil Cerrahi Derg* 2021;27:1-8.

Address for correspondence: Gökhan Yılmaz, M.D.

Medipol Üniversitesi Tıp Fakültesi, Genel Cerrahi Anabilim Dalı, İstanbul, Turkey

Tel: +90 216 - 682 80 00 E-mail: drgokhanyilmz@gmail.com

Ulus Travma Acil Cerrahi Derg 2021;27(1):1-8 DOI: 10.14744/tjtes.2020.41624 Submitted: 19.03.2019 Accepted: 28.02.2020 Online: 10.12.2020

Copyright 2021 Turkish Association of Trauma and Emergency Surgery



Colonic mucosal blood flow, the anastomosis technique, inflammation, patient demographics, nutritional state of the patient, additional diseases, medications, and type of operation may influence the colonic anastomosis leakage. In addition, infection, suture materials, sepsis, and steroid use may affect wound healing.^[3]

Reoperations are frequently required because of complications, such as ileus or anastomotic leakage, which may occur after colonic anastomosis. The presence of intra-abdominal adhesions increases the rate of morbidity and mortality during reoperations.^[4,5] Several clinical and experimental studies have discussed the significance of increased mortality and morbidity because of intra-abdominal adhesions. However, to our knowledge, there is no evidence identifying a decline in the intra-abdominal adhesions with an increase in anastomosis safety.^[6,7]

Polyurethane membrane (Opsite, Smith & Nephew) is a material that has antibacterial properties and has been used in superficial wounds for several years. Notably, it is preferred because of its properties, such as easy application and long-term covering, compared with conventional dressing techniques. The primary reasons for choosing this material in our study were that it leads to a barrier against body fluids, prevents wound disintegration, and causes rapid healing.^[8] Notably, the most crucial aspect of colon anastomoses is the early prevention of fluid leakage. The present study aimed to investigate the effects of polyurethane membrane on colon anastomosis healing and intra-abdominal adhesions.

MATERIALS AND METHODS

Study Plan and Experimental Groups

This study was conducted at Istanbul University Experimental Medicine Research Institute, Istanbul Medical Faculty Biochemistry Department, and Okmeydani Training and Research Hospital Pathology laboratories after approval from the local ethics committee (2011/88). In our study, 32 healthy Wistar albino rats weighing between 200–250 g were used. All the animals were kept in dual cages at 22°C room temperature. Cage maintenance was done twice a day, and animals were fed with a normal rat diet and tap water.

Rats were randomly divided into four groups, with eight rats per group.

Group 1 (n = 8): Laparotomy + intra-abdominal sepsis + left colon anastomosis + euthanasia on day three

Group 2 (n = 8): Laparotomy + intra-abdominal sepsis + left colon anastomosis + polyurethane membrane + euthanasia on day three

Group 3 (n = 8): Laparotomy + intra-abdominal sepsis + left colon anastomosis + euthanasia on day five

Group 4 (n = 8): Laparotomy + intra-abdominal sepsis + left

colon anastomosis + polyurethane membrane + euthanasia on day five.

All rats were euthanized at the end of the experiment to assess the burst pressure; perform the histopathologic examination of the perianastomotic tissue; and evaluate hydroxyproline, nitric oxide (NO), tissue plasminogen activator (tPA), tumor necrosis factor-alpha (TNF- α), and interleukin-6 (IL-6) levels.

Experimental Procedure

After general anesthesia was administered with 10 mg/kg of subcutaneous ketamine, the anterior abdominal wall was shaved and cleaned with povidone-iodine, and a median laparotomy was performed. We performed a cecal ligation and puncture to create intra-abdominal sepsis. The cecum was exposed, ligated with 3–0 silk at 1 cm distally to the ileocecal valve to avoid intestinal obstruction. Two punctures were performed in the cecum with an 18-gauge needle, and it was gently squeezed to force out the feces, following which it was returned to the abdominal cavity. The left colon was found, and the sigmoid colon was transected at 3-cm above the peritoneal reflection, and a 1-cm segment was excised. An end-to-end single-layer anastomosis was performed using a 5–0 polypropylene suture. All anastomoses were performed using the same technique by the same surgeon. Polyurethane membrane was applied all around the anastomosis in the rats of groups 2 and 4. Closure of abdominal muscle layers and skin was performed using single 3–0 silk sutures. The animals were permitted to eat 24 hours after the surgery.

The rats of groups 1 and 3 were euthanized on day three, whereas those of groups 2 and 4 were euthanized on day five using high doses of ketamine. After anastomotic burst pressures were measured, samples were taken for biochemical and histopathological examination from rats of all groups.

Measurement of Burst Pressure

A sphygmomanometer was used to measure the burst pressure. The segment containing the anastomotic site was separated without dissecting the adhesions, and a 2 cm proximal and 2 cm distal side segment was prepared. Later, the proximal bowel segment was cannulated and connected to the insufflation pump of the sphygmomanometer, and the distal part was also ligated. Insufflation was initiated in a container filled with physiological serum. The colon was inflated with the sphygmomanometer at a pressure of 4 mL/min. The anastomotic burst pressure was recorded for all the study animals by noting the pressure when the first bubble was observed.

Adhesion Scoring System

Intra-abdominal adhesions were evaluated according to the classification system described by Majuzi^[9] (Table 1).

Table 1. Adhesion scoring system

Rank	Score
No adhesions	0
Adhesions that can be separated by blunt dissection	1
Lysis possible less than 50% sharp dissection	2
Lysis possible more than 50% sharp dissection	3
Serozal injury	4
Full-thickness injury	5

Histopathological Evaluations

Colon tissues obtained from the rats were fixed in 10% formaldehyde solution for 24 hours with subsequent preparation of paraffin blocks. Transverse sections of 4 μ m were cut from paraffinized tissue blocks. Anastomotic segments were stained using hematoxylin and eosin (H&E) stain and examined under light microscopy (Olympus, BX51, Japan) at 20x, 40x and 100x magnification power by the same pathology specialist who was blinded to the groups. Scores of inflammatory infiltration, edema, lymphocyte activation, and collagen accumulation were measured for evaluation of changes and healing in the anastomotic line. The results of each evaluation were scored between 0 and 3.

Biochemical Evaluations

Measurement of Hydroxyproline: Hydroxyproline was measured after storing the perianastomotic bowel segment at -70°C . Hydroxyproline was evaluated spectrophotometrically at 560 nm using the Prockop and Kivirikko technique.^[10]

Measurement of NO: A colorimetric method was used to measure NO (Boehringer Mannheim kit, cat no: 175 6281). Typical values of NO concentration in tissue were 0.5 $\mu\text{g}/\text{mL}$ /mg tissue.

Measurement of TNF- α and IL-6: TNF- α and IL-6 levels in tissue homogenate were measured using enzyme-linked immunosorbent assay (Quantikine Sensitivity Human, R&D Systems, USA).

Measurement of tPA: The tPA levels in the tissue were measured using the radioimmunoassay (RIA) method (mU/mg protein).

Statistical Evaluation

Quantitative results were expressed as the mean \pm standard deviation. The Mann–Whitney U test was used to make comparisons between groups. Multiple comparisons and multiple assessments between groups were performed using Tukey's post-hoc HSD test. Values of $p=0.05$ were considered statistically significant. Statistical calculations were performed using the statistical package for social sciences (SPSS) for Windows 15.0 (SPSS Inc., Chicago, IL, USA).

RESULTS

No mortality or anastomosis leakage was observed in the experimental animals. TNF- α , NO, tPA, IL-6 and hydroxyproline levels were measured in the tissue of the anastomotic line after the explosion pressure was measured by performing adhesion scoring in vitro in all subjects. Biochemical samples were taken, and histopathologic examination was performed.

Biochemical evaluation results and burst pressures of the groups are summarized in Table 2 and Fig. 1. The anastomotic burst pressures of the rats euthanized on days three and five were compared between the groups that used or did not use polyurethane membrane. No statistically significant intergroup difference was observed between burst pressures based on the use of the polyurethane membrane ($p=0.259$, $p=0.177$).

NO levels were measured to assess the oxidative damage in the tissue. Statistically, no significant difference was observed in the tissue NO levels between groups that used or did not use polyurethane membrane ($p=0.793$, $p=0.332$).

TNF- α and IL-6 levels were evaluated to assess the level of inflammation in the tissue. No significant difference was observed in IL-6 levels between groups that used or did not use polyurethane membrane ($p=0.400$, $p=0.317$). However, the findings showed that the TNF- α level decreased significantly

Table 2. Biochemical evaluation results of the groups and comparison of explosion pressures

Parameter	Group 1	Group 2	Group 3	Group 4	p^1	p^2
IL 6 ($\mu\text{g}/\text{mg}$)	81.66 \pm 21.70	79.71 \pm 9.04	68.35 \pm 3.71	66.66 \pm 5.80	0.400	0.317
TNF- α ($\mu\text{g}/\text{mg}$)	16.50 \pm 3.50	12.50 \pm 2.92	2.92 \pm 1.12	9.25 \pm 1.03	0.026	0.785
TPA (mU/mg)	108.00 \pm 7.21	140.00 \pm 14.10	100.00 \pm 3.77	126.00 \pm 17.26	0.001	0.003
NO (mmol/l)	101.1 \pm 8.27	98.80 \pm 11.20	94.75 \pm 6.22	97.62 \pm 2.43	0.793	0.332
Hydroxyproline (mg/mg)	44.70 \pm 8.19	44.80 \pm 4.42	42.80 \pm 2.11	43.92 \pm 1.11	0.916	0.429
Explosion pressure (mmHg)	87.5 \pm 18.5	96.80 \pm 5.30	142.50 \pm 7.55	138.12 \pm 4.58	0.259	0.177

IL 6: Interleukin 6; TNF- α : Tumor necrosis factor- α ; TPA: Tissue plasminogen activator; NO: Nitric oxide. p^1 : Group 1 vs group2; p^2 : Group 3 vs group 4.

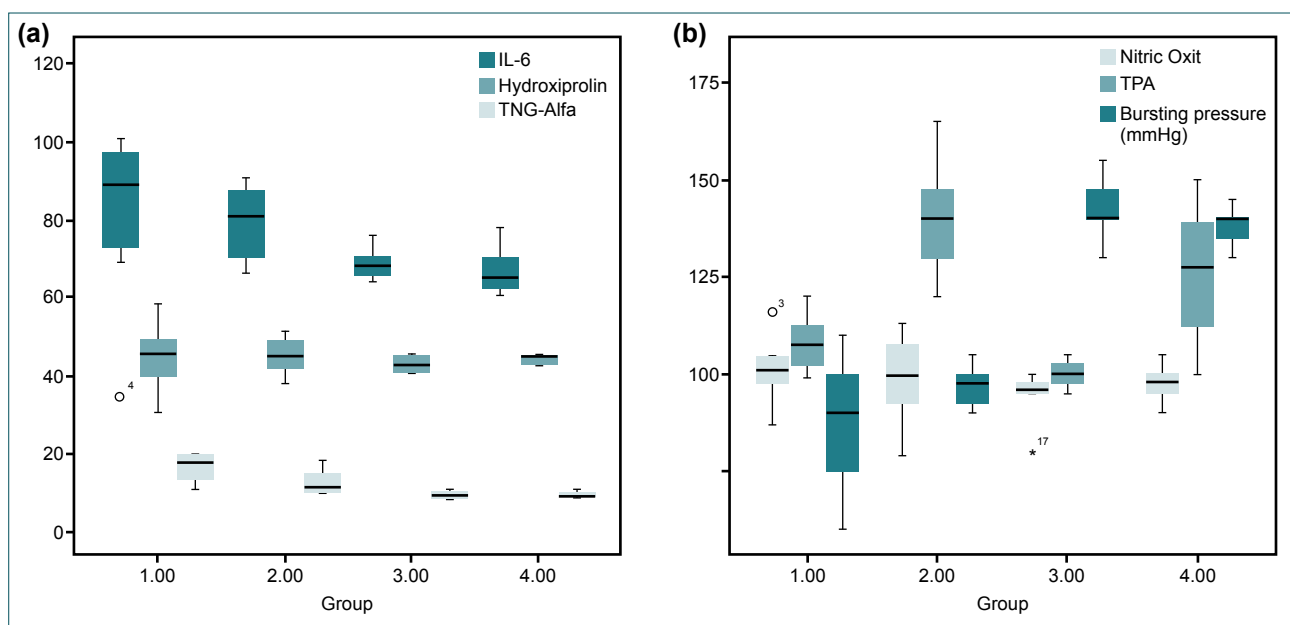


Figure 1. Comparison of IL-6, hydroxyproline, and TNF- α values between groups (a), Comparison of NO, tPA, and burst pressures between the groups (b).

in the group treated with the polyurethane membrane and euthanized on day three ($p=0.026$).

Tissue hydroxyproline levels were measured to evaluate anastomosis healing. Statistically, tissue hydroxyproline levels did not show any significant differences between each of the four groups ($p=0.916$, $p=0.429$).

Intergroup comparison of tPA levels was performed to determine the fibrinolytic activity in the tissue, and they were significantly higher in the groups that used polyurethane membrane than the groups that did not ($p=0.001$, $p=0.003$).

Intra-abdominal and perianastomotic adhesions scores are summarized in Table 3. Notably, a significant decrease in the adhesions was found in the group that used polyurethane membrane compared with the group that did not, on both days three and five ($p=0.045$, $p=0.035$).

The histopathological evaluation of the groups is summarized in Table 3 and Fig. 2. The results of each evaluation were

scored between 0 and 3 (0 = none, 1 = less, 2 = moderate, 3 = high). Histopathologically, edema, inflammatory infiltration, lymphocyte activation, and collagen accumulation were compared between groups. Although no significant intergroup difference was observed regarding all parameters in the early period, lymphocyte activation was statistically lower in the later period ($p=0.029$).

DISCUSSION

In our study, we researched the benefits of applying an intra-abdominal polyurethane membrane concerning the strength of anastomosis and intra-abdominal adhesions. Notably, polyurethane membrane did not positively contribute toward the strength of anastomosis but significantly reduced intra-abdominal adhesions and adhesions around the anastomosis.

Adhesions can be prevented by performing intra-abdominal procedures, using the appropriate surgical technique, performing minimally-invasive surgery, causing less trauma to tis-

Table 3. Histopathological results

Parameter	Group 1	Group 2	Group 3	Group 4	P ¹	P ²
Adhesion score	3 (1–4)	1 (1–3)	3 (3–5)	2 (0–3)	0.045	0.035
Edema	2 (1–3)	2.5 (2–3)	2 (2–3)	2 (1–2)	0.079	0.097
Inflammatory infiltration	2 (0–3)	2 (1–3)	2 (1–3)	1.5 (0–2)	0.411	0.059
Lymphocyte activation	3 (2–3)	3 (2–3)	3 (1–3)	3 (1–3)	0.148	0.029
Collagen accumulation	2 (1–3)	2 (2–3)	2 (1–3)	2 (1–3)	0.449	0.214

P¹: Group 1 vs group 2; P²: Group 3 vs group 4.

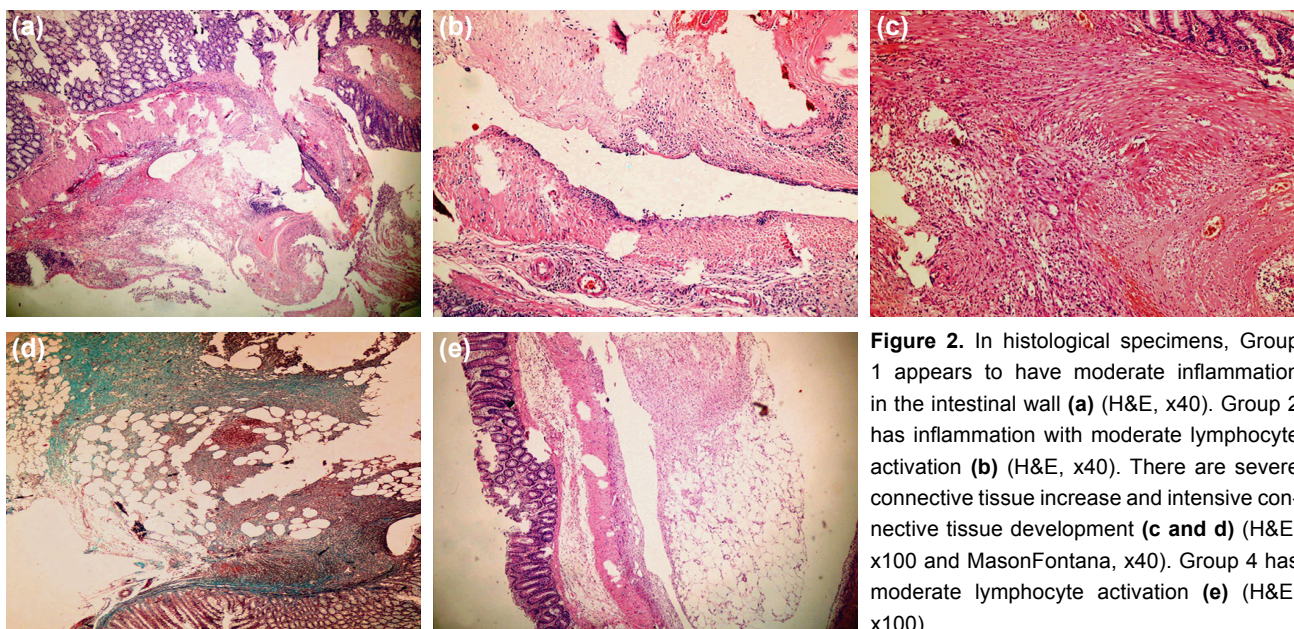


Figure 2. In histological specimens, Group 1 appears to have moderate inflammation in the intestinal wall (a) (H&E, x40). Group 2 has inflammation with moderate lymphocyte activation (b) (H&E, x40). There are severe connective tissue increase and intensive connective tissue development (c and d) (H&E, x100 and MasonFontana, x40). Group 4 has moderate lymphocyte activation (e) (H&E, x100).

sues during surgery, preventing excessive drying and warming of tissues, and minimizing the use of sutures to the peritoneum. Despite several recent studies focusing on pharmacological agents and physical barriers to prevent adhesions during intra-abdominal procedures, none of them could qualify as a method for preventing postoperative intra-abdominal adhesions.^[11–15]

Polyurethane (PU) is a segmented polymer with a micro-phase-segmented morphology reflected in its elastomeric behavior. Electrospun nanofibers composed of polycaprolactone-based PU are widely applied in tissue engineering and drug delivery because of their biodegradability, favorable mechanical properties, and Food and Drug Administration (FDA) approval.^[16] Notably, polyurethane membrane has been used as a spray in postoperative wound dressing for many years. Although polyurethane membrane is permeable to moisture and vapor, it prevents liquid penetration. Moreover, it is a non-irritant material that is resistant to body fluids. Furthermore, it prevents bacterial contamination. Although the literature has no data regarding the intra-abdominal use of polyurethane membrane, it seems appropriate because of its properties.^[17,18] US FDA-approved adhesion barriers, such as Seprafilm™ and SurgiWrap™, are designed to prevent peritoneal adhesion after abdominal surgery. Notably, the most commonly used and recognized of these products is Seprafilm™—a bioresorbable membrane composed of hyaluronic acid and carboxymethylcellulose that is typically placed intraperitoneally under the midline incision at the end of an operation. Bioresorbable hyaluronic acid and carboxymethylcellulose barriers reduce the formation of adhesions by preventing the close apposition and adherence of injured or healing peritoneal tissues.^[19] The advent of physical barriers, such as HA/CMC bioresorbable membranes, have significantly reduced the incidence of adhesions at the midline incision.

However, as noted earlier, the efficacy of physical barriers in reducing the long-term adhesion-related complications, especially adhesive small bowel obstruction, may still require further investigation.^[20]

Peritoneal trauma, ischemia and inflammation are the starting points of adhesions, alongside the release of tissue factor. Tissue thromboplastin converts prothrombin to thrombin. Thrombin converts intra-abdominal fibrinogen to fibrin, such that fibrin interferes or delays intra-abdominal bacterial infections. Fibrin is fragmented by fibrinolytic enzymes, such as plasmin, in a healthy intra-abdominal environment. However, in the presence of inflammation, fibrinolytic enzymes are deactivated, thereby leading to the formation of permanent adhesions.^[13,14] In general, intra-abdominal adhesions form through the same mechanism as that of inflammation and anastomosis healing. Some clinical and experimental studies have demonstrated that inflammation, such as peritonitis, is a cause of intra-abdominal adhesion formation. Intra-abdominal infection is a potent stimulus of peritoneal injury and is accompanied by fibrin deposition in the abdominal cavity. In bacterial peritonitis, fibrin is formed in the peritoneal cavity because of activation of the intra-abdominal coagulation cascade; however, the fibrinolytic activity may reduce during peritonitis. This reduced peritoneal fibrinolytic capacity is associated with the development of adhesion. The reduced fibrinolytic capacity in peritonitis is probably caused by a decrease in tPA synthesis/release or an increase in PAI-1 expression.^[21–25] Experimental evidence suggests a direct relationship between decreased fibrinolytic activity and increased adhesions.^[11,12] Thompson et al.^[12] showed that the inflamed peritoneum had significantly less tPA than the normal peritoneum. Ivarsson et al.^[26] demonstrated that fibrinolytic capacity reduces in the peritoneal tissue of patients with a higher propensity for development of adhesions and likewise in the

adhesion tissue. Thus, components of the fibrinolytic system, such as tPA, may be used as markers of an increased risk for adhesion development. In our study, we evaluated the fibrinolytic system by measuring tPA levels. We detected increased tPA levels in both early and late periods in groups using polyurethane membranes ($p=0.001$ and $p=0.003$, respectively). These results confirmed that increased fibrinolytic activity reduces adhesion.

Surgical trauma to the abdomen initiates an inflammatory response in the peritoneum associated with the recruitment and activation of inflammatory cells and the secretion of proinflammatory mediators, such as interleukin (IL)-1, TNF- α , and transforming growth factor (TGF)- β 1. This proinflammatory process promotes the formation of a fibrin-rich matrix at the sites of peritoneal injury, thereby leading to the formation of fibrinous adhesions and eventually permanent adhesions.^[20] Hoshino et al.^[27] analyzed the significance of peritoneal macrophage activation and their expression of chemokine receptors in promoting postoperative and post-inflammatory peritoneal adhesion formation. The identification of macrophages and T lymphocytes proves an inflammatory activity, which is concordant with the findings of Binnebösel et al.,^[28,29] who found persistent inflammatory activity in adhesions even years after the initial surgery. In our study, we evaluated inflammation by measuring IL-6 and TNF- α levels. IL-6 levels were lower in the groups treated with polyurethane membranes during both early and late periods but were not statistically significant. In addition, TNF- α levels were significantly lower in the polyurethane membrane group in the early period ($p=0.026$).

Despite advances in surgery, the rate of anastomotic leakage is 3%–25% in most of the clinics around the world. Anastomotic healing is a complex mechanism involving inflammation, re-epithelialization, and collagen metabolism and is required to function in equilibrium with both cellular and intra-abdominal factors.^[30] Sepsis, systemic diseases, and conditions that cause deterioration in the intra-abdominal balance adversely affect anastomosis safety. Primary anastomosis is avoided in the case of intra-abdominal sepsis, and multistep procedures are preferred not only during elective but also emergency colon surgery.^[31] The literature revealed that several trials were conducted in patients with primary anastomosis using agents that could increase the safety of anastomosis and reduce the risk of reoperation.^[32,33]

Various methods have been described for testing the safety of anastomosis, with the measurement of explosion pressure being one of them. Rabau et al.^[34] found that the burst pressure and tensile strength is an essential finding concerning anastomotic strength, and the measurement of burst pressure indicates the safety of anastomosis. A study by Hendriks et al.^[35] recommended that the tissue hydroxyproline level should be measured besides the burst pressure, and these two parameters should be used together to test the safety

of the anastomosis. Cronin^[36] has reported that in anastomosis burst pressure measurements, the force to be applied from day three increased gradually and reached its maximum between seven and 10 days after the anastomosis. He also reported that the hydroxyproline concentration in the first three days decreased by 40% in the anastomosis area and reached normalcy from day five but was higher than normal between 10 and 14 days. In our study, we used both burst pressure and tissue hydroxyproline levels to test anastomosis safety. We found that the polyurethane membrane affected the hydroxyproline levels and burst pressures neither in the early nor late phase ($p=0.916$ and $p=0.429$ for early and late phase hydroxyproline levels, respectively; and $p=0.259$ and $p=0.177$ for early and late phase burst pressures, respectively).

In conclusion, the use of polyurethane membrane did not adversely affect the anastomosis healing despite reducing intra-abdominal adhesions. Nonetheless, intra-abdominal application of polyurethane membrane is beneficial in reducing intra-abdominal adhesions. This study has shown that polyurethane membrane can be an alternative to the materials used for this purpose because it is inexpensive and easy to apply. However, there is a need for a broader series of experimental and clinical studies on this subject. Notably, the burst pressure is directly related to the intra-abdominal adhesions. Therefore, it is essential to not extensively dissect the adhesions from the tissue when measuring the burst pressure in the rats for the accuracy of the measurement. Based on the intra-abdominal and perianastomotic adhesion score that we obtained, we found that the polyurethane membrane significantly reduced adhesions.

Limitations

The interesting point noted in our study was that tPA does not cause histopathologically adverse effects on the anastomosis despite being elevated in the group that used the polyurethane membrane. Notably, the polyurethane membrane allows the fibrinolytic activity to reduce adhesions by acting on the peritoneal surface without directly affecting the anastomosis. Nonetheless, the most significant limitation of our study is its inability to explain the effects of using polyurethane membrane without an aseptic environment. Therefore, future studies may explore the benefits of polyurethane membrane use in intra-abdominal anastomosis without sepsis.

Acknowledgments

We would like to thank the employees of the operating room and the department of pathology.

Ethics Committee Approval: Ethics committee approval was received for this study from the Ethics Committee of Istanbul University Faculty of Medicine (2011/88).

Peer-review: Internally peer-reviewed.

Authorship Contributions: Concept: G.Y.; Design: G.Y., Y.Ö.; Supervision: Y.T.; Resource: G.Y., Y.Ö., O.K.; Materials: G.Y., G.K.; Data: G.Y., Y.Ö.; Analysis: Y.T., G.K., O.Y.; Literature search: G.Y.; Writing: G.Y.; Critical revision: Y.T., O.Y.

Conflict of Interest: None declared.

Financial Disclosure: The authors declared that this study has received no financial support.

REFERENCES

- Ruggiero R, Sparavigna L, Docimo G, Gubitosi A, Agresti M, Procaccini E, et al. Post-operative peritonitis due to anastomotic dehiscence after colonic resection. Multicentric experience, retrospective analysis of risk factors and review of the literature. *Ann Ital Chir* 2011;82:369–75.
- Lefevre JH, Bretagnol F, Maggiori L, Ferron M, Alves A, Panis Y. Redo surgery for failed colorectal or coloanal anastomosis: a valuable surgical challenge. *Surgery* 2011;149:65–71. [CrossRef]
- Thornton FJ, Barbul A. Healing in the gastrointestinal tract. *Surg Clin North Am* 1997;77:549–73. [CrossRef]
- Kanellos I, Blouhos K, Demetriades H, Pramateftakis MG, Mantzoros I, Zacharakis E, et al. The failed intraperitoneal colon anastomosis after colon resection. *Tech Coloproctol* 2004;8:s53–5. [CrossRef]
- Marra F, Steffen T, Kalak N, Warschkow R, Tarantino I, Lange J, et al. Anastomotic leakage as a risk factor for the long-term outcome after curative resection of colon cancer. *Eur J Surg Oncol* 2009;35:1060–4. [CrossRef]
- Giuratrabocchetta S, Rinaldi M, Cuccia F, Lemma M, Piscitelli D, Polidoro P, et al. Protection of intestinal anastomosis with biological glues: an experimental randomized controlled trial. *Tech Coloproctol* 2011;15:153–8. [CrossRef]
- Prabhu R, Thomas S, Balasubramanian KA. Oral glutamine attenuates surgical manipulation-induced alterations in the intestinal brush border membrane. *J Surg Res* 2003;115:148–56. [CrossRef]
- Poonyakariyagorn T, Sirimaharaj W, Pinchai O, Angspatt A. Comparison among Op-site, polyvinyl chloride film and tulle gauze in the treatment of skin graft donor sites. *J Med Assoc Thai* 2002;85:455–61.
- Mazuji MK, Kalambaheti K, Pawar B. Prevention of adhesions with polyvinylpyrrolidone. Preliminary Report. *Arch Surg* 1964;89:1011–5.
- Prockop DJ, Kivirikko KI. Relationship of hydroxyproline excretion in urine to collagen metabolism: biochemistry and clinical applications. *Ann Intern Med* 1967;66:1243–66. [CrossRef]
- Aarons CB, Cohen PA, Gower A, Reed KL, Leeman SE, Stucchi AF, et al. Statins (HMG-CoA reductase inhibitors) decrease postoperative adhesions by increasing peritoneal fibrinolytic activity. *Ann Surg* 2007;245:176–84. [CrossRef]
- Thompson JN, Paterson-Brown S, Harbourne T, Whawell SA, Kalodiki E, Dudley HA. Reduced human peritoneal plasminogen activating activity: possible mechanism of adhesion formation. *Br J Surg* 1989;76:382–4.
- Holmdahl L, Eriksson E, al-Jabreen M, Risberg B. Fibrinolysis in human peritoneum during operation. *Surgery* 1996;119:701–5. [CrossRef]
- Holmdahl L, Eriksson E, Eriksson BI, Risberg B. Depression of peritoneal fibrinolysis during operation is a local response to trauma. *Surgery* 1998;123:539–44. [CrossRef]
- Senthilkumar MP, Dreyer JS. Peritoneal adhesions: pathogenesis, assessment and effects. *Trop Gastroenterol* 2006;27:11–8.
- Chen SH, Chou PY, Chen ZY, Lin FH. Electrospun Water-Borne Polyurethane Nanofibrous Membrane as a Barrier for Preventing Postoperative Peritoneal Adhesion. *Int J Mol Sci* 2019;20:1625. [CrossRef]
- Ghosh SJ, Kumar K, Gilbert PM. Opsite spray: its use for fixation of meshed skin grafts. Simple and low tech. *Burns* 1997;23:601–3. [CrossRef]
- Dunst KM, Bauer T, Huemer GM. Opsite as a useful addition to surgical draping in reduction mammoplasty. *Plast Reconstr Surg* 2004;114:820.
- Burns JW, Colt MJ, Burgees LS, Skinner KC. Preclinical evaluation of Septrafil bioresorbable membrane. *Eur J Surg Suppl* 1997;(577):40–8.
- Lim R, Morrill JM, Lynch RC, Reed KL, Gower AC, Leeman SE, et al. Practical limitations of bioresorbable membranes in the prevention of intra-abdominal adhesions. *J Gastrointest Surg* 2009;13:35–41; discussion 41–2. [CrossRef]
- O’Leary DP, Coakley JB. The influence of suturing and sepsis on the development of postoperative peritoneal adhesions. *Ann R Coll Surg Engl* 1992;74:134–7.
- Hau T, Payne WD, Simmons RL. Fibrinolytic activity of the peritoneum during experimental peritonitis. *Surg Gynecol Obstet* 1979;148:415–8.
- Holmdahl L, Eriksson E, al-Jabreen M, Risberg B. Fibrinolysis in human peritoneum during operation. *Surgery* 1996;119:701–5. [CrossRef]
- Vipond MN, Whawell SA, Thompson JN, Dudley HA. Peritoneal fibrinolytic activity and intra-abdominal adhesions. *Lancet* 1990;335:1120–2.
- van Goor H, Bom VJ, van der Meer J, Sluiter WJ, Bleichrodt RP. Coagulation and fibrinolytic responses of human peritoneal fluid and plasma to bacterial peritonitis. *Br J Surg* 1996;83:1133–5. [CrossRef]
- Ivarsson M, Bergström M, Eriksson E, Risberg B, Holmdahl L. Tissue markers as predictors of postoperative adhesions. *Br J Surg* 1998;85:1549–54. [CrossRef]
- Hoshino A, Kawamura YI, Yasuhara M, Toyama-Sorimachi N, Yamamoto K, Matsukawa A, et al. Inhibition of CCL1-CCR8 interaction prevents aggregation of macrophages and development of peritoneal adhesions. *J Immunol* 2007;178:5296–304. [CrossRef]
- Binnebösel M, Rosch R, Junge K, Lynen-Jansen P, Schumpelick V, Klinge U. Macrophage and T-lymphocyte infiltrates in human peritoneal adhesions indicate a chronic inflammatory disease. *World J Surg* 2008;32:296–304. [CrossRef]
- Binnebösel M, Klink CD, Serno J, Jansen PL, von Trotha KT, Neumann UP, et al. Chronological evaluation of inflammatory mediators during peritoneal adhesion formation using a rat model. *Langenbecks Arch Surg* 2011;396:371–8. [CrossRef]
- Marques e Silva S, Oliveira MV, Brandão AM, Carneiro FP, Ferreira VM, Parra RS, et al. Study on adhesion formation and the healing of colon anastomosis in rats with induced peritoneal sepsis. *Acta Cir Bras* 2011;26:100–5. [CrossRef]
- Thornton M, Joshi H, Vimalachandran C, Heath R, Carter P, Gur U, et al. Management and outcome of colorectal anastomotic leaks. *Int J Colorectal Dis* 2011;26:313–20. [CrossRef]
- Subhas G, Bhullar JS, Cook J, Shah A, Silberberg B, Andrus L, et al. Topical gentamicin does not provide any additional anastomotic strength when combined with fibrin glue. *Am J Surg* 2011;201:339–43. [CrossRef]
- Pantelis D, Beissel A, Kahl P, Wehner S, Vilz TO, Kalf J. The effect of sealing with a fixed combination of collagen matrix-bound coagulation factors on the healing of colonic anastomoses in experimental high-risk mice models. *Langenbecks Arch Surg* 2010;395:1039–48. [CrossRef]
- Rabau M, Eyal A, Kluger Y, Dayan D. Bursting pressure in anastomotic healing in experimentally induced colitis in rats. *Dis Colon Rectum* 1998;41:468–72. [CrossRef]
- Hendriks T, Mastboom WJ. Healing of experimental intestinal anastomoses. Parameters for repair. *Dis Colon Rectum* 1990;33:891–901.
- Cronin K, Jackson DS, Dunphy JE. Changing bursting strength and collagen content of the healing colon. *Surg Gynecol Obstet* 1968;126:747–53.

DENEYSSEL ÇALIŞMA - ÖZET

Poliüretan membranın karınıçi adezyonlar ve septik kolon anastomozu üzerine etkileri

Dr. Gökhan Yılmaz,¹ Dr. Yaşar Özdenkaya,¹ Dr. Oğuzhan Karatepe,²
Dr. Yusuf Tanrıkulu,³ Dr. Gülçin Kamalı,⁴ Dr. Orhan Yalçın⁵

¹Medipol Üniversitesi Tıp Fakültesi, Genel Cerrahi Anabilim Dalı, İstanbul

²Memorial Hastanesi, Genel Cerrahi Kliniği, İstanbul

³KTO Karatay Üniversitesi Tıp Fakültesi, Genel Cerrahi Anabilim Dalı, İstanbul

⁴Okmeydanı Eğitim ve Araştırma Hastanesi, Patoloji Kliniği, İstanbul

⁵Okmeydanı Eğitim ve Araştırma Hastanesi, Genel Cerrahi Kliniği, İstanbul

AMAÇ: Gastrointestinal sistem cerrahisinden sonra görülen anastomoz kaçağı ve adezyonlar hala önemli bir morbidite ve mortalite nedenidir. Anastomoz kaçağı oranı %3–8 iken, kaçağa bağlı mortalite oranı %30'un üzerindedir. Karınıçi sepsis anastomoz kaçağının iyi bilinen bir nedenidir. Ayrıca, karınıçi adezyon hastane başvuru oranının ve morbidite ve mortalite ile ilişkili reoperasyonların önemli bir nedenidir. Bu çalışmada, bir poliüretan membranın anastomoz iyileşmesi ve karınıçi yapışıklıklar üzerine etkileri araştırıldı.

GEREÇ VE YÖNTEM: Bu çalışma için dört gruba ayrılmış 32 Wistar Albino sıçan kullanıldı. Çekal ligasyon ve perforasyon oluşturulduktan sonra peritoneal refleksiyonun 2 cm yukarısından standart sol kolon rezeksiyonu ve anastomozu yapıldı. Kontrol gruplarına (1, 3) herhangi bir tedavi verilmedi. Deney grubunda (2, 4) ise kolon anastomozunun etrafına poliüretan membran sarıldı. Patlama basıncı, hidroksiprolin, IL-6 (interlökin 6), NO (nitrik oksit), TPA (doku plazminojen aktivatörü), TNF- α (Tümör nekroz faktörü alfa) seviyeleri ölçüldü ve relaparotomi sonrası anastomozun histopatolojik özellikleri analiz edildi. Ayrıca adezyon skorları ölçüldü.

BULGULAR: Üçüncü ve beşinci günler arasında sakrifiye edilen hayvanlar arasındaki ortalama patlama basıncı değerlerinde istatistiksel olarak anlamlı bir fark yoktu ($p=0.259$, $p=0.177$). Tüm gruplar karşılaştırıldığında, hidroksiprolin, NO, IL-6 seviyeleri arasında anlamlı bir fark gözlenmedi ($p=0.916$, $p=0.429$, $p=0.793$, $p=0.332$, $p=0.400$, $p=0.317$). Bununla birlikte, grup 2 ve grup 4'te, TPA seviyeleri poliüretan membran tedavisi ile anlamlı olarak yüksekti ($p=0.001$, $p=0.003$) ve adezyon skorlarına göre istatistiksel olarak anlamlı bir fark vardı ($p<0.035$). Grup 2 ve grup 4, grup 1 ve grup 3'ten daha düşük adezyon skorlarına sahipti.

TARTIŞMA: Biz deneysel septik kolon anastomoz modelinde poliüretan membranın histopatolojik ve biyokimyasal iyileşme üzerinde pozitif veya negatif bir etkisi olmadığını bulduk. Ancak, poliüretan membranın anastomoz çevresine uygulanması intraabdominal adezyonları etkili bir şekilde azaltmaktadır.

Anahtar sözcükler: Adezyon; intraabdominal sepsis; kolon anastomozu; poliüretan membran.

Ulus Travma Acil Cerrahi Derg 2021;27(1):1-8 doi: 10.14744/tjtes.2020.41624