



Rotational head trauma with callosal contusion and C6 fracture: a high-speed motorcycle accident

Kallozal kontüzyonla birlikte rotasyonel kafa travması ve C6 kırığı:
Yüksek hızlı motosiklet kazası

Gentian VYSHKA,¹ Blerti TROSHANI,² Dorjan BOZAXHIU,³ Arben MITRUSHI⁴

We present the case of a 34-year-old Albanian male who was riding a motorcycle when he collided at high-speed with a four-wheel vehicle. After a triple pivotal rotation in the air at the moment of impact, he fell from the motorcycle to the ground. The clinical picture thereafter was one of deep coma, treated in the intensive care unit for nine days, until he regained consciousness and long-term rehabilitation procedures were put in place. The magnetic resonance and computed tomography images were very illustrative of a rotational head trauma mechanism, since in addition to multiple callosal hemorrhages and the lack of cranial fractures, a linear complex fracture of the C6 vertebra was seen, justifying orthopedic treatment through immobilization of the cervical spine. Rotational angular acceleration seems to be an important causative factor toward provoking diffuse brain and/or axonal injury; the etiological importance on the direct skull impact is controversial, but in any case not negligible.

Key Words: Axonal injury; brain trauma; rotational angular acceleration; traffic accident.

Bu yazıda, yüksek hızla motosiklet sürerken dört tekerli bir araca çarpmış 34 yaşındaki bir Arnavut erkeği olgusu sunuldu. Çarpma anında havada eksenini etrafında üç kez döndükten sonra motosikletinden yere düşen olgu, daha sonra derin koma klinik tablosuyla yoğun bakım ünitesinde, bilincine yeniden kavuşana kadar dokuz gün tedavi edilmiş ve uzun dönemli rehabilitasyon prosedürleri uygulanmış. Manyetik rezonans ve bilgisayarlı tomografi görüntüleri rotasyonel kafa travması açısından çok aydınlatıcıydı. Gerçekten kafatası kırıkları olmaksızın birden fazla kallozal kanama odağına ilaveten C6 vertebraında lineer kompleks kırık hattı izlenmekteydi. Bu olgu boyun omurgasını hareketsiz durumda tespit edip ortopedik tedavi uygulanmaya uygundu. Rotasyonel açısal akselerasyonun diffüz beyin ve/veya aksonal hasarına neden olan önemli bir nedensel faktör olduğu görünmektedir. Doğrudan kafatasına gelen darbenin etyolojik önemi tartışma konusuysa da asla gözardı edilmemelidir.

Anahtar Sözcükler: Aksonal travma; beyin travması; rotasyonel açısal akselerasyon; trafik kazası.

CASE REPORT

A 34-year-old male (height 176 cm, weight 85 kg) was riding his motorcycle on a secondary rural road in central Albania when the motorcycle collided at high speed with a four-wheel drive vehicle. According to witnesses, the injured person was wearing a helmet and was driving approximately 50 km/hr. At the site of the accident, tracks on the ground indicating a triple pivotal rotation of the motorcycle were evident. The injured lost consciousness immediately at the site of

the collision; the driver of the car causing the crash and other witnesses accompanied the patient to the nearest hospital.

Upon arrival, he was in a deep coma (Glasgow Coma Scale score: 5 points) with flexion provoked only by painful stimuli; an anisocoria with left but reactive mydriasis was present. The patient was otherwise stable from the hemodynamic point of view. He was admitted in the Intensive Care Unit (ICU) and intubated; appropriate therapy followed, and a com-

Departments of ¹Neurology, ⁴Radiologic Anatomy, Tirana University Faculty of Medicine, Tirana; Departments of ²Radiology, ³Surgery, Hygeia Hospital, Tirana, Albania.

Tiran Üniversitesi Tıp Fakültesi, ¹Nöroloji Anabilim Dalı, ⁴Radyolojik Anatomi Anabilim Dalı, Tiran; Hygeia Hastanesi, ²Radyoloji Bölümü, ³Cerrahi Kliniği, Tiran, Arnavutluk.

plete diagnostic workup was performed within the day of admittance.

Magnetic resonance imaging (MRI) performed upon admission showed multiple contusions, almost all of which were remarkably concentrated in the mid-line structures: callosal gyrus and upper brain stem; no skull fractures were seen (Figs. 1a, b). A discrete subdural temporal-occipital hematoma requiring no neurosurgical intervention resolved under conserva-

tive treatment. On the computed tomography (CT) scan of the cervical spine, a linear complex fracture of the posterior arch of C6 was also evident and treated through immobilization (Fig. 1c, d).

The patient left the ICU nine days after admittance and was discharged from the hospital three weeks after being released from the ICU; amnesia regarding the traumatic event and anosmia were the only sequelae. He was referred to a neuropsychological facility

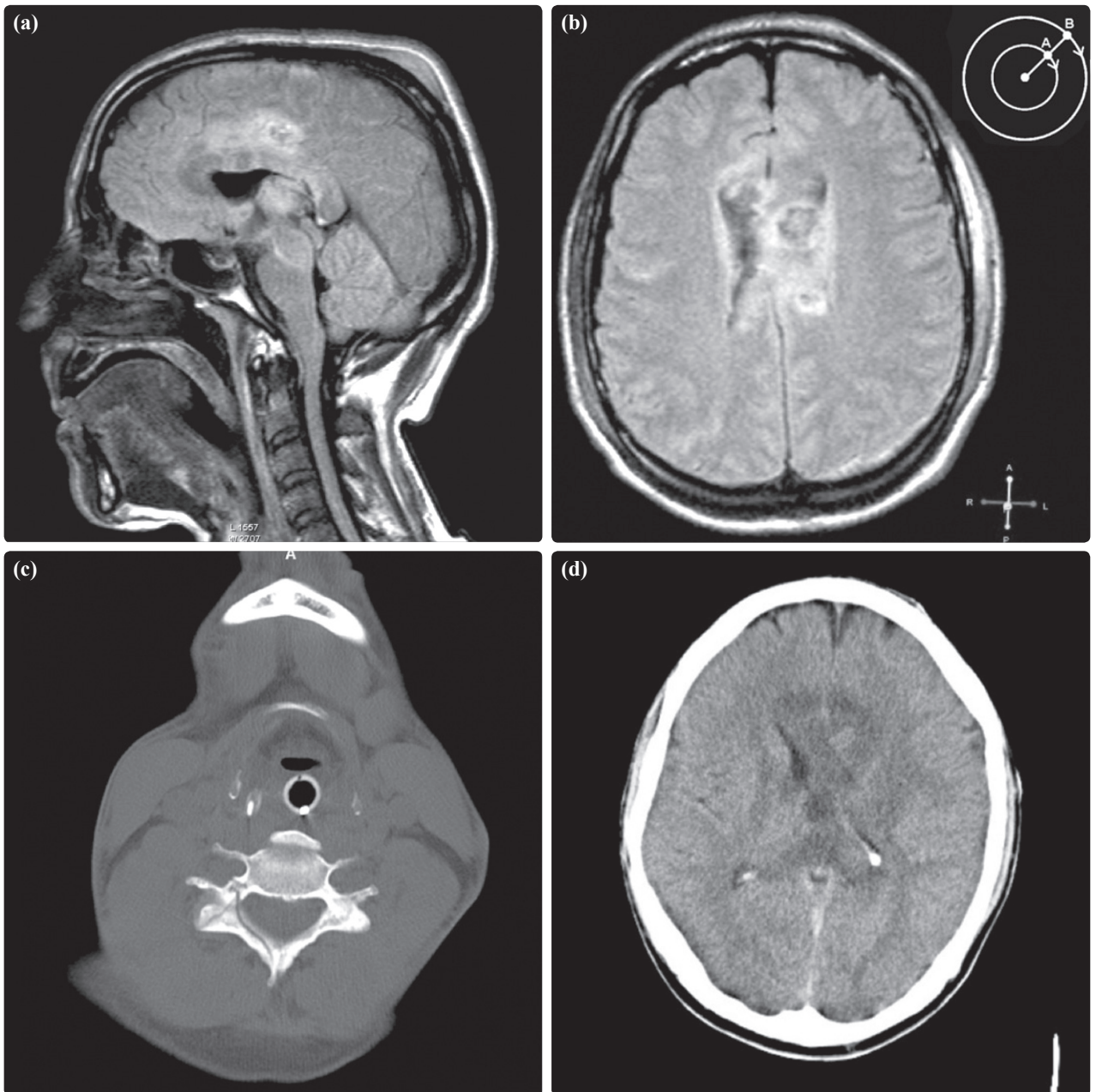


Fig. 1. (a) Callosal contusion and hemorrhagic upper brain stem foci (MRI image T2-weighted, FLAIR). (b) Contusive hemorrhagic foci concentrated on the midline and on the central structures, suggesting the existence of a shear momentum, probably related to the fact that the outer [cortical] structures [inset schema, above right] had a higher tangential speed during acceleration-deceleration when compared to the inner and medially positioned areas (MRI image T2-weighted, FLAIR). (c) A linear complex fracture at the left posterior arch of the 6th cervical vertebra was treated through immobilization (CT image). (d) A follow-up cranial CT was performed five days after the MRI; callosal hemorrhagic foci and diffuse white matter edema are visible, with a slight midline shift.

abroad for long-term cognitive rehabilitation, and no pharmacological therapy was advised upon discharge; no eventual clinical and imaging follow-up took place.

DISCUSSION

Angular and rotational acceleration has been mentioned as an important factor causing head injury of different gravity, since 1943.^[1] Generally, all studies point to brain deformation, strain and shear forces created during the high-speed motion, be it linear or angular, and direct impact with hard structures. When angular acceleration was proposed as a cause of gliding contusion, creating strain and eventually lacerating deep small vessels, it was suggested that the maximum shear zone deepened with an increasing angular acceleration speed.^[2] On the other hand, intracranial motion seems to be slower and following that of the skull; inertia of central midline structures might play a role in rapid accelerative rotation, even more during the deceleration phase prior to the final impact with the hard structures (for example, during fall to the ground). The severity of diffuse brain injury (DBI) and diffuse axonal injury (DAI) has been correlated with the amplitude of the angular acceleration.^[3]

Different models have been proposed and experimented, aiming for a better comprehension of the head trauma mechanism in humans. Among others, rabbits, rats and even sheep have been selected and experimented, although the authors themselves sometimes acknowledge the structural and morphologic differences in comparison to the human brain, thus making the laboratory results hard to extrapolate to everyday settings.^[4,5]

It is accepted that the brain is heterogeneous and anisotropic. Furthermore, when studying soft tissue properties, elastoplastic responses and viscoelastic mechanisms, authors suggest different mechanical intrinsic properties of three cranial structures: gray matter (GM), white matter (WM), and brain stem with corpus callosum (BSCC).^[6] Thus, data offered for the long-term shear modulus (elastoplastic response) are 6.80 kPa for GM, 8.20 kPa for WM and 11.60 kPa for BSCC.^[6] The same source also offers different figures for the initial shear modulus for all three of

these rather schematic divisions of the central nervous system, which might correspond, in an approximate form, to the cortex (GM), to the corona radiata, with the subcortical and periventricular areas (WM), and to the central-midline structures (BSCC). Thus, albeit authors generally agree that the brain and spinal cord move as a unit when exposed to a sagittal rotational acceleration of the head and neck,^[7] our case suggests that a different momentum might exist, mainly during the deceleration that follows the abrupt cessation of an angular head motion, creating an important shear factor between the cortical-external structures and the BSCC on the other side. The angular speed is by far a very important aggravating factor for the overall clinical picture and prognosis.^[8] In our case, the presence of a vertebral fracture warranted even more the suspicion of a high-speed rotational head trauma, causing multiple callosal and brain stem contusions.

Conflict-of-interest issues regarding the authorship or article: None declared.

REFERENCES

1. Holbourn AHS. Mechanics of head injuries. *Lancet* 1943; ii: 438-441.
2. Löwenhielm P. Mathematical simulation of gliding contusions. *J Biomech* 1975;8:351-6.
3. Margulies SS, Thibault LE. A proposed tolerance criterion for diffuse axonal injury in man. *J Biomech* 1992;25:917-23.
4. Krave U, Al-Olama M, Hansson HA. Rotational acceleration closed head flexion trauma generates more extensive diffuse brain injury than extension trauma. *J Neurotrauma* 2011;28:57-70.
5. Davidsson J, Risling M. A new model to produce sagittal plane rotational induced diffuse axonal injuries. *Front Neurol* 2011;2:41.
6. El Sayed T, Mota A, Fraternali F, Ortiz M. A variational constitutive model for soft biological tissues. *J Biomech* 2008;41:1458-66.
7. Bayly PV, Black EE, Pedersen RC, Leister EP, Genin GM. In vivo imaging of rapid deformation and strain in an animal model of traumatic brain injury. *J Biomech* 2006;39:1086-95.
8. King AI, Yang KH, Zhang L, Hardy W, Viano DC. Is head injury caused by linear or angular acceleration? Proceedings of the IRCOBI Conference, Lisbon Portugal: September 2003. p. 1-12.