

Evaluation of the effects of ectopic replantation on amputate survival in the management of crush traumatic amputations in rats: An experimental study

 Münür Selçuk Kendir,¹  Bilsev İnce,²  Majid İsmayılzade,³  Zikrullah Baycar,⁴
 Hayri Ahmet Burak Nurşen,⁵  Mehmet Dadacı⁵

¹Plastic, Reconstructive and Aesthetic Surgery Clinic, Ankara Dr Abdurrahman Yurtaslan Oncology Training and Research Hospital, Ankara-Türkiye

²Private Practice, Izmir- Türkiye

³Department of Plastic and Reconstructive and Aesthetic Surgery, Istinye University Faculty of Medicine, Istanbul-Türkiye

⁴Plastic, Reconstructive and Aesthetic Surgery Clinic, Konya City Hospital, Konya-Türkiye

⁵Department of Plastic, Reconstructive and Aesthetic Surgery, Meram Faculty of Medicine, Necmettin Erbakan University, Konya-Türkiye

ABSTRACT

BACKGROUND: This controlled experimental study aimed to compare ectopic replantation with other replantation techniques in a rat model of crush amputations. It also assessed the impact of different replantation methods on the viability of amputates.

METHODS: Forty male Wistar albino rats were divided into four groups. Groin flaps served as the amputation model. Group 1 underwent guillotine-style amputation followed by orthotopic replantation, Group 2 experienced crush-type amputation and orthotopic replantation, Group 3 had crush-type amputation and orthotopic replantation with a vein graft, and Group 4 underwent crush-type amputation followed by ectopic replantation. Flap viability and perfusion rates were assessed on day 3 using an infrared perfusion assessment system. The ratio of viable area to total flap area and thrombus formation in the pedicle vessels were evaluated on day 7.

RESULTS: Infrared evaluations on day 3 post-replantation revealed flap perfusion percentages of 73.5% in Group 1, 11.1% in Group 2, 65% in Group 3, and 64.1% in Group 4. Statistical analysis indicated that Group 1 exhibited the highest perfusion rates, while Group 2 showed the lowest. No differences were observed between Groups 3 and 4. On the seventh day, the average surviving flap areas were found to be 74.6% in Group 1, 2.5% in Group 2, 64.5% in Group 3, and 64% in Group 4. Statistically, Group 1 exhibited the best outcomes, while Group 2 had the poorest, with no differences between Groups 3 and 4. Additionally, thrombus formation was observed in the vessels of two animals in Group 1, nine in Group 2, and three each in Groups 3 and 4. Significant statistical differences were noted among the groups.

CONCLUSION: The results indicate that ectopic replantation and replantation with a vein graft are equally effective. The preferred method for crush-type replantations may depend on the patient's and the amputated limb's conditions. In crush-type amputations, we recommend vein graft repair if the patient's overall condition supports replantation and if crushed segments can be debrided without excessive shortening of the amputated part. If these conditions are not met, temporary ectopic replantation is advised to preserve the amputated limb.

Keywords: Crush-type injury; ectopic replantation; microsurgery; replantation; vascular anastomosis.

Cite this article as: Kendir MS, İnce B, İsmayılzade M, Baycar Z, Nurşen HAB, Dadacı M. Evaluation of the effects of ectopic replantation on amputate survival in the management of crush traumatic amputations in rats: An experimental study. *Ulus Travma Acil Cerrahi Derg* 2024;30:382-389.

Address for correspondence: Münür Selçuk Kendir

Ankara Dr Abdurrahman Yurtaslan Oncology Training and Research Hospital, Ankara, Türkiye

E-mail: selcuk_kendir@msn.com

Ulus Travma Acil Cerrahi Derg 2024;30(6):382-389 DOI: 10.14744/tjtes.2024.39470

Submitted: 14.12.2023 Revised: 01.05.2024 Accepted: 15.05.2024 Published: 00.00.0000

OPEN ACCESS This is an open access article under the CC BY-NC license (<http://creativecommons.org/licenses/by-nc/4.0/>).



INTRODUCTION

Traumatic limb amputations result in significant functional and psychological losses for individuals. Particularly over the last century, the incidence of traumatic amputations has surged globally, largely due to increased employment in heavy industries and the prevalence of highly explosive weapons in military conflicts.^[1] Replantation is the optimal choice for reconstructing a traumatically amputated limb, as it most closely resembles the original.^[2]

In cases of crush amputations, vascular destruction extends both proximal and distal to the trauma site, affecting other tissues similarly. Given the complexity of the trauma, orthotopic replantation may not be feasible for some crush-type amputations due to limitations with recipient vessels.^[3] Furthermore, even when orthotopic replantation is possible after crush and avulsion amputations, complications such as deep tissue infection, necrosis, and the potential for subsequent re-amputation are commonly observed in the early follow-up period.^[4,5] Additionally, the overall condition of a patient, particularly in cases involving multiple traumas, may preclude a lengthy and demanding operation like replantation.^[6] Under such conditions, ectopic replantation may be recommended both to preserve the amputated part, which cannot be otherwise restored, and to allow time for the patient's general condition to stabilize.^[7,8]

Ectopic replantation is defined as the transplantation of an amputated body part to a site other than its original anatomical location, utilizing alternative recipient vessels. In this protocol, the blood supply to the limb replanted ectopically is sustained at the new location until the patient's condition and blood vessel status are conducive to orthotopic replantation. The limb is then returned to its original anatomical location in a subsequent operation when conditions are favorable.^[9,10]

Although the literature features a limited number of case reports and reviews on ectopic replantation, there are no experimental controlled studies addressing this topic. The success of amputation viability reported in cases of ectopic replantation, based on relevant clinical experiences, underscores the need for a controlled study on this topic. This research aims to compare the outcomes of ectopic replantation following crush injuries with other techniques, and to assess amputation viability after ectopic replantation in an experimental controlled setting.

MATERIALS AND METHODS

This study was conducted using 40 male Wistar-Albino rats between September and December 2021, following ethical approval from the Local Ethics Committee for Animal Experiments. The rats were divided into four experimental groups:

- Group 1: Ten rats underwent orthotopic replantation following guillotine amputation.
- Group 2: Ten rats received orthotopic replantation with intact vessel ends after crush amputation.
- Group 3: Ten rats underwent orthotopic replantation after

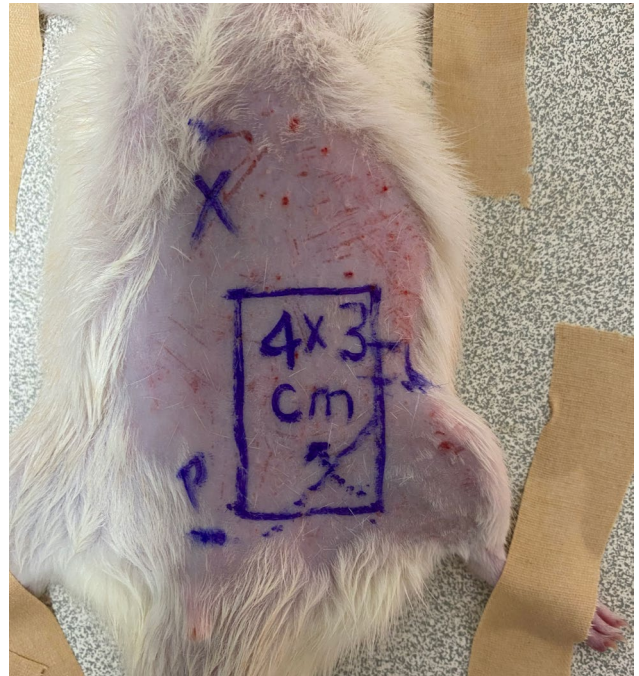


Figure 1. Preoperative design of the left inguinal flap on a rat, showing delineated borders. X: Xiphoid Process; P: Pubic Bone; Dotted line: Iliac Ligament.

crush-type amputation, which involved cleaning the crushed vessel segments and using a vein graft to address the resultant vascular defect.

- Group 4: Ten rats underwent ectopic replantation to the recipient vessels on the contralateral side following crush-type amputation, with the procedure including the cleaning of crushed vessel segments.

Surgical Procedure

The left groin flaps of the rats served as the replantation model in this study. Following appropriate anesthesia, the lower abdomen and inguinal regions were shaved on both sides. The rats were then positioned supine on the experimental board, with all four limbs and tails secured to the board using surgical tapes. Prior to surgery, the surgical field was disinfected with Baticinol® (Alg, Istanbul, Türkiye).

In all animals, the left inguinal flap was marked for standardization with a predetermined size of 4 x 3 cm². While defining the borders of the flap, we ensured not to cross the midline and remained within the rectangular area between the xiphoid process, inguinal ligament, pubic bone, and costae (Fig. 1).

Following the preoperative design, superior, medial, and lateral incisions were made. During the elevation of the flap using Mayo scissors, it was noted that the pedicle vessels originating from the inferior side were incorporated into the flap. The inferior incision was then performed with caution to avoid damaging the pedicle. Subsequent pedicle dissection allowed for the harvesting of the flap as an island flap based on the superficial epigastric artery (SEA) and vein (SEV) (Fig. 2).

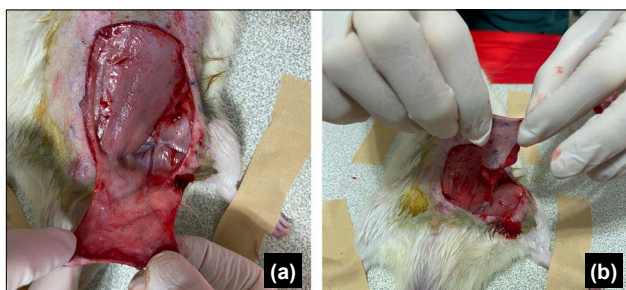

Figure 2. Harvesting of the left groin island flap. (a) The groin flap includes superficial epigastric vessels. (b) View of the flap harvested based on the superficial epigastric artery and vein (SEA and SEV).

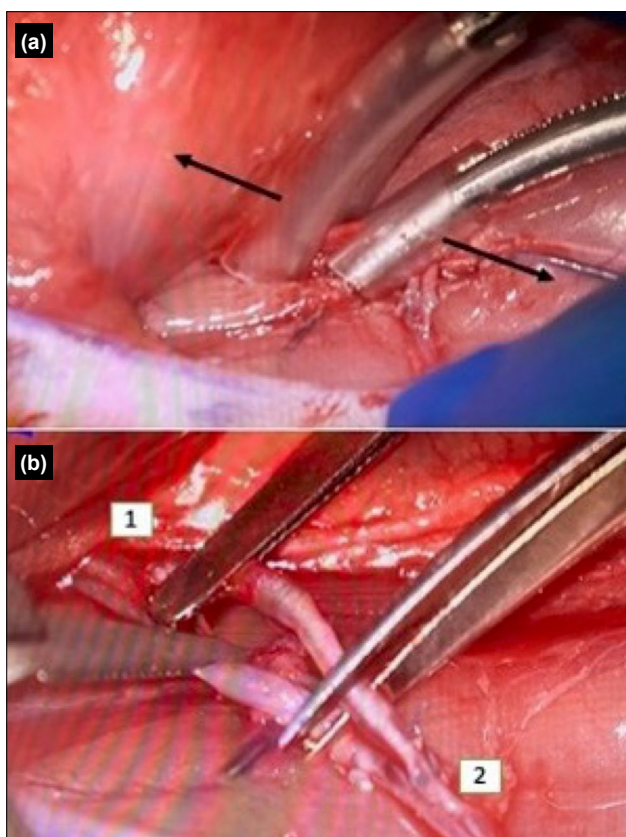


Figure 3. Crush type amputation procedure. (a) Avulsion injury achieved by pulling mosquito clamps with silicone tubes placed in their jaws, applied in both proximal and distal directions. (b) Following the creation of a crush-type injury, amputation was performed using scissors (1. Proximal end of femoral vessels. 2. Crushed vascular segment showing thrombus due to avulsion).

Vascular dissection was extended toward the femoral vessels, the primary source of circumflex vessels. Side branches of the femoral vessels, except for the SEA and SEV, were ligated, and the distal parts of the femoral vessels were also severed following surgical ligation. This process facilitated the preparation of an island flap based on the femoral vessels.

Amputation Models

After flap dissection, the femoral arteries and veins of the

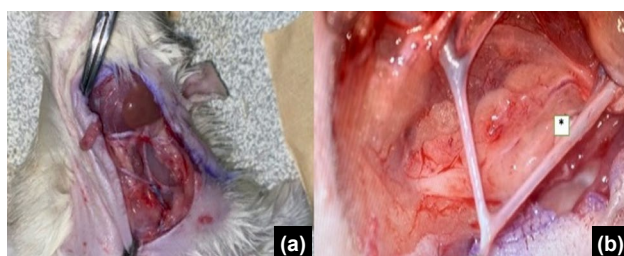


Figure 4. Posterior facial vein graft harvesting in rats. (a) Naked eye view. (b) Microscopic view. * indicates the posterior facial vein.

rats in the Group 1, which underwent guillotine amputation, were cleanly severed using microscissors. This procedure was carefully performed to avoid damage to the surrounding tissues, thus completing the amputation process.

For rats in Groups 2, 3, and 4, scheduled for crush amputation, we adhered to the crush amputation model described by Lykoudis et al.^[11] A standard Dieffenbach bulldog vessel clamp (48 mm in length, maximum pressure 30 N) was applied to the femoral artery and vein to induce a crush injury. This clamp was left in place for 30 minutes. After the waiting period, the second phase of the model commenced, which involved creating an avulsion-type injury. Two standard Halsted mosquito hemostat clamps (BH 110, 125 mm in length) equipped with silicone tubes in their jaws were placed 0.2 mm distal and proximal to the injury site. The clamps were then squeezed at the level of the first tooth, and the hemostats were pulled in both distal and proximal directions to avulse the vessel over a total distance of 1 cm. After completing the avulsion procedure, the amputation was finalized using microscissors, leaving a 1 cm length of the crush-injured region on the amputate (Fig. 3).

Replantation Models

Replantation procedures were performed as per the previously designated groups. In Groups 1 and 2, the amputated parts were orthotopically replanted without any additional procedures to the vessels or other structures.

In Group 3, the avulsed 1 cm long vessel segments were debrided, and orthotopic replantation was conducted by replacing the excised segment with vein grafts harvested from the posterior facial vein of the same animal. The left side was used for vein graft harvesting. If a vein graft of sufficient length could not be collected from one side, the contralateral side was utilized to obtain the necessary length of veins (Fig. 4).

In Group 4, during the 30-minute application period of the bulldog clamp, the contralateral femoral artery and vein were dissected and prepared as recipient vessels for replantation. After debriding the avulsed portion of the vessels from the flap, ectopic replantation was performed onto these contralateral vessels. Post-replantation, the anterior abdominal skin island was employed as an advancement flap to cover the donor area, while the replanted flap was positioned in the right inguinal region (Fig. 5).

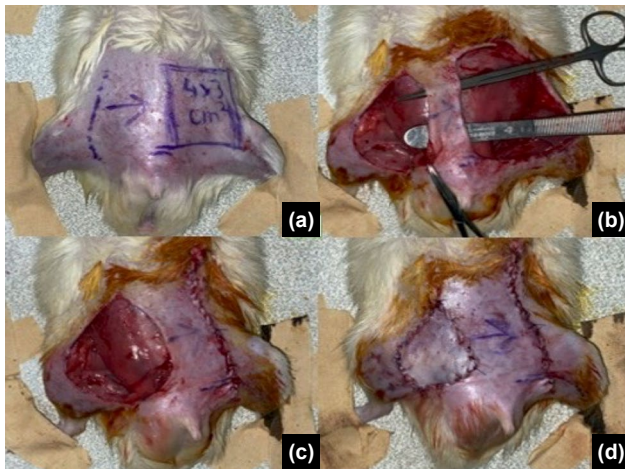


Figure 5. Ectopic replantation. (a) Preoperative planning. (b) Mobilization of the advancement flap for donor site coverage. (c) Suturing of the advancement flap to the new location. (d) The ectopically replanted skin island covering the right inguinal region.

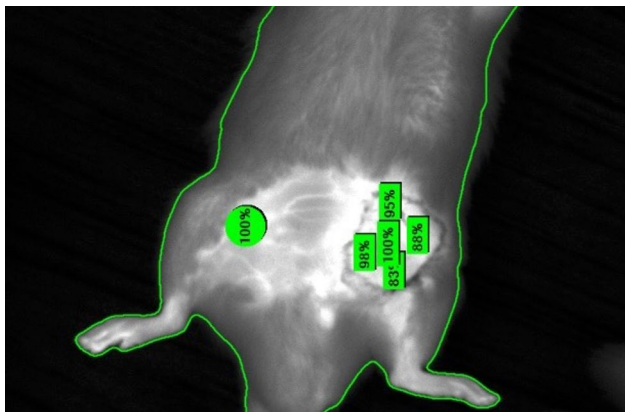


Figure 6. Determination of skin perfusion rate on day 3 with ICG-assisted infrared imaging system. The anterior abdominal wall served as a reference; perfusion percentage was averaged from the corners and the midpoint of the flap.

All vascular anastomoses were performed using 10/0 nylon sutures under an operating microscope and microsurgical instruments. Skin closures were accomplished with 4/0 Prolene sutures. Following the surgery, all rats were housed individually and monitored regularly. Additionally, an antiseptic solution was applied daily to the incision sites for 5 days post-surgery, and the wounds were monitored without closure.

Outcome Evaluations

The ratio of flap perfusion to intact tissue perfusion was determined using the Indocyanine Green-assisted (ICG-assisted) intraoperative perfusion assessment system (SPY, LifeCell Corp., Branchburg, NJ, USA) under general anesthesia at the 72nd hour post-operation in all groups. For ICG injection, subclavian veins of all animals were catheterized, and ICG at a dose of 0.3 mg/kg diluted to 0.1 ml was administered intravenously.^[12] For perfusion assessment, intact skin on the anterior abdominal wall was used as the reference point. Perfusion rates were then measured at all four corners and the

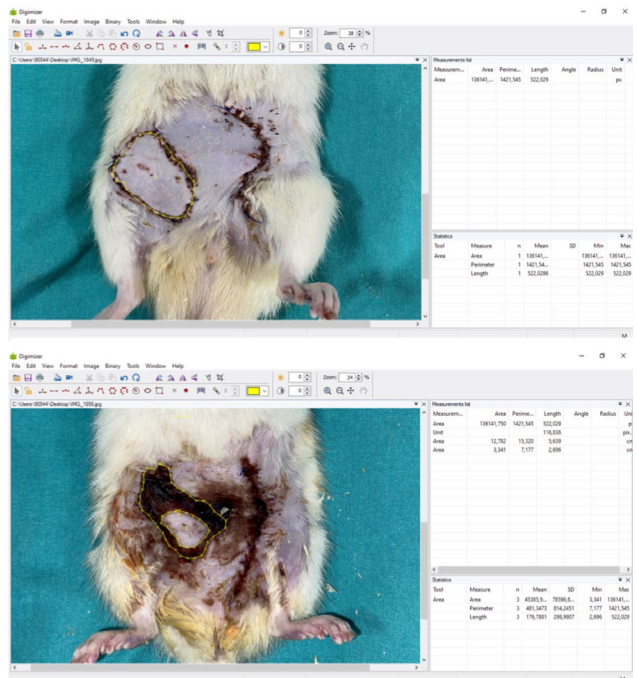

Figure 7. Determination of the percentage of living flap area using the Digimizer image analysis program.

center of the flap skin using a perfusion assessment device, as previously described. On the third day, the flap perfusion rates for each rat were calculated by averaging these five measurements (Fig. 6).

Seven days after the surgical procedures, rats from all groups were immobilized on the operating board under appropriate anesthesia. Photographs of the replanted skin islands were taken in a standardized manner using an Apple iPhone 11 (Apple Corp., California, USA). The images were analyzed with Digimizer image analysis software (MedCalc Software Ltd., Ostende, Belgium), and the proportions of living and necrotic flap areas were calculated using this software (Fig. 7).

Following the photo session on the seventh day, rats still under general anesthesia underwent a subsequent surgery to expose the femoral vessels. The presence of thrombi in the recipient artery was assessed under an operating microscope, and all rats were classified as having either thrombus present or absent. At the end of the procedure, all animals were euthanized using the cervical dislocation method.

The threshold value for perfusion was set at 35% on the third day postoperatively.^[13] Subsequently, the correlation between the percentage of surviving flap area, as assessed at the end of the seventh day, and the perfusion rates measured on the third day was evaluated.

Statistical Analyses

Data were collected using the Statistical Package for the Social Sciences (SPSS) version 27.0 (IBM Corp., Armonk, New York, USA). We assessed conformity to normal distribution and employed Kruskal-Wallis Analysis of Variance for analyz-

ing independent variables related to flap viability. Pairwise comparisons were conducted using the Mann-Whitney U test with a Bonferroni correction. The presence of thrombi in the vessels was evaluated using the Chi-square test. In all analyses, a p-value of less than 0.05 was considered statistically significant. The data obtained were evaluated by group.

RESULTS

Flap perfusion evaluations conducted on the third day post-surgery revealed mean flap perfusion percentages of 73.5% (minimum 14 - maximum 97) in Group 1, 11.1% (minimum 6 - maximum 32) in Group 2, 65% (minimum 13 - maximum 97) in Group 3, and 64.1% (minimum 9 - maximum 99) in Group 4 (Fig. 8). Upon statistical analysis, Group 1 had the best results and Group 2 the worst ($p < 0.05$), with no significant differences between Groups 3 and 4 ($p > 0.05$).

Standard photographs were taken on the seventh day after surgery and analyzed using the Digimizer image analysis program. This analysis determined the percentages of viable and necrotic areas within each flap. The results showed that the average viable flap areas were 74.6% (ranging from 0 to 100%) in Group 1, 2.5% (ranging from 0 to 25%) in Group 2, 64.5% (ranging from 0 to 100%) in Group 3, and 64% (ranging from 0 to 100%) in Group 4 (Fig. 9). Statistical analysis revealed that Group 1 exhibited the highest viability, significantly outperforming Group 2—the group with the lowest viability ($p < 0.05$). No significant differences were noted between Groups 3 and 4 ($p > 0.05$).

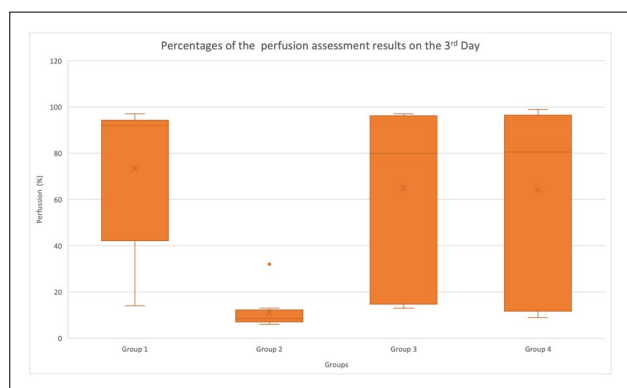


Figure 8. Graphical representation of perfusion assessment results on day 3.

On reassessment of the anastomosis sites on day 7 post-

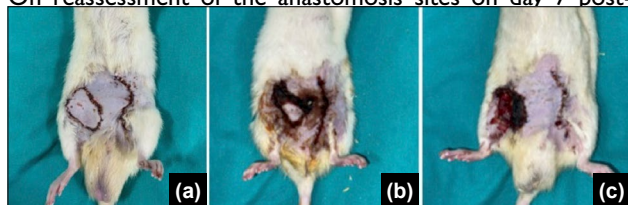


Figure 9. Examination of three rats from Group 4 on postoperative day 7. (a) View of complete flap viability. (b) View of partial flap viability. (c) Complete flap loss.

operation, thrombus formation was noted in the arteries. Specifically, thrombi were observed in two animals in Group 1, nine in Group 2, and three in each of Groups 3 and 4. Statistical analysis of the data indicated significant differences in thrombus formation among the groups ($p < 0.05$).

DISCUSSION

Advances in microsurgical techniques have significantly raised the expectations of patients, physicians, and the community for outcomes following severe injuries and amputations, surpassing those of the last century. These higher expectations have compelled surgeons to undertake reconstructions of injuries previously deemed infeasible, achieving partial success in this endeavor. Microsurgical vascular repairs, successful replantations, and favorable functional outcomes post-rehabilitation are all results of these efforts and studies.

Although high success rates have been observed in guillotine amputations and less severe injuries, such success has not been replicated to the desired extent with crush-type injuries. Often, replantation in cases of crush-type amputations is not pursued, with stump closure being the preferred treatment. For instance, between 2008 and 2012 in New York State, replantation was not attempted in 2,786 out of 3,417 finger amputation cases due to unfavorable conditions of the proximal or distal stumps.^[14] This high rate underscores the challenges in managing crush injuries within the realms of hand surgery and microsurgery.

Currently, replantation is not feasible for severely crushed limbs where there is a complete loss of structural integrity. However, if the amputation involves only partial crush injuries or if the crush site is confined to the stump rather than the amputate, options such as ectopic or heterotopic replantation become viable.^[15]

Heterotopic replantation involves transferring a completely severed limb to a similar anatomical site other than its original location. In contrast, ectopic replantation is defined as the transfer of an amputated part to a completely different anatomical location.^[16] Heterotopic replantations are more than mere preservation procedures; they enable the amputated part to function in its new location. An example of this is the replantation of the most viable amputated finger to the thumb stump in cases of multiple finger amputations. Although replantation in this study was performed at a similar anatomical site, the term “ectopic replantation” was deemed more appropriate, as this was a procedure performed for ectopic preservation.

The crush injury model selected for this study was preferred because it has been used extensively in previous research, it has minimal systemic effects, it specifically targets the relevant anatomical region—similar to the conditions experienced by patients undergoing replantation in clinical practice—and it is easy to apply. A literature review indicates that various crush injury models, produced using different methods, exist. How-

ever, some models are specifically used to evaluate systemic crush syndrome.^[17] This is an important consideration when selecting an appropriate model for study purposes.

The choice of using a free flap instead of a limb for the replantation model might initially draw criticism. The primary reason for selecting a free flap is the observed high rate of autophagy following limb replantation in rats.^[18] Additionally, animals with mobility impairments post-amputation struggle with feeding and other movement-requiring activities. Moreover, limb replantation, involving a significant amount of muscle, would impose an additional metabolic burden on the experimental animals; hence, the use of extremities was avoided. The groin flap was deemed suitable for use as a replantation model due to its ease of application and lack of additional morbidity. The methodology of our study did not assess functional evaluation, focusing instead solely on necrosis and survival rates of the replanted tissues, further justifying the non-use of limb models.

Temporary ectopic replantation has proven to be an effective and successful method in suitable cases.^[19] Previous review articles have reported success rates for ectopic replantation ranging from 75% to 100%.^[10,20] In our study, complete flap survival was observed in 5 out of 10 rats, with partial flap survival in 2, following ectopic replantation. The survival rates in this study were lower compared to those in prior clinical studies, which may be attributed to its experimental nature. In a related rat study, groin flap survival was 75%, while clinical practice shows much higher rates of free flap survival.^[21] Considering this data, the survival rate after ectopic replantation in our study can be considered acceptable.

When evaluating our results, as anticipated, the best outcomes in terms of both flap survival and thrombus formation in the vessels were observed in the guillotine-type amputation group. Conversely, the poorest results occurred in the group subjected to crush-type injury, which was repositioned without any procedural intervention. Interestingly, no statistically significant differences were observed between the third and fourth groups.

In the vein graft group, all crushed vessel segments in both the recipient vessels and the amputated limb were debrided, presumably preventing the local effects of the crush-type injury. For Group 3, debridement continued until microscopic examination of the recipient arteries confirmed that the vascular integrity was fully preserved and that the flow strength and pulsatility of the proximal flow were maintained. However, in practice, it is not always possible to debride the amputation stump sufficiently to completely remove it from the trauma zone.

In Group 4, the crushed vessel segments in the amputated limb were entirely removed, and the limb was ectopically replanted to an untraumatized recipient site. Given the similar outcomes of both groups, it can be concluded that for crush-type amputations, debridement and repair of the defect with

a vein graft may be suitable, provided that adequate debridement of the stump vessels is achieved and pulsatile flow is observed. Otherwise, we believe that temporary ectopic replantation of the amputated limb, without delay, is a more viable approach.

Furthermore, it can be argued that banking with ectopic replantation is a good alternative to vein grafting or other management strategies in cases of amputations from electrical trauma or gunshot wounds, where circulation to the proximal stump is compromised, or in contaminated injuries requiring ongoing monitoring with repeated debridements, or in situations that may necessitate aggressive future debridement for any reason.

A previous study indicated no difference in survival rates between vein graft repair and primary repair in free flaps, suggesting the reliability of vein grafts.^[22] The absence of a group in our study undergoing vein grafting for guillotine-type injuries was based on the expectation that the outcomes would be similar to those of Group 1, guided by this information.

Comparing the outcomes of Group 1 with those of Groups 3 and 4 revealed that Group 1, the control group, achieved better results than the other groups. In Group 3, all vessel segments suspected of being damaged were debrided, and in Group 4, the entire crushed portion of the amputation was debrided and the amputee was transferred to a new recipient site with an assured blood supply. However, the reason why Groups 3 and 4 did not achieve the success of Group 1 is that the crush injury impacts not only the directly damaged vessel segment but also affects a much broader area at the molecular level. Studies have shown significant discrepancies in the size of the crushed segment as assessed by surgical microscopy versus pathological examination.^[23] In this regard, our study corroborates existing research.

Total or near-total necrosis was observed at the end of the seventh day in flaps with perfusion below the threshold value during evaluation with the infrared system. Conversely, necrosis was absent in rats with perfusion values above 35%. This situation allows two inferences. First, flap loss occurs early after replantation surgery due to arterial or venous complications, as similarly reported by Lykoudis et al.^[24] Secondly, our results confirm the perfusion threshold value identified with the infrared system, previously determined to be 35% in earlier publications.

By the seventh day, complete flap loss was observed in rats with thrombus formation in the vessels, as expected. However, no thrombus was observed in any of the rats with partial flap loss. Moreover, in studies conducted by Cooley and Gravannis using the same model in mice, either complete flap survival or complete necrosis was observed in all rats, suggesting that partial necrosis would not occur in this model.^[25,26] In our study, we observed results that were contrary to previous literature. The occurrence of partial necrosis in the absence of thrombus in the vessels may be attributed to

the rats applying regional compression to the flaps, leading to partial circulatory disturbances and subsequent necrosis.

A limitation of our study is that the ectopically replanted amputates were not returned to their original sites, thus the complications that may arise during this process could not be observed. Although necrosis during the second session has not been reported in previous case studies, there is a lack of controlled studies on this topic. Similarly, our literature search did not uncover any controlled studies investigating the optimal waiting period before the second session. These two issues can be explored in future research.

Based on the results obtained from this study, controlled clinical trials are warranted to evaluate the viability and functional outcomes of ectopic replantation and replantation using vein grafts after crush injuries. Such studies could include multicenter clinical trials, meta-analyses, and reviews, which would facilitate the recommendation of a gold standard method for managing crush-type injuries.

CONCLUSION

We recommend debridement and repair with a vein graft for amputations following crush injuries, provided that the condition of the amputated limb is conducive to replantation and it is possible to debride the stump adequately without excessive shortening, to remove all debris and crushed tissue, and to ensure reliable blood flow. In cases where these conditions are not met, where repeated debridement is necessary, or where the injury is contaminated and blood flow is questionable, we recommend temporary ectopic replantation.

Ethics Committee Approval: This study was approved by the Necmettin Erbakan University Ethics Committee (Date: 05.11.2021, Decision No: 2021-046).

Peer-review: Externally peer-reviewed.

Authorship Contributions: Concept: M.S.K., B.İ., M.I., Z.B., H.A.B.N., M.D.; Design: M.S.K., B.İ., M.I., Z.B., H.A.B.N., M.D.; Supervision: M.S.K., B.İ., M.I., Z.B., H.A.B.N., M.D.; Data collection and/or processing: M.S.K., M.I., Z.B.; Analysis and/or interpretation: M.S.K., H.A.B.N.; Literature search: M.S.K., M.I.; Writing: M.S.K.; Critical review: M.S.K., B.İ., M.I., Z.B., H.A.B.N., M.D.

Conflict of Interest: None declared.

Use of AI for Writing Assistance: Not declared.

Financial Disclosure: The author declared that this study has received no financial support.

REFERENCES

- Clasper J, Ramasamy A. Traumatic amputations. *Br J Pain* 2013;7:67–73. [CrossRef]
- Pederson WC. Replantation. *Plast Reconstr Surg* 2001;107:823–41.
- An PC, Kuo YR, Lin TS, Yeh MC, Jeng SF. Heterotopic replantation in mutilating hand injury. *Ann Plast Surg* 2003;50:113–9. [CrossRef]
- Del Pinal F, Urrutia E, Klich M. Severe crush injury to the forearm and hand: the role of microsurgery. *Clin Plast Surg* 2017;44:233–5. [CrossRef]
- Cavadas PC, Landin L, Thione A. Secondary ectopic transfer for replantation salvage after severe wound infection. *Microsurg* 2011;31:288–92.
- Williams ZF, Boole LM, Adams A, Clancy TV, Hope WW. Early versus delayed amputation in the setting of severe lower extremity trauma. *Am Surg* 2015;81:564–8. [CrossRef]
- Wei FC, Colony LH. Microsurgical reconstruction of opposable digits in mutilating hand injuries. *Clin Plast Surg* 1989;16:491–504. [CrossRef]
- Jones JW, Gruber SA, Barker JH, Breidenbach WC. Successful hand transplantation. One-year follow-up. Louisville Hand Transplant Team. *N Engl J Me.* 2000;343:468–73. [CrossRef]
- Godina M, Bajec J, Baraga A. Salvage of the mutilated upper extremity with temporary ectopic implantation of the undamaged part. *Plast Reconstr Surg* 1986;78:295–9. [CrossRef]
- Tu Y, Lineaweaver WC, Culnan DM, Bitz GH, Jones KJ, Zhang F. Temporary ectopic implantation for salvaging amputated parts: A systematic review. *J Trauma Acute Care Surg* 2018;84:985–93. [CrossRef]
- Lykoudis EG, Panayotou PN, Stamatopoulos CN, Frangia KB, Papalois AE, Ioannovich JD. Microvascular repair following a modified crush-avulsion injury in a rat model: effect of recombinant human tissue-type plasminogen activator on the patency rate. *Microsurgery* 2000;20:52–8.
- Mücke T, Fichter AM, Schmidt LH, Mitchell DA, Wolff KD, Ritschl LM. Indocyanine green videoangiography-assisted prediction of flap necrosis in the rat epigastric flap using the flow* 800 tool. *Microsurgery* 2017;37:235–42. [CrossRef]
- Newman MI, Jack MC, Samson MC. SPY-Q analysis toolkit values potentially predict mastectomy flap necrosis. *Ann Plast Surg* 2013;70:595–8. [CrossRef]
- Brown M, Lu Y, Chung KC, Mahmoudi E. Annual hospital volume and success of digital replantation. *Plast Reconstr Surg* 2017;139:672–80.
- Chernofsky MA, Sauer PF. Temporary ectopic implantation. *J Hand Surg Am* 1990;15:910–4. [CrossRef]
- Trapero A, Thione A, Alonso Carpio M, Pérez-García A. Heterotopic versus ectopic replantation: what's the difference? *Plast Reconstr Surg* 2021;147:180–1e. [CrossRef]
- Akimau P, Yoshiya K, Hosotsubo H, Takakuwa T, Tanaka H, Sugimoto H. New experimental model of crush injury of the hindlimbs in rats. *J Trauma* 2005;58:51–8. [CrossRef]
- Wang Z, He B, Duan Y, Shen Y, Zhu L, Zhu X, et al. Cryopreservation and replantation of amputated rat hind limbs. *Eur J Med Res* 2014;19:28.
- Higgins JP. Ectopic banking of amputated parts: a clinical review. *J Hand Surg Am* 2011;36:1868–76. [CrossRef]
- Nazerani S, Motamedi MH. Ectopic single-finger transplantation, a novel technique for nonreplantable digits: assessment of 24 cases--presenting the "piggyback" method. *Tech Hand Up Extrem Surg* 2009;13:65–74.
- Ruby LK, Greene M, Risitano G, Torrejon R, Belsky MR. Experience with epigastric free flap transfer in the rat: technique and results. *Microsurgery* 1984;5:102–4. [CrossRef]
- Zhang F, Oliva A, Kao SD, Newlin L, Buncke HJ. Microvascular vein grafts in the rat cutaneous free-flap model. *J Reconstr Microsurg* 1994;10:229–33. [CrossRef]
- Ozkan O, Ozgentaş HE, Safak T, Dogan O. Unique superiority of microsurgical repair technique with its functional and aesthetic outcomes in ring avulsion injuries. *J Plast Reconstr Aesthet Surg* 2006;59:451–9.
- Lykoudis EG, Contodimos GB, Tsoutsos DA, Frangia KB, Papalois AE, Stamatopoulos CN, et al. Microsurgical repair after crush-avulsion injury of the femoral vein in rats: prevention of microvascular thrombosis with recombinant human tissue-type plasminogen activator (rt-PA). *Microsurgery* 2001;21:357–61. [CrossRef]
- Cooley BC, Groner JP, Hoer SR, Dollinger BM, Hanel DP. Experimental study of the influence of arterial trauma on dependent distal tissue survival. *Microsurgery* 1991;12:86–8. [CrossRef]
- Gravvanis AI, Tsoutsos DA, Lykoudis EG, Iconomou TG, Tzivaridou DV, Papalois AE, et al. Microvascular repair following crush-avulsion type injury with vein grafts: effect of direct inhibitors of thrombin on patency rate. *Microsurgery* 2003;23:402–7; discussion 408–9. [CrossRef]

DENEYSEL ÇALIŞMA - ÖZ

Şıçanlarda ezilme tipi travmatik amputasyonların yönetiminde ektopik replantasyonun diğer yöntemlere üstünlüğü var mı? Deneysel bir çalışma

Münür Selçuk Kendir,¹ Bilsev İnce,² Majid İsmayılzade,³ Zikrullah Baycar,⁴ Hayri Ahmet Burak Nurşen,⁵ Mehmet Dadacı⁵

¹Ankara Dr. Abdurrahman Yurtaslan Onkoloji Eğitim ve Araştırma Hastanesi, Plastik, Rekonstrüktif ve Estetik Cerrahi Kliniği, Ankara, Türkiye

²Serbest Hekim, İzmir, Türkiye

³İstinye Üniversitesi Tıp Fakültesi, Plastik, Rekonstrüktif ve Estetik Cerrahi Anabilim Dalı, İstanbul, Türkiye

⁴Konya Şehir Hastanesi, Plastik, Rekonstrüktif ve Estetik Cerrahi Kliniği, Konya, Türkiye

⁵Necmettin Erbakan Üniversitesi Tıp Fakültesi, Plastik, Rekonstrüktif ve Estetik Cerrahi Anabilim Dalı, Konya, Türkiye

AMAÇ: Bu çalışmanın amacı, deneysel bir kontrollü çalışma ile, ezilme tipi amputasyon modelinde ektopik replantasyonu diğer replantasyon teknikleriyle karşılaştırmak ve replantasyon tekniğine bağlı olarak ampute canlılığında meydana gelen değişiklikleri değerlendirmektir.

GEREÇ VE YÖNTEM: 40 adet erkek Wistar Albino şıçanı 4 gruba ayrıldı. Amputasyon modeli olarak kasık flepleri kullanıldı. Grup 1'e giyotin tarzı amputasyon ve ortotopik replantasyon, Grup 2'ye ezilme tipi amputasyon ve ortotopik replantasyon, Grup 3'e ezilme tipi amputasyon ve ven grefti ile ortotopik replantasyon, Grup 4'e ezilme tipi amputasyon ve ektopik replantasyon uygulandı. Flep canlılığı ve perfüzyon oranları 3. günde kızılötesi perfüzyon değerlendirme sistemi ile değerlendirildi. Canlı alanın toplam flep alanına oranı ve pedikül damarlarda trombüs oluşumu 7. günde değerlendirildi.

BULGULAR: Replantasyon sonrası üçüncü gün yapılan kızılötesi değerlendirmeye göre flep perfüzyon yüzdeleri Grup 1'de %73.5, Grup 2'de %11.1, Grup 3'te %65, Grup 4'te %64.1 olarak belirlendi. İstatistiksel analizde Grup 1 en iyi sonucu veren grup oldu. Grup 2 en kötü sonuçları alırken, Grup 3 ve 4 arasında fark yoktu. Yedinci günde canlılığını sürdüren flep alanları Grup 1'de ortalama %74.6, Grup 2'de ortalama %2.5, Grup 3'te ortalama %64.5, Grup 4'te ortalama %64 olarak tespit edildi. İstatistiksel değerlendirmede en iyi sonucu Grup 1, en kötü sonucu ise Grup 2 alırken, Grup 3 ile 4 arasında fark yoktu. 7. günde Grup 1'de 2, Grup 2'de 9, Grup 3 ve 4'te 3'er hayvanın damarlarında trombüs oluşumu tespit edildi. Gruplar arasında istatistiksel olarak anlamlı fark vardı.

SONUÇ: Ektopik replantasyon ve ven grefti ile replantasyonun sonuçlarının birbirine üstünlüğü yoktur. Ezilme tipi replantasyonlarda tercih edilecek yöntem hastanın ve amputatın durumuna göre değişiklik gösterebilir. Ezilme tipi amputasyonlarda, hastanın genel durumu replantasyon için uygunsa ve ampüte kısmı çok fazla kısaltmadan ezilmiş segmentleri debride etmek mümkünse ven grefti ile onarımı öneriyoruz. Bu koşullar sağlanamıyorsa amputatın kurtarılması için geçici ektopik replantasyon öneriyoruz.

Anahtar sözcükler: Ezilme tipi yaralanma; ektopik replantasyon; mikrocerrahi; replantasyon; vasküler anastomoz.

Ulus Travma Acil Cerrahi Derg 2024;30(6):382-389 DOI: 10.14744/tjtes.2024.39470