

Trans-syndesmotic fixation in supination external rotation type 4 injuries: Are intraoperative tests reliable?

✉ Gürkan Çalışkan, ✉ Yunus Elmas, ✉ Orhun Çelik

University of Health Sciences Istanbul Kanuni Sultan Suleyman Training and Research Hospital, İstanbul-Türkiye

ABSTRACT

BACKGROUND: Ankle fractures occur due to a rotational mechanism. According to the Lauge-Hansen classification, supination-external rotation (SER) injuries are the most common type. Following osseous fixation, the evaluation and treatment of syndesmotic injuries in these injuries are controversial. This study aimed to evaluate the clinical, functional, and radiological results of trans-syndesmotic fixation using intraoperative tests in SER type 4 ankle injuries.

METHODS: Ankle syndesmosis was intraoperatively evaluated using cotton/hook and manual external rotation stress tests in 64 patients with SER type 4 fracture dislocation injuries. These patients were divided into two groups: those treated with and without trans-syndesmotic fixation in addition to open reduction and internal fixation of the fractures. Ankle range of motion (ROM), American Orthopedic Foot and Ankle Society (AOFAS) Ankle-Hindfoot Score, and Olerud-Molander Ankle Score (OMAS), tibiofibular overlap, tibiofibular clear space, and joint arthritis based on the Kellgren-Lawrence (K-L) scale were evaluated.

RESULTS: Median values of OMAS ($Z=-3.92$, $p<0.001$), AOFAS ($Z=-4.31$, $p<0.001$), and ROM ($Z=-2.95$, $p=0.003$) were higher in Group I. There were no differences between the groups regarding tibiofibular overlap median values ($Z=-0.59$, $p=0.0554$), tibiofibular clear space ($Z=-1.13$, $p=0.258$), and Kellgren-Lawrence arthritis scale. Lack of posterior malleolus fixation was found to increase the risk of arthritis by 18.197 times, despite having trans-syndesmotic fixation, which was statistically significant (Confidence Interval, CI: 2.482-133.417, $p=0.004$) (Table 4).

CONCLUSION: Median values of OMAS, AOFAS, and ROM in patients without trans-syndesmotic fixation were lower. These results indicate that intraoperative tests may not provide entirely accurate results in SER type 4 injuries. Failure to detect a syndesmotic injury timely can result in instability. Therefore, we think that routine trans-syndesmotic fixation, as well as posterior malleolus fixation in SER type 4 ankle injuries, may improve outcomes.

Keywords: intraoperative test; supination external rotation; trans-syndesmotic fixation.

INTRODUCTION

The diagnosis and treatment of syndesmotic injuries following the initial fixation of the fibula in supination-external rotation type 4 ankle injuries is still controversial. Supination-external rotation (SER) injuries are the most common type of ankle injury.^[1-3] SER type 4 ankle injuries can be accompanied by fractures of the lateral, medial, and posterior malleoli, as well as tibiotalar dislocation and syndesmotic injury. Failing to diag-

nose a syndesmotic injury leads to long-term ankle instability and joint arthritis. In these injuries, pre-operative direct radiographs including anteroposterior (AP), lateral, and mortise views are followed by computed tomography (CT) if necessary.^[4-7] Intraoperative tests are also commonly used in the assessment of ankle syndesmotic injuries. Cotton/hook and manual external rotation tests are performed after the fixation of the fibula. However, intraoperative tests are subjective.^[8-12] In this study, the clinical, functional, and radiological

Cite this article as: Çalışkan G, Elmas Y, Çelik O. Trans-syndesmotic fixation in supination external rotation type 4 injuries: Are intraoperative tests reliable? *Ulus Travma Acil Cerrahi Derg* 2024;30:754-760.

Address for correspondence: Orhun Çelik

University of Health Sciences Istanbul Kanuni Sultan Suleyman Training and Research Hospital, İstanbul, Türkiye

E-mail: celikorhun@gmail.com

Ulus Travma Acil Cerrahi Derg 2024;30(10):754-760 DOI: 10.14744/tjtes.2024.37225

Submitted: 27.07.2024 Revised: 11.08.2024 Accepted: 16.08.2024 Published: 07.10.2024

OPEN ACCESS This is an open access article under the CC BY-NC license (<http://creativecommons.org/licenses/by-nc/4.0/>).



results of operatively treated SER type 4 fracture dislocations were evaluated. It was hypothesized that intraoperative diagnostic tests in SER type 4 fracture dislocations are not reliable and that routine trans-syndesmotom fixation would provide better clinical, functional, and radiological outcomes.

MATERIALS AND METHODS

Permission from the local clinical research ethics committee was obtained (ethics committee number 2020.08.174 and topic number KAEK/2020.08.174). Patient-related information from the hospital database was collected anonymously. This study was conducted in accordance with the Helsinki Declaration.

In this retrospective study, operatively treated patients admitted to our orthopedic surgery and traumatology department (level 3 trauma center) with SER type 4 fracture dislocations were evaluated. A total of 1,637 patients admitted to our orthopedic surgery and traumatology department between January 2016 and January 2022 with ankle fractures were screened for this study. The radiological tests of these patients were assessed and classified according to the Lauge-Hansen classification. Out of these, 296 patients were identified to have sustained SER type 4 injuries. Among these patients, only 83 had accompanying dislocations. Only patients older than 18 years of age without concomitant injuries were

included in the study. Patients who were operated on within one week after sustaining the injury and with at least one year of follow-up time were included in the study. Patients with open fractures, polytrauma, additional injuries on the ipsilateral extremity, external fixator application, application of supra-syndesmotom fixation, compartment syndrome, additional intervention due to soft tissue complications, isolated deltoid ligament injuries, and those who did not come for follow-up were excluded from the study. Finally, 64 operatively treated patients who sustained SER type 4 ankle fracture dislocations and fulfilled the eligibility criteria were included in the study. The included patients were divided into two groups. Group 1 consisted of 37 patients who received trans-syndesmotom fixation (Fig. 1), and Group 2 consisted of 27 patients who did not receive trans-syndesmotom fixation (Fig. 2).

Data Collection and Evaluation Criteria

Patients' demographic, functional, and radiological data were evaluated. Demographic evaluation included age, gender, body mass index (BMI), and time to surgery. Clinical evaluation consisted of ankle range of motion (ROM), American Orthopaedic Foot and Ankle Society (AOFAS) scoring scale, and the Olerud-Molander Ankle Score (OMAS). Radiological evaluation involved tibiofibular overlap, tibiofibular clear space, and degree of ankle arthritis based on the Kellgren-Lawrence scale.^[13] The medial clear space was considered irrelevant and was not assessed.

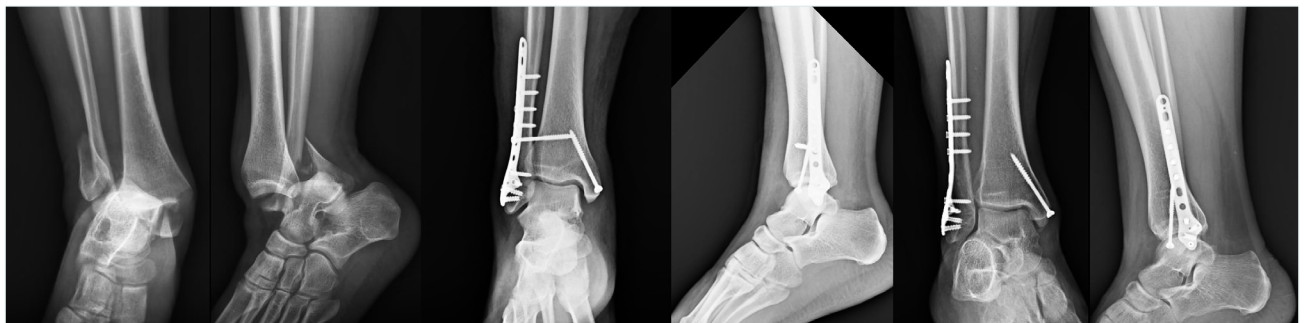


Figure 1. Supination-external rotation (SER) type 4 injury treated with trans-syndesmotom fixation. Views include pre-operative, early post-operative, and late post-operative.

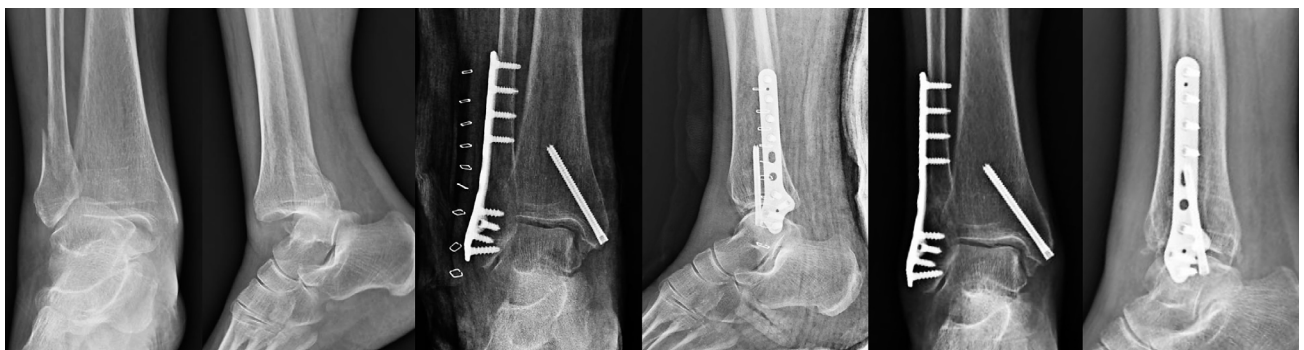

Figure 2. SER type 4 injury treated without trans-syndesmotom fixation. Views include pre-operative, early post-operative, and late post-operative.

Surgical Procedure

Surgeries were performed under general anesthesia or spinal block according to the standard protocol. Antibiotic prophylaxis (cefazolin sodium) was administered routinely during the first 24 hours after the surgery. The surgical technique was decided by the attending surgeon. Some surgeons did not prefer trans-syndesmotic fixation if intraoperative tests were negative, while some preferred trans-syndesmotic fixation routinely despite a negative test. Surgical steps began with open reduction and internal fixation where a screw or a buttress plate was applied to posterior malleolus fractures if the fragment size was more than 10% of the articular surface or if there was more than 2 mm articular step-off. Then, osseous fixation of the fibula was performed with an anatomical plate. Finally, the medial malleolus was fixed using a screw or tension-band wiring technique, followed by intraoperative stress tests to evaluate syndesmotic stability and to determine the need for temporary syndesmotic fixation. These intraoperative stress tests included a manual external rotation stress test and a cotton/hook test. The former is done by abducting and externally rotating the dorsiflexed foot. The latter is done by placing a hook around the fibula and pulling it while applying countertraction on the tibia. Fixation was performed if one of these two intraoperative tests was positive. A positive test was defined if tibiofibular diastasis occurred. Fixation of the posterior malleolus did not preclude intraoperative tests. A 3.5 millimeter screw (partially or fully threaded, cannulated screw) was applied proximally and parallel to the

joint line in a posterolateral to anteromedial direction, penetrating three cortices. A short leg splint was applied initially. Early active ROM exercises were started after the removal of the splint, and weight-bearing was avoided for six weeks. Trans-syndesmotic screws were not extracted earlier than eight weeks.

Statistical Analysis

Demographic and clinical traits of the cases included in the study were examined with statistical analyses (quantity, percentage, average, standard deviation, etc.). The Mann-Whitney U test was used to compare age, BMI, time to surgery, follow-up period, fractured posterior malleolus fragment size, functionality calculations, tibiofibular overlap, and tibiofibular clear space between the two groups. Chi-square analysis was applied to compare gender, injury side, the existence of posterior fixation, and the Kellgren-Lawrence scale between the two groups. The level of significance was set to $p < 0.05$ for all analyses. IBM SPSS 22.0 (IBM, Chicago, IL, USA) was utilized for statistical evaluations.

RESULTS

Group 1 had a median age of 38, whereas Group 2 had a median age of 42. In Group 1, 48.6% were male, and in Group 2, 51.9% were male patients. There was no statistically significant difference between the groups regarding the median values of age ($Z = -1.19$, $p = 0.234$), BMI ($Z = -1.35$, $p = 0.178$), time to surgery ($Z = -0.27$, $p = 0.786$), follow-up period ($Z =$

Table 1. Comparison of demographic and clinical traits of patients evaluated in the study

	Trans-Syndesmotic Fixation Applied		Trans-Syndesmotic Fixation Not Applied		Analysis	p
	Median/n	25-75%	Median/n	25-75%		
Age	38.00	29.00-48.00	42.00	35.00-55.00	$Z = -1.19$	0.234
Gender						
Male	18	48.6	14	51.9	$\chi^2 = 0.06$	0.800
Female	19	51.4	13	48.1		
Body Mass Index (BMI)	28.08	26.84-29.97	28.98	27.78-30.83	$Z = -1.35$	0.178
Time to Surgery (days)	2.00	1.00-4.00	2.00	1.00-4.00	$Z = -0.27$	0.786
Follow-up Period (months)	38.0	29.0-47.0	44.0	30.0-54.0	$Z = -1.03$	0.304
Fractured Posterior Malleolus	10.00	0.00-15.00	5.00	0.00-15.00	$Z = -0.27$	0.789
Fragment Size						
Injured Side						
Right	17	45.9	15	55.6	$\chi^2 = 0.58$	0.448
Left	20	54.1	12	44.4		
Presence of Posterior Fixation						
Yes	33	89.2	21	77.8	$\chi^2 = 1.54$	0.214
No	4	10.8	6	22.2		

Z: Mann-Whitney U test; χ^2 : Chi-Square Test.

Table 2. Comparison of radiological calculations between the two groups

	Trans-Syndesmotic Fixation Applied		Trans-Syndesmotic Fixation Not Applied		Analysis	p
	Median/n	25-75%	Median/n	25-75%		
Age	38.00	29.00-48.00	42.00	35.00-55.00	Z=-1.19	0.234
Gender						
Male	18	48.6	14	51.9	X ² =0.06	0.800
Female	19	51.4	13	48.1		
Body Mass Index (BMI)	28.08	26.84-29.97	28.98	27.78-30.83	Z=-1.35	0.178
Time to Surgery (days)	2.00	1.00-4.00	2.00	1.00-4.00	Z=-0.27	0.786
Follow-up Period (months)	38.0	29.0-47.0	44.0	30.0-54.0	Z=-1.03	0.304
Fractured Posterior Malleolus	10.00	0.00-15.00	5.00	0.00-15.00	Z=-0.27	0.789
Fragment Size						
Injured Side						
Right	17	45.9	15	55.6	X ² =0.58	0.448
Left	20	54.1	12	44.4		
Presence of Posterior Fixation						
Yes	33	89.2	21	77.8	X ² =1.54	0.214
No	4	10.8	6	22.2		

Z: Mann-Whitney U test; X²: Chi-Square Test.

1.03, p=0.304), and fractured posterior malleolus fragment size (Z=-0.27, p=0.789). No statistically significant difference was found between the groups regarding gender (X²=0.06, p=0.800), injured side (X²=0.58, p=0.448), and presence of posterior fixation (X²=1.54, p=0.214) (Table 1).

There was no statistically significant difference regarding the median values of post-operative tibiofibular overlap (Z=-0.59, p=0.0554) and post-operative tibiofibular clear space (Z=-1.13, p=0.258) between the two groups. There was no statistically significant difference regarding the Kellgren-Lawrence scale between the two groups (Table 2).

Group 1 demonstrated significantly higher results compared to Group 2 regarding median values of the OMAS (Z=-3.92, p<0.001), AOFAS (Z=-4.31, p<0.001) scoring scale, and ROM

(Z=-2.95, p=0.003) (Table 3).

Furthermore, patients with mild, moderate, and severe arthritis were grouped together to categorize and compare 46 patients with arthritis and 18 patients without any signs of arthritis. According to multivariate logistic regression analysis, parameters such as age (p=0.492), gender (p=0.492), BMI (p=0.319), injured side (p=0.080), presence of a posterior malleolus fracture (p=0.216), and presence of trans-syndesmotic fixation (p=0.131) were found to have no statistically significant effect on increasing the risk of arthritis. However, the lack of posterior malleolus fixation was found to increase the risk of arthritis by 18.197 times despite having a trans-syndesmotic fixation, which was statistically significant (confidence interval (CI): 2.482-133.417, p=0.004) (Table 4).

Table 3. Comparison of functional evaluations between the two groups

	Trans-Syndesmotic Fixation Applied		Trans-Syndesmotic Fixation Not Applied		Analysis	p
	Med.	25-75%	Med.	25-75%		
OMAS	80.00	75.00-85.00	75.00	60.00-75.00	Z=-3.92	<0.001
AOFAS	76.00	69.00-79.00	68.00	53.00-72.00	Z=-4.31	<0.001
ROM	60.00	50.00-65.00	55.00	20.00-60.00	Z=-2.95	0.003

Med.: Median; Z: Mann-Whitney U test; OMAS: Olerud-Molander Ankle Score; AOFAS: American Orthopaedic Foot and Ankle Society; ROM: Range of Motion.

Table 4. Variables associated with increased risk of arthritis

	B	SE	Wald	df	p	Odds Ratio	95% CI	
							LL	UL
Age	-0.019	0.027	0.473	1	0.492	0.981	0.930	1.035
Gender (Male)	-0.286	0.751	0.145	1	0.703	0.751	0.172	3.274
Body Mass Index (BMI)	0.143	0.143	0.994	1	0.319	1.154	0.871	1.528
Injured Side (Right)	-1.238	0.708	3.059	1	0.080	0.290	0.072	1.161
Presence of Posterior Malleolus Fracture (None)	0.987	0.797	1.533	1	0.216	2.684	0.562	12.809
Presence of Posterior Malleolus Fixation (None)	2.901	1.016	8.147	1	0.004	18.197	2.482	133.417
Group (Trans-Syndesmotic Fixation Applied)	-1.151	0.762	2.280	1	0.131	0.316	0.071	1.409

n=64; $\chi^2=17.43$; p=0.015; Nagelkerke R²=0.34. Result of multivariate logistic regression analysis. CI: Confidence Interval; LL: Lower Limit; UL: Upper Limit; SE: Standard Error.

DISCUSSION

The outcomes of this study are as follows: First, the overall values of the OMAS, AOFAS scoring scale, and ROM were better in Group 1. Second, post-operative tibiofibular clear space and tibiofibular overlap values were similar between the two groups. Third, the level of arthritis according to the Kellgren-Lawrence scale was found to be similar between the two groups. Fourth, the risk of arthritis increased approximately 18 times in patients who did not receive a posterior malleolus fixation due to small size, despite having a trans-syndesmotic fixation performed.

Evaluation of clinical and radiological results of SER type 4 fracture dislocations of the ankle with a mean follow-up time of 4.7 years was performed. SER injuries of the ankle are associated with syndesmotic instability. Evaluation of ankle functions with the AOFAS and OMAS scoring systems, which were used in this study, has been found to be effective.^[14,15] In accordance with the current literature, this study demonstrated that trans-syndesmotic fixation is associated with higher OMAS, AOFAS, and ROM values.

In their prospective study with 38 patients suffering from SER injuries, Jenkinson et al.^[8] concluded that preoperative radiographic examinations and biomechanical criteria are insufficient to detect syndesmotic injury, and suggested the use of intraoperative tests. However, a cadaver bone model study by Hallbauer et al.^[11] emphasizes the high variability of widely used intraoperative tests. They reported that the cotton test, frequently used during operations to identify syndesmotic injury in ankle fractures, is not reliable for intraoperative diagnosis. Additionally, Pakarinen et al.^[12] demonstrated that the sensitivity of intraoperative tests is inadequate in detecting

syndesmotic joint stability. They further claimed that trans-syndesmotic fixation has no functional effect and concluded that syndesmosis injury is rather rare in SER injuries of the ankle. In their prospective study including 24 patients, Lehtola et al.^[6] reported that trans-syndesmotic fixation made no functional difference in SER type 4 injuries of the ankle. Choi et al.^[17] investigated the effect of deltoid ligament repair in SER type 4 injuries but also did not find a significant difference between the repaired group and the non-repaired group. In contrast, Gill et al.^[10] suggested the application of trans-syndesmotic fixation in SER type 4 injuries due to the insufficiency of intraoperative tests in detecting syndesmosis injury. Thus, we assumed that the poor radiological and functional outcomes associated with Group 2 in our study are correlated to the low sensitivity of pre-operative and intraoperative tests.

Regarding the radiological parameters (tibiofibular clear space and tibiofibular overlap), our results were in accordance with the current literature. In their prospective randomized trial with 140 SER type 4 ankle injury patients, Kortekangas et al.^[18] reported no significant radiological difference between the patient group that received trans-syndesmotic fixation and the group that did not. In another cadaver study, Stoffel et al.^[19] claimed that intraoperative parameters of medial clear space, tibiofibular clear space, and tibiofibular overlap were fairly sensitive, but the medial clear space could be affected by isolated injuries to the anterior inferior tibiofibular and deltoid ligaments. In the same manner, Jiang et al.^[20] indicated that widening of the tibiofibular clear space is much more directive in assessing ankle syndesmosis. On the contrary, Beumer et al.^[21] concluded that none of the parameters, including tibiofibular clear space, tibiofibular overlap, and me-

dial clear space, is optimal in diagnosing a syndesmotic injury. Furthermore, Pakarinen et al.^[12] demonstrated no significant difference in radiological parameters between patients who were and were not treated with trans-syndesmotic fixation. Moreover, in a cadaveric study, Fisher et al.^[22] suggested the utilization of dynamic ultrasound to determine syndesmosis injuries. These results were thought to be related to the insufficient sensitivity of radiographic calculations. In our study, no significant correlation was identified between syndesmotic injury and post-operative radiological parameters. Therefore, it may be concluded that conventional radiographic diagnostic tools are not sensitive enough to reveal post-operative syndesmotic instability.

The relationship between degenerative osteoarthritis and SER type 4 ankle injuries is highly controversial. In this regard, Kortekangas et al.^[23] also reported no significant difference between patients who received trans-syndesmotic fixation and those who did not. Furthermore, Blom et al.^[24] claimed that accompanying posterior malleolus fracture significantly worsened functional outcomes, and they emphasized the importance of the fracture pattern rather than the fragment size. Also, in a study by Lübbecke et al.,^[25] they evaluated follow-up data varying between 12 and 22 years and reported that associated dislocation is a significant factor that increases the risk of osteoarthritis. In the same manner, Dahmen et al.^[26] mentioned that chondral injury occurring during the initial trauma may be a predisposing factor in subsequent osteoarthritis. In our study, although no significant difference was identified between Group 1 and Group 2 regarding the degree of ankle osteoarthritis, functional results were better in Group 1. In a magnetic resonance imaging study, Gardner et al.^[27] identified that the posterior inferior tibiofibular ligament was intact in SER injuries with a posterior malleolar fragment. In a study including 31 patients, Miller et al.^[28] concluded that posterior malleolus fixation was equivalent to syndesmotic fixation with an oppositional screw. However, according to our results from multivariate logistic regression analysis, we identified an increase in ankle arthritis risk by approximately 18 times in patients with posterior malleolus fragments who received trans-syndesmotic fixation but no posterior malleolus fixation. To our knowledge, our study is the first one to emphasize that fixation of small-sized posterior malleolus, regardless of a syndesmotic screw fixation, has a positive impact on ankle osteoarthritis.

Limitations: In this study comparing the patients who received trans-syndesmotic fixation and those who did not, researcher bias was not checked during the evaluation process, which could be a limitation. An independent observer to participate in the functional evaluation of patients who received trans-syndesmotic fixation might be beneficial to provide unbiased results. The quality of intraoperative tests can also indicate a limitation due to its performer-dependent nature. Moreover, lower functional scores related to the group without syndesmotic fixation might be influenced by other factors. For

instance, the degree of initial chondral injury on subsequent joint arthritis could not be portrayed. Multi-center prospective studies with larger patient groups should be performed, and longer follow-up data must be obtained to achieve more conclusive results.

CONCLUSION

Median values of the OMAS, the AOFAS scoring scale, and ROM in patients without trans-syndesmotic fixation were lower. These results indicate that intraoperative tests may not provide completely correct results in SER type 4 injuries. Also, patients without posterior malleolus fixation demonstrated higher degrees of osteoarthritis. Therefore, we think that routine trans-syndesmotic fixation as well as posterior malleolus fixation in SER type 4 ankle injuries may improve outcomes.

Ethics Committee Approval: This study was approved by the Kanuni Sultan Suleyman Training and Research Hospital Ethics Committee (Date: 03.09.2020, Decision No: KAEK/2020.08/174).

Peer-review: Externally peer-reviewed.

Authorship Contributions: Concept: G.Ç., Y.E.; Design: G.Ç., O.Ç.; Supervision: G.Ç., Y.E.; Materials: Y.E., O.Ç.; Data collection and/or processing: Y.E., O.Ç.; Analysis and/or interpretation: O.Ç., G.Ç.; Literature search: O.Ç., G.Ç.; Writing: Y.E., O.Ç.; Critical reviews: G.Ç., Y.E.

Conflict of Interest: None declared.

Financial Disclosure: The author declared that this study has received no financial support.

REFERENCES

1. Cao MM, Zhang YW, Hu SY, Rui YF. A systematic review of ankle fracture-dislocations: Recent update and future prospects. *Front Surg* 2022;9:965814. [CrossRef]
2. Regan DK, Gould S, Manoli A III, Egol KA. Outcomes over a decade after surgery for unstable ankle fracture: functional recovery seen 1 year postoperatively does not decay with time. *J Orthop Trauma* 2016;30:e236–41. [CrossRef]
3. Miller SD. Controversies in ankle fracture treatment. Indications for fixation of stable Weber type B fractures and indications for syndesmosis stabilization. *Foot Ankle Clin* 2000;5:841–51. [CrossRef]
4. Yuen CP, Lui TH. Distal tibiofibular syndesmosis: anatomy, biomechanics, injury and management. *Open Orthop J* 2017;11:670–7. [CrossRef]
5. Porter DA, Jagers RR, Barnes AF, Rund AM. Optimal management of ankle syndesmosis injuries. *Open Access J Sports Med* 2014;5:173–82.
6. Choi Y, Kwon SS, Chung CY, Park MS, Lee SY, Lee KM. Preoperative radiographic and CT findings predicting syndesmotic injuries in supination-external rotation-type ankle fractures. *J Bone Joint Surg Am* 2014;96:1161–7. [CrossRef]
7. Kellett JJ, Lovell GA, Eriksen DA, Sampson MJ. Diagnostic imaging of ankle syndesmosis injuries: A general review. *J Med Imaging Radiat Oncol* 2018;62:159–68. [CrossRef]
8. Jenkinson RJ, Sanders DW, Macleod MD, Domonkos A, Lydestadt J. Intraoperative diagnosis of syndesmosis injuries in external rotation ankle fractures. *J Orthop Trauma* 2005;19:604–9. [CrossRef]
9. Tourné Y, Molinier F, Andrieu M, Porta J, Barbier G. Diagnosis and treat-

- ment of tibiofibular syndesmosis lesions. *Orthop Traumatol Surg Res* 2019;105:S275–86. [CrossRef]
10. Gill SL, Behman A, Cochrane LA, Love GJ. The use and efficacy of intra-operative stress tests in supination-external rotation IV ankle fracture fixation. *The Surgeon* 2015;13:9–14. [CrossRef]
 11. Hallbauer J, Schenk P, Herrmann L, Ullrich BW, Biedermann U, Wildemann B, et al. Objective assessment of syndesmosis stability using the hook test. *J Clin Med* 2023;12:4580. [CrossRef]
 12. Pakarinen H, Flinkkilä T, Ohtonen P, Hyvönen P, Lakovaara M, Lepolahti J, et al. Intraoperative assessment of the stability of the distal tibiofibular joint in supination-external rotation injuries of the ankle: sensitivity, specificity, and reliability of two clinical tests. *J Bone Joint Surg Am* 2011;93:2057–61. [CrossRef]
 13. Kellgren JH, Lawrence JS. Radiological assessment of osteo-arthritis. *Ann Rheum Dis* 1957;16:494–502. [CrossRef]
 14. Olerud C, Molander H. A scoring scale for symptom evaluation after ankle fracture. *Arch Orthop Trauma Surg* 1984;103:190–4. [CrossRef]
 15. Nilsson GM, Eneroth M, Ekdahl CS. The Swedish version of OMAS is a reliable and valid outcome measure for patients with ankle fractures. *BMC Musculoskelet Disord* 2013;14:109. [CrossRef]
 16. Lehtola R, Leskelä HV, Flinkkilä TE, Pakarinen HJ, Niinimäki JL, Ohtonen PP, et al. Syndesmosis fixation in supination-external rotation ankle fractures. Long-Term results of a prospective randomised study. *Foot Ankle Surg* 2022;28:229–34. [CrossRef]
 17. Choi S, Choi Y, Baek E, Jo S. Does repair of deltoid ligament contribute to restoring a mortise in SER type IV ankle fracture with syndesmosis diastasis? *Arch Orthop Trauma Surg* 2022;142:535–41. [CrossRef]
 18. Kortekangas TH, Pakarinen HJ, Savola O, Niinimäki J, Lepojärvi S, Ohtonen P, et al. Syndesmosis fixation in supination-external rotation ankle fractures: a prospective randomized study. *Foot Ankle Int* 2014;35:988–95. [CrossRef]
 19. Stoffel K, Wysocki D, Baddour E, Nicholls R, Yates P. Comparison of two intraoperative assessment methods for injuries to the ankle syndesmosis. A cadaveric study. *J Bone Joint Surg Am* 2009;91:2646–52.
 20. Jiang KN, Schulz BM, Tsui YL, Gardner TR, Greisberg JK. Comparison of radiographic stress tests for syndesmosis instability of supination-external rotation ankle fractures: a cadaveric study. *J Orthop Trauma* 2014;28:e123–7. [CrossRef]
 21. Beumer A, van Hemert WL, Niesing R, Entius CA, Ginai AZ, Mulder PG, et al. Radiographic measurement of the distal tibiofibular syndesmosis has limited use. *Clin Orthop Relat Res* 2004;(423):227–34. [CrossRef]
 22. Fisher CL, Rabbani T, Johnson K, Reeves R, Wood A. Diagnostic capability of dynamic ultrasound evaluation of supination-external rotation ankle injuries: a cadaveric study. *BMC Musculoskelet Disord* 2019;20:502. [CrossRef]
 23. Kortekangas T, Flinkkilä T, Niinimäki J, Lepojärvi S, Ohtonen P, Savola O, et al. Effect of syndesmosis injury in SER IV (Weber B)-type ankle fractures on function and incidence of osteoarthritis. *Foot Ankle Int* 2015;36:180–7. [CrossRef]
 24. Blom RP, Meijer DT, de Muinck Keizer RO, Stufkens SAS, Siersevelt IN, Schepers T, et al. Posterior malleolar fracture morphology determines outcome in rotational type ankle fractures. *Injury* 2019;50:1392–7.
 25. Lübbecke A, Salvo D, Stern R, Hoffmeyer P, Holzer N, Assal M. Risk factors for post-traumatic osteoarthritis of the ankle: an eighteen year follow-up study. *Int Orthop* 2012;36:1403–10. [CrossRef]
 26. Dahmen J, Karlsson J, Stufkens SAS, Kerkhoffs GMMJ. The ankle cartilage cascade: incremental cartilage damage in the ankle joint. *Knee Surg Sports Traumatol Arthrosc* 2021;29:3503–7. [CrossRef]
 27. Gardner MJ, Demetrakopoulos D, Briggs SM, Helfet DL, Lorich DG. The ability of the Lauge-Hansen classification to predict ligament injury and mechanism in ankle fractures: an MRI study. *J Orthop Trauma* 2006;20:267–72. [CrossRef]
 28. Miller AN, Carroll EA, Parker RJ, Helfet DL, Lorich DG. Posterior malleolar stabilization of syndesmosis injuries is equivalent to screw fixation. *Clin Orthop Relat Res* 2010;468:1129–35. [CrossRef]

ORJİNAL ÇALIŞMA - ÖZ

Supinasyon eksternal rotasyon tip 4 yaralanmalarda trans-sindezmotik fiksasyon: İntra-operatif testler güvenilir mi?

Gürkan Çalışkan, Yunus Elmas, Orhun Çelik

Sağlık Bilimleri Üniversitesi İstanbul Kanuni Sultan Süleyman Eğitim ve Araştırma Hastanesi, İstanbul-Türkiye

AMAÇ: Ayak bileği kırıklı rotasyonel mekanizma ile oluşan Lauge-Hansen sınıflamasına göre, supinasyon-eksternal rotasyon (SER) tip yaralanmalar en sık görüldür. Bu yaralanmalarda, kemik fiksasyonunun ardından sindezmotik yaralanmaların değerlendirilmesi ve tedavisi tartışmalıdır. Bu çalışmada, SER tip 4 ayak bileği yaralanmalarında intra-operatif testlerden yararlanılarak yapılan trans-sindezmotik fiksasyonun klinik, fonksiyonel ve radyolojik sonuçlarının değerlendirilmesi hedeflenmiştir.

GEREK VE YÖNTEM: Ayak bileği sindezmoz eklemi intra-operatif olarak cotton/hook testi ve el ile manuel eksternal rotasyon stres testi ile 64 SER tip 4 kırıklı çıkığı olan hastada değerlendirildi. Hastalar, trans-sindezmotik fiksasyon yapılanlar ve yapılmayanlar şeklinde iki gruba ayrıldı. Ayak bileği eklemler hareket açıklığı (EHA), Amerikan Ortopedik Ayak ve Ayak Bileği Topluluğu (AOFAS) Ayak bileği-Ardayak Skoru, Olerud-Molander Ayak Bileği Skoru (OMAS), tibiofibular örtüşme, tibiofibular açık alan ve Kellgren-Lawrence (K-L) skalası kullanılarak eklem artritisi değerlendirildi.

BULGULAR: Median OMAS ($Z=-3.92$, $p<0.001$), AOFAS ($Z=-4.31$, $p<0.001$) ve EHA ($Z=-2.95$, $p=0.003$) değerleri grup 1'de daha yüksekti. İki grup arasında median tibiofibular örtüşme değeri ($Z=-0.59$, $p=0.0554$), median tibiofibular açık alan değeri ($Z=-1.13$, $p=0.258$) ve Kellgren-Lawrence artrit skalası açısından bir fark saptanamadı. Trans-sindezmotik fiksasyon yapılmasına rağmen posterior malleoli fiksasyonu yapılmayan hastalarda artrit riskinin istatistiksel olarak anlamlı bir şekilde 18.197 kat arttığı tespit edildi. (CI: 2.482-133.417, $p=0.004$) (Tablo 4)

SONUÇ: OMAS, AOFAS ve EHA median değerleri, trans-sindezmotik fiksasyon yapılmayan hastalarda daha düşüktü. Bu sonuçlar, SER tip 4 yaralanmalarında intra-operatif testlerin kesin doğru bilgi veremeyeceğini gösteriyor olabilir. Sindezmotik yaralanmaların zamanında tespit edilemesi instabilite ile sonuçlanabilir. Bu nedenle, SER tip 4 yaralanmalarda trans-sindezmotik fiksasyon ile posterior malleoli fiksasyonun birlikte uygulanmasının sonuçları olumlu etkileyebileceğini düşünmekteyiz.

Anahtar sözcükler: İntraoperatif test; supinasyon eksternal rotasyon; trans sindezmotik fiksasyon.