

# Effect of glutamine use on the formation of intestinal neomucosa on peritoneal surface in rats

 Ahmet Akbaş, M.D.,<sup>1</sup>
 Osman Bilgin Gülcicek, M.D.,<sup>2</sup>
 Erkan Yavuz, M.D.,<sup>2</sup>
 Hakan Yigitbas, M.D.,<sup>2</sup>  
 Ali Solmaz, M.D.,<sup>2</sup>
 Yigit Ulgen, M.D.,<sup>3</sup>
 Nadir Adnan Hacım, M.D.,<sup>2</sup>
 Gulcin Ercan, M.D.,<sup>2</sup>  
 Yuksel Altinel, M.D.,<sup>2</sup>
 Aysegul Kirankaya, M.D.,<sup>4</sup>
 Atilla Çelik, M.D.<sup>2</sup>

<sup>1</sup>Department of General Surgery, Faculty of Medicine, Karadeniz Technical University, Trabzon-Türkiye

<sup>2</sup>Department of General Surgery, University of Health Sciences İstanbul Bağçılar Training and Research Hospital, İstanbul-Türkiye

<sup>3</sup>Department of Pathology, University of Health Sciences İstanbul Bağçılar Training and Research Hospital, İstanbul-Türkiye

<sup>4</sup>Department of Biochemistry, University of Health Sciences İstanbul Bağçılar Training and Research Hospital, İstanbul-Türkiye

## ABSTRACT

**BACKGROUND:** Short bowel syndrome (SBS) is a clinical condition with high mortality and morbidity, which leads to the lack of absorption of fluids or nutrients necessary for the body due to the decrease in the length of the small bowel (SB). Glutamine is an amino acid essential for the nutrition and proliferation of intestinal mucosa cells. The main aim of the present study was to investigate the effect of glutamine on intestinal neomucosa formation in rats which developed SBS.

**METHODS:** Sixteen Wistar Hannover rats were randomly divided into two groups of eight rats. Saline was applied to the rats in Group 1 (control) following the enteroperitoneal anastomosis between mucosal surface of the ileum and the parietal peritoneum surface (adherent to abdominal wall) while glutamine was applied to the rats in Group 2 following the same anastomosis. Fourteen days later, the rats were euthanatized and blood samples were taken. Simultaneously, en bloc resection of the anastomosis part was performed and histopathological examination was carried out to observe neomucosa formation. The effects of glutamine on anastomosis were determined by microscopic and biochemical evaluations.

**RESULTS:** Biochemical analyses were performed by measuring serum oxidant (malondialdehyde [MDA] and 8-hydroxy-2'-deoxyguanosine [8-OHdG]) and antioxidant (superoxide dismutase [SOD] and glutathione peroxidase [GPx]) parameters. Based on the biochemical evaluation results of the antioxidant values of the control and glutamine groups, it was found that while the serum antioxidant level (SOD and GPx activity) was significantly higher ( $p < 0.05$ ) in the glutamine-administered rats compared to the control group, the oxidative damage (MDA and 8-OHdG) was lower ( $p < 0.05$ ). In terms of the histological evaluations made for the neomucosa formation, the number of neomucosa formation was higher in the glutamine group, but the difference was not significant ( $p = 0.315$ ).

**CONCLUSION:** The use of glutamine in patients with SBS may increase surface absorption by increasing neomucosa formation. However, additional studies of large statistical power are needed.

**Keywords:** Glutamine; neomucosa; peritoneal surface; short bowel syndrome.

## INTRODUCTION

Short bowel syndrome (SBS) refers to the clinical condition that develops due to the lack of absorption of fluids or nutrients necessary for the body as a result of decrease in the length of the small bowel (SB).<sup>[1]</sup> While it mostly develops

after surgical procedures involving massive bowel resection in adulthood, it could be observed during childhood for congenital reasons or in situations where massive bowel resection was performed early in life.<sup>[2]</sup> While the risk of occurrence increases when more than 50% of the SB length is resected, the cases in which more than 70% of the SB length is resected or

Cite this article as: Akbaş A, Gülcicek OB, Yavuz E, Yigitbas H, Solmaz A, Ulgen Y, et al. Effect of glutamine use on the formation of intestinal neomucosa on peritoneal surface in rats. *Ulus Travma Acil Cerrahi Derg* 2022;28:1541-1548.

Address for correspondence: Ahmet Akbaş, M.D.

Karadeniz Teknik Üniversitesi Tıp Fakültesi, Genel Cerrahi Bölümü, Trabzon, Türkiye

Tel: +90 462 - 377 54 04 E-mail: draakbas@hotmail.com

*Ulus Travma Acil Cerrahi Derg* 2022;28(11):1541-1548 DOI: 10.14744/tjtes.2021.36903 Submitted: 28.07.2021 Revised: 15.09.2021 Accepted: 07.11.2021  
OPEN ACCESS This is an open access article under the CC BY-NC license (<http://creativecommons.org/licenses/by-nc/4.0/>).



SB length is <100 cm after resection could have clinical outcomes of SBS such as diarrhea, steatorrhea, malnutrition, and dehydration secondary to digestion and absorption disorders.<sup>[3]</sup> Patients who develop SBS require long-term parenteral nutrition, which significantly increases the mortality and morbidity of the patients.<sup>[3-5]</sup> However, surgical approaches such as reconstruction of remaining bowel and intestinal transplantation can improve the intestinal digestion and absorption.<sup>[6,7]</sup> The reconstructive procedures aim to slow down the intestinal transition and to allow new intestinal mucosa development. All these procedures are still experimental, involving high morbidity and mortality rates.

Glutamine is involved in proliferation of enterocytes, regulation of tight junction proteins, and suppression of pro-inflammatory signaling pathways. Besides, it has a protective role for cells against apoptosis and cellular stresses. It is also functional in production of these cells.<sup>[8,9]</sup> In some previous studies, glutamine supplementation was evaluated to remedy depletions of glutamine stores during serious metabolic stresses such as trauma, sepsis, and inflammatory bowel disease.<sup>[10,11]</sup>

Wound healing and neomucosa formation are a process that encompasses successive events following the anastomosis after tissue injury, and are regulated by different factors. Free radicals or reactive oxygen species (ROS) may cause tissue damage at the anastomosis site and may adversely affect healing. Severe inflammatory reaction and high ROS in chronic wounds with healing disorders are considered as indicators of the presence of oxidative stress. The production of high levels of ROS causes cytotoxicity and delays wound healing. Therefore, the elimination of ROS production is important in wound healing.<sup>[12]</sup> When the oxidative balance is disrupted in favor of oxidative stress as a result of increased ROS and failure of antioxidant systems, free radicals react with fatty acids, proteins, and DNA, increasing the damage. Levels of malondialdehyde (MDA), the final product of lipid peroxidation, and 8-hydroxy-2'-deoxyguanosine (8-OHdG), an indicator of oxidative DNA damage, are most commonly used parameters of oxidative damage.

In animal and human studies, it was shown that damage secondary to the increase in free radicals was significantly improved after topical application of antioxidant compounds.<sup>[13,14]</sup> Superoxide dismutase (SOD) and glutathione peroxidase (GPx), the antioxidant systems in the body, prevent the accumulation of ROS in the organism. Disorders in any of these mechanisms cause increased oxidative damage, harm to the organism, and delay in tissue healing as a result of ROS accumulation. This situation causes increases in the levels of enzymes which are indicative of oxidative damage such as MDA and 8-OHdG in the serum, while it causes a decrease in antioxidant enzymes such as SOD and GPx.<sup>[15]</sup> It was stated in the studies using indomethacin-induced experimental ulcer model of rats that the high levels of antioxidant enzymes such as SOD and GPx can be considered as indicators of improved wound healing.<sup>[16]</sup>

Serosal patching is a method employed to grow new intestinal mucosa. This experimental method is used to increase the absorptive surface.<sup>[17]</sup> The aim of the present experimental study was to evaluate the potential of glutamine on the formation of neomucosa from parietal peritoneum to be used as a patch for terminal ileal defect in rats.

## MATERIALS AND METHODS

### Experimental Design

Sixteen male Wistar Hannover rats (300–500 g) were obtained from Bagcilar Training and Research Hospital Animal Center (BADABEM) and kept in cages under controlled room temperature ( $21 \pm 2^\circ\text{C}$ ) and humidity (60–70%) with 12 h light and 12 h dark regime. The rats were fed ad libitum using standard pellet (MBD Animal Feed, Kocaeli, Turkey). The Local Ethics Committee of University of Health Sciences Turkey, Bagcilar Training and Research Hospital approved the study (Project No: 2019-35).

### Chemicals and Reagents

Glutamine was purchased from Nestle (Resource Glutamine SASE 5 g; Nestle Healthcare Nutrition, Germany).

### Study Groups and Treatment

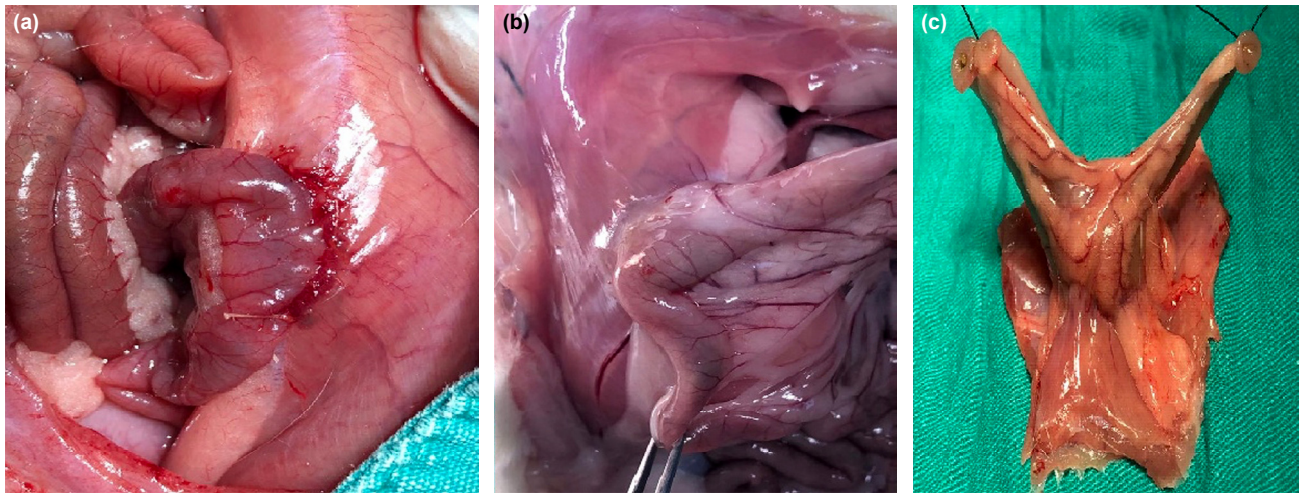
Rats were randomly divided into two groups of eight rats. Group 1 (control) was treated with saline after enteroperitoneal anastomosis applied between mucosal surface of the ileum and parietal peritoneum surface (adherent to abdominal wall). Glutamine (4 mL/kg/day) was administered by gavage to the rats in Group 2 after the same anastomosis.

After 14 days, all rats were euthanized under anesthesia, and blood collected by cardiac puncture was centrifuged and stored at  $-20^\circ\text{C}$  for serum biochemical analyses. After midline laparotomy, anastomotic part of terminal ileum and parietal peritoneum was resected en bloc and washed with saline. The tissues were fixed using 10% formaldehyde for histopathological examination (Fig. 1).

### Surgical Procedure

Rats were anesthetized using isoflurane (Isoflurane; Baxter, Puerto Rico, USA) (5% for induction and 2% for maintenance). A 3 cm midline abdominal incision was made under aseptic conditions. In the terminal ileal region, another 3 cm longitudinal incision was made. The full-thickness defect of ileum was patched (anastomosis) using peritoneum surface with continuous 5.0 Vicryl sutures (Dogsan, Trabzon, Turkey) (Fig. 1).

The effects of glutamine on anastomosis were determined by microscopic and biochemical analyses. Biochemical analyses were performed by measuring oxidant (MDA and 8-OHdG) and antioxidant parameters (SOD and GPx) in serum. Biochemical analyses were performed within 3 days with serum stored at  $-20^\circ\text{C}$ .



**Figure 1.** Surgical procedure and histopathological evaluation. (a) Enteroperitoneal anastomosis conducted between ileum and peritoneum. (b) The appearance of the enteroperitoneal anastomosis on the 14<sup>th</sup> post-operative day. (c) Macroscopic evaluation of anastomosis before histopathological examination.

## Biochemical Analyses

### MDA, 8-OHdG, SOD, and GPx Assays

In addition to the histopathological evaluation of enteroperitoneal anastomosis in rats, 8-OHdG and MDA were assayed to determine the oxidative damage, and serum SOD and GPx enzyme activities were measured to determine antioxidant activity. All assays were conducted at room temperature.

#### MDA Assay

The serum MDA level was measured using a method based on its reaction with thiobarbituric acid (TBA) at 90–100°C. In this assay, MDA or MDA-like substances react with TBA and produce of a pink pigment which has a maximum absorption at 532 nm. The reaction was carried out for 15 min at 90°C and at pH = 2–3 conditions. Two volumes of cold 10% (w/v) trichloroacetic acid were added to the sample and mixed for protein precipitation. After centrifugation, the supernatant was reacted with an equal volume of 0.67% (w/v) TBA in a boiling water bath for 10 min. After cooling the reaction, the absorbance was measured at 532 nm. Serum MDA levels were expressed as nmol/l (Relassay, Turkey).<sup>[18]</sup>

#### 8-OHdG Assay

An ELISA kit based on competitive ELISA principle was used for this assay. The micro-ELISA plate provided by the supplier was pre-coated with 8-OHdG. In the reaction, 8-OHdG in the sample or standard competes with a fixed amount of 8-OHdG on the solid phase for sites on the 8-OHdG-specific Biotinylated Detection antibody. Excess conjugate and unbound sample or standard were eluted, and Avidin conjugated to horseradish peroxidase was added to microplate wells and incubated. TMB substrate solution was then added to wells. The enzyme-substrate reaction was ended by a stop solution and the color change was measured at 540±2 nm. By comparing the OD of the samples and the standard curve, the concentration of 8-OHdG in sample was calculated.<sup>[19]</sup>

Serum 8-OHdG levels were expressed as nmol/l (Relassay, Turkey).

#### SOD Activity Assay

SOD activity was measured according to Sun et al.<sup>[20]</sup> This assay is based on the superoxide radical production by xanthine and xanthine oxidase, which react with nitroblue tetrazolium (NBT) to form formazan dye. SOD activity was measured at 560 nm through determining the degree of inhibition of this reaction. Serum SOD activity was expressed as U/mL (Relassay, Turkey).

#### GPx Activity Assay

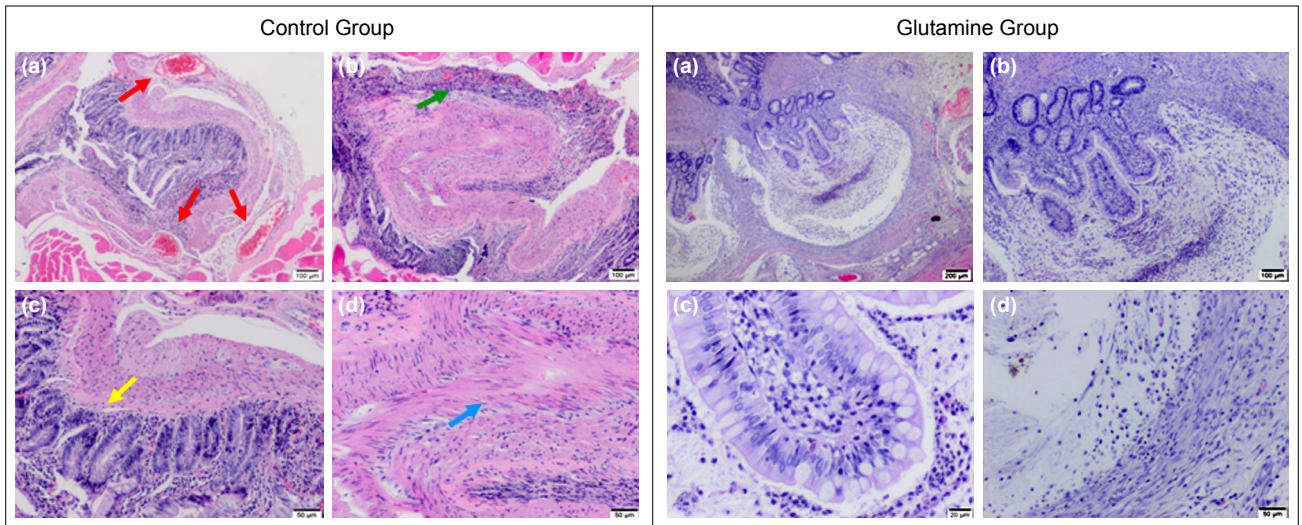
GPx activity was determined according to Lawrence and Burk.<sup>[21]</sup> The absorbance at 340 nm was measured for 5 min. Serum GPx levels were expressed as U/L.

#### Histological Assay

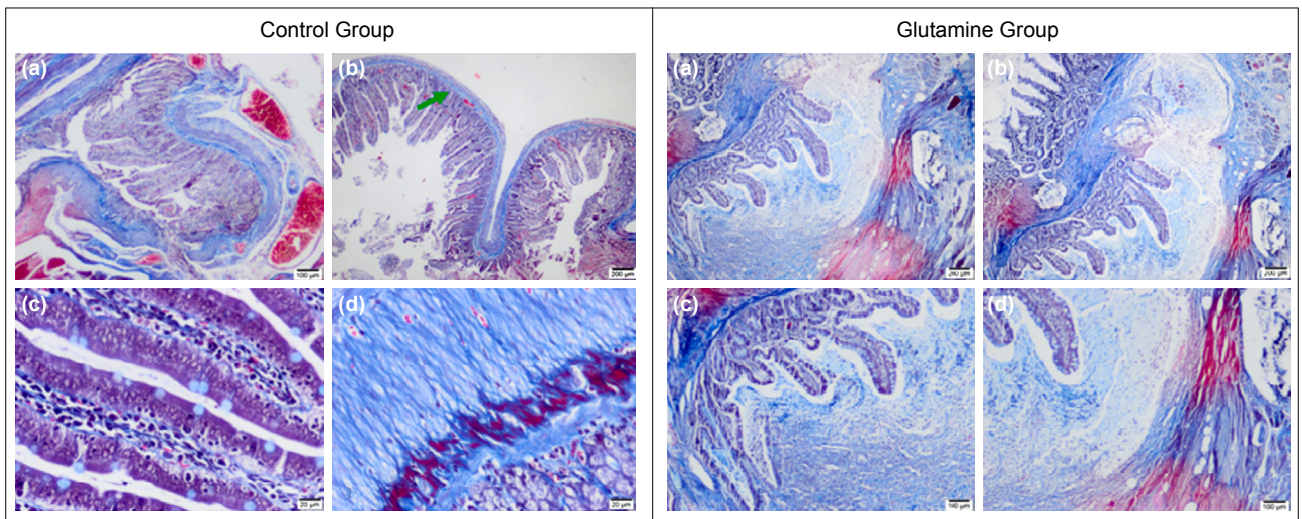
The anastomotic parts were fixed in 10% formaldehyde and prepared for paraffin embedding. Paraffin sections of 4 micron thick were taken and stained with hematoxylin-eosin for the evaluation of neomucosa formation. Scoring was as follows: 0: Neomucosa formation was not observed and 1: Neomucosa formation was observed (Fig. 2). For the examination of fibroblastic activity in the neomucosal region, Masson's trichrome staining was performed (Alcian blue, pH = 2.5) for the examination of intestinal-type mucin (Fig. 3).

## Statistical Analyses

In the study, conformity of the data to the normal distribution was evaluated with the Kolmogorov–Smirnov test. Descriptive statistics of continuous variables were expressed as minimum, maximum, and mean±standard deviation, while categorical variables were expressed as numbers and percentages. Student's t-test and Chi-square test family (Fisher's exact Chi-square and Pearson Chi-square) were used to com-



**Figure 2.** Effect of glutamine use on the formation of intestinal neomucosa on the peritoneal surface (hematoxylin-eosin staining scale in the control group: (a) 100 µm, (b) 100 µm, (c) 50 µm, and (d) 50 µm, hematoxylin-eosin staining scale in the glutamine group: (a) 200 µm, (b) 100 µm, (c) 20 µm, and (d) 50 µm).



**Figure 3.** Evaluation of fibroblastic activity in the areas of peritoneal surface where neomucosa formed in the control group and glutamine groups in rats (Masson trichrome staining scale in the control group: (a) 100 µm, (b) 200 µm, (c) 200 µm, and (d) 200 µm, Masson trichrome staining scale in the glutamine group: (a) 200 µm, (b) 200 µm, (c) 100 µm, and (d) 100 µm).

pare the mean and frequencies of the variables. The frequencies of categorical variables were presented as contingency tables. The p-values obtained as a result of the statistical analyses were evaluated at  $\alpha=0.05$  significance level with a 95% confidence interval, and the comparisons were considered statistically significant when  $p<0.05$  was considered. All statistical analyses were performed using MS Excel and IBM SPSS Statistics 22.0 software.

## RESULTS

### Biochemical Evaluation

In terms of the biochemical evaluation of antioxidant values, SOD activity was  $184.85\pm 15.30$  U/mL in the control group and  $250.96\pm 27.17$  U/mL in the glutamine-treated rats

( $p=0.000$ ). GPx activity was  $194.83\pm 94.73$  U/L in the control group and  $351.66\pm 77.33$  U/L in the glutamine-administered group ( $p=0.011$ ). Thus, serum antioxidant levels (SOD and GPx activities) were significantly higher in glutamine-administered rats compared to the control group ( $p<0.05$ ) (Table I).

With regard the measurements made to evaluate the oxidative damage in the tissues, MDA level was  $0.24\pm 0.04$  mmol/L in the control group and  $0.18\pm 0.01$  mmol/L in the glutamine-administered group ( $p=0.034$ ). The 8-OHdG level was  $1.67\pm 0.09$  ng/mL in the control group and  $1.41\pm 0.08$  ng/mL in the glutamine group ( $p=0.001$ ). Based on these results, oxidative damage (MDA and 8-OHdG) was significantly lower in glutamine-administered rats compared to the control group ( $p<0.05$ ) (Table I).

**Table 1.** Effect of glutamine on serum SOD, GPx, MDA and 8-OHdG levels in enteroperitoneal anastomosis induced rats

	Control group	Glutamine group	p
SOD (U/ml)	184.85±15.30	250.96±27.17	0.000
GPx (U/l)	194.83±94.73	351.66±77.33	0.011
MDA (nmol/l)	0.24±0.04	0.18±0.01	0.034
8-OHdG (ng/ml)	1.67±0.09	1.41±0.08	0.001

SOD: Superoxide dismutase; GPx: Glutathione peroxidase; MDA: Malondialdehyde; 8-OHdG: 8-hydroxy-2'-deoxyguanosine.

**Table 2.** Statistical comparison of neomucosa formation in control and glutamine groups

Groups	Neomucosa		Total	p
	Absent	Present		
Control group				
n	5	3	8	0.315*
% within group	62.50	37.50	100	
% within neomucosa	71.40	33.30	50.00	
Glutamine group				
n	2	6	8	0.315*
% within group	25.00	75.00	100.00	
% within neomucosa	28.60	66.70	50.00	
Total				
n	7	9	16	0.315*
% within group	43.80	56.30	100.00	
% within neomucosa	100.00	100.00	100.00	

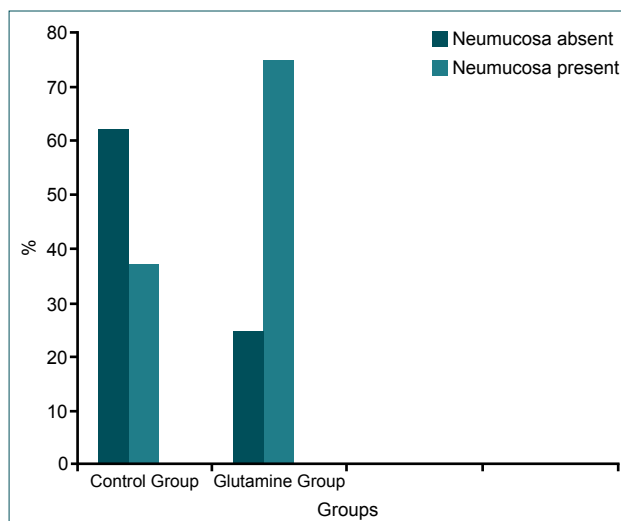
\*Exact Test,  $p > 0.05$ .

## Histological Evaluation

Based on histological evaluation, neomucosa formation was observed in three rats in the control group (37.5%) and in six rats in the glutamine group (75%). However, the difference was not significant ( $p=0.315$ ) (Table 2 and Fig. 4).

## DISCUSSION

In this experimental study on enteroperitoneal anastomosis-induced rats, serum oxidative damage level (MDA and 8-OHdG) and activities of antioxidant enzymes (SOD and GPx) were measured along with the effect of glutamine on neomucosa formation. The results showed that the oxidative damage was lower and the antioxidant enzyme activities were higher in the glutamine supplemented group compared to the control group. In addition, based on the histopathological evaluation, we observed that the administration of glutamine increased the formation of neomucosa in number, but this effect was not statistically significant.

**Figure 4.** Neomucosa formation in the control and glutamine-administered groups.

For the body to maintain a healthy metabolism, appropriate amounts of fluid, electrolytes, trace elements, and vitamins should be absorbed from the gastrointestinal tract. Under normal conditions, there is a tightly regulated balance between nutrient intake and the demands of the body. Inadequate oral intake, intestinal absorption disorders, or an increase in metabolic needs cause the disruption of this homeostasis. While minimal disturbances in the body's homeostasis are tolerated by balancing mechanisms, in case of intolerable deficiencies, disruptions in body metabolism, dehydration, electrolyte disturbances, and even death may occur.<sup>[22]</sup> The most common cause of intestinal failure, leading to the deterioration in the homeostasis of the body, is SBS which is observed after massive bowel resection. The most common cause of SBS in children is SB atresia, aganglionosis, gastroschisis, necrotizing enterocolitis, volvulus, and intussusception, while strangulated bowel, Crohn's disease, ischemia, and trauma are the most common in adults. The management of this clinical condition is very difficult and requires a complex and multidisciplinary approach such as parenteral nutrition and surgical treatment. These complex and specialized treatment modalities which necessitate specialized experience are associated with high morbidity and mortality rates even in the best centers.<sup>[5]</sup> SBS is one of the most common causes that require patients to receive long-term parenteral nutrition (PN). In the long run, PN can cause serious infections, venous thromboembolism, catheter malfunction, metabolic complications such as liver and kidney disease, and eventual organ failure and death.<sup>[23]</sup>

SBS could be managed using several surgical options. Intestinal valve reconstruction, intestinal segment reversion, colon interposition and lengthening are among them. However, all these procedures still have limited success rates. SBS is currently treated with surgical approaches of intestinal transplantation and autologous reconstruction procedures, and these methods involve enlargement of the mucosal surface

area and lengthening of the bowel.<sup>[24]</sup> Two of the main autologous intestinal reconstruction procedures are the Longitudinal Intestinal Lengthening and Tailoring (LILT) (also known as Bianchi procedure) and the serial transverse enteroplasty (STEP). Both of these non-transplant surgical approaches (LILT and STEP procedures) are accepted modalities to eliminate the need for parenteral nutrition supplementation. Both surgical procedures could cause serious complications such as hemorrhage, anastomosis leak, and stricture. Because of its high morbidity and mortality rates, intestinal transplantation is the last option in patients who develop SBS.<sup>[25]</sup>

Growing neomucosa is a novel technique to increase absorptive surface of the intestinal mucosa. It is still an experimental procedure. One of the methods employed to grow new intestinal mucosa to enlarge the mucosal surface is serosal patching technique. In this procedure, the new intestinal mucosa grows laterally by in-growth of the adjacent mucosa and the resulting mucosa has the same functions as the normal intestinal mucosa.<sup>[5]</sup>

Serosal patching technique was evaluated for the growing of neomucosa in some previous studies using experimental models. As the source of serosal patch, serosal surface of the SB, colon, and peritoneal surface was used in these studies.<sup>[2,7,26]</sup> There are studies showing that the use of glutamine has protective and healing properties in inflammation and damage to the intestinal mucosa due to various reasons.<sup>[11,27]</sup> In a study by Wu et al.,<sup>[28]</sup> glutamine was shown to alleviate the heat stress-related damage on intestinal mucosa and improved the healing process. Glutamine has proliferative effect on enterocytes, regulatory effects for tight junction proteins, and suppressive effects on pro-inflammatory signaling pathways. Besides, under normal and pathologic conditions, it protects cells against apoptosis and cellular stresses, and stimulates these cells to proliferate. During serious depletion of glutamine stores in severe metabolic stress conditions such as trauma, sepsis, and inflammatory bowel disease, glutamine supplementation was evaluated as a remedy to improve the clinical outcomes.<sup>[5,10]</sup> Histopathological evaluation of rats treated with glutamine in the present study showed higher neomucosa formation in terms of numbers compared to the control group, but the difference was not significant ( $p=0.315$ ) (Table 2 and Fig. 4). In cases with SBS, prolonging the intestinal transition time and/or increasing the absorption of vitamins and minerals necessary for the body through increasing the formation of neomucosa is very important for reducing the mortality and morbidity. From this point of view, the higher number of neomucosa formation in the enteroperitoneal anastomoses between the ileum and parietal peritoneum in glutamine administered rats compared to the control group is a promising finding for reducing the mortality and morbidity in cases who develop SBS.

In biological systems, electron acceptor molecules are called free radicals. Active oxygen derivatives of free radicals, on

the other hand, are called oxidants. Under normal conditions, oxidants and antioxidants are in balance in a living body. As a result of excessive formation of oxidant substances or a decrease of antioxidant substances for any reason, oxidant substances increase, resulting in oxidative stress.<sup>[29]</sup> Oxidants cause cell damage by taking electrons from target molecules, changing the structure and functions of the target molecule, and affecting the cell membrane, genetic material such as DNA and RNA, and various enzymatic events. This causes delays in wound healing.<sup>[30,31]</sup> It was shown in many studies that under oxidative stress conditions, various toxic agents produced by ROS cause many diseases such as diabetes mellitus, ischemia-reperfusion injury, cancer, aging, and impaired wound healing.<sup>[16,31,32]</sup> In experimental studies with diabetic rats, oxidative stress was shown to cause severe damage to fibroblasts, decreasing collagen fibril formation, and increasing inflammation. As a result, ROS production increased and antioxidant levels decreased. This was mentioned to be one of the most important causes of impaired wound healing in patients with diabetes.<sup>[33]</sup> 8-OHdG, a DNA damage product produced by ROS, and MDA, a lipid peroxidation product, are widely used markers to indicate the oxidative stress level associated with ROS.<sup>[14,19,31]</sup> Nakai et al.<sup>[34]</sup> stated that 8-OHdG and MDA levels are important indicators of oxidative stress, and play important roles in the emergence of diseases by causing toxicity in many systems. In another study,<sup>[35]</sup> it was observed that the MDA level, which is used as an indicator of oxidative damage, was significantly higher ( $p<0.001$ ) in the disease group compared to the healthy control group. According to the results of that study, MDA and 8-OHdG levels increased in many pathologies related to oxidative damage. In experimental wound models induced in rats, increased MDA and 8-OHdG levels were shown to delay wound healing due to oxidative damage.<sup>[36]</sup> In the present study, MDA and 8-OHdG levels, indicators of oxidative damage, were significantly lower in glutamine-administered rats compared to the control group ( $p<0.05$ ) (Table 1). From this point of view, in cases with SBS development, the administration of glutamine in the enteroperitoneal anastomoses formed between the ileum and parietal peritoneum is important in terms of reducing the oxidative damage in the body, improving the healing in the anastomotic tissue, and increasing the intestinal absorption surface as a result of neomucosa formation.

Antioxidant enzymes such as SOD and GPx play an important role in balancing oxidative damage in the body. As a result of the decrease in the activities of antioxidant enzymes in the cells or the depletion of antioxidant compounds, an increase in the levels of oxidant substances occurs, and this results in oxidative stress.<sup>[16]</sup>

Antioxidants such as SOD and GPx prevent damage to cells and improve wound healing by reducing or completely eliminating the effects of ROS.<sup>[37,38]</sup> The balance between oxidative and antioxidant systems was investigated in various experimental disease models created in rats. In experimental mod-

els, it was observed that oxidative stress increased and antioxidant enzyme activities such as SOD and GPx decreased significantly compared to the control groups.<sup>[31,35]</sup> Similarly, other studies showed that SOD is an effective enzyme in early stages of the inflammatory phase in the wound healing process and hastens the wound healing when applied topically.<sup>[12]</sup> It was shown in rat experimental disease models that low levels of antioxidant enzymes such as SOD and GPx were associated with more severe damage due to oxidative stress. These enzymes work together to remove ROS, and reductions in their levels can have an impact on the stability of cellular proteins, lipids, and DNA against the oxidative damage. Consequently, the activity of these antioxidant enzymes is important factors necessary to protect tissues and organs against oxidative stress.<sup>[39]</sup>

Excess production of ROS leads to oxidative stress, which, in turn, results in cytotoxicity and impaired wound repair. Therefore, eliminating the production of ROS could be an efficient way to promote healing of chronic wounds. Activity levels of antioxidant enzymes such as SOD and GPx in granulation tissues are also critical because they improve the wound healing process through eliminating the free radicals.<sup>[36]</sup> In the present study, SOD and GPx enzyme activity levels were significantly higher in rats treated with glutamine compared to the control group ( $p < 0.05$ , Table 1). Administration of glutamine to the rats that underwent enteroperitoneal anastomosis was beneficial in that it increased the levels of antioxidant enzymes such as SOD and GPx, reduced the oxidative damage in cases with SBS development, improved the healing in anastomosis tissue, and increased the intestinal absorption surface through neomucosa formation.

## Conclusion

Increasing the intestinal absorption surface through neomucosa formation is critical for avoiding the risks posed by parenteral nutrition in organisms in which SBS develops. In the experimental models, the healing of the anastomosis and the formation of neomucosal tissue were shown to be a set of cellular and biochemical events involving all systems, not only the wound area. There are many factors that play roles in the neomucosa formation process, and reducing oxidative damage and increasing antioxidant activity may be some of them. In this regard, use of glutamine may be beneficial due to its antioxidant effect and cellular proliferation-enhancing effect. Further experimental studies are needed in this regard.

**Ethics Committee Approval:** This study was approved by the İstanbul Bağcılar Training and Research Hospital Animal Experiment Ethics Committee (Date: 03.09.2019, Decision No: 2019-35).

**Peer-review:** Internally peer-reviewed.

**Authorship Contributions:** Concept: A.A., O.B.G.; Design: E.Y., H.Y.; Supervision: A.S., Y.U.; Resource: N.A.H., G.E.; Materials: Y.A., A.K.; Data: A.A., O.B.G., N.A.H.; Anal-

ysis: A.A., A.K., A.Ç.; Literature search: A.A., O.B.G., E.Y.; Writing: A.A., N.A.H., G.E.; Critical revision: A.A., A.Ç.

**Conflict of Interest:** None declared.

**Financial Disclosure:** The present work was supported by the SBU Bağcılar Training and Research Hospital Educational Planning and Coordination Committee (Project no: 2019-35).

## REFERENCES

- Jeppesen PB. New approaches to the treatments of short bowel syndrome-associated intestinal failure. *Curr Opin Gastroenterol* 2014;30:182–8.
- Greig CJ, Oh PS, Gross ER, Cowles RA. Retracing our STEPs: Four decades of progress in intestinal lengthening procedures for short bowel syndrome. *Am J Surg* 2019;217:772–82. [CrossRef]
- Yildiz BD. Where are we at with short bowel syndrome and small bowel transplant. *World J Transplant* 2012;2:95–103. [CrossRef]
- Yang GT, Zhao HY, Kong Y, Sun NN, Dong AQ. Study of the effects of nesfatin-1 on gastric function in obese rats. *World J Gastroenterol* 2017;23:2940–7. [CrossRef]
- Gulcicek OB, Solmaz A, Yiğitbas H, Ercetin C, Yavuz E, Ozdogan K, et al. Comparison of the effects of glutamine, curcumin, and nesfatin-1 on the gastric serosal surface neomucosa formation: An experimental rodent model. *Gastroenterol Res Pract* 2016;2016:2081962. [CrossRef]
- Kesseli S, Sudan D. Small bowel transplantation. *Surg Clin North Am* 2019;99:103–16. [CrossRef]
- Totonelli G, Tambucci R, Boscarelli A, Hermans D, Oglio LD, Diamanti A, et al. Pediatric intestinal rehabilitation and transplantation registry: Initial report from a European collaborative registry. *Eur J Pediatr Surg* 2018;28:75–80. [CrossRef]
- Yang XF, Qin JF, Wang L, Gao KG, Zheng CT, Huang L, et al. Improved milk glutamine level and growth performance of suckling piglets by glutamine supplementation in maternal diet. *Annal Ani Sci* 2018;18:441–52. [CrossRef]
- Chen S, Xia Y, Zhu G, Yan J, Tan C, Deng B, et al. Glutamine supplementation improves intestinal cell proliferation and stem cell differentiation in weanling mice. *Food Nutr Res* 2018;62:10.29219/fnr.v62.1439. [CrossRef]
- Bortoluzzi C, Rochell SJ, Applegate TJ. Threonine, arginine, and glutamine: Influences on intestinal physiology, immunology, and microbiology in broilers. *Poul Sci* 2018;97:937–45. [CrossRef]
- Kim MH, Kim H. The roles of glutamine in the intestine and its implication in intestinal diseases. *Int J Mol Sci* 2017;18:1051. [CrossRef]
- Aksoy H, Özakpınar ÖB. Wound healing and oxidative stress. *Marmara Pharm J* 2014;18:153–8. [CrossRef]
- Parihar A, Parihar MS, Milner S, Bhat S. Oxidative stress and anti-oxidative mobilization in burn injury. *Burns* 2008;34:6–17. [CrossRef]
- Latha B, Babu M. The involvement of free radicals in burn injury: A review. *Burns* 2001;27:309–17. [CrossRef]
- Odabasoglu F, Cakir A, Süleyman H, Aslan A, Bayir Y, Halici M, et al. Gastroprotective and antioxidant effects of usnic acid on indomethacin-induced gastric ulcer in rats. *J Ethnopharmacol* 2006;103:59–65. [CrossRef]
- Celebi F, Akbas A, Sağlam M, Kisaoglu A, Alp HH. Effect of sertraline in indomethacin-induced gastric mucosal damage. *Asian J Chem* 2012;24:1966–70.
- Millar AJ. Non-transplant surgery for short bowel syndrome. *Pediatr Surg Int* 2013;29:983–7. [CrossRef]
- Janero DR. Malondialdehyde and thiobarbituric acid-reactivity as diagnostic indices of lipid peroxidation and peroxidative tissue injury. *Free Radic Biol Med* 1990;9:515–40. [CrossRef]
- Valavanidis A, Vlachogianni T, Fiotakis C. 8-hydroxy-2'-deoxyguanosine (8-OHdG): A critical biomarker of oxidative stress and carcinogenesis. *J Environ Sci Health C Environ Carcinol Ecotoxicol Rev* 2009;27:120–39.

20. Sun Y, Oberley LW, Li Y. A simple method for clinical assay of superoxide dismutase. *Clin Chem* 1988;34:497–500. [CrossRef]
21. Lawrence RA, Sunde RA, Schwartz GL, Hoekstra WG. Glutathione peroxidase activity in rat lens and other tissues in relation to dietary selenium intake. *Exp Eye Res* 1974;18:563–9. [CrossRef]
22. Jeppesen PB. Gut hormones in the treatment of short-bowel syndrome and intestinal failure. *Curr Opin Endocrinol Diabetes Obes* 2015;22:14–20. [CrossRef]
23. Schwartz LK, O'Keefe SJ, Fujioka K, Gabe SM, Lamprecht G, Pape UF, et al. Long-term teduglutide for the treatment of patients with intestinal failure associated with short bowel syndrome. *Clin Transl Gastroenterol* 2016;4:7:142. [CrossRef]
24. Sommovilla J, Warner BW. Surgical options to enhance intestinal function in patients with short bowel syndrome. *Curr Opin Pediatr* 2014;26:350–5. [CrossRef]
25. Frongia G, Kessler M, Weih S, Nickkholgh A, Mehrabi A, Holland-Cunz S. Comparison of LILT and STEP procedures in children with short bowel syndrome-a systematic review of the literature. *J Pediatr Surg* 2013;48:1794–805. [CrossRef]
26. Freud E, Eshet R. Insights from animal models for growing intestinal neomucosa with serosal patching-a still untapped technique for the treatment of short bowel syndrome. *Lab Anim* 2001;35:180–7. [CrossRef]
27. Li N, Lewis P, Samuelson D, Liboni K, Neu J. Glutamine regulates Caco-2 cell tight junction proteins. *Am J Physiol Gastrointest Liver Physiol* 2004;287:G726–33. [CrossRef]
28. Wu QJ, Liu N, Wu XH, Wang GY, Lin L. Glutamine alleviates heat stress-induced impairment of intestinal morphology, intestinal inflammatory response, and barrier integrity in broilers. *Poult Sci* 2018;97:2675–83. [CrossRef]
29. Karabulut H, Gülay MŞ. Antioxidants. *Veterinary J Mehmet Akif Ersoy Uni* 2016;1:65–76. [CrossRef]
30. Kılıç A, Erdoğan S, Yorulmaz A, Doğan S, Ergin M, Artüz F, et al. The oxidative stress parameters and the effect of dyslipidemia on the parameters of oxidative stress in lichen planus. *Turkderm - Arch Turk Dermatol Venerology* 2015;49:7–12. [CrossRef]
31. Cihan G, Kandemir F, Aydın G. The effect of berberine on oxidative and nitrosative stress in rats with bortezumib-induced heart damage. *Tr J Nature Sci* 2020;9:118–26.
32. Ercan N, Fidancı UR. Urine 8-Hydroxy-2'-Deoxyguanosine (8-OHdG) levels of dogs in pyoderma. *Ankara Univ Vet Fac J* 2012;59:163–8.
33. Shetty S, Udupa S, Udupa L. Evaluation of antioxidant and wound healing effects of alcoholic and aqueous extract of *Ocimum sanctum* Linn in rats. *Evid Based Complement Alternat Med* 2008;5:95–101. [CrossRef]
34. Nakai K, Yoneda K, Maeda R, Murehiro A, Fujita N, Yokoi I, et al. Urinary biomarker of oxidative stress in patients with psoriasis vulgaris and atopic dermatitis. *J Eur Acad Dermatol Venereol* 2009;23:1405–8. [CrossRef]
35. Jalel A, Yassine M, Hamdaoui MH. Oxidative stress in experimental vitiligo C57BL/6 mice. *Indian J Dermatol* 2009;54:221–4. [CrossRef]
36. Al-Khowaiter SS, Brahmia M, Kim E, Madden M, Harris A, Yoshida EM, et al. Clinical and endoscopic significance of bowel-wall thickening reported on abdominal computed tomographies in symptomatic patients with no history of gastrointestinal disease. *Can Assoc Radiol J* 2014;65:67–70. [CrossRef]
37. Buyuklu M, Kandemir FM, Ozkaraca M, Set T, Bakirci EM, Topal E, et al. Beneficial effects of lycopene against contrast medium-induced oxidative stress, inflammation, autophagy, and apoptosis in rat kidney. *Hum Exp Toxicol* 2015;34:487–96. [CrossRef]
38. Kandemir FM, Benzer F, Yildirim NC, Özdemir N. Compensatory effects of curcumin on cisplatin-induced toxicity in rabbit testis. *J Med Plants Res* 2011;5:456–61.
39. Kucukler S, Derendelioglu E, Caglayan C, Ayna A, Yildirim S, Kandemir FM. Zingerone attenuates vancomycin-induced hepatotoxicity in rats through regulation of oxidative stress, inflammation and apoptosis. *Life Sci* 2020;259:118382. [CrossRef]

## DENEYSSEL ÇALIŞMA - ÖZ

### Şıçanlarda Glutamin kullanımının peritoneal yüzeyde intestinal neomukoza oluşumuna etkisi

Dr. Ahmet Akbaş,<sup>1</sup> Dr. Osman Bilgin Gülcicek,<sup>2</sup> Dr. Erkan Yavuz,<sup>2</sup> Dr. Hakan Yigitbas,<sup>2</sup> Dr. Ali Solmaz,<sup>2</sup> Dr. Yigit Ulgen,<sup>3</sup> Dr. Nadir Adnan Hacim,<sup>2</sup> Dr. Gulcin Ercan,<sup>2</sup> Dr. Yuksel Altinel,<sup>2</sup> Dr. Aysegül Kirankaya,<sup>4</sup> Dr. Atilla Çelik<sup>2</sup>

<sup>1</sup>Karadeniz Teknik Üniversitesi Tıp Fakültesi, Genel Cerrahi Anabilim Dalı, Trabzon

<sup>2</sup>Sağlık Bilimleri Üniversitesi İstanbul Bağıcılar Eğitim ve Araştırma Hastanesi, Genel Cerrahi Kliniği, İstanbul

<sup>3</sup>Sağlık Bilimleri Üniversitesi İstanbul Bağıcılar Eğitim ve Araştırma Hastanesi, Patoloji Kliniği, İstanbul

<sup>4</sup>Sağlık Bilimleri Üniversitesi İstanbul Bağıcılar Eğitim ve Araştırma Hastanesi, Biyokimya Kliniği, İstanbul

**AMAÇ:** Kısa bağırsak sendromu (SBS) ince bağırsakların uzunluğunun azalmasına bağlı vücut için gerekli olan sıvı veya besinlerin emilim eksikliğine yol açan mortalitesi ve morbiditesi yüksek klinik durumdur. Glutamin ise bağırsak mukoza hücrelerinin beslenmesini ve proliferasyonunu artıran bir proteindir. Bu çalışmanın temel amacı SBS gelişen ratlarda Glutaminin intestinal neomucosa oluşumu üzerine olan etkisini araştırmaktır.

**GEREÇ VE YÖNTEM:** On altı wistar-Hannover şıçan üzerinde ileumun mukozal yüzeyi ile parietalperiton yüzeyinin (karın duvarına yapışık) arasında enteroperitoneal anastomoz yapıldıktan sonra rastgele iki eşit gruba bölündü. Grup 1 (kontrol grubu), Salin ile tedavi edilirken grup 2 Glutamin ile tedavi edildi. On dört gün sonra tüm şıçanlara ötenazi uygulandı ve kan alındı. Eş zamanlı olarak anastomoz parçasının en blok rezeksiyonu yapılarak neomukoza oluşumu yönü ile histopatolojik inceleme yapıldı. Glutaminin anastomoz üzerine olan etkileri mikroskopik ve biyokimyasal analizler yapılmak sureti ile belirlendi.

**BULGULAR:** Biyokimyasal analizler serumda oksidan (MDA ve 8-OHdG), antioksidan (SOD ve GPx) parametrelerin ölçümü ile yapıldı. Kontrol grubu ve Glutamin verilen grubun antioksidan değerlerinin biyokimyasal değerlendirme sonuçlarına göre Glutamin verilen şıçanlarda serum antioksidan seviyesi (SOD ve GPx aktivitesi) kontrol grubuna göre anlamlı ölçüde yüksek ( $p < 0.05$ ) iken oksidatif hasarın (MDA ve 8-OHdG) kontrol grubuna göre düşük olduğu ( $p < 0.05$ ) gözlemlendi. Neomukoza oluşumu yönü ile yapılan histolojik değerlendirme sonucunda ise Glutamin verilen grupta neomukoza oluşumu sayıca fazla olmasına rağmen kontrol grubuna göre istatistiksel olarak anlamlı çıkmamıştır ( $p = 0.315$ ).

**TARTIŞMA:** Kısa bağırsak sendromu gelişen hastalarda Glutamin kullanımı neomukoza oluşumunu artırarak yüzey emilimini artırabilir. Ancak bunun yeterince güçlü klinik deneylerle belirlenmesi gerekiyor.

**Anahtar sözcükler:** Glutamin; kısa bağırsak sendromu; neomukoza; peritoneal yüzey.

Ulus Travma Acil Cerrahi Derg 2022;28(11):1541-1548 doi: 10.14744/ıtjes.2021.36903