

Is the zeolite hemostatic agent beneficial in reducing blood loss during arterial injury?

Zeolite kanama durdurucu ajanı, arteriyel yaralanmalarda oluşan kan kaybını azaltmada faydalı mı?

Mehmet ERYILMAZ,¹ Tahir ÖZER,¹ Öner MENTEŞ,² Nurkan TORER,¹
Murat DURUSU,¹ Armağan GÜNAL,³ Ali İhsan UZAR²

BACKGROUND

Uncontrolled hemorrhage is the leading cause of fatality. The aim of this study was to evaluate the effect of zeolite mineral (QuikClot - Advanced Clotting Sponge [QC-ACS]) on blood loss and physiological variables in a swine extremity arterial injury model.

METHODS

Sixteen swine were used. Oblique groin incision was created and a 5 mm incision was made. The animals were allocated to control group (n: 6): Pressure dressing was applied with manual pressure over gauze sponge; or QC group (n: 10): QC was directly applied over lacerated femoral artery. Mean arterial pressure, blood loss and physiological parameters were measured during the study period.

RESULTS

Application of QC led to a slower drop in blood pressure. The control group had a significantly higher increase in lactate within 60 minutes. The mean prothrombin time in the control group was significantly increased at 60 minutes. The application of QC led to decreased total blood loss. The QC group had significantly higher hematocrit levels. QC application generated a significant heat production. There were mild edematous and vacuolar changes in nerve samples.

CONCLUSION

According to the physiological parameters, we observed that zeolite tends to reduce blood loss, however could not stop bleeding completely. We believe that further clinical trials are needed to conclude that zeolite could be used in the routine practice.

Key Words: Hemorrhage control; hemostatic agent; zeolite; QuikClot.

AMAÇ

Kontrolsüz kanamalar ölümlerin en sık nedenlerindedir. Çalışmada domuz femoral arteri yaralanması sonucu kan kaybıyla oluşan fizyolojik değişikliklere karşı zeolite mineralin (QC-ACS) etkisi değerlendirildi.

GEREÇ VE YÖNTEM

On altı domuz kullanıldı. Oblig bir kasık kesisi sonrasında femoral arter bulunup 5 mm'lik kesi yapıldı. Denekler gruplara ayrıldı; altı domuzdan oluşan kontrol grubu'nda (KG) kanayan bölgeye gaz kompres konularak elle baskı uygulandı. QC uygulanan gruptaki 10 domuzda ise kanayan alana doğrudan QC yerleştirildi ve elle baskı uygulandı. Çalışma sürecinde ortalama arteriyel basınç, kan kaybı ölçümleri gerçekleştirildi. Histolojik inceleme için örnekler alındı.

BULGULAR

QC uygulaması sonrasında kan basıncında düşüşün tedricen azaldığı saptandı. 60. dk'dan sonra serum laktat düzeyinde KG'ye göre anlamlı şekilde yükselme saptandı. Protrombin zamanı KG için 60 dk'da anlamlı uzamış bulundu. QC uygulamasının kan kaybını durduramadığı ancak azalttığı saptandı. Hematokrit değerleri, QC uygulanan grupta KG'ye göre daha anlamlı idi. QC uygulaması sonrasında ortaya çıkan yüksek ısıya bağlı histopatolojik değerlendirme sonucunda özellikle nöral dokuda orta derecede ödem ve vakuolar değişiklikler saptandı.

SONUÇ

Çalışmadaki fizyolojik parametreler değerlendirildiğinde; zeolitin kanamaya bağlı kan kaybını azaltma eğilimi gösterdiği ancak tam olarak durduramadığı saptandı. Bu tür deneysel çalışma sonuçlarının rutin kullanıma sokulabilmesi için klinik çalışmalarla desteklenmesi gerektiği kanısındayız.

Anahtar Sözcükler: Kanama kontrolü; hemostatik ajan; zeolite; QuikClot.

Departments of ¹Emergency Medicine, ²General Surgery, and ³Pathology
Gülhane Military Medical Academy, Ankara, Turkey.

Gülhane Askeri Tıp Akademisi, ¹Acil Tıp Anabilim Dalı, ²Genel Cerrahi
Anabilim Dalı, ³Patoloji Anabilim Dalı, Ankara.

Correspondence (İletişim): Mehmet Eryılmaz, M.D. Department of Emergency Medicine and Surgery, GATA, Etlik 06018, Ankara, Turkey.
Tel: +090 - 312 - 304 30 30 Fax (Faks): +090 - 312 - 352 81 81 e-mail (e-posta): mehmeteryilmaz@hotmail.com

Uncontrolled hemorrhage is one of the leading causes of fatality after trauma in both civilians and military personnel. Approximately 50% of trauma deaths occur during the second phase of trauma due to exsanguination.^[1] This issue is especially important for combat extremity wounds in which hemorrhage can be potentially controlled by direct compression and application of a pressure dressing by a fellow comrade or any first responder. Considerable efforts have been made to study the effectiveness of some hemostatic agents that can be applied directly to the bleeding wound. There are several advanced hemostatic agents such as oxidized cellulose, fibrin glue and synthetic adhesives.^[2,3] The mineral zeolite (QuikClot-Advanced Clotting Sponge [QC-ACS®], Z-Medica, Wallingford, CT, USA) is one of these topical hemostatics that has shown some promising results. Zeolite is an inert mineral composed of silicon, aluminium, sodium, magnesium and quartz oxides. It creates an exothermic process leading to the adsorption of water. This exothermic effect is proportional to the ratio of zeolite to water. This physical reaction concentrates erythrocytes, platelets and clotting factors, leading to rapid clot formation at the site of application.^[4]

There are some controversies in the studies using zeolite in actively bleeding extremity injuries.^[4] The beneficial effect of zeolite in high-grade liver injury has been demonstrated.^[5] Zeolite decreased blood loss and mortality in mixed femoral arterial and venous injuries.^[6,7] However, zeolite was found to be ineffective in reducing blood loss or increasing survival in another lethal femoral injury model.^[8] Furthermore, a potential tissue injury due to the thermal effect of zeolite, which generates an exothermic physical effect, has been addressed in several studies, with conflicting results.^[4,8-10] There are numerous case reports from military medical personnel of the beneficial use of zeolite in injured troops in the battlefield such as in the Iraq and Afghanistan conflicts.^[4]

The aim of the present study was to evaluate the effect of zeolite on blood loss, physiological variables and mortality in a model of swine extremity arterial injury.

MATERIALS AND METHODS

The Ethics Committee on Experimental Research in our institution approved the study. Laboratory animals were cared for according to the Guide for the Care and Use of Laboratory Animals (National Institutes of Health publication, 1996).

Animal preparation

Sixteen pathogen-free swine, 75-100 kg in weight, were used in the study. They were fasted 8 hours before the experimental study, with water allowed ad libitum as suggested by our local Animal Care Committee. Anesthesia was induced after pre-medication with intramuscular ketamine (10 mg/kg) (Alfamine®, EgeVet, Izmir, Turkey) and inhaled isoflurane. After endotracheal intubation, anesthesia was maintained with isoflurane 2.5-3.0% in 100% oxygen, and animals were placed on ventilator. After supine positioning, carotid artery and internal jugular vein were catheterized for hemodynamic monitoring (Pressure Monitor Set, Bicakcilar®, Istanbul, Turkey and Cardiocap/5 monitor, Datex-Ohmeda®, Louisville, CO, USA) and blood sampling. Arterial and venous blood samples were analyzed by Kodak EKTACHEM DT60 II System (Johnson&Johnson®, Rochester, New York, USA). Mean arterial pressure (5, 15, 30 and 60 minutes), serum lactate (0, 5 and 60 minutes), hematocrit (0, 5, 15, 30 and 60 minutes) and prothrombin time (PT) (0, 15 and 60 minutes) were measured during the study period.

Surgical and experimental procedure

A right-sided oblique groin incision was created. After transection of the proximal thigh skin, soft tissues and muscles, a 3 to 4 cm of femoral artery was dissected free from the surrounding tissue. A 5 mm standard size lateral transverse incision was made along the artery by puncture arteriotome. The femoral vein was left intact. After 5 minutes of free bleeding, the animals were allocated to control or zeolite groups. The animals were not randomized because the incision size was standard. The experimental groups were as follows: Control group (n: 6): Pressure dressing was applied with manual pressure over standard two gauze sponges; and zeolite group (n: 10): Two standard size QC-ACS® were applied over the lacerated femoral artery under manual pressure after suctioning the surgical wound. Two gauze sponges were applied on them.

Manual compression was applied for 10 minutes in all animals in both groups. After 5 minutes of free bleeding and 10 minutes of QC-ACS® application, the gauze compresses and QC-ACS® were removed at the 15th minute of the experiment. Standard pressure dressing was replaced on the wound at the 15th, 30th and 60th minutes of the experiment. Blood loss was measured by suctioning the wound and weigh-

Table 1. Physiological parameters in control and QC-ACS® groups

	Time (min)	QC	Control	p
		Mean ± SD		
Hematocrit (/mm ³)	0	32.6±0.7	31.6±0.6	NS
	5	33.5±0.7	31.4±0.7	NS
	15	31.7±0.7	29.3±0.5	0.03
	30	29.2±0.6	24.8±0.6	0.001
	60	27.4±0.6	21.6±0.9	0.002
Lactate (mmol/L)	0	0.9±0.03	0.9±0.04	NS
	5	2.2±0.09	2.2±0.10	NS
	60	2.4±0.08	3.1±0.15	0.002
PT (sec)	0	10.8±0.3	11.4±0.4	NS
	15	13.6±0.6	16.2±0.5	NS
	60	14.3±0.6	23.0±0.7	0.01

QC: QuikClot Advanced Clotting Sponge group; PT: Prothrombin time; NS: Non-significant.

ing the gauze sponges during the experiment. The heat effect of the exothermic reaction was monitored by placing a digital heat probe under the dressing sponge, beginning from the onset of the study and at 5, 15, 30 and 60 minutes. All animals were resuscitated starting at the 15th minute after the incision with 1500 ml lactated Ringer solution. At the end of the experiment, animals were sacrificed by intravenous bolus of a lethal dose of sodium pentobarbital (25 mg/kg).

Histopathological examination

Artery, vein, nerve and muscle segments were obtained from application areas at the end of the experiment and were fixed in 10% buffered formaldehyde. Artery and vein samples were embedded in paraffin transversely. Nerve and muscle samples were embedded in paraffin transversely and longitudinally. Four mm sections were sliced and stained with hematoxylin-eosin (H-E).

Statistical analysis

All data were presented as mean ± SEM. All continuous variables (blood loss, temperature, partial thromboplastin time [PTT], lactate levels and hemodynamic data) were compared by t-test and Mann-Whitney U-test for the non-parametric counterparts.

Chi-square test was performed for categorical variables. p<0.05 was accepted as significant.

RESULTS

There was no mortality in either of the study groups.

Hemodynamic parameters (blood pressure, blood loss and hematocrit levels)

Mean arterial blood pressure (BP) records are presented in Fig. 1. The femoral arterial injury caused a decrease in BP in both groups; however, the application of zeolite led to a significantly slower drop in BP (p=0.001).

The zeolite group had significantly higher hematocrit levels at 15, 30 and 60 minutes of the study, when compared to the control group (p=0.03, p=0.001 and p=0.002, respectively) (Table 1).

Standard wound dressing and manual pressure did not effectively decrease bleeding from the wound in the control group. Before wound dressing within the first 5 minutes, blood loss was similar in both groups. Blood loss was significantly high in the control group at 15, 30 and 60 minutes of the study (p=0.001 for all time points). The application of zeolite led to significantly decreased total blood loss (Fig. 2).

Physiologic parameters (serum lactate and PT)

The physiologic parameters of blood lactate and PT levels are shown in Table 1. The injury increased arterial lactate levels in both groups. The control group had a significantly higher increase in lactate at 60 minutes (p=0.002).

Although hemorrhage caused a significant increase in PT in both groups, there was no significant difference in PT levels at 15 minutes between the groups. The mean PT level in the control group was significantly increased when compared to that of the zeolite group at 60 minutes (p=0.001) (Table 1).

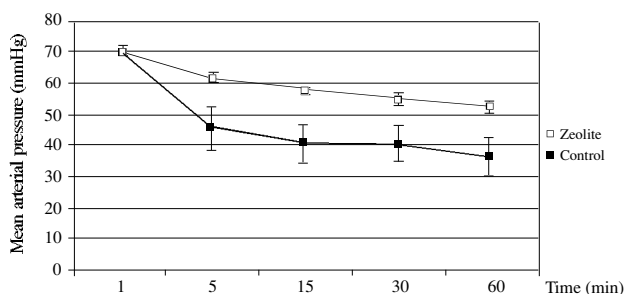


Fig. 1. Mean arterial pressure records in mmHg in control and QC-ACS® groups.

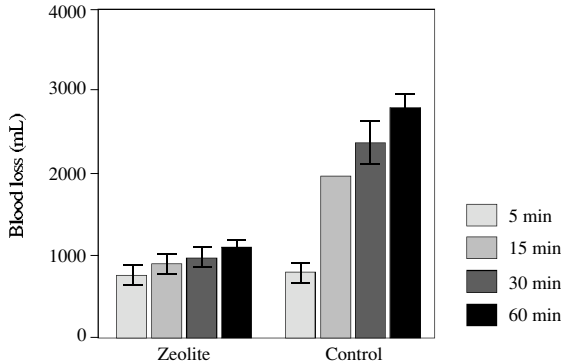


Fig. 2. Total blood loss at 5, 15, 30, and 60 minutes in both groups.

Exothermic reaction

Standard wound packing and manual pressure did not cause any significant change in wound temperature, as expected. However, zeolite application generated a significant heat production. This effect appeared immediately following the application of the zeolite mineral. Peak heat production was detected immediately after 5 minutes. Although the significant heat production effect continued through the whole study period, there was a trend toward a decrease in heat production after 5 minutes, and it had significantly decreased at 15 minutes (Fig. 3).

Histopathologic evaluation

There was no sign of allergic reaction in the examined tissue samples. Histopathological examination of artery samples revealed a pink coagulum that intermixed with red blood cells in the lumen and surrounding tissue of the laceration area. Loss of smooth muscle cell detail and pyknosis of nuclei were also observed (Fig. 4a). There were mild edematous and vacuolar changes in nerve samples of the application area (Fig. 4b). Muscle fibers demonstrated irregular staining in some areas (Fig. 4c). No

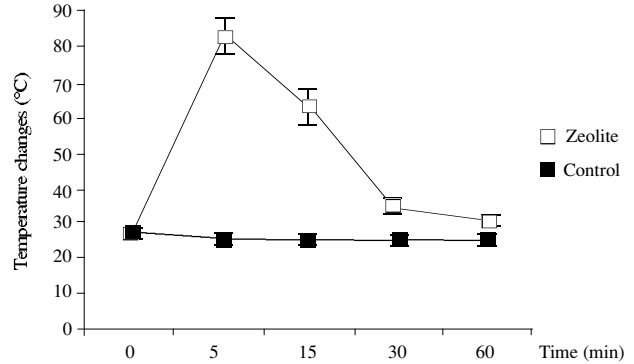


Fig. 3. Temperature changes (°C) due to exothermic reaction in control and QC-ACS® groups.

abnormal histological view was seen in sections of vein samples. There were no differences between the control group and zeolite group with respect to histopathologic changes.

DISCUSSION

Most injuries in the battlefield are extremity injuries. A substantial percent of the mortalities in recent wars have been caused by extremity injuries.^[11] Tourniquet application is usually not sufficient to stop bleeding, especially in proximally located penetrating extremity wounds, such as the axillary or femoral region. This insufficiency has led to an increased interest in topical hemostatic agents among military surgical researchers. One of the most investigated topical agents has been the mineral zeolite material. Previous studies have suggested beneficial effects of zeolite in reducing blood loss and correcting physiological abnormalities and hemodynamic variables.^[4-9,12] Both animal studies and a few data from battlefield usage have encouraged the use of this material.^[4]

Some previous studies designed the groin injury model with complete transection of the femoral

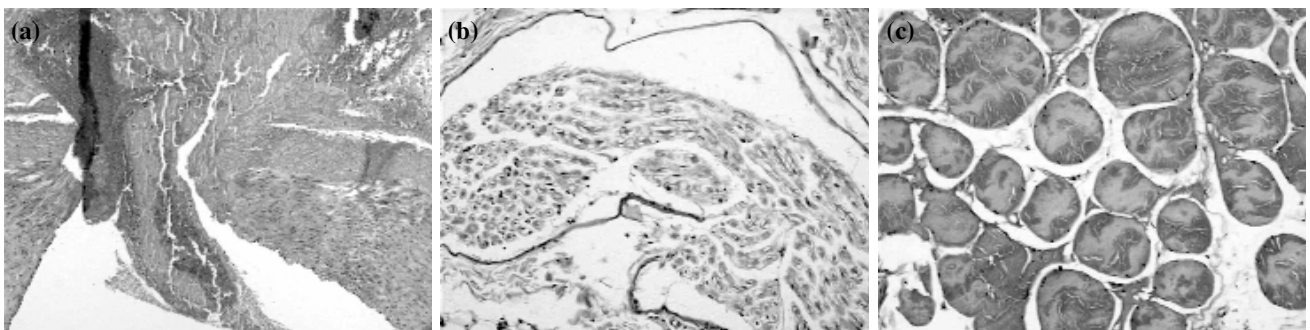


Fig. 4. (a) Loss of smooth muscle cell detail and pyknosis of nuclei (H-E x 40). (b) Mild edematous and vacuolar changes in nerve samples of application area (H-E x 100). (c) Muscle fibers demonstrate irregular staining (H-E x 100).

artery.^[8,9] This type of injury usually results in complete vasoconstriction and retraction, which stops the active bleeding. Another researcher conducted a groin arterial injury model by lateral surface arteriotomy.^[5] Most penetrating injury includes some type of incomplete tissue destruction with blast injury. Thus, we preferred a standard size lateral arteriotomy model, which includes potentially lethal bleeding that can be stopped by direct pressure, but that is unsuitable for tourniquet application. The weakness of our study design was that the animals were not randomized.

In some previous studies, zeolite was found to be effective in reducing blood loss or hemostasis time.^[7,10] In these studies, researchers poured the granular form of the zeolite material into the surgical cavity directly on the bleeding artery. In our study, we used QC-ACS[®], which is a fabric sponge form of the material. Alam et al.^[7] suggested that packaging zeolite in fabric pouches acted as a barrier and decreased its effectiveness. However, we found that zeolite material packed in fabric sponges more effectively acted in reducing blood loss when compared with the control group. Further studies are needed to compare the effectiveness of both sponge and powder forms of zeolite.

As presented in previous studies,^[7-10] the application of zeolite causes a significant exothermic reaction with increasing wound temperature. In these studies, researchers observed transmural necrosis of veins, focal areas of necrosis involving adventitia and media in arteries, and focal degeneration and necrosis in peripheral nerves, because of this exothermic effect.^[8,9] We also demonstrated in this study increasing wound temperature with a limited arterial and muscle injury and a mild nerve tissue injury, without any demonstrable venous tissue injury. We did not observe any necrosis as reported previously. Therefore, we concluded that application of zeolite did not lead to an extensive tissue injury in the short-term. However, we do not know the long-term effect of zeolite on the applied tissues. There is insufficient data regarding the thermal effects of zeolite in human studies. QC-ACS[®] was recently reported in an uncontrolled descriptive study to be effective in clinical use for civilian and military trauma.^[13] Further, there is a new form of zeolite that does not produce exothermic reaction.^[14] This new form low-temperature bagged formulation is called QC-ACS[®]. However, there is not yet enough data for use of this new form in clinical practice.

In conclusion, we found that the zeolite hemostatic material (QC-ACS[®]) in a swine model of penetrating femoral vascular injury reduced blood loss and improved physiological parameters and hemodynamic variables, without significant tissue damage in the short-term. However, these findings should be re-evaluated in further controlled clinical studies.

REFERENCES

1. Sauaia A, Moore FA, Moore EE, Moser KS, Brennan R, Read RA, et al. Epidemiology of trauma deaths: a reassessment. *J Trauma* 1995;38:185-93.
2. Recinos G, Inaba K, Dubose J, Demetriades D, Rhee P. Local and systemic hemostatics in trauma: a review. *Ulus Travma Acil Cerrahi Derg* 2008;14:175-81.
3. Eryilmaz M, Menten O, Ersoy G, Durusu M, Rodoplu U, Bilgic S, et al. Topikal hemostatik ajanların travmalı olgularında güncel kullanım esasları. *Türkiye Acil Tıp Dergisi* 2007;7:179-82.
4. Alam HB, Burris D, DaCorta JA, Rhee P. Hemorrhage control in the battlefield: role of new hemostatic agents. *Mil Med* 2005;170:63-9.
5. Pusateri AE, Delgado AV, Dick EJ Jr, Martinez RS, Holcomb JB, Ryan KL. Application of a granular mineral-based hemostatic agent (QuikClot) to reduce blood loss after grade V liver injury in swine. *J Trauma* 2004;57:555-62.
6. Alam HB, Uy GB, Miller D, Koustova E, Hancock T, Inocencio R, et al. Comparative analysis of hemostatic agents in a swine model of lethal groin injury. *J Trauma* 2003;54:1077-82.
7. Alam HB, Chen Z, Jaskille A, Querol RI, Koustova E, Inocencio R, et al. Application of a zeolite hemostatic agent achieves 100% survival in a lethal model of complex groin injury in Swine. *J Trauma* 2004;56:974-83.
8. Acheson EM, Kheirabadi BS, Deguzman R, Dick EJ Jr, Holcomb JB. Comparison of hemorrhage control agents applied to lethal extremity arterial hemorrhages in swine. *J Trauma* 2005;59:865-75.
9. Wright JK, Kalns J, Wolf EA, Traweek F, Schwarz S, Loeffler CK, et al. Thermal injury resulting from application of a granular mineral hemostatic agent. *J Trauma* 2004;57:224-30.
10. Pusateri AE, Delgado AV, Dick EJ Jr, Martinez RS, Holcomb JB, Ryan KL. Application of a granular mineral-based hemostatic agent (QuikClot) to reduce blood loss after grade V liver injury in swine. *J Trauma* 2004;57:555-62.
11. Champion HR, Bellamy RF, Roberts CP, Leppaniemi A. A profile of combat injury. *J Trauma* 2003;54(5 Suppl):S13-9.
12. Pusateri AE, Holcomb JB, Kheirabadi BS, Alam HB, Wade CE, Ryan KL. Making sense of the preclinical literature on advanced hemostatic products. *J Trauma* 2006;60:674-82.
13. Rhee P, Brown C, Martin M, Salim A, Plurad D, Green D, et al. QuikClot use in trauma for hemorrhage control: case series of 103 documented uses. *J Trauma* 2008;64:1093-9.
14. Ahuja N, Ostomel TA, Rhee P, Stucky GD, Conran R, Chen Z, et al. Testing of modified zeolite hemostatic dressings in a large animal model of lethal groin injury. *J Trauma* 2006;61:1312-20.