

Comparison of percutaneous gallbladder aspiration with percutaneous cholecystostomy in acute cholecystostomy patients. Can gall bladder aspiration alone be sufficient?

Ümmihan Topal, M.D.,¹ Süleyman Sönmez, M.D.,¹ Sevinç Dağistanlı, M.D.,²

¹Department of Radiology, Kanuni Sultan Süleyman Training and Research Hospital, Istanbul-Türkiye

²Department of General Surgery, Kanuni Sultan Süleyman Training and Research Hospital, Istanbul-Türkiye

ABSTRACT

BACKGROUND: The aim of this study is to compare the efficacy and complication rates of percutaneous gallbladder aspiration (PA) and percutaneous cholecystostomy (PC) in the management of AC and present the experiences of a single third-line center.

METHODS: The results of 159 patients with AC who admitted to our hospital between 2015 and 2020, that underwent PA and PC procedures, because they did not respond to conservative treatment and LC could not be performed, were retrospectively analyzed. Clinical and laboratory data before and 3 days after PC and PA procedure, technical success, complications, response to treatment, duration of hospital stay, and reverse transcriptase-polymerase chain reaction (RT-PCR) test results were recorded.

RESULTS: Out of 159 patients, 22 (8 men 14 women) underwent PA procedure and 137 (57 men 80 women) underwent PC. No significant difference was detected between the PA and PC groups in terms of clinical recovery (P:0.532) and duration of hospital stay (P:0.138) in 72 h. The technical success of both procedures was 100%. While 20 out of 22 patients with PA were having a noticeable recovery, only one was treated with twice PA procedures and a complete recovery was observed (4.5%). Complication rates were low in both groups and were statistically insignificant (P:1.00).

CONCLUSION: In this pandemic period, PA and PC procedures are effective, reliable, and successful treatment method that can be applied at the bedside for critical patients with AC who are not compatible with surgery, which are safe for health workers and low-risk minimal invasive procedures for patients. In uncomplicated AC patients, PA should be performed, and if there is no response to treatment, PC should be reserved as a salvage procedure. The PC procedure should be performed in patients with AC who have developed complications and are not suitable for surgery.

Keywords: Acute cholecystitis; percutaneous transhepatic gallbladder aspiration; percutaneous transhepatic gallbladder drainage.

INTRODUCTION

Acute cholecystitis (AC) is the inflammation of the GB. The diagnostic criteria for AC include the right upper quadrant pain or sensitivity, leukocytosis, and/or high C-reactive protein (CRP) levels, and at least one of the imaging findings (distended GB, GB wall thicker than 3 mm or debris in the GB).^[1-6] Most of these cases have AC, which is caused by the occlusion of the cystic duct or GB neck by gallstones.

^[2,5] AC is often seen in 0.2–0.4% of critical patients with GB stasis and/or GB ischemia.^[6] The main treatment approach for AC is early cholecystectomy.^[1-3] However, some patients with AC are surgical high-risk candidates when accompanied with comorbidities, sepsis, or septic shock. Percutaneous cholecystostomy (PC) with high technical and clinical success rate is used when no response to conservative treatment is available.^[3,4] Perkutan GB aspiration (PA) is one of the GB drainage methods. PA and PC are minimally invasive proce-

Cite this article as: Topal U, Sonmez S, Dagistanli S. Comparison of percutaneous gall bladder aspiration with percutaneous cholecystostomy in acute cholecystostomy patients. Can gallbladder aspiration alone be sufficient? *Ulus Travma Acil Cerrahi Derg* 2023;29:582-589.

Address for correspondence: Ummihan Topal, M.D.

Kanuni Sultan Süleyman Eğitim ve Araştırma Hastanesi, Radyoloji Bölümü, İstanbul, Türkiye

E-mail: drummihan_tpll@outlook.com

Ulus Travma Acil Cerrahi Derg 2023;29(5):582-589 DOI: 10.14744/tjtes.2022.36443 Submitted: 06.07.2022 Revised: 26.07.2022 Accepted: 09.10.2022
OPEN ACCESS This is an open access article under the CC BY-NC license (<http://creativecommons.org/licenses/by-nc/4.0/>).



dures that can be performed at the bedside under ultrasound guidance.^[1,5] Bile drainage improves the general condition of patients by causing decompression of the GB and reducing edema and inflammation of the GB wall. A small number of studies have been published on the results and complications associated with the PA. During LC, the surgical team is at risk of viral infection.^[7] Especially during the current and ongoing pandemic period, health workers need procedures that are safe and provide rapid recovery for patients. Our goal is to compare the PA procedure for critical patients with AC with the PC procedure to show that it is effective and reliable.

MATERIALS AND METHODS

Study Design

The retrospective observational study has been approved by the Ethics Committee of our hospital. Retrospectively, interventional radiology (IR) electronic medical records were reviewed. One hundred and fifty-nine patients who applied to our hospital from August 2015 to December 2020 who did not respond to conservative treatment or who could not undergo LC and who performed PA and PC procedures were included in the study. Patients with non-complicated AC and patients with complications such as pericholecystic liver abscess, partial rupture of GB, and necrotizing GB were included in the study. Patients with severe coagulopathy or no informed approval, who came to our unit for PA or PC procedure and returned to their centers immediately after the procedure were not included in the study. In addition, patients with high liver enzyme levels and ascites were not included in the study.

Demographic data of patients with the PC and PA procedure have been noted. Clinical and laboratory data (fever, pain, and CRP) and white blood cell (WBC) were compared with before the PC and PA procedure and after 3rd day of procedure, in terms of technical success of the PC and PC procedure, complications, treatment response, length of hospital stay, and postprocedural monthly observation. Culture samples obtained by PC and PA were determined for reproduction. The GB has been noted for stones or biliary sludge. It was recorded whether cholecystectomy was performed within 1 month after the PC and PA procedure. In 3 days, clinical recovery (normalization of the fever and loss of pain) and normalization of the WBC value were considered to be successful in the procedure.

The results of the reverse transcriptase-polymerase chain reaction (RT-PCR) test were taken into account for patients who applied to our hospital during this period, although not primary study, as our working range covers a year of pandemic period.

PA and PC Procedure

Bedside PA or PC procedure was performed in patients with newly developing AC while they were being followed up in the intensive care unit.

Patients with AC with COVID-19 RT-PCR test positive were admitted to isolation services, patients with RT-PCR test negative AC were admitted to related services. The oral intake of the patients was stopped and the treatment of intravenous antibiotics was started by the specialized physicians of the relevant clinic. Patients with AC who have not improved between 1 and 5 days after the treatment were sent to the IR department with the request for a PC or PA.

Before the pandemic, patients with negative COVID-19 were prepared for standard surgery. The RT-PCR test positive patients were given a PC or PA procedure, both at the bedside in the intensive care unit and in the IR unit, wearing personal protective equipment (water and virus-proof coveralls, N95 masks, gowns, safety glasses, and sterile gloves).

PA was performed by transhepatic puncture of the GB with an 18 gauge needle under local anesthesia. Then, it was taken 8–10 cc of GB content and sent for culture and cytology. Almost all of the contents of the GB were aspirated by the PA procedure. The GB lumens were washed with saline, the injections were removed and the procedure was terminated. PA was performed by transhepatic puncture of the GB with an 18 gauge needle under local anesthesia. Then, it was taken 8–10 cc of GB content and sent for culture and cytology. The guide wire was then sent from the needle to the GB lumen. Needle removed, the tract extended with dilators through guide wire. Pigtail drainage catheter locked through guide wire (8 or 10 Franch) placed in GB lumen. The catheter is placed on the skin. For free drainage, the end is connected to the drainage bag. The transperitoneal pathway was used in patients with bleeding disorders. Both procedures were carried out by trained interventional radiologists.

During the pandemic period, bedside PC and PA procedures were performed for COVID-positive patients in COVID services and patients with AC in the intensive care unit.

Catheter removal was performed in non-operated patients, but not earlier than 3 weeks, after tract maturation, confirming cystic duct patency by scopy (contrast material from the catheter) and clinical improvement. PA procedure was repeated when the complaints in the follow-up patients were not regressed and hydrops were redeveloped in the GB. However, the PC procedure was performed on patients who did not respond to the PA procedure twice.

Patients who have been treated with oral antibiotics were discharged and were followed weekly in both general surgery and IR clinics. Elective surgery was scheduled within 6 weeks at the latest for the patients whose general conditions were suitable for surgery in both the PA and PC groups.

Statistical Analysis

Descriptive statistics were used to describe continuous variables (mean, standard deviation, minimum, median, and max-

imum). Categorized variables are defined using frequency (n) and percentages. Normal dispersion of continuous variables has been reviewed by the Shapiro–Wilks test. The comparison of two independent and non-normally distributed variables was made with the Mann–Whitney U-test. The relationship between categorical data was examined using the Chi-square test (or Fisher Exact test/Yates continuity correction where appropriate). The level of statistical significance is 0.05. Analysis was carried out using MedCalc® Statistical Software version 19.7.2 (MedCalc Software Ltd, Ostend, Belgium; <https://www.medcalc.org>; 2021).

RESULTS

Demographic Properties of All Patients

Out of 159 patients, 22 (8 men 14 women) underwent PA procedure and 137 (57 men 80 women) underwent PC. There were no statistically significant differences between the PA and PC groups in terms of gender distribution and age (P: 0.797 and P: 0.439, respectively) (Table 1).

Comparison of Groups and Evaluation of Results

CRP (mg/dL) initial median value median 165 (range 10–332) in PA group, median 147 (range 5–493) found in PC group, and no statistically significant difference was detected (P: 0.6132). WBC ($\times 10^3/\mu\text{L}$) initial median value was found in PA group 10.5 (range 5–24), PC group 12.9 (range 2.90–36). Statistically no significant difference (p:0.091) was detected. There was no significant difference between PA and PC groups for acalculous AC and calculosis AC type (P: 1.00) (Table 1, Figures 1 and 2).

No significant difference was detected between the PA and

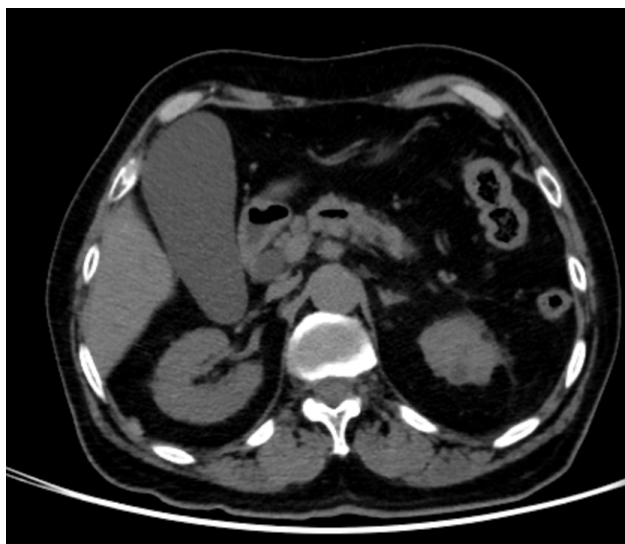

Figure 1. Acalculous acute cholecystitis. A 79-year-old male patient was admitted to the emergency department with the right upper quadrant pain. Contrast-enhanced computed tomography shows hydrops in the gallbladder and an increase in the gallbladder wall thickness (arrows). A single session percutaneous gallbladder aspiration was performed. Two days later, the patient was discharged

PC groups in terms of clinical recovery (P: 0.532) and length of hospital stay (P: 0.138) in 72 h. The technical success of the PA and PC procedure was 100%. No significant difference was found in terms of complications in both groups (Table 2). The length of hospital stay was found to be median 3 (range 1–12) in the PA group and 3 (range 1–30) in the PC group, and no statistically significant difference was found (P: 0.1381) (Table 3 and Fig. 1).

Twenty out of 22 patients with PA were noticeable improve-

Table 1. Comparison of patient characteristics for PA and PC processing

| | PA | PC | P-value |
|--|--------------|----------------|--------------------|
| Age ¹ | 68.5 (43–91) | 68 (16–93) | 0.439 ² |
| Gender n (%) | | | |
| Male | 8 (36.4) | 57 (42.3) | 0.797 ³ |
| Female | 14 (63.6) | 80 (57.7) | |
| CRP (mg/dL) admission value ¹ | 165 (10–332) | 147 (5–493) | 0.613 ² |
| WBC ($\times 10^3/\mu\text{L}$) admission value ¹ | 10.5 (5–24) | 12.9 (2.90–36) | 0.091 ² |
| Acute cholecystitis type (%) | | | |
| Acalculous cholecystitis | 20 (90.9) | 120 (87.6) | 1.00 ⁴ |
| Calculous cholecystitis | 13 (59.1) | 105 (76.6) | |
| Bile culture result (%) | | | 0.868 ³ |
| Positive | 7(50) | 33 (43.1) | |
| Negative | 7(50) | 33 (56.9) | |

¹med (min–maks); ²Mann–Whitney U-test; ³Yates Continuity Correction; ⁴Fisher Exact test.

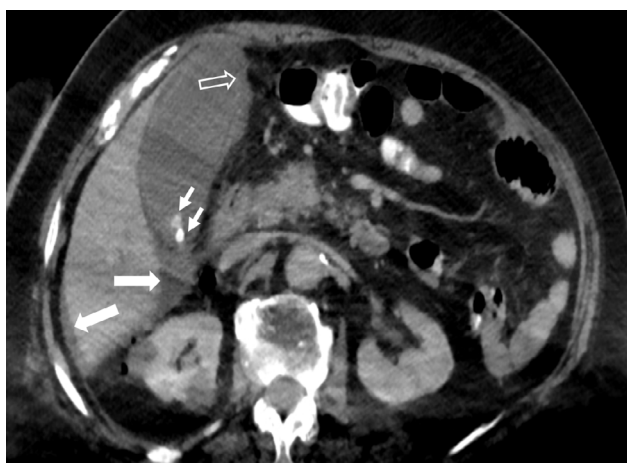

Figure 2. Calculus acute cholecystitis. An 84-year-old male patient. He was admitted to the emergency department due to chills, shivering, and abdominal pain that had started 2 days ago. Contrast-enhanced computed tomography shows hydrops in the gallbladder. Millimetric hyperdense structures representing stones (small arrows) are seen at the level of the gallbladder neck. Irregularities in the wall, especially at the level of the fundus of the gallbladder, are striking (hollow arrow). A small amount of fluid (large arrows) is noted in the pericholecystic and perihepatic areas. Percutaneous gallbladder drainage was performed. The patient, who developed low saturation during the follow-up, was admitted to the intensive care unit. She was discharged after staying in the intensive care unit for 4 days

ment, but only one was performed 2 times and a complete recovery was observed (4.5%). Since CRP continued to rise again after 72 h in four patients, they were switched to PC after PA (18.2%).

The technical success was 100% in both groups. Complications rates were found to be low in both groups and were not statistically insignificant ($P: 1.00$).

LC was not performed within 1 month for any patient, including PA group, but was performed on four patients (2.9%) in the PC group.

DISCUSSION

There was no significant difference between the groups undergoing PA and PC procedures in terms of first-admission laboratory findings. There was no significant difference between acalculous AC and calculous AC type in both groups. However, in patients who were included in the PC group, the number of patients with complications, such as rupture AC, pericholecystic abscess, and emphysematous cholecystitis, was higher at the time of first application, especially during the year containing pandemic (Figures 2-4). The technical success was 100% in both groups. The complication rates were low in both groups and were statistically insignificant. In both groups, clinical recovery and hospitalization times were similar in 72 h. No group developed serious complications such as biliar peritonitis and acute bleeding. The most frequently observed complication in the PC group was the dislocation of the catheter. This situation was observed mostly in obese and elderly patients with lack of compatibility.

Treatment of AC is conservative. However, LC continues to be the gold standard in patients who do not respond to treatment, whose symptoms last longer than 72 h, and who have a low American Society of Anesthesiologists score. LC complications and conversion rates to open cholecystectomy increase as adhesions are expected to develop in patients with AC whose symptoms have persisted for more than 72 h. Kiviluoto et al. reported that in 16% of post-LC patients had converted to open cholecystectomy.^[8] PC has been a successful and effective treatment option in patients who cannot undergo LC due to comorbid diseases and do not respond to conservative treatment.^[9-11]

Table 2. Comparison of technical success-complications of PA and PC procedures and evaluations of response to treatment

| n (%) | PA | PC | P-value |
|---|-----------|------------|--------------------|
| 72-h clinical recovery | | | |
| Yes | 20 (90.9) | 112 (81.8) | 0.532 ² |
| No | 2 (9.1) | 23 (16.8) | |
| Duration of hospitalization (days) ³ | 3 (1-12) | 3 (1-30) | 0.138 ¹ |
| Technical success | | | |
| Yes | 22 (100) | 137 (100) | - |
| No | 0 | 0 | |
| Complications | | | 1.00 ² |
| Yes | 1 (4.5) | 5 (3.6) | |
| No | 21 (95.5) | 132 (96.4) | |

¹med (min-maks); ²Mann-Whitney U-test; ³Yates Continuity Correction; ⁴Fisher Exact test.

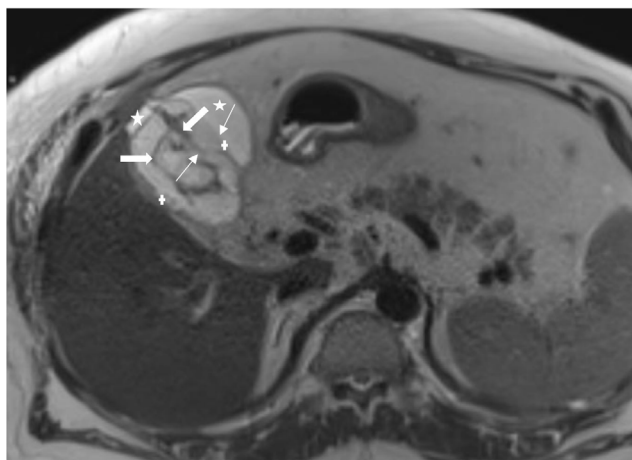


Figure 3. Delayed rupture of acute gangrenous cholecystitis. A 60-year-old male patient. He was admitted to the emergency room with the right upper quadrant pain during the pandemic period. Hydropic gallbladder showing gangrenous cholecystitis (distance between + signs), wall irregularities (thin arrows) are observed on axial T2-weighted MRI. Intraluminal intensities (thick arrows) represent exfoliated mucosa. It is also accompanied by pericholecystic free fluid (stars). The patient was treated by placing a separate drainage catheter in both the gallbladder lumen and the pericholecystic free fluid. He was discharged 5 days later

Since patients undergoing PC are discharged with drainage catheters after clinical recovery, they are open to undesirable situations such as discomfort in the patients and dislocation of the catheter with patient movements. In a study by Tsutsui et al., they reported that 32 of 45 patients achieved recovery with PA at once. Success was achieved in 11 of the remaining 13 patients following the second application of PA. They did not detect any other serious complication related to PA in any of the patients.^[12]

Table 3. Length of hospitalization (number of discharge days)

| n (%) | PA | PC | PA+PC |
|---|-----------|------------|------------|
| 1 day | 3 (13.6) | 5 (3.6) | 8 (5) |
| 2 days | 3 (13.6) | 23 (16.8) | 26 (16.4) |
| 3 days | 11 (50) | 52 (38) | 63 (39.6) |
| 4 days | 0 | 24 (17.5) | 24 (15.1) |
| Total number of patients discharged in the first 4 days | 17 (77.2) | 104 (75.9) | 121 (76.1) |

In our study, significant clinical recovery was observed in 20 (90.9%) of 22 patients who underwent PA. Only one underwent twice PA procedures and showed complete recovery (4.5%). Since CRP continued to rise again after 72 h in four patients, they were returned to PC after PA (18.2%). Pericholecystic collection developed in only one patient (4.5%), and the PC procedure was performed because clinical response could not be obtained. No mortality was observed in any of our patients in both groups.

In a study by Komatsu et al., 65.3% of 147 patients with AC stated that a single PA was sufficient. Of the remaining 51 patients, 29.3% showed improvement after repeated administration of PA and/or PC. Two of the five patients had intra-abdominal bleeding, two had bile leakage, and one had GB bleeding. However, none of the patients found mortality due to treatment-related complications.^[5]

In a study by Haas et al., in which 33 patients were included, the PA procedure was found to be successful in 25 patients (76%) in a single session. The PA procedure was repeated in

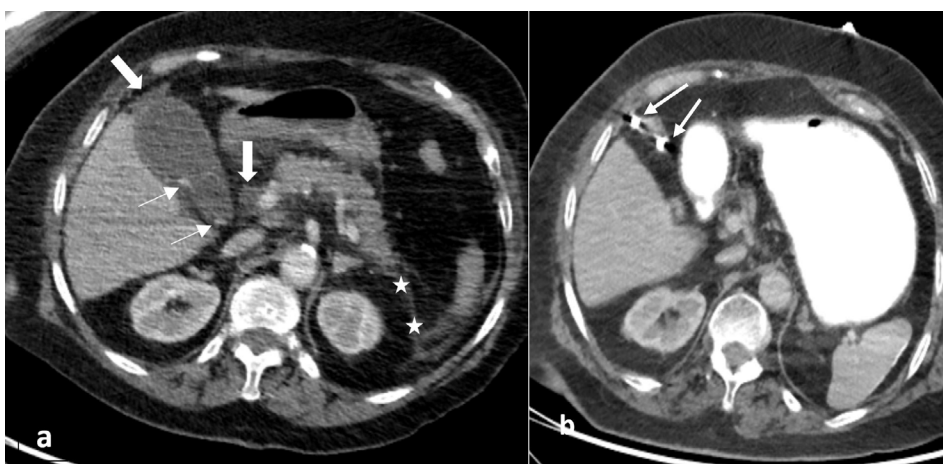


Figure 4. Acute calculous cholecystitis caused by biliary acute pancreatitis. A 45-year-old female patient presented to the emergency department with the right upper quadrant pain. Computed tomography (a) shows gallbladder wall thickening, hydrops, and calculous opacities in its lumen (thin arrows). Poorly limited free fluid and thickening are observed at the level of the anterior perirenal fascia on the left, adjacent to the gallbladder fundus and pancreatic head (thick arrows). The patient was treated with the percutaneous cholecystostomy method (b). Arrows demonstrate drainage catheter.

seven patients. Eight patients (24%) showed no improvement and PC was applied. They did not report any complications related to the PA procedure. They found the LC conversion rate of 4.3%. They stated that PA is a successful and effective method, because it is reproducible and allows safe interval laparoscopic surgery. In our study, the rate of LC in the 1st month was 0% in the PA group and 4 (2.9%) in the PC group.^[1]

Ito et al. reported that PC and PA were 100% and 82% technically successful, respectively. The procedure was found to be unsuccessful in 18% of patients in the PA group. They found that 90% in the PC group and 61% in the GB aspiration group had good clinical response. No major complications were detected in either group. As a minor complication, the catheter displaced in one patient in the PC group. They stated that minor bleeding occurred in the PA group. They stated that PC is superior to PA in terms of clinical efficacy in severe AC.^[13]

Chopra et al. achieved technical success in 97% and 97% of patients in the PA and PC groups, respectively. Of these, 77% and 90% received clinical response within 72 h. While 12% complications occurred in the PC group, they did not detect any complications in the PA group. They emphasized that the clinical results of PA and PC were similar in patients with high surgical risk who were not critically ill in the treatment of AC. It has been emphasized that PA may be preferred in high-risk patients with AC who are not critically ill, and that PC should be retained as a rescue procedure in case PA fails technically or clinically.^[14]

The past 1 year of our work included the first period of pandemic. We applied PA to a patient who was hospitalized in the isolation service due to COVID-19 and we achieved a successful result. We performed a PA procedure on a patient who developed AC while being followed in intensive care unit. The AC findings have been corrected radiologically. However, the patient connected to the mechanical ventilator died due to respiratory failure and heart failure. During this pandemic, there were only two aspirations. We chose the PC procedure because patients with AC were more complex during the pandemic period (ruptured AC, pericholecystic abscess, emphysematous cholecystitis, metastatic ruptured AC, etc.). Another study by our center during the pandemic period proved the effectiveness of the PC procedure.^[15-22] Since the past year of the study coincided with the pandemic period (2020), when we look back, severe acute respiratory syndrome (SARS-CoV) (COVID-19) disease began to spread rapidly throughout the world in the city of Wuhan, China at the end of 2019. It was the most important public health issues faced by healthcare workers struggling with COVID-19, and the risk of getting COVID-19 disease among healthcare workers was higher than the normal population.^[16] There was an extraordinary increase in patients in hospitals. Our hospital was quickly converted into one of the central pandemic hospitals. Intensive care units are quickly filled with COVID-19 patients. Furthermore, the operating table was

revised for COVID-19 patient admission, except for a few desks reserved for emergencies. A lot of elective surgical procedures have been delayed. Although LC is the gold standard in patients suitable for surgery with AC, blood-borne viruses were found in the smoke produced by electrocautery during LC and other abdominal surgery, and SARS-Cov-2 RNA was detected in the peritoneal cavity. Considering the patient load, most surgical centers supported minimally invasive procedures, since all centers do not have a virus-permeable, quality evacuation filter system that prevents the risk of infection by the surgical team during abdominal gas evacuation.^[6,17,18] This has caused an increase in the number of IR procedures. PC and PA have proven to be an effective, cheap, and safe treatment method for healthcare professionals.^[19-22] Furthermore, post-operative pulmonary complications were reported to have increased and associated with high mortality, especially with older patients with a perioperative SARS-COV-2 infection. Therefore, we think percutaneous treatments can be the best treatment strategy, especially in AC patients with COVID-19 positive during pandemic. Despite all this, patients with AC who are suitable for surgery should not be deprived of LC even in the period of COVID-19.^[22,23] During the pandemic period, no health worker was infected by the process during PA and PC procedures.

As for the limitations of our work, as well as a retrospective study, the postprocedural follow-up period is one month. In addition, the number of patients with cancer was low. The number of patients in the PA group was less than the PC group. It was only a year of the pandemic period, since we provided our single-centric 5-year experience. While the PC proves its effectiveness in pandemic and pre-pandemic period, new studies are needed for the PA during the pandemic period.

Conclusion

In the current and ongoing pandemic period, health workers need minimal invasive procedures that are safe and effective at low risk for patients, ensuring reliable, and rapid recovery. The PA and PC procedure for critical patients with AC, especially not eligible for surgery, is an effective, reliable and successful treatment method that can be applied at the bedside. In uncomplicated AC patients, PA should be administered and if there is no response to treatment, PC must be stored as a recovery procedure. For patients with AC patients who are not suitable for surgery with complications, the PC procedure must be applied.

Ethics Committee Approval: This study was approved by the Kanuni Sultan Süleyman Training and Research Hospital Ethics Committee (Date: 22.04.2021, Decision No: 2021.04.136)

Peer-review: Externally peer-reviewed.

Authorship Contributions: Concept: Ü.T.; Design: Ü.T., S.S.; Supervision: Ü.T.; Materials: Ü.T.; Data: Ü.T., S.D.; Anal-

ysis: Ü.T.; Literature search: Ü.T.; Writing: Ü.T.; Critical revision: Ü.T.

Conflict of Interest: None declared.

Financial Disclosure: The authors declared that this study has received no financial support.

REFERENCES

- Haas I, Lahat E, Griton Y, Shmulevsky P, Shichman S, Elad G, et al. Percutaneous aspiration of the gall bladder for the treatment of acute cholecystitis: A prospective study. *Surg Endosc* 2016;30:1948–51.
- Lo CM, Liu CL, Fan ST, Lai EC, Wong J. Prospective randomized study of early versus delayed laparoscopic cholecystostomy for acute cholecystitis. *Ann Surg* 1998;227:461–7. [CrossRef]
- Cirocchi R, Kwan SH, Popivanov G, Ruscelli P, Lancia M, Gioia S, et al. Routine drain or no drain after laparoscopic cholecystectomy for acute cholecystitis. *Surgeon* 2021;19:167–74. [CrossRef]
- Yokoe M, Hata J, Takada T, Strasberg SM, Asbun HJ, Wakabayashi G, et al. Tokyo Guidelines 2018: Diagnostic criteria and severity grading of acute cholecystitis (with videos). *J Hepatobiliary Pancreat Sci* 2018;25:41–54. [CrossRef]
- Komatsu S, Tsuchida S, Tsukamoto T, Wakahara T, Ashitani H, Ueno N, et al. Current role of percutaneous transhepatic gallbladder aspiration: From palliative to curative management for acute cholecystitis. *J Hepatobiliary Pancreat Sci* 2016;23:708–14. [CrossRef]
- Kwak HD, Kim SH, Seo YS, Song KJ. Detecting hepatitis B virus in surgical smoke emitted during laparoscopic surgery. *Occup Environ Med* 2016;73:857–63. [CrossRef]
- Li CI, Pai JY, Chen CH. Characterisation of smoke generated during the use of surgical knife in laparotomy surgeries. *J Air Waste Manag Assoc* 2020;70:324–32. [CrossRef]
- Kiviluoto T, Siren J, Luukkonen P, Kivilaakso E. Randomized trial of laparoscopic versus open cholecystectomy for acute and gangrenous cholecystitis. *Lancet* 1998;351:321–5. [CrossRef]
- Paran H, Zissin R, Rosenberg E, Griton I, Kots E, Gutman M. Prospective evaluation of elective cholecystectomy after percutaneous cholecystostomy. *Int J Surg* 2006;4:101–5. [CrossRef]
- Patel M, Miedema BW, James MA, Marshall JB. Percutaneous cholecystostomy is an effective treatment for high-risk patients with acute cholecystitis. *Am Surg* 2000;66:33–7. [CrossRef]
- Abraham S, Toth I, Benko R, Matuz M, Kovács G, Morvay Z, et al. Surgical outcome of percutaneous transhepatic GB drainage in acute cholecystitis: Ten years' experience at a tertiary care centre. *Surg Endosc* 2021;36:2850–60. [CrossRef]
- Tsutsui K, Uchida N, Hirabayashi S, Kamada H, Ono M, Ogawa M, et al. Usefulness of single and repetitive percutaneous transhepatic gallbladder aspiration for the treatment of acute cholecystitis. *J Gastroenterol* 2007;42:583–8. [CrossRef]
- Ito K, Fujita N, Noda Y, Kobayashi G, Kimura K, Sugawara T, et al. Percutaneous cholecystostomy versus gallbladder aspiration for acute cholecystitis: A prospective randomized controlled trial. *AJR Am J Roentgenol* 2004;183:193–6. [CrossRef]
- Chopra S, Dodd GD 3rd, Mumbower AL, Chintapalli KN, Schwesinger WH, Sirinek KR, et al. Treatment of acute cholecystitis in non-critically ill patients at high surgical risk: Comparison of clinical outcomes after GB aspiration and after percutaneous cholecystostomy. *AJR Am J Roentgenol* 2001;176:1025–31. [CrossRef]
- Zhan M, Qin Y, Xue X, Zhu S. Death from covid-19 of 23 health care workers in China. *N Engl J Med* 2020;382:2267–8. [CrossRef]
- Coccolini F, Tartaglia D, Puglisi A, Giordano C, Pistello M, Lodato M, et al. SARS-CoV-2 is present in peritoneal fluid in COVID-19 patients. *Ann Surg* 2020;272:e240–2. [CrossRef]
- Alp E, Bijl D, Bleichrodt RP, Hansson B, Voss A. Surgical smoke and infection control. *J Hosp Infect* 2006;62:1–5. [CrossRef]
- Moletta L, Pierobon ES, Capovilla G, Costantini M, Salvador R, Merigliano S, et al. International guidelines and recommendations for surgery during Covid-19 pandemic: A systematic review. *Int J Surg* 2020;79:180–8. [CrossRef]
- Al-Jabir A, Kerwan A, Nicola M, Alsafi Z, Khan M, Sohrabi C, et al. Impact of the coronavirus (COVID-19) pandemic on surgical practice. *Int J Surg* 2020;79:168–79. [CrossRef]
- Zhong J, Datta A, Gordon T, Adams S, Guo T, Abdelaziz M, et al. Impact of COVID-19 on IR services in the UK. *Cardiovasc Intervent Radiol* 2021;44:134–40. [CrossRef]
- Somuncu E, Kara Y, Kızılkaya MC, Bozdağ E, Yıldız ZB, Özkan C, et al. Percutaneous cholecystostomy instead of laparoscopy to treat acute cholecystitis during the COVID-19 pandemic period: Single center experience. *Ulus Travma Acil Cerrahi Derg* 2021;27:89–94. [CrossRef]
- COVID Surg Collaborative. Mortality and pulmonary complications in patients undergoing surgery with perioperative SARS-CoV-2 infection: An international cohort study. *Lancet* 2020;396:27–38. [CrossRef]
- Barabino M, Piccolo G, Trizzino A, Fedele V, Ferrari C, Nicastro V, et al. COVID-19 outbreak and acute cholecystitis in a hub hospital in Milan: Wider indications for percutaneous cholecystostomy. *BMC Surg* 2021;21:180. [CrossRef]

ORIJİNAL ÇALIŞMA - ÖZ

Akut kolesistitli hastalarda perkütan safra kesesi aspirasyonunun perkütan kolesistostomi ile karşılaştırılması. Sadece safra kesesi aspirasyonu yeterli olabilir mi?

Dr. Ümmihan Topal,¹ Dr. Süleyman Sönmez,¹ Dr. Sevinc Dağistanlı²

¹Kanuni Sultan Süleyman Eğitim ve Araştırma Hastanesi, Radyoloji Bölümü, İstanbul

²Kanuni Sultan Süleyman Eğitim ve Araştırma Hastanesi, Genel Cerrahi Kliniği, İstanbul

AMAÇ: Bu çalışmanın amacı, akut kolesistitin (AK) yönetiminde, perkütan safra kesesi aspirasyonu (PA) ile perkütan kolesistostomi'nin (PK) tedavideki etkinliklerini, komplikasyon oranlarını karşılaştırarak 3. basamak tek bir merkezin tecrübelerini sunmaktır.

GEREÇ VE YÖNTEM: 2015 ve 2020 tarihleri arasında hastanemize başvuran AC'li hastalardan konservatif tedaviye cevap vermeyen, LC uygulanamayan PA ve PC prosedürleri uygulanan 159 hastanın sonuçları geriye dönük incelendi. PC ve PA prosedüründen önceki ve işlemden sonra 3. günde klinik ve laboratuvar verileri, teknik başarı, komplikasyon, tedaviye yanıt, hastanede kalış süreleri, reverse transcriptase-polymerase chain reaction (RT-PCR) testinin sonucu kaydedildi.

BULGULAR: Toplam 159 hastanın 22'sine (8 erkek, 14 kadın) PA ve 137'sine (57 erkek, 80 kadın) PC prosedürü uygulandı. PA ve PC grupları arasında 72 saatte klinik iyileşme ($p=0.532$) ve hastanede kalış süreleri ($p=0.138$) açısından anlamlı farklılık saptamadı. Her iki prosedürünün teknik başarıları %100 idi. PA uygulanan 22 hastanın 20'sinde belirgin düzelme olurken sadece birine 2 kez yapıldı ve tamamen iyileşme görüldü (%4.5). Komplikasyon oranları her iki grupta düşük bulundu ve istatistiksel olarak anlamlı değildi ($p=1.00$).

TARTIŞMA: İçinde bulunduğumuz pandemi döneminde sağlık çalışanları için güvenli, hastalar için düşük riskli minimal invaziv prosedürler olan PA ve PC cerrahiye uygun olmayan AK'li kritik hastalarda yatak başında uygulanabilen etkin, güvenilir başarılı bir tedavi yöntemidir. Komplikasyon geliştirmemiş AK li hastalarda PA uygulanmalı tedaviye cevap alınmaz ise PC bir kurtarma prosedürü olarak saklanmalıdır. Komplikasyon geliştirmiş cerrahiye uygun olmayan AK li hasta ise PC prosedürü uygulanmalıdır.

Anahtar sözcükler: Akut kolesistit; perkütan transhepatik safra kesesi aspirasyonu; perkütan transhepatik safra kesesi drenajı.

Ulus Travma Acil Cerrahi Derg 2023;29(5):582-589 doi: 10.14744/tjtes.2022.36443