

# Trichophagia as a cause of acute appendicitis in a patient with bipolar disorder

Halit Eren Taşkın, M.D.,<sup>1</sup> Ergin Erginöz, M.D.,<sup>1</sup> Gökçe Hande Çavuş, M.D.<sup>2</sup>

<sup>1</sup>Department of General Surgery, İstanbul University Cerrahpaşa-Cerrahpaşa Faculty of Medicine, İstanbul-Turkey

<sup>2</sup>Department of Pathology, İstanbul University Cerrahpaşa-Cerrahpaşa Faculty of Medicine, İstanbul-Turkey

## ABSTRACT

Acute appendicitis is one of the most common abdominal surgical emergencies worldwide. Clinical diagnosis is possible in most of the cases although imaging modalities may become necessary if the diagnosis is uncertain. Appendectomy, preferably the laparoscopic approach, still remains the gold standard treatment to date. The pathophysiology usually includes luminal obstruction by an appendicolith or lymphoid hyperplasia and rarely parasitic infections. In this report, we present an extremely rare case of a patient with diagnosis of bipolar disorder and a history of trichophagia resulting in trichobezoar formation within the appendiceal lumen leading to acute appendicitis.

**Keywords:** Acute appendicitis; bipolar disorder; trichophagia.

## INTRODUCTION

Acute appendicitis is a common general surgical emergency worldwide that requires prompt and an accurate diagnosis.<sup>[1]</sup> It can often be reliably diagnosed clinically; however, imaging modalities are often necessary to reach a conclusion. The exact cause of acute appendicitis is often multifactorial and most commonly results due to luminal obstruction, although dietary and familial factors have also been suggested previously.<sup>[2-4]</sup> Trichophagia is the ingestion of hair that is mostly associated with trichotillomania.<sup>[5]</sup> This compulsive behavior may lead to a trichobezoar formation, indicating a serious surgical condition. In this report, we present a rare case with a history of bipolar disorder and trichophagia leading to luminal obstruction of vermiform appendix and resulting in acute appendicitis.

## CASE REPORT

A 23-year-old male patient presented to the emergency department with abdominal pain, anorexia, and nausea of 1 day in duration. The pain was initially located in the periumbilical

region that has shifted to the right lower quadrant. The medical history includes bipolar disorder and migraine headaches. The patient takes maprotilin, trifluoperazin, lithium, and olanzapin for medication. Physical examination revealed tenderness on deep palpation of the right lower quadrant and rebound. The obturator and psoas signs were positive. Physical examination was normal. The laboratory parameters were normal except for leukocytosis (white cell count 10,600  $\mu$ L) and an elevated C-reactive protein value of 76.9 mg/L. The abdominal ultrasonography and computerized tomography were taken and the findings were consistent with acute appendicitis (Fig. 1). Laparoscopic appendectomy was performed and the pathologic specimen was confirmed to be acute appendicitis with local inflammatory findings along with hair follicles within the appendix (Figs. 2 and 3). The patient has given consent for this case report to be published.

## DISCUSSION

Acute appendicitis is a common reason for acute abdominal surgery worldwide and prompt diagnosis is essential to minimize morbidity. Usually, the cause of acute appendicitis is due

Cite this article as: Taşkın HE, Erginöz E, Çavuş GH. Trichophagia as a cause of acute appendicitis in a patient with bipolar disorder. *Ulus Travma Acil Cerrahi Derg* 2022;28:554-556.

Address for correspondence: Ergin Erginöz, M.D.

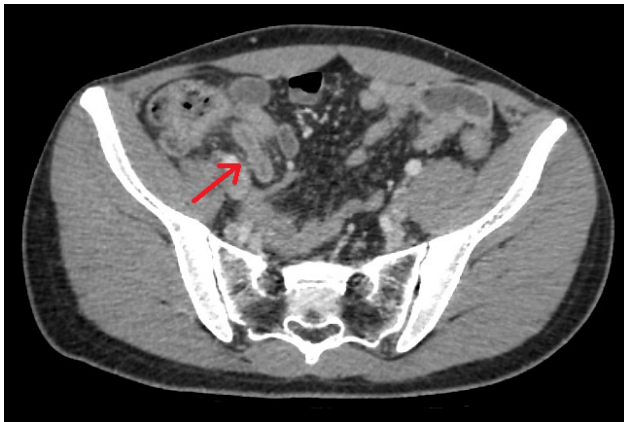İstanbul Üniversitesi Cerrahpaşa - Cerrahpaşa Tıp Fakültesi, Genel Cerrahi Anabilim Dalı, İstanbul, Turkey

Tel: +90 212 - 414 30 00 E-mail: eerginoz@ku.edu.tr

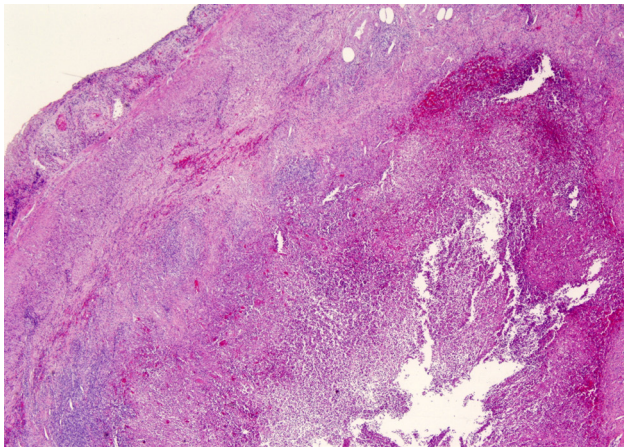
*Ulus Travma Acil Cerrahi Derg* 2022;28(4):554-556 DOI: 10.14744/tjtes.2022.34808 Submitted: 28.08.2021 Accepted: 11.02.2022

Copyright 2022 Turkish Association of Trauma and Emergency Surgery

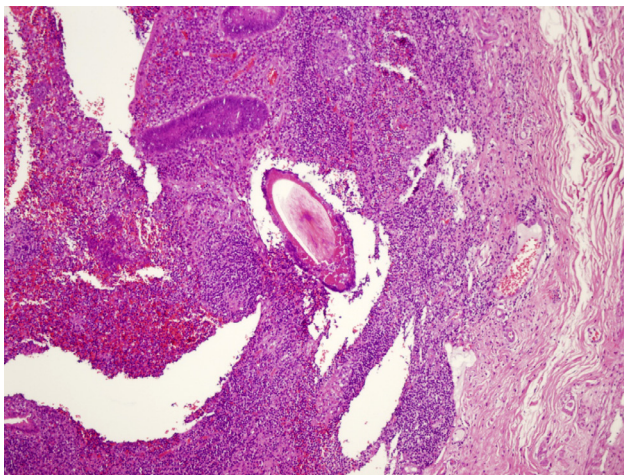




**Figure 1.** The computerized tomography of the patient consistent with acute appendicitis. The signs observed in this patient include an increased appendix diameter of 9 mm, wall thickening, and edema of the appendix wall. Lymphadenopathy surrounding this region was also observed.



**Figure 2. (a)** Acute inflammation of the appendix with local peritonitis (H&E stain,  $\times 40$  magnification).



**Figure 3.** Hair shaft in the appendix lumen (H&E stain,  $\times 100$  magnification).

to the obstruction of the appendiceal lumen by an appendicolith, intestinal parasites, and hypertrophic lymphoid tissue or some tumors such as carcinoid.<sup>[6]</sup> The obstruction of the

lumen of vermiform appendix leads to suppurative inflammation and sometimes perforation.<sup>[7]</sup> This may then lead to localized or generalized peritonitis and an appendiceal abscess. The diagnosis is often established clinically although imaging modalities such as ultrasonography and computerized tomography may be necessary.<sup>[8]</sup> Appendectomy, preferably the laparoscopic approach, is currently the gold standard treatment of choice.<sup>[9,10]</sup>

Trichophagia is a psychiatric disorder of repetitive, compulsive behavior of ingesting, and swallowing hair that may lead to trichobezoar formation within the gastrointestinal tract. It is often seen together with trichotillomania and causes a great danger to a patient's health due to the risk of intestinal obstruction. Trichophagia is usually associated with anxiety, depressive disorders, obsessive-compulsive disorder, anorexia nervosa, and trichotillomania.<sup>[11]</sup> Rapunzel syndrome is a common result of this disorder which is due to a trichobezoar formation within the stomach extending up to the small bowel.<sup>[12]</sup> Rarely, as seen in this case, trichobezoar formation may occur in the distal intestine and may cause appendiceal obstruction, which can cause acute appendicitis.

## Conclusion

Trichobezoar formation within the gastrointestinal system has been extensively reported previously in the literature but only a few cases of trichobezoar formation leading to appendicitis have been previously published.<sup>[13–15]</sup> Patients often remain asymptomatic in the early stages and symptoms of gastrointestinal obstruction manifest as the trichobezoar builds up within the gastrointestinal tract.<sup>[11]</sup> This condition may become a surgical emergency since it can lead to an intestinal obstruction causing acute abdomen. Therefore, trichobezoar formation should be in the differential diagnosis in any patient presenting with signs of acute abdomen with a psychiatric disorder of trichotillomania and trichophagia.

**Informed Consent:** Written informed consent was obtained from the patient for the publication of the case report and the accompanying images.

**Peer-review:** Internally peer-reviewed.

**Authorship Contributions:** Concept: E.E., H.E.T., G.H.C.; Design: E.E., G.H.C.; Supervision: H.E.T., G.H.C.; Materials: H.E.T., G.H.C.; Data: E.E., H.E.T.; Analysis: E.E., G.H.C.; Literature search: E.E., H.E.T., G.H.C.; Writing: E.E., G.H.C.; Critical revision: E.E., H.E.T.

**Conflict of Interest:** None declared.

**Financial Disclosure:** The authors declared that this study has received no financial support.

## REFERENCES

1. Bhangu A, Søreide K, Di Saverio S, Assarsson JH, Drake FT. Acute appendicitis: Modern understanding of pathogenesis, diagnosis, and management. *Lancet* 2015;386:1278–87. [\[CrossRef\]](#)

2. Giudici F, Scaringi S, Zambonin D, Voglino C, Messerini L, Ficari F, et al. Poor pathogenetic role of luminal obstruction in the development of appendicitis: A case report. *Medicine (Baltimore)* 2018;97:e0381. [CrossRef]
3. Humes DJ, Simpson J. Acute appendicitis. *BMJ* 2006;333:530–4. [CrossRef]
4. Alder AC, Fomby TB, Woodward WA, Haley RW, Sarosi G, Livingston EH. Association of viral infection and appendicitis. *Arch Surg* 2010;145:63–71. [CrossRef]
5. Cisoň H, Kuš A, Popowicz E, Szyca M, Reich A. Trichotillomania and trichophagia: Modern diagnostic and therapeutic methods. *Dermatol Ther (Heidelb)* 2018;8:389–98. [CrossRef]
6. Jones MW, Lopez RA, Deppen JG. *Appendicitis*. In: StatPearls. Treasure Island, FL: StatPearls Publishing; 2021.
7. Stringer MD. Acute appendicitis. *J Paediatr Child Health* 2017;53:1071–6. [CrossRef]
8. Parks NA, Schroepel TJ. Update on imaging for acute appendicitis. *Surg Clin North Am* 2011;91:141–54. [CrossRef]
9. Fitzmaurice GJ, McWilliams B, Hurreiz H, Epanomeritakis E. Antibiotics versus appendectomy in the management of acute appendicitis: A review of the current evidence. *Can J Surg* 2011;54:307–14. [CrossRef]
10. Kumar S, Jalan A, Patowary BN, Shrestha S. Laparoscopic appendectomy versus open appendectomy for acute appendicitis: A prospective comparative study. *Kathmandu Univ Med J* 2016;14:244–8.
11. Jain A, Agrawal A, Tripathi AK, Bansod RK, Jain G, Yadav KS. Trichobezoar without a clear manifestation of trichotillomania. *J Family Med Prim Care* 2020;9:2566–8. [CrossRef]
12. Naik S, Gupta V, Naik S, Rangole A, Chaudhary AK, Jain P, et al. Rapunzel syndrome reviewed and redefined. *Dig Surg* 2007;24:157–61.
13. Michael G, Qureshi E, Miah M, Husain N. An unusual form of a trichobezoar causing a peculiar case of appendicitis: A case of rapunzel syndrome. *Cureus* 2020;12:e7554. [CrossRef]
14. Renu KT, Chinna RG. Isolated Rapunzel tail' presenting as acute appendicitis. *Indian J Pediatr* 2014;81:1260. [CrossRef]
15. Dogra S, Yadav YK, Sharma U, Gupta K. Rapunzel syndrome causing appendicitis in an 8-year-old girl. *Int J Trichol* 2012;4:278–9. [CrossRef]

## OLGU SUNUMU - ÖZ

### Bipolar bozukluğu olan bir hastada trikofajiye bağlı gelişen akut apandisit

Dr. Halit Eren Taşkın,<sup>1</sup> Dr. Ergin Erginöz,<sup>1</sup> Dr. Gökçe Hande Çavuş<sup>2</sup>

<sup>1</sup>İstanbul Üniversitesi Cerrahpaşa-Cerrahpaşa Tıp Fakültesi, Genel Cerrahi Anabilim Dalı, İstanbul

<sup>2</sup>İstanbul Üniversitesi Cerrahpaşa-Cerrahpaşa Tıp Fakültesi, Patoloji Anabilim Dalı, İstanbul

Akut apandisit, dünya çapında en sık görülen acil abdominal cerrahi işlemlerindedir. Çoğu zaman öykü ve klinik muayene tanıya büyük ölçüde katkı sağlamaktadır, ancak tanı belirsizse görüntüleme yöntemleri gerekli olabilir. Akut apandisit için apendektomi, çoğunlukla laparoskopik yaklaşım, bugüne kadar halen altın standart tedavi olmaya devam etmektedir. Patofizyolojisinde genellikle apendikolit veya lenfoid hiperplazi ile lümen obstrüksiyonu ve nadiren paraziter enfeksiyonları içerir. Bu olgu sunumunda, bipolar bozukluk tanılı trikofaji öyküsü olan ve akut apandisitte apandiks lümeninde trikobezoar oluşumu ile yol açan çok nadir bir olguyu sunmaktayız.

**Anahtar sözcükler:** Akut apandisit; bipolar hastalık; trikofaji.

Ulus Travma Acil Cerrahi Derg 2022;28(4):554-556 doi: 10.14744/tjtes.2022.34808