

An unusual injury pattern: arm wrestling injury, treatment modalities, clinical outcomes, and return to sport

Yavuz Şahbat, M.D.,¹ Emir Kütük, M.D.,² Görkem Çat, M.D.,² Oğulcan Ünsalan, M.D.,²
Hayati Kart, M.D.,² Osman Mert Topkar, M.D.,² Özgür Baysal, M.D.,² Bülent Erol, M.D.,²

¹Department of Orthopaedic Surgery and Traumatology, Maresal Cakmak State Hospital, Erzurum-Türkiye

²Department of Orthopaedics and Traumatology, Marmara University School of Medicine, Istanbul-Türkiye

ABSTRACT

BACKGROUND: In the sport of arm wrestling, the great rotational force is applied to the upper extremity, which can result in muscle and tendon injuries in the shoulder, elbow, and wrist joints, and even bone fractures. The aim of this study was to present the treatment modalities, functional outcomes, and return to sport after arm wrestling injuries.

METHODS: A retrospective evaluation was made of the trauma mechanisms, treatment modalities, clinical outcomes, and time of return to sports of patients admitted to our hospital with an arm wrestling injury between 2008 and 2020. At the final follow-up examination, the functional scores (DASH score and constant score) of the patients were evaluated.

RESULTS: Evaluation was made of 22 patients comprising 18 (82%) males and 4 (18%) females with a mean age of 20±6.1 years (range, 12–33 years). Two (10%) patients were professional arm wrestlers. The DASH scores at the final follow-up (mean 4 years) examination were 0.57 (min: 0 and max: 1.7) for the patients with humerus shaft fracture. All the patients with isolated soft-tissue injuries returned to sports within 1 month. Patients with humeral shaft fractures returned to sports later and had a lower functional score (P<0.05). There was no disability in any patient during long-term follow-up. Patients with soft-tissue injuries continued arm wrestling more than patients with bone injuries (P<0.001).

CONCLUSION: This study constitutes the largest patient series evaluating patients presenting at a health-care institution with any complaint after arm wrestling. Arm wrestling is not a sport that only results in bone pathologies. Therefore, providing the participants in this sport with information that they may be injured in arm wrestling but there will be a full recovery, may reassure and encourage them.

Keywords: Arm wrestling; humeral shaft fracture; medial epicondyle fracture; shoulder dislocation; soft-tissue injury.

INTRODUCTION

Arm wrestling is a competitive sport with simple rules, which does not require any equipment, and is popular among young adults.^[1] This sport, in which two people face each other across a table or bar, place their elbow on the table and clasp hands, aiming to force down the arm of the opponent so that the back of the hand touches the table, is included in official competitions and can be used as a sign of strength

among young adults. Official competitions started in the 1950s, and these are managed by the World Arm Wrestling Federation, with categories based on weight and dominant hand.^[2] Although this competition seems harmless, the upper extremity is exposed to a high rotational torque force. That this high torque can cause some injuries have been confirmed in biomechanical studies.^[3] Case reports and case series in literature have reported tendon ruptures, nerve injuries, medial epicondyle fractures, forearm fractures, scapula fractures, and radial head fractures.^[2,4-7]

Cite this article as: Şahbat Y, Kütük E, Çat G, Ünsalan O, Kart H, Topkar OM, Baysal Ö, Erol B. An unusual injury pattern: arm wrestling injury, treatment modalities, clinical outcomes, and return to sport. *Ulus Travma Acil Cerrahi Derg* 2023;29:733-740.

Address for correspondence: Yavuz Şahbat, M.D.
Marmara University School of Medicine, Istanbul, Türkiye
E-mail: yavuzsahbat@gmail.com



Ulus Travma Acil Cerrahi Derg 2023;29(6):733-740 DOI: 10.14744/tjtes.2023.34247 Submitted: 02.12.2022 Revised: 29.01.2023 Accepted: 20.02.2023
OPEN ACCESS This is an open access article under the CC BY-NC license (<http://creativecommons.org/licenses/by-nc/4.0/>).

Humerus shaft fractures classified as Arbeitsgemeinschaft für Osteosynthesefragen 12.A1 and 12.A2 are known to be fractures directly related to arm wrestling.^[8] This spiral fracture pattern, known as Holstein Lewis fracture, creates a risk of radial nerve damage both in itself and by the high torque force created.^[9,10] The majority of literature related to humerus fractures associated with arm wrestling is in the form of single case reports or limited case series.^[11,12] To the best of our knowledge, there is no study that has presented the functional results of patients with humerus fractures and patients with isolated soft-tissue injuries caused by arm wrestling.

Sports-related injuries affect the mental health of athletes and can cause them to leave sports. Injuries suffered in arm wrestling change the attitude of amateur and professional athletes to arm wrestling and other upper extremity sports. The aim of this study was (1) to evaluate all the patients who presented at our clinic with complaints of pain in the upper extremity after arm wrestling, in respect of demographic data, the fracture pattern, treatment options, the return to the sport of patients who suffered an injury, and their view of the sport and (2) to compare the return to sports rates and functional scores of patients with soft tissue and bone injuries as a result of arm wrestling.

MATERIALS AND METHODS

Approval for the study was granted by the Institutional Ethics Committee (09.2022.677). Data were retrieved from the hospital information system of patients who presented at the Emergency Department between 2008 and 2020 with complaints of pain in the upper extremity following arm wrestling (Indian wrestling).

A record was made of the demographic characteristics (age,

gender) of the patients, the dominant extremity, the injured extremity, and the region of the extremity where the pain was felt.

For patients treated surgically for a humerus fracture, the pre-operative, perioperative, and post-operative findings were documented, and for patients who followed up conservatively, the conservative follow-up methods and findings were noted.

At the beginning of the study, the patients were called for a follow-up examination. The information related to the dominant extremity, whether or not they had engaged in arm wrestling again, and the times of return to work and sport were confirmed by the patients. The range of movement of the upper extremity, especially of the elbow joint, was evaluated. The constant score was determined for patients who sustained a humerus shaft fracture.

Statistical Analysis

Data obtained in the study were analyzed statistically using IBM SPSS Statistics v. 20.0 software (IBM Corp., Armonk, NY, USA). Descriptive analyses were presented using median, minimum and maximum, and mean \pm standard deviation values, frequency, and percentage. Independent quantitative data were analyzed using the independent samples t-test and the Mann–Whitney U-test. Independent qualitative data were analyzed using the Chi-square test. The type I error level was determined as 0.05. A probability value of $p < 0.05$ was considered statistically significant.

RESULTS

An evaluation was made of 22 patients comprising 18 (82%) males and 4 (18%) females with a mean age of 20 ± 6.1 years

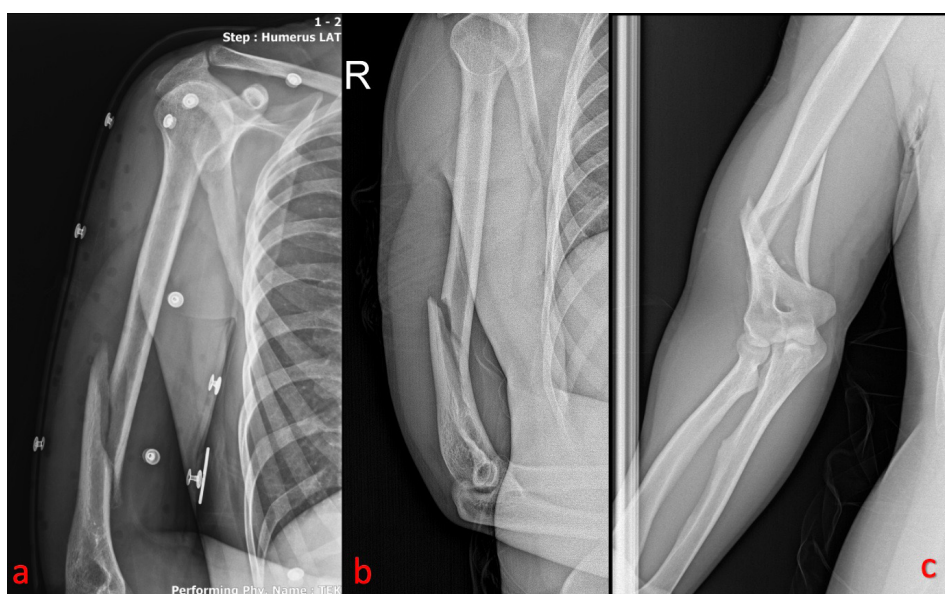


Figure 1. The different fracture patterns formed associated with arm wrestling. (a) AO 12A1 8/10/13/15/16/20 (b) AO 12A2 7/9/ (c) AO 12B2 11/14.

Table 1. Patient data

Patient	Gender	Age	Trauma side	Dominant side	Trauma	Treatment	Position
1	Male	12	Right	Right	Hand wrist pain	Short arm splint	Standing
2	Male	14	Right	Right	Forearm muscle strain	Arm sling	Sitting
3	Male	15	Right	Right	Elbow pain	Arm sling	Sitting
4	Female	15	Left	Left	Hand wrist pain	Short arm splint	Sitting
5	Male	16	Left	Right	Hand wrist pain	Short arm splint	Standing
6	Male	16	Right	Right	Shoulder muscle strain	Arm sling	Sitting
7	Male	18	Left	Right	AO I2A2 Hfx	U splint	Sitting
8	Male	18	Right	Right	AO I2A1 Hfx	Hanging cast	Standing
9	Male	19	Right	Right	AO I2A2 Hfx	Hanging cast	Sitting
10	Male	21	Right	Right	AO I2A1 Hfx	Hanging cast	Standing
11	Male	23	Right	Right	AO I2B2 Hfx	Operation	Sitting
12	Male	31	Right	Right	Shoulder pain	Arm sling	Standing
13	Male	31	Right	Right	AO I2A1 Hfx	U splint	Sitting
14	Male	33	Right	Right	AO I2B2 Hfx	Operation	Standing
15	Female	16	Left	Left	AO I2A1 Hfx	Arm sling	Standing
16	Female	18	Left	Right	AO I2A1 Hfx	U splint	Sitting
17	Male	19	Right	Right	Shoulder pain	Arm sling	Sitting
18	Male	16	Left	Left	Forearm muscle strain	Arm sling	Standing
19	Female	27	Right	Right	Hand wrist pain	Short arm splint	Sitting
20	Male	23	Right	Right	AO I2A1 Hfx	Operation	Sitting
21	Male	14	Right	Right	Medial epicondyl fracture	Operation	Standing
22	Male	20	Right	Right	Shoulder dislocation	Close reduction	Standing

(range, 12–33 years). Humerus shaft fracture was determined in ten cases (Group 1), isolated soft-tissue injury in ten cases (Group 2), glenohumeral shoulder dislocation in one case, and medial epicondyle fracture in one case. Two (10%) patients were professional arm wrestlers. The mean follow-up period was 4 ± 1.5 years. The injured extremity was the dominant extremity in 19 (86%) patients. The patient data are summarized in Table 1.

In patients with humerus fracture, the most common fracture pattern was determined to be spiral oblique fracture (Fig. 1). Of the ten patients with humerus fractures, the fracture occurred while standing in four (40%) and while seated in six (60%). Of the ten patients with a humerus fracture, seven were treated conservatively (Fig. 2). The youngest patient with humerus fracture was 16 years old, and this patient was followed up conservatively (3 weeks in an arm sling, followed by 6 weeks with a Sarmiento brace) (Fig. 3).

In two patients who developed humerus shaft fracture, the radial nerve damage was determined on the first presentation, and in one patient with medial epicondyle fracture, the ulnar nerve damage was determined on the first presentation. This was confirmed on electromyography (EMG) with the finding of no motor unit potential. Patients with radial

nerve damage were treated conservatively. In the patient applied with open reduction and internal fixation (ORIF) for a medial condyle fracture, ulnar nerve exploration was performed (Fig. 4). The motor unit potential of the radial nerve injury in patients with humerus fracture returned completely in the 3rd and 4th months, and of the ulnar nerve in the patient with medial epicondyle fracture in the 6th month after the trauma.

Bone union was obtained in the median 9 weeks (min: 4 and max: 11) in all the patients with humerus fractures.

No additional pathology or injury in any other region of the extremity was observed in any patient. In the patients with isolated soft-tissue damage, the pain recovered in a maximum of 3 weeks and there was no need for additional investigative tests.

The DASH scores at the final follow-up examination were 0.57 (min: 0 and max: 1.7) for the patients with humerus shaft fracture, 0 for all the patients with isolated soft-tissue injury, 2.5 for the patient with medial epicondyle fracture (Fig. 5), and 2.5 for the patient with shoulder dislocation. There was a statistically significant difference between the groups ($p=0.01$).

Arm wrestling was reported to be taken up again by three

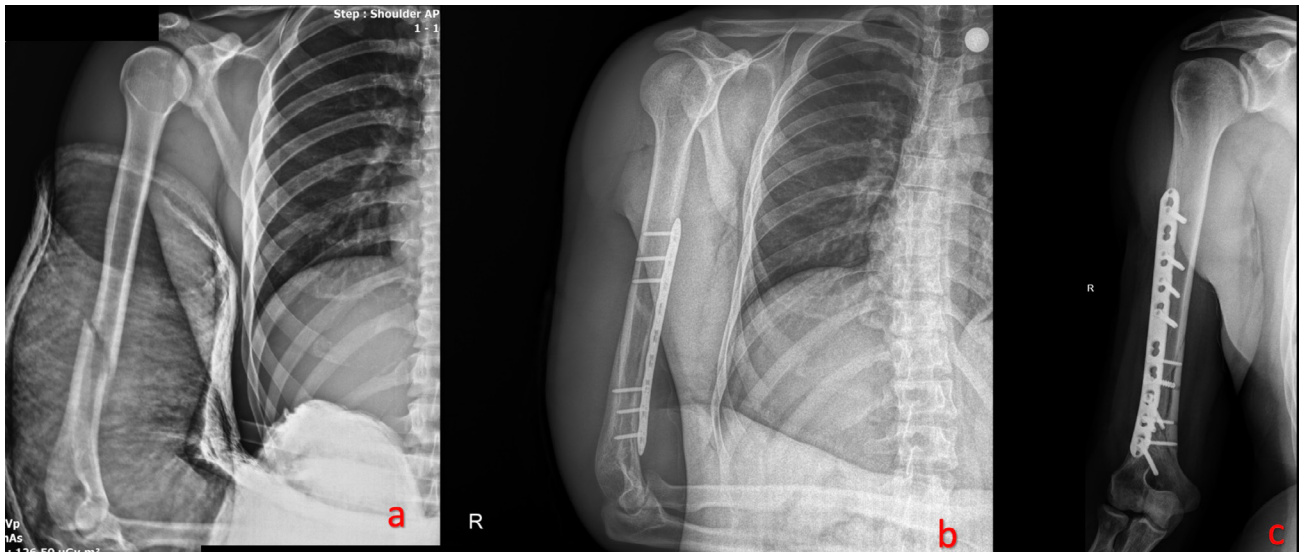


Figure 2. (a) Hanging cast treatment, (b) Mini open plate technique, (c) Lateral plate technique.

(30%) of the ten patients with humerus shaft fractures and by seven (70%) of the ten patients with isolated soft-tissue injuries. The difference between the groups was statistically

significant ($p < 0.001$).

The patients with humerus shaft fractures returned to sports within the mean of 10 months (min: 5, max: 12). All the pa-

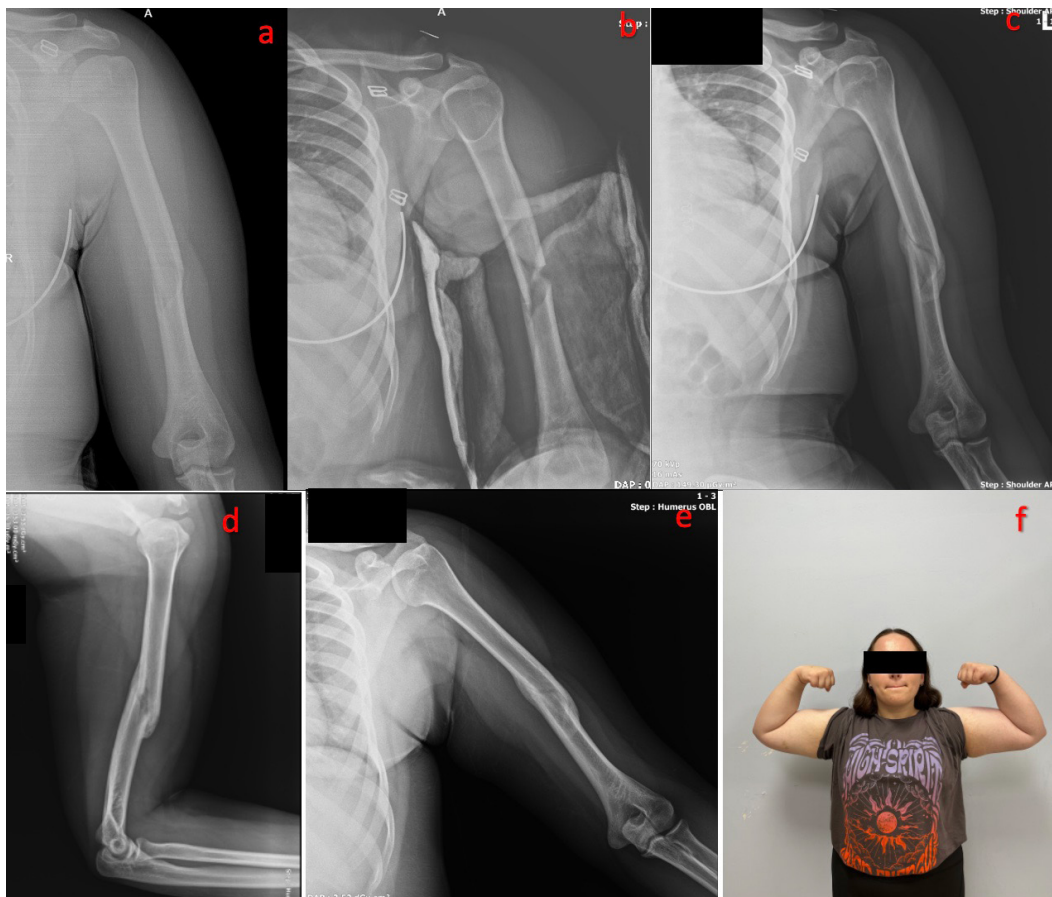


Figure 3. A 16-year-old female arm wrestler. On anterior posterior humerus x-ray images, an Orthopaedics Trauma Association (OTA) 12A1 spiral fracture of the left humerus was determined. An arm sling was applied to the patient without any manipulation. It was decided to treat this patient conservatively as alignment was within acceptable limits. (a, b) Preoperative X-Ray showing humerus shaft fracture after arm wrestling (c) Callus formation after 7 weeks (d, e) Total healing after 6 months of follow-up (f) The patient after 1 year follow-up.

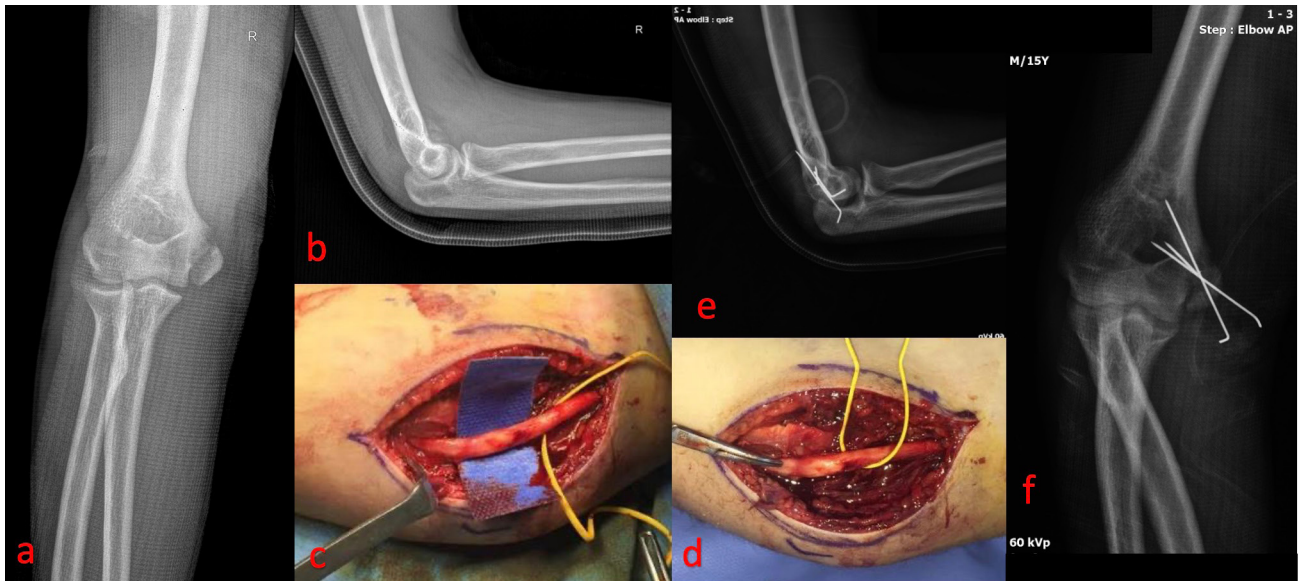


Figure 4. A 14-year-old male presented with the complaint of sudden pain while arm wrestling with a friend at school. On the anterior posterior x-rays, right-side medial epicondyle fracture was determined, so surgery was planned. The ulnar nerve was explored perioperatively, and it was seen that fracture fragments were compressing the ulnar nerve. Following ulnar nerve release and ORIF applied to the fracture, fixation was made with 3 K-wires. (a, b) Pre-operative X-ray showing medial epicondyle fracture after arm wrestling. (c, d) Perioperative photograph showing intact ulnar nerve with minimal ulnar nerve damage. (e, f) Early post-operative X-Ray showing K-wire fixation of the fracture. ORIF: Open reduction and internal fixation.

tients with isolated soft-tissue injuries returned to sports within 1 month. There was a statistically significant difference between the groups ($p=0.043$).

At the final follow-up examination, the constant score of the patients with humerus shaft fracture was a mean of 88 (min: 85 and max: 92).

DISCUSSION

Humeral shaft fracture is the most discussed injury following

arm wrestling.^[11,12] Some atypical injuries (scapula fracture, radius head fracture, radius shaft fracture, olecranon fracture, etc.) have been reported in the literature, but in the form of case reports.^[5,6,13] The current study presents the first case of shoulder dislocation due to arm wrestling. This study is the largest patient series evaluating all patients experiencing pain for any reason following arm wrestling. Citak et al. reported three muscle strains in three patients, whereas in the current study, there was muscle strain in 3 of 21 patients and isolated soft-tissue damage was determined in a total of 10 patients.^[5]

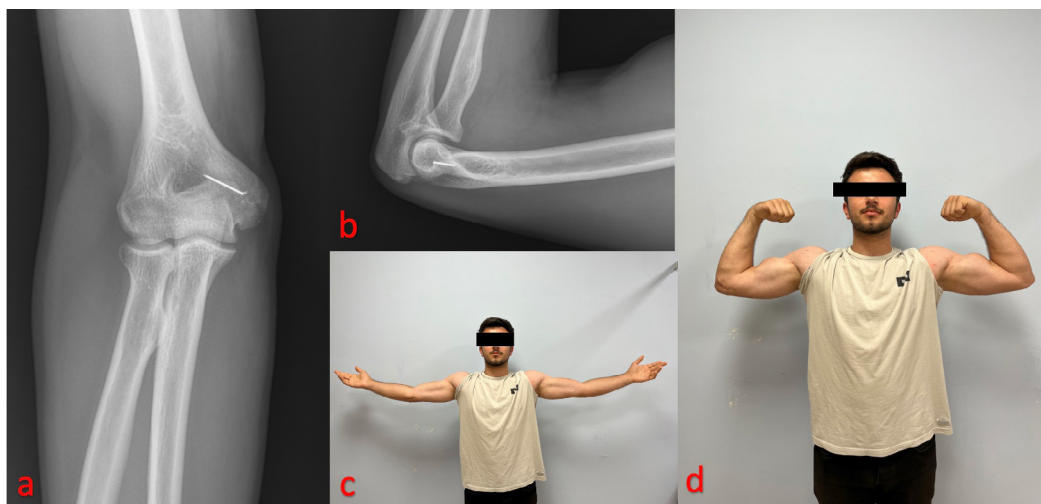


Figure 5. At the final follow-up examination at 5 years post-operatively of the medial epicondyle fracture patient, the right elbow range of movement was restricted by 5° and there was full flexion. Full forearm pronation and supination was determined. (a and b) 5-year follow-up X-Ray showing total healing and no epiphyseal damage. (c and d) Clinical status of the patient.

Contrary to the previous data, soft-tissue injuries were found to be the most common injury in this series.

Several authors have focused only on humerus shaft fractures, but arm wrestling is not a sport that only results in bone pathologies, as isolated soft-tissue injuries can develop such as proximal biceps rupture.^[14] The results of the current study showed that the long-term functional results of patients with a fracture were similar to those of patients with isolated pain. There was one case of medial epicondyle fracture in the current series. This injury can be formed associated with arm wrestling at a younger age.^[2]

Patients with a fracture in the early period of arm wrestling may experience more loss of work and have more complaints of pain, with a more delayed return to work and sport. In the current study, no disability was determined in any patient during the follow-up period of at least 1 year. It can be considered that providing the information that injury may be experienced when arm wrestling but there will be full recovery could reassure and encourage athletes.

Humerus fractures can occur with direct or indirect trauma.^[15] In oncology patients and those with affected bone metabolism, indirect fractures may form in conditions such as excessive muscle strain. Soldiers throwing hand grenades and arm wrestler muscle contraction are examples forming the basis of indirect fracture mechanism.^[5,12] In arm wrestling, the elbow joint is fixed in flexion by the biceps and brachialis muscles and the shoulder joint is forced into active internal rotation against the force created by the pectoralis major, subscapularis, and teres major muscles. These forces result in strong torque along the humerus shaft and can result in a spiral fracture.^[1,4,8] It has also been reported that the rotational force applied on the humerus not only causes a spiral fracture, but the rotator force with axial loading can also cause butterfly fragments.^[8] Kim et al. reported that the most common etiology was arm wrestling for humerus shaft fractures in Korean soldiers.^[12] However, that was a specific group and may not represent the general population.

Humerus shaft fractures are often seen in amateur arm wrestlers. Of the current series, two (10%) patients were professionals. Although there are reports stating that the risk of fracture is increased when the competitors are in a prone position, sitting, or standing, others have shown no relationship of the fracture with the position or stage of the match.^[5,8,16] All the patients with fractures in the current series (42%) were standing, and no pre-dominance of standing or seated positions could be found.

Distal humerus spiral fracture, known as Holstein–Lewis fracture, is typical for this sport.^[10] The radial nerve is a known risk for Holstein–Lewis fracture, and radial nerve damage has been reported in the literature as 22%–31% of the known injuries in these fractures.^[9,12] The radial nerve can be injured because of the damage that can be caused to the nerve by the fracture fragments or the direct neuropraxia effect of the

rotational force. Karadeniz et al. reported that there were radial nerve findings in 22% of patients on first presentation, but no radial nerve findings remained in any patient by the 6th month of follow-up.^[11] Kim et al. reported prolonged radial nerve damage after direct trauma but cases of prolonged radial nerve damage after arm wrestling were not mentioned.^[12] In the current series, radial nerve damage was seen in only two patients and this completely recovered in 5 months of follow-up. This was confirmed with EMG, but routine use of EMG may not always be necessary because in arm wrestling, the radial nerve is not injured between the fragments but by neuropraxia caused by the rotational torque power.

Karadeniz et al. recommended surgery for social reasons to provide more rapid healing and a return to work as soon as possible.^[11] Frankowska-Rutkowska et al. treated all patients with ORIF and Pande et al. treated 3 of 6 patients with ORIF.^[16,17] In the current study, one patient with medial epicondyle fracture and two patients with intra-articular fracture and humerus shaft fracture were treated surgically for social reasons. However, surgery should not be routinely recommended. To the best of our knowledge, there are no reports in the literature of non-union of a humerus shaft fracture after arm wrestling. Non-union was not seen in any of the current patients and there were no findings of delayed union. Conservative treatment can be safely selected even for displaced humerus fractures associated with arm wrestling.

In a comparison of distal humerus spiral fractures occurring after arm wrestling with fractures in the same region caused by different mechanisms, Mayfield et al. reported that bone union was obtained earlier in the arm wrestling group. It was suggested that a potential reason for this could be the better bone quality and capacity for the union of athletic adults.^[15]

With surgery, athletes may have an early return to sports and work life, and sufficient alignment is provided, but plaster casting and the use of braces should be preferred before surgery. Karadeniz et al. reported a minimal range of movement restriction together with no functional limitation.^[11] In the current study, the patients were evaluated with the DASH score at the final follow-up examination. No functional joint restriction was determined in any of the patients. In one patient with humerus shaft fracture followed up conservatively, a 10° extension limitation was determined.

The study of Korean soldiers by Kim et al. is the study in literature with the highest number of humerus shaft fracture patients.^[12] Although it has been reported previously in the literature that the dominant arm is injured more, Kim et al. observed no arm predominance.^[11,12,16] In the current study, fractures were seen more on the dominant side. This was thought to be because although professional arm wrestlers compete with both arms, amateurs only use their dominant arm.

Fracture alignment is important for there to be no functional problems remaining after a humerus fracture. Takahara et al.

reported that 20°–45° rotation from proximal can be tolerated in a humerus fracture.^[18] However, in conservative treatment with plaster cast or brace, fracture fragments may migrate and may cause coronal and sagittal malalignment. In the current series, no functional varus or valgus problems were observed in any patient.

Of the current study patients with humerus fractures, a high percentage did not participate in arm wrestling again, which was attributed to the psychological effect on the patients. Although there was no documentation on this subject, in the interviews with the patients, the most common reason given was fear of refracture. Therefore, it was thought that bone pathology had a greater protective effect on the patients who had experienced it compared to those who had not.

Limitations of this study can be said to be the retrospective design and the relatively low number of patients. There is a need for further studies with greater patient numbers to be able to conduct multiple analyses.

Conclusion

Arm wrestling will undoubtedly continue to be a cause of injuries in the future as it is a simple sport that does not require any equipment and is a sign of strength among adolescents. This study has the greatest number of patients presenting the functional results of all patients presenting at a hospital with any complaint after arm wrestling. It was seen that not all the injuries included a bone pathology and the vast majority were soft-tissue injuries. No permanent function loss or disability was determined in any patient. On the basis of the data in this study, information can be given to professional arm wrestlers that they may sustain injuries in this sport but no significant disability will remain.

Ethics Committee Approval: This study was approved by the Marmara University School of Medicine Clinical Research Ethics Committee (Date: 06.05.2022, Decision No: 09.22.677)

Peer-review: Externally peer-reviewed.

Authorship Contributions: Concept: Y.Ş.; Design: Ö.B., Y.Ş.; Supervision: B.E., Y.Ş.; Materials: E.K., H.K.; Data: Ö.B., G.Ç.; Analysis: M.T., E.K.; Literature search: O.Ü., Y.Ş.; Writing: Ö.B., Y.Ş.; Critical revision: B.E., Y.Ş.

Conflict of Interest: None declared.

Financial Disclosure: The authors declared that this study has received no financial support.

REFERENCES

1. Chao SL, Miller M, Teng SW. A mechanism of spiral fracture of the humerus: A report of 129 cases following the throwing of hand grenades. *J Trauma* 1971;11:602–5. [\[CrossRef\]](#)
2. Moloney DP, Feeley I, Hughes AJ, Merghani K, Sheehan E, Kennedy M. Injuries associated with arm wrestling: A narrative review. *J Clin Orthop Trauma* 2021;18:30–7. [\[CrossRef\]](#)
3. Pedrazzini A, Pedrazzoni M, De Filippo M, Nicoletto G, Govoni R, Caccarelli F. Humeral fractures by arm wrestling in adult: A biomechanical study. *Acta Biomed* 2012;83:122–6.
4. Ogawa K, Ui M. Fracture-separation of the medial humeral epicondyle caused by arm wrestling. *J Trauma* 1996;41:494–7. [\[CrossRef\]](#)
5. Citak M, Backhaus M, Seybold D, Muhr G, Roetman B. Arm wrestling injuries--report on 11 cases with different injuries. *Sportverletz Sportschaden* 2010;24:107–10. [\[CrossRef\]](#)
6. Considine S, Hirpara KM, Hynes DE. Fracture of the scapular neck sustained in an arm wrestling match. *Ir Med J* 2014;107:298–9.
7. Fallis G, Ferguson K, Malcolm B. An unusual fracture in arm wrestling. *Phys Sportsmed* 1990;18:93–6. [\[CrossRef\]](#)
8. Kruczyński J, Nowicki JJ, Topoliński T, Srokowski G, Mańko G, Chantoulis M, et al. Radiological and biomechanical analysis of humeral fractures occurring during arm wrestling. *Med Sci Monit* 2012;18:CR303–7. [\[CrossRef\]](#)
9. Ekholm R, Ponzer S, Törnkvist H, Adami J, Tidermark J. The Holstein-Lewis humeral shaft fracture: Aspects of radial nerve injury, primary treatment, and outcome. *J Orthop Trauma* 2008;22:693–7. [\[CrossRef\]](#)
10. Holstein A, Lewis GM. Fractures of the humerus with radial-nerve paralysis. *J Bone Joint Surg Am* 1963;45:1382–8. [\[CrossRef\]](#)
11. Karadeniz E, Demiroz S, Oktem F, Memisoglu K, Kesemenli CC. Humeral fractures sustained during arm wrestling. *Eur J Trauma Emerg Surg* 2022;48:3109–14. [\[CrossRef\]](#)
12. Kim KE, Kim EJ, Park J, Kim S, Kwon J, Moon G. Humeral shaft fracture and radial nerve palsy in Korean soldiers: Focus on arm wrestling related injury. *BMJ Mil Health* 2021;167:80–3. [\[CrossRef\]](#)
13. Pasquina PF, O'Connor FG. Olecranon fracture sustained in arm wrestling. *Phys Sportsmed* 1999;27:81–7. [\[CrossRef\]](#)
14. Pratt DA, Tennent TD. Proximal biceps rupture: Management of an unusual injury in an arm wrestler. *Br J Sports Med* 2007;41:459. [\[CrossRef\]](#)
15. Mayfield CK, Egol KA. Humeral fractures sustained during arm wrestling: A retrospective cohort analysis and review of the literature. *Orthopedics* 2018;41:e207–10. [\[CrossRef\]](#)
16. Pande KC, Nishat N, Afzal S, Ishak L. Humeral shaft fracture sustained during arm wrestling with review of factors contributing to its causation. *Malays Orthop J* 2021;15:15–20. [\[CrossRef\]](#)
17. Frankowska-Rutkowska M, Górska J, Jedwabiński M, Mątewski D, Maciejewski M. Fracture of the humerus during arm wrestling: Report on 9 cases and review of the literature. *Med Biol Sci* 2013;27:36–8.
18. Takahara M, Sasaki I, Kimura T, Kato H, Minami A, Ogino T. Second fracture of the distal humerus after varus malunion of a supracondylar fracture in children. *J Bone Joint Surg Br* 1998;80:791–7. [\[CrossRef\]](#)

ORJİNAL ÇALIŞMA - ÖZ

Farklı bir yaralanma şekli: Bilek güreşi yaralanması; tedavi şekilleri, klinik sonuçlar ve spora dönüş**Dr. Yavuz Şahbat,¹ Dr. Emir Kütük,² Dr. Görkem Çat,² Dr. Oğulcan Ünsalan,² Dr. Hayati Kart,² Dr. Osman Mert Topkar,² Dr. Özgür Baysal,² Dr. Bülent Erol²**¹Mareşal Çakmak Devlet Hastanesi Ortopedi Cerrahi ve Travmatoloji Kliniği, Erzurum-Türkiye²Marmara Üniversitesi Tıp Fakültesi Ortopedi ve Travmatoloji Anabilim Dalı, İstanbul-Türkiye

AMAÇ: Bilek güreşi sırasında üst ekstremiteye büyük bir rotasyonel tork kuvveti uygulanır. Bilek güreşi omuz, dirsek ve el bilek eklemlerinde kas ve tendon yaralanmaları ve hatta kemik kırıklarına sebep olabilir. Bu çalışmanın amacı, bilek güreşi sonrası tedavi şekillerini, fonksiyonel sonuçları ve spora dönüş durumlarını sunmaktır.

GEREÇ VE YÖNTEM: 2008-2020 yılları arasında hastanemize başvuran hastaların travma mekanizmaları, tedavi şekilleri, klinik sonuçları ve spora dönüş durumları retrospektif olarak değerlendirildi. Son takipte hastaların fonksiyonel skorları (DASH skoru, Constant skoru) değerlendirildi.

BULGULAR: Yaş ortalaması 20±6.1 (12-33) olan 18(82%) erkek, 4(%18) kadın toplam 22 hasta çalışmaya dahil edildi. 10 hastada humerus shaft kırığı, 10 hastada izole yumuşak doku yaralanması, 1 hastada medial epikondil kırığı ve 1 hastada omuz çıkığı vardı. Hastaların ikisi (%10) hasta profesyonel bilek güreşçisiydi. Humerus cisim kırığı olan hastaların son kontrol (ortalama 4 yıl) DASH skorları ortalaması 0.57 (0-1.7 min max) idi. İzole yumuşak doku yaralanması olan hastaların tümü 1 ay içinde spora döndü. Humerus cisim kırığı olan hastalarda spora dönüş süresi daha uzun ve fonksiyonel skor daha düşüktü (p<0.043). Uzun dönem takipte hiçbir hastada sakatlık tespit edilmedi. Yumuşak doku yaralanması olan hastaların kemik yaralanması olan hastalara göre daha fazla bilek güreşine devam ettiği görüldü (p<0.001)

TARTIŞMA: Çalışmamız bir sağlık kuruluşuna bilek güreşi sonrası herhangi bir şikayetle başvuran hastaların değerlendirildiği en geniş hasta serisini sunmaktadır. Bilek güreşi sadece kemik patolojileriyle sonuçlanan bir spor değildir. Bilek güreşi sporcularına spor sırasında sakatlanabilecekleri ancak tam bir iyileşme olacağı bilgisinin verilmesinin sporcuları rahatlatacağı ve cesaretlendireceği düşünülebilir.

Anahtar sözcükler: Bilek güreşi; humerus shaft kırığı; medial epikondil kırığı; omuz çıkığı; yumuşak doku yaralanması.

Ulus Travma Acil Cerrahi Derg 2023;29(6):733-740 doi: 10.14744/tjtes.2023.34247