

Heparin-free veno-venous ECMO applied to a patient with severe lung contusion and hypovolemic shock due to trauma

 Seong Ho Moon, M.D.,¹  Ki Nyun Kim, M.D.,¹  Jae Jun Jung, M.D.,¹
 Jae Hong Park, M.D.,²  Jung Hun Byun, M.D.¹

¹Department of Thoracic and Cardiovascular Surgery, Changwon Hospital, Gyeongsang National University College of Medicine, Republic of Korea, Changwon - South Korea

²Department of Thoracic and Cardiovascular Surgery, Samsung Changwon Hospital, Sungkyunkwan University College of Medicine, Gyeongsangnam-do - Korea

ABSTRACT

Veno-venous extracorporeal membrane oxygenation (VV-ECMO) plays a crucial role when the lung is extensively damaged and when conventional management has failed. ECMO provides adequate tissue oxygenation and an opportunity for lung recovery. However, ECMO remains contraindicated in patients with a risk of bleeding because of systemic anticoagulation during the treatment. A 26-year-old female experienced polytrauma due to a traffic accident 1 h before arrival. Simple chest radiography and chest computed tomography showed a large right hemopneumothorax with atelectasis of the right lung and severe contusion of the left lung. Heparin-free VV-ECMO was applied peripherally via both femoral veins. Under the ECMO support, right lower lobectomy was successfully performed. Although contraindicated in polytraumatic patients with hemorrhagic shock, surgical repair with the application of ECMO may be feasible if bleeding is well controlled. The patient was discharged without significant complications.

Keywords: Extracorporeal membrane oxygenation; hemorrhagic shock; polytraumatic.

INTRODUCTION

Patients with polytrauma reportedly experience associated chest trauma in 50% of cases.^[1,2] Life-threatening complications include hemorrhagic shock and severe respiratory failure due to chest trauma.^[3] Extracorporeal membrane oxygenation (ECMO) helps maintain systemic tissue oxygenation when pulmonary function is compromised. However, ECMO is contraindicated in some patients, particularly in those where further bleeding may be induced by systemic anticoagulation used during treatment, for example, patients with hemorrhagic polytrauma associated with pulmonary contusion and other organ damage.^[4] The application of heparin-free ECMO may be a solution for systemic anticoagulation during treatment. Polytraumatic patients rarely undergo

surgery with the application of ECMO. There are few cases of VV-ECMO application to patients with massive hemothorax due to deep lung lacerations. Here, we report the successful use of ECMO in a 26-year-old female who experienced hypovolemic shock and respiratory failure due to an extensively damaged lung.

CASE REPORT

A 26-year-old female experienced polytrauma due to a traffic accident 1 h before arrival. She did not have any known relevant medical history. At the time of arrival at our emergency department, her vital signs were as follows: blood pressure, 70/50 mmHg; heart rate, 120/min; respiratory rate, 25/min; and mental status, semicoma (Glasgow Coma Score: 8). Ar-

Cite this article as: Moon SH, Kim KN, Jung JJ, Park JH, Byun JH. Heparin-free veno-venous ECMO applied to a patient with severe lung contusion and hypovolemic shock due to trauma. *Ulus Travma Acil Cerrahi Derg* 2018;24:497-500.

Address for correspondence: Jung Hun Byun, M.D.

11, Samjeongja-ro, Seongsan-gu, Changwon-si 51472, Rep. of Korea Changwon, South Korea

Tel: 82-55-214-1000 E-mail: jhunikr@naver.com

Ulus Travma Acil Cerrahi Derg 2018;24(5):497-500 DOI: 10.5505/tjtes.2018.33802 Submitted: 27.03.2018 Accepted: 27.06.2018 Online: 07.09.2018

Copyright 2018 Turkish Association of Trauma and Emergency Surgery



terial blood gas analysis revealed hypoxemia and acidosis with a pH of 7.16, PaO₂ of 35 mmHg, PaCO₂ of 54 mmHg, and oxygen saturation of 50%. Her hemoglobin level was 10.9 g/dL, and her platelet count was 290,000/ μ L. She was intubated immediately and was placed on a mechanical ventilator [FiO₂, 1.0; positive end expiratory pressure (PEEP), 10 cmH₂O; peak inspiratory pressure (PIP), 35 cmH₂O]. The pupils were 2 mm in diameter and minimally reactive bilaterally. The left arm had sustained crushing injuries, and ulnar, radius, and humerus fractures were suspected. Blood flow in the left radial artery was identified using Doppler ultrasound. Breathing sounds were decreased, and a flail chest and severe subcutaneous emphysema of the entire upper body were observed. Chest computed tomography (CT), brain CT, and focused assessment with sonography for trauma were performed at the earliest. There was no intracranial hemorrhage or definitive abdominal organ injury. Simple chest radiography

and chest CT showed a large right hemopneumothorax with atelectasis of the right lung and severe contusion of the left lung (Figs. 1a, b). A 28-Fr chest tube was inserted in the right pleural cavity, and 3,000 cc of blood was drained for 1 h. Arterial blood gas analysis after 1 h under the previous mechanical ventilation settings (FiO₂, 1.0; PEEP, 10 cmH₂O; PIP, 35 cmH₂O) showed that pH, PaO₂, and PaCO₂ were 7.02, 50 mmHg (oxygen saturation, 60%), and 80 mmHg, respectively. Massive transfusion [packed red blood cells (PRBCs), 8 U; fresh frozen plasma (FFP), 5 U] was given via a pressure infusion system (Auto PC Automatic Pressure Infuser, Acemedical), and right exploratory thoracotomy was performed. Because hypoxia (oxygen saturation, 70%) was persistent during anesthesia, heparin-free VV-ECMO (3.0 L/min; MAQUET Cardiopulmonary AG, Hirrlingen, Germany) was applied peripherally via both femoral veins using a DLP-21, 22-Fr venous cannula (Medtronic Inc., Minneapolis, MN, USA). Under the

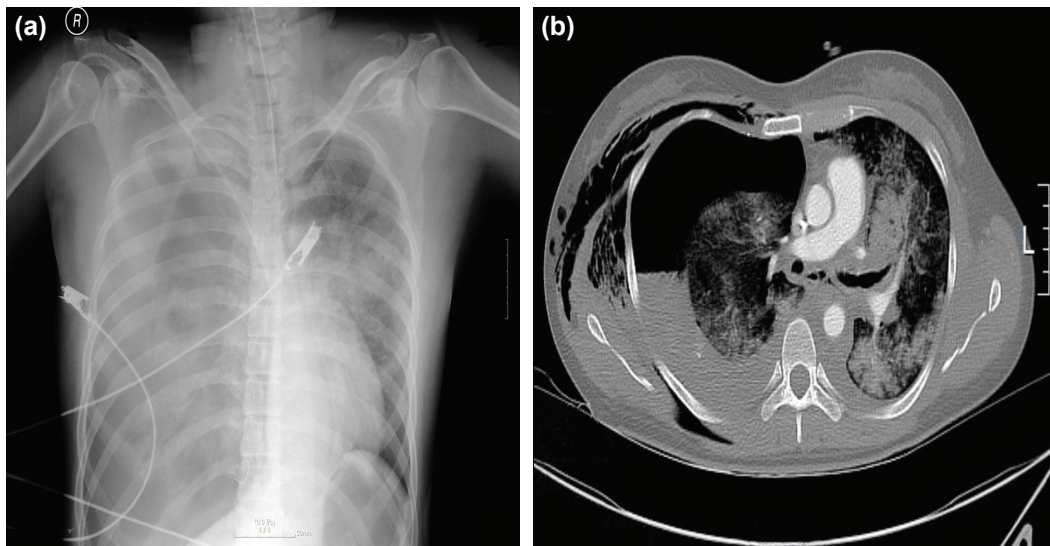


Figure 1. Simple chest radiography (a) and chest computed tomography (b) show a large right hemopneumothorax and severe contusion of the left lung.

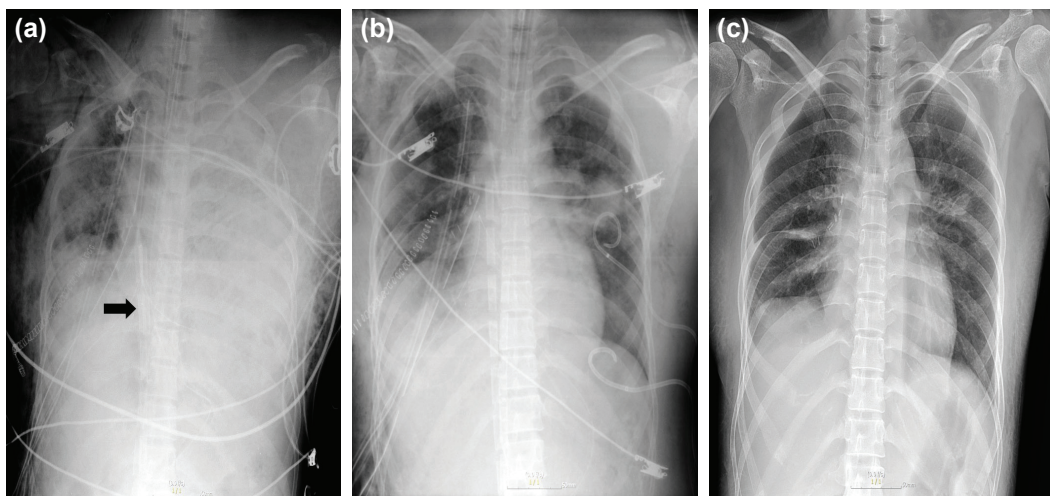


Figure 2. Immediate postoperative simple chest radiography shows venous catheters (black arrow) for extracorporeal membrane oxygenation (a). Simple chest radiography shows improvement on postoperative day 4 (b) and at the time of patient discharge (c).

ECMO support, the oxygen saturation level was maintained at 95% during surgery.

Right lower lobe lobectomy was performed because of a deep laceration of approximately 8 cm and severe lung contusion on the right lower lobe. PRBCs (8 U) and platelet concentrate (8 U) were transfused during surgery. Fasciotomy was performed due to left forearm compartment syndrome. Figure 2a shows immediate postoperative simple chest radiography. The amount of hemothorax in the left pleural cavity was increased, and two 6-Fr pigtail catheters were placed under sonography guidance; 400 cc of blood was drained for 1 h via two left pigtail catheters, and no more subsequent draining was performed.

There was no definitive postoperative bleeding, and 1 U of PRBCs was transfused. ECMO (3.4 L/min) with a mechanical ventilator (FiO₂: 0.6, PEEP: 7 cmH₂O, PIP: 25 cmH₂O) was applied for 4 days. FuthanR (nafamostat mesilate) was used postoperatively for 2 days to control the activating clotting time at 150 s. Simple chest radiography showed improvement at postoperative day 4 (Fig. 2b), and ECMO weaning was initiated. There were no ECMO-related complications during the course. Mechanical ventilator weaning was initiated on postoperative day 8. On postoperative days 19 and 36, internal fixation for the left forearm fracture was performed and a left forearm skin graft was applied, respectively. At discharge, an improvement in simple chest radiography without operative wound complications was seen (Fig. 2c).

DISCUSSION

Severe trauma causes approximately 5 million global deaths annually.^[3,5] Many patients respond well to trauma-care specialist treatments, including fluid resuscitation, mechanical ventilation, and other invasive procedures. However, patients with concurrent severe chest trauma and hemorrhagic shock have poor prognosis. The significant treatment goals for patients with severe chest trauma and hemorrhagic shock are restoration of blood coagulation by appropriate transfusion (PRBC, platelet, and FFP), surgical repair of bleeding focus, and maintenance of body temperature. The potential survival benefit of ECMO applied to patients with severe lung injury has recently been reported.^[6,7]

We believe that if there is no hemorrhage of organs other than contused lungs, the application of ECMO will likely have a low risk of additional hemorrhage. However, if there is hemorrhage in other organs, the application of ECMO should be cautiously considered depending on whether any additional hemorrhage can be controlled. In such cases, heparin-free ECMO should be considered. Similarly, if there is a pulmonary hemorrhage, regardless of a hemorrhage in other

organs, careful consideration of ECMO is needed to account for possible hemorrhage control.

Our patient underwent right chest tube insertion with massive hemothorax (3,000 mL/h), and the hypovolemic shock was not corrected, despite substantial blood transfusion. Hypoxemia was not corrected with full mechanical ventilation due to severe injury of both lungs. Because hypovolemic shock and multiple organ damage continued, we decided on an emergency operation; however, several complications developed. First, conventional exploratory thoracotomy requires a lateral decubitus position. Hypoxemia was problematic due to severe lung contusion and blood aspiration to the contralateral lung. Second, a severely injured lung is vulnerable to acute respiratory distress syndrome and acute lung failure during massive fluid or blood product infusion. Third, hypothermia and acidosis due to massive transfusion may occur. Based on these potential complications, we decided to apply heparin-free VV-ECMO to the patient.

Our goals included restoring oxygen, maintaining normothermia, and securing massive transfusion and lung protective ventilation during the operation. Damage control focused on bleeding, and stable vital signs were maintained. Matthias et al. reported that the use of a heparin-free ECMO is beneficial for the survival of polytraumatic patients with pulmonary failure and hemorrhagic shock.^[3] In conclusion, although contraindicated in polytraumatic patients with hemorrhagic shock, surgical repair with the application of ECMO may be feasible if bleeding is well controlled.

Conflict of interest: None declared.

REFERENCES

1. Ried M, Bein T, Philipp A, Müller T, Graf B, Schmid C, et al. Extracorporeal lung support in trauma patients with severe chest injury and acute lung failure: a 10-year institutional experience. *Crit Care* 2013;17:R110.
2. Vecsei V, Arbes S, Aldrian S, Nau T. Chest injuries in polytrauma. *Eur J Trauma* 2005;31:239–43.
3. Arlt M, Philipp A, Voelkel S, Rupprecht L, Mueller T, Hilker M, et al. Extracorporeal membrane oxygenation in severe trauma patients with bleeding shock. *Resuscitation* 2010;81:804–9.
4. Wen PH, Chan WH, Chen YC, Chen YL, Chan CP, Lin PY. Non-heparinized ECMO serves a rescue method in a multitrauma patient combining pulmonary contusion and nonoperative internal bleeding: a case report and literature review. *World J of Emerg Surg* 2015;10:15.
5. Rossaint R, Cerny V, Coats TJ, Duranteau J, Fernández-Mondéjar E, Gordini G, et al. Key issues in advanced bleeding care in trauma. *Shock* 2006;26:322–31.
6. Cordell-Smith JA, Roberts N, Peek GJ, Firmin RK. Traumatic lung injury treated by extracorporeal membrane oxygenation (ECMO). *Injury* 2006;37:29–32.
7. Madershahian N, Wittwer T, Strauch J, Franke UF, Wippermann J, Kaluza M, et al. Application of ECMO in multitrauma patients with ARDS as rescue therapy. *J Card Surg* 2007;22:180–4.

OLGU SUNUMU - ÖZET

Travmaya baęlı ciddi akcięer kontüzyonu ve hipovolemik řoku olan bir hastaya heparin verilmeden uygulanan venovenöz ECMO

Dr. Seong Ho Moon, Dr. Ki Nyun Kim, Dr. Jae Jun Jung, Dr. Jae Hong Park, Dr. Joung Hun Byun

¹Gangwongsang Ulusal Üniversitesi Tıp Fakültesi, Göęüs ve Kalp Damar Cerrahisi Bölümü, Changwon Hastanesi, Changwon, Güney Kore

²Sungkyunkwan Üniversitesi Tıp Fakültesi, Göęüs ve Kalp-Damar Cerrahisi Bölümü, Samsung Changwon Hastanesi, Gyeongsangnam-do, Güney Kore

Akcięer aşırı derecede hasarlandığında ve konvansiyonel tedavi başarısız olduęunda venovenöz ekstrakorporeal membran oksijenizasyonu (VV-ECMO) kritik rol oynar. ECMO dokunun yeterince oksijenlenmesine ve akcięerin toparlanmasına olanak saęlar. Tedavi sırasında sistemik antikoagülasyon uygulandıęından kanama riski olan hastalarda ECMO kontrendike olmayı sürdürmektedir. Yirmi altı yaşımda kadın hasta gelmeden bir saat önce trafik kazası nedeniyle politravma geçirmiř. Basit torasik radyografi ve bilgisayarlı tomografi saę akcięer atelektaziyle birlikte geniř bir saę hemopnömotoraks ve saę akcięerde ciddi kontüzyonun varlıęını gösterdi. ECMO desteęi altında başarıyla saę alt lob çıkartıldı. Hemorajik řoklu politravma hastalarında kontrendike olmasına raęmen kanama iyice kontrol altına alınmiřsa ECMO uygulaması mümkün olabilir. Hasta önemli bir komplikasyon olmaksızın taburcu edilmiřtir.

Anahtar sözcükler: Ekstrakorporeal membran oksijenizasyonu; hemorajik řok; politravmatik.

Ulus Travma Acil Cerrahi Derg 2018;24(5):497-500 doi: 10.5505/tjtes.2018.33802