

# Radiological outcomes of two non-surgical management methods for mid-shaft clavicle fractures in school-age children: No difference between figure-of-eight bandage and arm sling

Ali Engin Daştan,<sup>1</sup> Arman Vahabi,<sup>2</sup> Volga Öztürk,<sup>2</sup> Taha Ahmet Türkoğlu,<sup>2</sup>

Aytek Hüseyin Çeliksöz,<sup>3</sup> Okan Tezgel,<sup>4</sup> Levent Küçük,<sup>5</sup> Erhan Coşkunol,<sup>2</sup> Kemal Aktuğlu<sup>2</sup>

<sup>1</sup>Department of Hand Surgery, Izmir City Hospital, Izmir-Türkiye

<sup>2</sup>Department of Orthopedics and Traumatology, Ege University University School of Medicine, Bornova, Izmir-Türkiye

<sup>3</sup>Department of Orthopedics and Traumatology, Eskişehir City Hospital, Eskişehir-Türkiye

<sup>4</sup>Department of Orthopedics and Traumatology, Medipol Bahçelievler Hospital, İstanbul-Türkiye

<sup>5</sup>Department of Orthopedics and Traumatology, Medicana International Hospital, Izmir-Türkiye

## ABSTRACT

**BACKGROUND:** Although non-surgical management is a commonly used treatment for pediatric clavicle fractures, there is limited data in the literature regarding the most effective method. This study aims to compare the radiological outcomes of the figure-of-eight bandage versus the arm sling in the treatment of mid-shaft clavicle fractures in school-age children.

**METHODS:** Patients were divided into two groups based on the preferred conservative management method: Group 1 (arm sling) and Group 2 (figure-of-eight bandage). The degree of angulation and shortening was measured at initial admission and during follow-up. Demographic characteristics and radiological data were compared between the two groups.

**RESULTS:** Group 1 included 10 girls and 10 boys, while Group 2 included 12 girls and 17 boys ( $p=0.761$ ). The mean shortening at initial presentation was  $7.28\pm 6.06$  mm in Group 1 and  $6.65\pm 5.58$  mm in Group 2 ( $p=0.625$ ). At follow-up, the mean shortening was  $6.24\pm 5.59$  mm in Group 1 and  $5.59\pm 4.91$  mm in Group 2 ( $p=0.569$ ). The mean angulation at initial presentation was  $21.28\pm 10.05^\circ$  in Group 1 and  $20.41\pm 12.23^\circ$  in Group 2 ( $p=0.752$ ). At follow-up, the mean angulation was  $14.45\pm 9.41^\circ$  in Group 1 and  $11.82\pm 10.27^\circ$  in Group 2 ( $p=0.189$ ). In intra-group comparisons, no significant difference was found between the initial shortening and follow-up shortening in either group (Group 1:  $p=0.062$ ; Group 2:  $p=0.190$ ). A significant reduction in angulation was observed in both groups during follow-up ( $p=0.001$  for Group 1;  $p=0.001$  for Group 2).

**CONCLUSION:** The radiological outcomes of the figure-of-eight bandage and the arm sling in the treatment of mid-shaft clavicle fractures in school-age children are similar.

**Keywords:** Arm sling; clavicle fracture; conservative treatment; figure-of-eight bandage; pediatric.

Cite this article as: Daştan AE, Vahabi A, Öztürk V, Türkoğlu TA, Çeliksöz AH, et al. Radiological outcomes of two non-surgical management methods for mid-shaft clavicle fractures in school-age children: No difference between figure-of-eight bandage and arm sling. *Ulus Travma Acil Cerrahi Derg* 2025;31:303-309.

Address for correspondence: Arman Vahabi

Department of Orthopedics and Traumatology, Ege University University School of Medicine, Bornova, Izmir, Türkiye

E-mail: armanvy@gmail.com

*Ulus Travma Acil Cerrahi Derg* 2025;31(3):303-309 DOI: 10.14744/tjtes.2025.29946

Submitted: 15.11.2024 Accepted: 18.12.2024 Published: 03.03.2025

OPEN ACCESS This is an open access article under the CC BY-NC license (<http://creativecommons.org/licenses/by-nc/4.0/>).



## INTRODUCTION

Clavicle fractures are among the most common fractures in childhood, with an incidence of up to 15% in this age group.<sup>[1,2]</sup> They most frequently occur in the midshaft region.<sup>[1,3]</sup> Due to the thick periosteum, most clavicle fractures in children are nondisplaced or minimally displaced and can be effectively managed with nonoperative treatment.<sup>[1,4]</sup> Additionally, 80% of clavicular growth is completed by age 9 in girls and age 12 in boys, which means that remodeling capacity is higher in younger children.<sup>[1,5]</sup> As a result, conservative treatment is the preferred approach for pediatric clavicle fractures. However, there is ongoing debate regarding the management of clavicle fractures in adolescents. Since clavicular growth is largely complete by adolescence, the potential for remodeling is reduced,<sup>[1,5]</sup> leading some studies to suggest that surgical treatment may be more beneficial in adolescents.<sup>[3,6]</sup>

Although conservative management is widely used for clavicle fractures, there is limited evidence in the literature regarding the optimal treatment method. The two most commonly employed traditional approaches are the figure-of-eight bandage and the arm sling. In a randomized controlled trial comparing these two methods in adults, researchers found that the arm sling provided better pain control and was easier to apply for clavicle fractures.<sup>[7]</sup> Conversely, a pediatric study indicated that the figure-of-eight bandage may be a more suitable option for children.<sup>[8]</sup>

The aim of this study was to compare the radiological outcomes of the figure-of-eight bandage and the arm sling in the

treatment of mid-shaft clavicle fractures in school-age children. The study was based on the hypothesis that there is no difference between the two treatment methods.

## MATERIALS AND METHODS

This study was conducted as a retrospective comparative analysis at Ege University Hospital. Approval was obtained from the Ege University Clinical Research Ethics Committee (Approval Number: 24-10T/11, Date: 03.10.2024). Data were collected through chart review.

Patients aged 5 to 10 years who presented to the emergency department with isolated mid-shaft clavicle fractures between 2015 and 2020 and had adequate follow-up and radiographs were included in the study. The exclusion criteria included cases of multiple trauma and individuals with a previous history of clavicle fractures (Fig. 1). The treatment of pediatric clavicle fractures at the tertiary university hospital where this study was conducted was managed by two orthopedic consultants. One consultant preferred the figure-of-eight bandage for conservative management. The other consultant favored the arm sling. Patients were divided into two groups based on the treatment method employed. The collected data included patient age, gender, and clavicle fracture classification based on the Robinson system.<sup>[9]</sup> The degree of angulation and shortening were measured at initial admission and final follow-up, and union status was recorded. The data were then compared between the two groups.

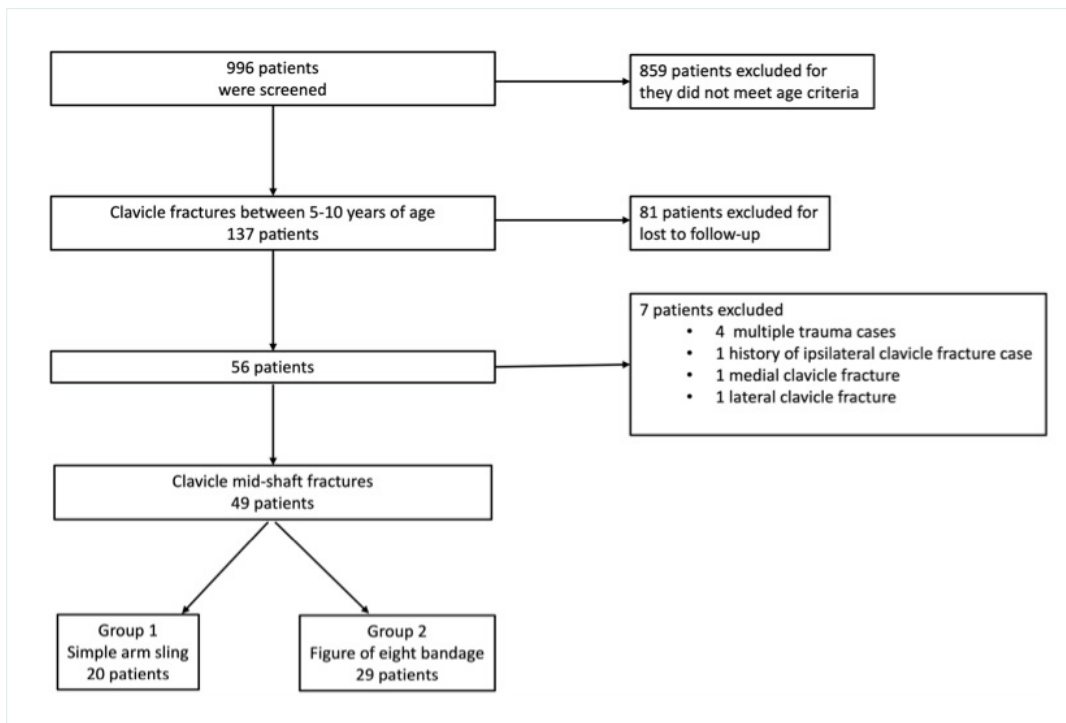
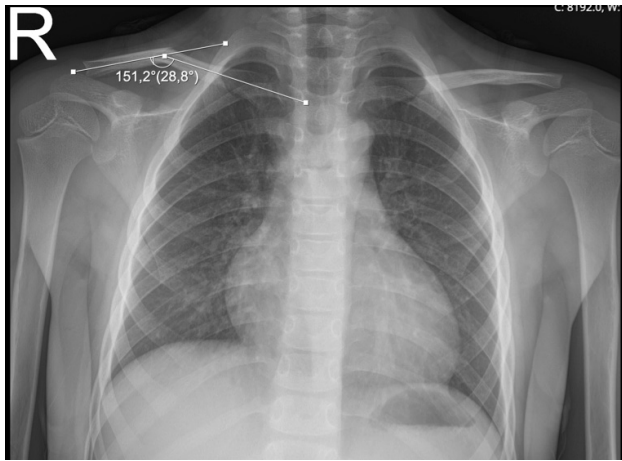


Figure 1. Flowchart of the patients.



**Figure 2.** Example of the measurement of clavicle angulation. Angulation was determined by measuring the angle between the lines passing through the midpoint of the medulla of the fractured clavicle.

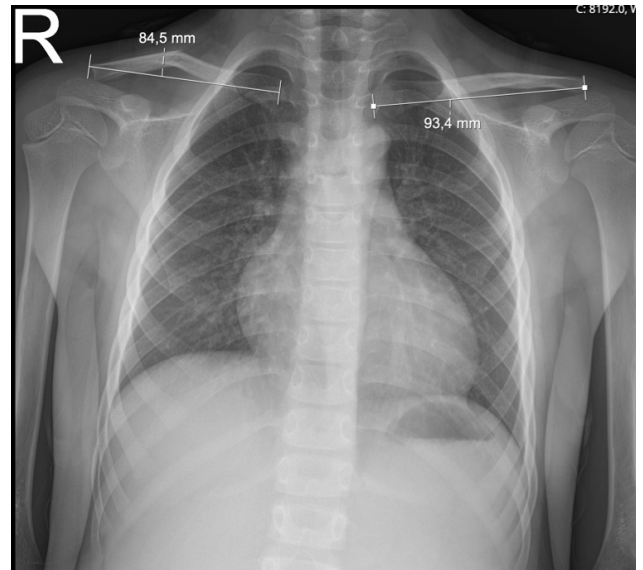
### Follow-up Protocol

All patients referred to the Orthopedics and Traumatology Department with a diagnosis of clavicle fracture underwent a comprehensive orthopedic examination, including a neurovascular assessment. Based on the consultant's treatment preference, either an arm sling or a figure-of-eight bandage was applied. The patient's family was instructed on the proper application technique, and analgesia was prescribed as needed. Follow-up appointments were scheduled 7 to 10 days later, depending on clinic availability.

During the initial follow-up visit, the use of the bandage or sling was verified, and any errors in application were corrected. The family was re-educated on proper usage, and a repeat neurovascular examination was performed. Further follow-up was scheduled for the third or fourth week post-injury, depending on the patient's age, consultant preference, and availability. An X-ray was obtained during this visit to assess fracture healing. If the patient experienced pain relief upon palpation and callus formation was visible on the radiograph, immobilization was discontinued. The patient and family were then encouraged to begin passive and active movements of the affected extremity. A final follow-up appointment was scheduled for the third month post-injury. If no movement restrictions or pain were noted upon palpation of the fracture site, no additional radiographs were obtained, and follow-up was concluded.

### Assessment of the Radiographs

Radiological evaluations and measurements were performed using Sectra version 22.1 software (Sectra AB, Linköping, Sweden). Angulation was determined by measuring the angle between lines passing through the midpoint of the medullary canal of the fractured clavicle (Fig. 2). Radiological shortening was assessed on radiographs that included both clavicles. The distance between the acromioclavicular joint and the ster-



**Figure 3.** Example of the measurement of clavicle shortening. The amount of shortening was measured by subtracting the length of the fractured clavicle from that of the contralateral uninjured clavicle ( $93.4 - 84.5 = 8.9$  mm). The percentage of shortening was determined by dividing the amount of shortening by the length of the contralateral uninjured clavicle ( $8.9 / 93.4 \times 100 = 9.53\%$ ).

noclavicular joint was measured for both the fractured and uninjured clavicle. The amount of shortening was determined by subtracting the length of the fractured clavicle from that of the uninjured clavicle. The percentage of shortening was then determined by dividing the measured shortening by the length of the uninjured clavicle (Fig. 3).

Measurements were independently performed by three researchers, and the average value of the obtained measurements was used for analysis. In cases where discrepancies greater than 10% were observed between measurements, final values were determined through face-to-face discussions among the researchers before inclusion in the analysis.

### Statistical Analysis

Data analysis was performed using SPSS version 26 (Chicago, IL, USA). The normality of the distribution was assessed using the Kolmogorov-Smirnov test. Since none of the data followed a normal distribution, nonparametric tests were used for analysis. The Mann-Whitney U test was used to compare independent continuous variables. The Wilcoxon Signed-Rank test was used to compare related continuous variables. The chi-square test was applied for comparisons of categorical variables. A p-value of less than 0.05 was considered statistically significant. Post hoc power analysis was performed using G\*Power software (version 3.1.9.7; Dusseldorf, Germany). The effect size was set at 0.5, and the alpha error probability was 0.05. The post hoc power values for the Mann-Whitney test, Wilcoxon Signed-Rank test for Group 1, Wilcoxon Signed-Rank test for Group 2, and chi-square test were 0.35, 0.5, 0.67, and 0.93, respectively.

**Table 1.** Comparison of the groups

	Group	Mean	Standard Deviation	Median	Minimum	Maximum	25 <sup>th</sup> Percentile	75 <sup>th</sup> Percentile	p
Age (years)	Group 1	6.90	1.62	6.50	5.00	10.00	6.00	7.00	0.723
	Group 2	6.90	1.90	6.00	5.00	10.00	5.00	8.00	
Initial shortening (mm)	Group 1	7.28	6.06	4.95	1.00	26.20	3.50	9.70	0.625
	Group 2	6.65	5.58	4.40	0.30	24.20	2.80	10.10	
Follow-up shortening (mm)	Group 1	6.24	5.03	5.10	0.50	17.90	2.15	9.65	0.569
	Group 2	5.59	4.91	4.20	0.10	20.60	2.30	6.80	
Δ shortening (mm)	Group 1	-1.04	3.27	-0.55	-8.40	6.50	-1.90	0.15	0.535
	Group 2	-1.06	2.94	-0.40	-9.40	3.50	-1.80	0.70	
Percentage of initial shortening (%)	Group 1	7.07	5.69	4.93	1.01	24.51	3.42	9.81	0.871
	Group 2	6.88	5.36	5.24	0.33	23.47	2.87	10.13	
Percentage of follow-up shortening (%)	Group 1	6.00	4.72	4.86	0.45	16.75	2.01	9.08	0.776
	Group 2	5.73	4.76	4.41	0.12	19.98	2.35	8.75	
Δ percentage of shortening (%)	Group 1	-1.06	3.15	-0.58	-8.99	5.61	-1.80	0.15	0.654
	Group 2	-1.15	3.05	-0.43	-10.40	3.57	-2.16	0.55	
Initial angulation (°)	Group 1	21.28	10.05	22.75	3.30	39.50	12.90	27.30	0.752
	Group 2	20.41	12.23	21.60	0.60	38.80	8.20	30.70	
Follow-up angulation (°)	Group 1	14.45	9.41	14.35	1.20	30.90	6.10	22.40	0.189
	Group 2	11.82	10.27	8.50	0.50	53.00	4.90	16.50	
Δ angulation (°)	Group 1	-6.84	7.31	-6.75	-22.70	6.80	-12.60	-1.50	0.562
	Group 2	-8.59	11.00	-8.90	-30.40	17.80	-17.00	0.20	

Group 1: Arm sling; Group 2: Figure-of-eight bandage.

## RESULTS

A review of hospital records revealed that 996 patients were referred from the emergency department to the Orthopedics and Traumatology Department over a five-year period. Among these, 137 patients met the age criteria for inclusion. However, 81 patients were excluded from the analysis due to loss to follow-up. Of the remaining 56 patients, four were excluded due to multiple trauma, one was excluded due to a history of ipsilateral clavicle fracture, one had a lateral-end clavicle fracture, and one had a medial-end clavicle fracture. Ultimately, 49 patients with mid-shaft clavicle fractures were included in the study (Fig. 1). The patients were categorized into two groups based on the type of immobilization applied: Group 1 (arm sling, n=20) and Group 2 (figure-of-eight bandage, n=29).

Group 1 comprised 10 girls and 10 boys, while Group 2 consisted of 12 girls and 17 boys (p=0.761). Age comparison between the groups revealed no statistically significant difference [6.50 (5-10) years vs. 6 (5-10) years (median (min./max.)), p=0.723] (Table 1). Additionally, there was no significant difference between the groups concerning Robinson classification (p=0.529) (Table 2). Radiological union was observed in all patients at follow-up.

When comparing the amount of clavicle shortening (in mil-

limeters) between the two groups, no statistically significant difference was observed. The mean shortening at initial presentation was 7.28±6.06 mm in Group 1 and 6.65±5.58 mm in Group 2 (p=0.625). The mean shortening at follow-up was 6.24±5.59 mm in Group 1 and 5.59±4.91 mm in Group 2 (p=0.569). The mean change in shortening (Δ shortening) was -1.04±3.27 mm in Group 1 and -1.06±2.94 mm in Group 2 (p=0.535) (Table 3).

Similarly, no significant difference was found in the percentage of shortening. The mean percentage of shortening at initial presentation was 7.07±5.69% in Group 1 and 6.88±5.36% in Group 2 (p=0.871). At follow-up, the mean percentage of shortening was 6.0±4.72% in Group 1 and 5.73±4.76% in Group 2 (p=0.776). The mean change in percentage of shortening (Δ shortening) was -1.06±3.15% in Group 1 and -1.15±3.05% in Group 2 (p=0.654).

No statistically significant difference was found regarding angulation at the fracture site. The mean angulation at initial presentation was 21.28±10.05° in Group 1 and 20.41±12.23° in Group 2 (p=0.752). The mean angulation at follow-up was 14.45±9.41° in Group 1 and 11.82±10.27° in Group 2 (p=0.189). The mean change in angulation (Δ angulation) was -6.84±7.31° in Group 1 and -8.59±11.0° in Group 2 (p=0.562).

**Table 2.** Robinson classifications of the patients

		Group				Total	p	
		Group 1		Group 2				
		N	%	N	%			N
Robinson Classification	2A1	1	5.0%	2	6.9%	3	6.1%	...
	2A2	12	60.0%	13	44.8%	25	51.0%	
	2B1	5	25.0%	14	48.3%	19	38.8%	
	2B2	2	10.0%	0	0.0%	2	4.1%	
Total	20	100.0%	29	100.0%	49	100.0%		
Robinson Classification	2A1 + 2A2	13	65.0%	15	51.7%	28	57.1%	0.529
	2B1 + 2B2	7	35.0%	14	48.3%	21	42.9%	
Total	20	100.0%	29	100.0%	49	100.0%		

Group 1: Arm sling; Group 2: Figure-of-eight bandage.

**Table 3.** Inter-group comparisons

	Group 1 (n=20) Median (IQR)	Group 2 (n=29) Median (IQR)
Initial shortening (mm)	4.95 (3.50-9.70)	4.40 (2.80-10.10)
Follow-up shortening (mm)	5.10 (2.15-9.65)	4.20 (2.30-6.80)
$\Delta$ shortening (mm)	-0.55 (-1.90-0.15)	-0.40 (-1.80-0.70)
P	0.062	0.190
Percentage of initial shortening (%)	4.93 (3.42-9.81)	5.24 (2.87-10.13)
Percentage of follow-up shortening (%)	4.86 (2.01-9.08)	4.41 (2.35-8.75)
$\Delta$ percentage of shortening (%)	-0.58 (-1.79-0.15)	-0.43 (-2.16-0.55)
P	0.062	0.139
Initial angulation (°)	22.75 (12.9-27.3)	21.6 (8.2-30.7)
Follow-up angulation (°)	14.35 (6.1-22.4)	8.5 (4.9-16.5)
$\Delta$ angulation (°)	-6.7 (-12.6--1.5)	-8.9 (-17-0.2)
P	0.001	0.001

Bold values indicate statistical significance at  $p < 0.05$ . Group 1: Arm sling; Group 2: Figure-of-eight bandage. IQR: Interquartile range.

In intra-group comparisons, no significant difference was observed between initial and follow-up shortening in either group ( $p=0.062$  for Group 1;  $p=0.190$  for Group 2). Similarly, no difference was found between the initial and final percentage of shortening in both groups ( $p=0.062$  for Group 1;  $p=0.139$  for Group 2). However, angulation significantly decreased in both groups during the follow-up period ( $p=0.001$  for Group 1;  $p=0.001$  for Group 2).

## DISCUSSION

The primary finding of this study is that the radiological outcomes of the figure-of-eight bandage and arm sling for mid-

shaft clavicle fractures in school-age children are comparable. Most pediatric clavicle fractures can be treated non-surgically,<sup>[4]</sup> and nonunion is rare in this age group.<sup>[10]</sup>

Surgical indications for pediatric clavicle fractures are generally limited. Kubiak et al.<sup>[11]</sup> reported that operative treatment is typically required in older children. They identified open fractures, soft tissue impingement or potential skin perforation, severe shortening of the shoulder girdle, and displaced fractures with potential risks to the neurovascular bundle or mediastinal structures as indications for surgery.<sup>[11]</sup> The optimal treatment approach for adolescents remains controversial due to the reduced remodeling capacity of the clavicle in



this age group. Some studies suggest that surgical treatment may yield better outcomes in adolescents.<sup>[1,3,5,6]</sup> In a systematic review and meta-analysis, Gao et al.<sup>[12]</sup> analyzed 12 studies involving 497 patients with a mean age of 14.1 years (range: 8-18 years). They concluded that both operative and non-operative treatments for displaced mid-shaft clavicle fractures in this age group result in excellent union rates and patient-reported outcomes. Surgically treated patients experienced a faster return to activity; however, surgical management was associated with higher complication rates.<sup>[12]</sup> In the present study, non-surgical management of mid-shaft clavicle fractures led to favorable radiological outcomes in all patients.

Although non-surgical treatment is commonly used for pediatric clavicle fractures, there is limited data in the literature regarding the most effective method. Sisman et al.<sup>[8]</sup> reviewed 41 patients aged 2-9 years and found no significant difference between the arm sling and the figure-of-eight bandage in the conservative treatment of clavicle fractures. They reported similar radiological and clinical outcomes in both groups. In the present study, radiological results were also comparable between the two treatment methods. However, functional outcomes were not assessed in this study.

Radiological measurements were dependent on the quality of the radiographs. To minimize errors in this study, measurements were performed independently by three researchers, and the average value was used for analysis. In cases where a discrepancy of more than 10% was observed between measurements, the final values were determined by consensus during face-to-face discussions among the researchers. Furthermore, due to potential variations in clavicle lengths within the age group assessed in this study, shortening was evaluated both in millimeters and as a percentage.

In a randomized controlled trial, Ersen et al.<sup>[7]</sup> compared the use of a simple arm sling and a figure-of-eight bandage for mid-shaft clavicle fractures in adults. They concluded that the broad arm sling was preferable due to its ability to reduce early pain and its ease of application. However, the present study does not provide data on ease of application or its impact on pain. A randomized controlled trial evaluating these factors in the pediatric population would be a valuable contribution to the literature.

This study has several limitations. First, it was designed as a retrospective analysis, which may introduce potential biases. Second, the sample size is relatively small, and a significant number of patients were lost to follow-up during the study period. Third, the study does not include assessments of functional outcomes, clinical scores, or pain scores, which would provide a more comprehensive evaluation of treatment effectiveness.

## CONCLUSION

The radiological outcomes of the figure-of-eight bandage and arm sling for mid-shaft clavicle fractures in this pediatric

population are comparable. Further studies assessing clinical outcomes and ease of application are needed to establish a definitive consensus on the optimal treatment approach for this patient group.

**Ethics Committee Approval:** This study was approved by the Ege University Clinical Research Ethics Committee (Date: 03.10.2024, Decision No: 24-10T/11).

**Peer-review:** Externally peer-reviewed.

**Use of AI for Writing Assistance:** ChatGPT 4.0 was used to enhance the English language

**Authorship Contributions:** Concept: K.A., E.C.; Design: A.E.D., A.V., L.K.; Supervision: K.A., E.C., L.K.; Resource: V.Ö., T.A.T., A.H.Ç.; Materials: T.A.T., A.H.Ç., A.V.; Data Collection and/or Processing: V.Ö., T.A.T., A.V., O.T.; Analysis and/or Interpretation: A.E.D., O.T., V.Ö.; Literature Review: A.E.D., A.H.Ç., O.T.; Writing: A.E.D., A.V.; Critical Review: K.A., E.C., L.K.

**Conflict of Interest:** None declared.

**Financial Disclosure:** The author declared that this study has received no financial support.

## REFERENCES

1. Caird MS. Clavicle shaft fractures: Are children little adults? *J Pediatr Orthop* 2012;32:S1-4. [\[CrossRef\]](#)
2. Bilge O, Kekeç AF, Atılgan N, Yaka H, Dundar ZD, Karagüven D, et al. The initial analysis of pediatric fractures according to the AO/OTA fracture classification and mechanisms of injuries. *Ulus Travma Acil Cerrahi Derg* 2022;28:1500-7. [\[CrossRef\]](#)
3. Vander Have KL, Perdue AM, Caird MS, Farley FA. Operative versus nonoperative treatment of midshaft clavicle fractures in adolescents. *J Pediatr Orthop* 2010;30:307-12. [\[CrossRef\]](#)
4. O'Neill BJ, Molloy AP, Curtin W. Conservative management of paediatric clavicle fractures. *Int J Pediatr* 2011;2011:172571. [\[CrossRef\]](#)
5. McGraw MA, Mehlman CT, Lindsell CJ, Kirby CL. Postnatal growth of the clavicle: Birth to 18 years of age. *J Pediatr Orthop* 2009;29:937-43. [\[CrossRef\]](#)
6. Mehlman CT, Yihua G, Bochang C, Zhigang W. Operative treatment of completely displaced clavicle shaft fractures in children. *J Pediatr Orthop* 2009;29:851-5. [\[CrossRef\]](#)
7. Ersen A, Atalar AC, Birisik F, Saglam Y, Demirhan M. Comparison of simple arm sling and figure of eight clavicular bandage for mid-shaft clavicular fractures: A randomised controlled study. *Bone Joint J* 2015;97:1562-5. [\[CrossRef\]](#)
8. Sisman A, Poyraz C, Cicek AC, Kor S, Cullu E. Are there any differences between the shoulder-arm sling and figure-of-eight bandage in the conservative treatment of paediatric clavicle fractures? *J Child Orthop* 2021;15:540-5. [\[CrossRef\]](#)
9. Robinson CM. Fractures of the clavicle in the adult. Epidemiology and classification. *J Bone Joint Surg Br* 1998;80:476-84. [\[CrossRef\]](#)
10. Hughes K, Kimpton J, Wei R, Williamson M, Yeo A, Arnander M, et al. Clavicle fracture nonunion in the paediatric population: A systematic review of the literature. *J Child Orthop* 2018;12:2-8. [\[CrossRef\]](#)
11. Kubiak R, Slongo T. Operative treatment of clavicle fractures in children: A review of 21 years. *J Pediatr Orthop* 2002;22:736-9. [\[CrossRef\]](#)
12. Gao B, Dwivedi S, Patel SA, Nwizu C, Cruz AI Jr. Operative versus non-operative management of displaced midshaft clavicle fractures in pediatric and adolescent patients: A systematic review and meta-analysis. *J Orthop Trauma* 2019;33:e439-46. [\[CrossRef\]](#)

ORİJİNAL ÇALIŞMA - ÖZ

## Okul çağı çocuklarındaki klavikula orta diafiz kırıklarında iki cerrahi dışı tedavi yönteminin radyolojik sonuçları: Sekiz bandajı ile kol askısı benzer etkinliğe sahiptir

**AMAÇ:** Cerrahi dışı tedavi, pediatrik klavikula kırıklarında için sıklıkla kullanılması, hangi yöntemle yapılacağına dair literatürde sınırlı veri bulunmaktadır. Çalışmanın amacı, okul çağı çocuklarındaki klavikula orta diafiz kırıklarında sekiz bandajı ve kol askısının radyolojik sonuçlarını karşılaştırmaktır.

**GEREÇ VE YÖNTEM:** Hastalar tercih edilen konservatif tedavi yöntemine göre iki gruba ayrıldı. (Grup 1: kol askısı, Grup 2: sekiz bandajı). İlk başvuruda ve takipte açılanma ve kılma miktarı ölçüldü. Genel özellikler ve radyolojik veriler iki grup arasında karşılaştırıldı.

**BULGULAR:** Grup 1'de 10 kız ve 10 erkek, Grup 2'de ise 12 kız ve 17 erkek vardı ( $p=0.761$ ). Grup 1'de ilk başvurudaki ortalama kılma  $7.28\pm 6.06$  mm ve Grup 2'de  $6.65\pm 5.58$  mm idi ( $p=0.625$ ). Takipteki ortalama kılma Grup 1'de  $6.24\pm 5.59$  mm ve Grup 2'de  $5.59\pm 4.91$  mm idi ( $p=0.569$ ). Başlangıç başvurusundaki ortalama açılanma Grup 1'de  $21.28\pm 10.05^\circ$  ve Grup 2'de  $20.41\pm 12.23^\circ$  idi ( $p=0.752$ ). Takipteki ortalama açılanma Grup 1'de  $14.45\pm 9.41^\circ$  idi; Grup 2'de  $11.82\pm 10.27^\circ$  ( $p=0.189$ ). Grup içi karşılaştırmalarda, her iki grupta da başlangıç kılma miktarı ile takipteki kılma miktarı arasında anlamlı bir fark bulunmadı [ $p=0.062$  (grup 1);  $p=0.190$  (grup 2)]. Açılma değerler incelendiğinde, iki grupta da takipler sırasında açılanma miktarının istatistiksel olarak anlamlı şekilde azaldığı görüldü [ $p=0.001$  (grup 1);  $p=0.001$  (grup 2)].

**SONUÇ:** Okul çağı çocuklarındaki klavikula orta diafiz kırıklarında sekiz bandajı ve kol askısının radyolojik sonuçları benzerdir.

**Anahtar sözcükler:** Klavikula kırığı; pediatrik; kol askısı; konservatif tedavi; sekiz bandajı.

Ulus Travma Acil Cerrahi Derg 2025;31(3):303-309 DOI: 10.14744/tjtes.2025.29946