

Primary exploration for radial nerve palsy associated with unstable closed humeral shaft fracture

Soo-Hong Han, M.D., In Tae Hong, M.D., Ho Jae Lee, M.D., Sang June Lee, M.D.,
Uk Kim, M.D., Dong Won Kim, M.D.

Department of Orthopaedic Surgery, CHA Bundang Medical Center, School of Medicine, CHA University, Seong-nam-Republic of Korea

ABSTRACT

BACKGROUND: The treatment of radial nerve palsy caused by closed humeral shaft fracture is a matter of debate. The purpose of this study is to evaluate the outcome of early surgical management of radial nerve palsy in patients with unstable closed humeral shaft fractures and to determine whether patients with this injury should be surgically explored.

METHODS: Medical records of 15 consecutive patients who had undergone open reduction and internal fixation for unstable closed humeral shaft fractures were reviewed. Injury mechanisms, radiographs, intraoperative findings of the injured nerve, and clinical improvement were analyzed. Of the 15 patients, two were injured during simple falls, two during baseball pitching, one by a fall from a height, one during skiing, and one by direct machine impaction during work. Fracture locations were middle humerus in six patients, middle-distal in eight patients, and middle-proximal in one patient. Fracture patterns were transverse fracture in six patients, butterfly segment fracture in four patients, oblique segment fracture in three patients, and spiral fracture in two patients.

RESULTS: Eleven patients showed macroscopically intact nerves, and four had total nerve transection. All four patients with total nerve transection were injured in traffic accident. Of these four patients, one showed comminuted fracture with butterfly fragment on the middle-distal shaft and the other three showed displaced transverse fracture on the middle to middle-distal shaft area. Transected nerves were directly repaired in two patients. In the other two patients, humerus shortening and nerve grafting were performed because of mangled nerve endings. All patients who had intact nerves showed fully recovered function at the last follow-up.

CONCLUSION: For radial nerve palsy accompanied by unstable humeral shaft fracture, primary exploration of the radial nerve and open reduction and plate fixation of the fracture should be considered as a treatment of choice. High-energy trauma, fracture location at the middle-distal humerus, and simple transverse fracture or comminuted fracture with butterfly fragment seems to be risk factors for radial nerve transection.

Keywords: Humeral fracture; primary exploration; radial nerve palsy.

INTRODUCTION

Radial nerve palsy is commonly accompanied with humeral shaft fracture. The overall incidence of radial nerve palsy after humeral shaft fracture is 11.8% according to the recent systematic review.^[1] As radial nerve is relatively fixed anatomi-

cally by spiral groove of the humeral shaft and lateral intermuscular septum of the arm, fracture at this level can easily damage the nerve.^[2]

The treatment of radial nerve palsy caused by the closed humeral shaft fracture is a matter of debate.^[1-3] Some authors recommend early exploration of the radial nerve and open reduction and fixation of the fracture, whereas others advocate conservative treatment of the fracture and a strategy of expectant management for radial nerve palsy.^[4-10] Korompilias et al. recommended 16–18 weeks of expectant management, followed by surgical intervention due to high rate of spontaneous recovery of radial nerve after closed humeral shaft fracture.^[2]

The treatment of closed humeral shaft fracture itself is controversial. There is no sufficient evidence available to ascertain whether surgical intervention of humeral shaft fractures results in a better or worse outcome than no surgery.^[11] However, surgery is recommended in cases with unstable

Address for correspondence: Soo-Hong Han, M.D.
Department of Orthopaedic Surgery, CHA Bundang Medical
Center, School of Medicine, CHA University, Seong-nam,
Republic of Korea Seong-nam - South Korea
Tel: (82)10-8668-0559 E-mail: hsoohong@hanmail.net

Submitted: 01.05.2016
Accepted: 09.02.2017

Ulus Travma Acil Cerrahi Derg
2017;23(5):405–409
doi: 10.5505/tjtes.2017.26517



Copyright 2017
TJTES

fracture, $>20^\circ$ angulation anterior/posterior, $>30^\circ$ varus/valgus, inability to maintain a reduction, floating elbow, and polytrauma.^[12] Furthermore, due to improvement of surgical technique and implants, a marked increase in the surgical treatment of humeral shaft fractures was seen.^[13] Therefore, for the treatment of radial nerve palsy associated with unstable closed humeral shaft fracture, early exploration of the radial nerve together with open reduction and internal fixation of the fracture may help confirm nerve injury on early stage and also prevent further nerve damage.

Although treatment is a controversial subject, certain principles of management must be applied. The purpose of this study is to evaluate the outcome of early surgical management of radial nerve palsy in patients with unstable closed humeral shaft fractures and to determine whether patients with this injury should be surgically explored.

MATERIALS AND METHODS

Medical records of 15 consecutive patients who had undergone open reduction and internal fixation for closed humeral shaft fractures between March 2001 and February 2012 were reviewed after institutional review board approval. Operative standards used for closed humeral shaft fractures are as follows: $>20^\circ$ angulation anterior/posterior, $>30^\circ$ varus/valgus, inability to maintain a reduction, floating elbow, and polytrauma.^[12] Inclusion criteria for this study were closed humeral shaft fracture, complete motor and sensory deficit of radial nerve, age >20 at the time of injury, and follow-up period of at least 12 months.

This study was conducted on 15 patients who had primary exploration for radial nerve and open reduction and plate fixation for closed humeral shaft fracture. Twelve male and three female patients with an average age of 39.8 years (20–66 years) were included. The average follow-up period was 2.4 years (14 months–4 years). All 15 patients visited the emergency room, applied a U-slap splint, and had their X-rays taken. All cases were of unilateral fractures with no accompanying damage. Physical examination of the radial nerve was initially performed at the emergency room. Motor powers of the wrist and metacarpophalangeal joints extension and sensory of the first web space were assessed.

Of 15 patients, the most common cause of injury was by traffic accident in eight patients (five in car, two pedestrians, and one motorcycle). Two patients were injured by simple falls, two during baseball pitching, one by falling from a height, one during skiing, and one by direct machine impaction during work (Table 1). Fracture locations were middle humerus in six patients, middle-distal in eight patients, and middle-proximal in one patient (Table 2). Fracture patterns were transverse fracture in six patients, butterfly segment fracture in four patients, oblique segment fracture in three patients, and spiral fracture in two patients (Table 3).

Table 1. Radial nerve palsy in relation to injury mechanism

Injury mechanism	Traffic accident	Simple fall	Fall from height	Sports injury	Direct trauma
	8 (4)*	2	1	3	1

*Patients with complete nerve transection are shown in parentheses.

Table 2. Radial nerve palsy in relation to fracture location

Fracture location	Middle-proximal	Middle	Middle-distal
	1	6 (1)*	8 (3)*

*Patients with complete nerve transection are shown in parentheses.

Table 3. Radial nerve palsy in relation to fracture type

Fracture type	Transverse	Butterfly	Oblique	Spiral
	6 (3)*	4 (1)*	3	2

*Patients with complete nerve transection are shown in parentheses.

Surgery was performed after an average of 3 days after admission to the hospital. All cases were managed by open reduction and internal fixation with plates and screws, which would allow for direct fracture reduction and visualization of the radial nerve. Standard anterolateral approach was used in all cases. After dissecting the internervous plane between brachialis and brachioradialis, the radial nerve and fracture site were identified. The radial nerve was thoroughly explored using loupes. Meticulous technique was used so as not to damage the nerve. With the radial nerve in protection, reduction and fixation of the fracture was performed using 4.5-mm limited-contact dynamic compression plate (Synthes, West Chester, USA). In case of complete transection of the radial nerve, neurolysis and repair of the injured radial nerve was performed by epi-perineural suture technique using a monofilament (Ethicon Nylon black monofilament, 8–0). Postoperatively, we applied long arm splint until 1–2 weeks. Gentle progressive range of motion exercises was permitted just after the removal of the splint. We recommend wearing low-profile short arm braces for radial nerve palsy until motor power is recovered to grade >4 .

Changes in symptoms were verified through observation at outpatient visits to the hospital. Based on data acquired through these observations, injury mechanisms, and intraoperative findings of nerve injury, clinical improvements (union, grip power, and wrist range of motion) at the last follow-up were evaluated. On radiographs, fracture location was analyzed. The three diaphyseal middle parts (middle-proximal, middle, and middle-distal) were included as shaft fractures in this study. Fracture patterns were also examined on the initial radiographs.

Neurological examination was conducted using the medical research council neurological scale, and for motor function, wrist and digit extension at the metacarpophalangeal joint were evaluated.^[14] Each follow-up observation was made during outpatient visits on postoperative 1 and 6 weeks, 3 and 6 months, and 1 and 2 years.

RESULTS

Surgical exploration of the radial nerve was performed in all patients. Eleven patients showed macroscopically intact nerves (Fig. 1), and four underwent total nerve transection. All four patients with total nerve transection were injured in traffic accident. Of these four patients, one showed comminuted fracture with butterfly fragment on the middle-distal shaft and the other three patients showed displaced transverse fracture on the middle to middle-distal shaft area. Transected nerves were directly repaired in two patients (Fig. 2). In the other two patients, humerus shortening and nerve grafting was performed because of mangled nerve endings.

All patients with intact nerves showed fully recovered function of wrist and finger extension at the metacarpophalangeal

joint at the last follow-up. The mean time to full functional recovery in patients with intact nerve was 5 months with a range of 1–9 months, whereas it was 13 months after surgery with a range of 12–15 months in patients with completely transected nerve. The mean time to fracture healing was 3 months with a range of 2–6 months. There was no acute or late complication, such as nonunion and infection, in all cases.

DISCUSSION

In our study, complete nerve transection was found in 26.7% (4 out of 15) of all cases. Common fracture patterns and location in complete nerve transected patients were transverse fractures on the middle to middle-distal shaft in three patients and comminuted fracture with a butterfly fragment on the middle shaft in one patient (Table 4). Nerve injury was most commonly associated with high-energy trauma, and all patients with transected nerve were injured through traffic accidents. Our result also showed that all patients with radial nerve palsy associated with humeral shaft fracture fully recovered function at the final follow-up.

An anatomic cadaver study demonstrated that the radial

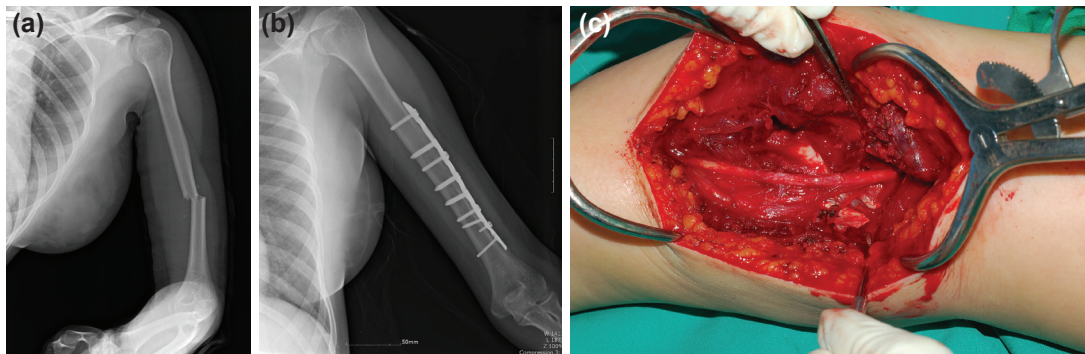


Figure 1. A 22-year-old injured in a motor vehicle accident with middle-distal transverse humeral shaft fracture. (a) Preoperative radiograph demonstrating displaced fracture on middle-distal humeral shaft. (b) Postoperative radiograph of patients who underwent open reduction and plate fixation. (c) Macroscopically intact radial nerve.

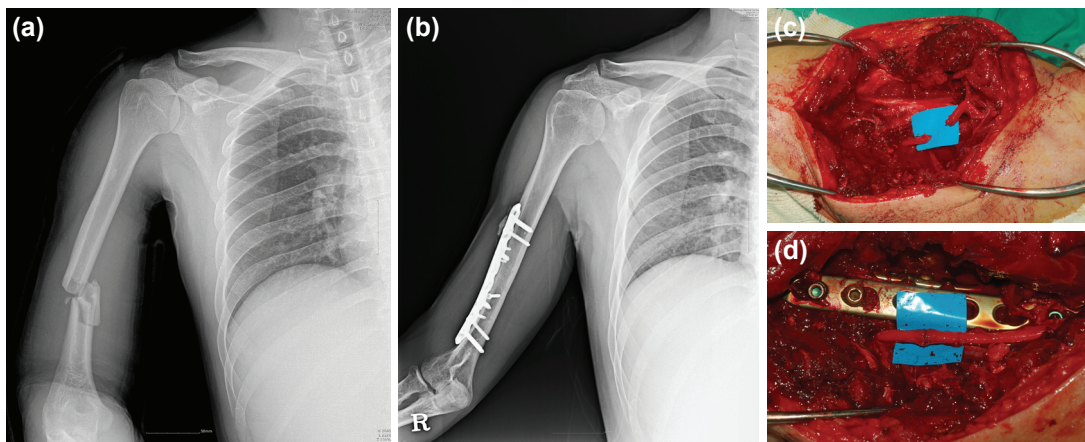


Figure 2. A 35-year-old injured in a motor cycle accident with humeral shaft fracture with middle butterfly fragment. (a) Preoperative radiograph demonstrating displaced fracture on middle-distal humeral shaft. (b) Postoperative radiograph of patients who underwent open reduction and plate fixation. (c) Intraoperative inspection of the radial nerve showed complete transection. (d) Neurolysis and perineural neurorraphy performed.

Table 4. Radial nerve palsy in relation to Fracture location, type

Location	Transverse	Butterfly	Oblique	Spiral	Total
Mid.-proximal	1	0	0	0	1
Middle	2	1	3	0	6
Mid.-distal	3 (3)*	3 (1)*	0	2	8
Total	6	4	3	2	110

*Complete nerve transection patient are shown in parentheses. Mid.: Middle.

nerve is at risk at two locations. These locations are the posterior midshaft, where the nerve lies in contact with the humerus, and the distal lateral humerus, where it pierces the lateral intermuscular septum.^[15] In our study, middle-distal fracture was most common and fracture location of all cases with transected nerve were middle to middle-distal shaft area.

The optimal management strategy for radial nerve palsy in the setting of a humeral shaft fracture remains controversial. Shao et al. presented a systematic review of the literature.^[1] Spontaneous recovery was documented in 315 of 435 patients with primary radial nerve palsy (RNP) (72%). Of the remaining 120 patients, 104 underwent late exploration at an adjusted mean time of 4.3 months, and 69% had postoperative recovery. Overall, 89% of those initially treated non-operatively achieved functional recovery.

Potential advantages of an initial non-operative approach include the fact that RNP often resolves spontaneously and that it avoids the risk of complications that may occur with surgery.^[16–18] Furthermore, proponents of an initial non-operative approach suggest that delaying surgical exploration does not affect the outcome and that surgical treatment is easier once the fracture has healed.^[1] Many researchers have demonstrated that RNP after a humeral shaft fracture is usually caused by a nerve conduction block, and therefore, exploration of the nerve is unnecessary because spontaneous recovery is nearly always the rule.^[4,19–21] In other studies, the rate of spontaneous RNP recovery among patients with humeral shaft fractures was quite impressive at 70%–89% for closed fractures and 71% for open fractures.^[1,4,19] Because of this, most authors recommend an exploration in cases where there are no clinical signs of recovery after 4–6 months.^[1,16,21]

On the other hand, advocates of early exploration of the radial nerve report a variety of advantages. Early exploration is technically easier and safer than delayed procedure. Direct examination of the injured nerve clarifies the diagnosis and the extent of the lesion, and the risk of nerve envelopment by scar tissue decreases. Occasionally, there are patients with lacerated nerves for which the primary operation is likely the optimal occasion to assess the status and management of the nerve. Moreover, in patients without recovery of nerve function after the primary internal fixation without nerve explora-

tion, a later exploration involves a more technically demanding procedure in which the nerve could be embedded in callus.^[22]

Early exploration and expedient repair of a radial nerve laceration will result in a superior outcome to a delayed repair. The review by Pollock et al. included both open and closed fractures and demonstrated that 68% of nerves with early exploration showed complete recovery. They noted nerve lacerations in 20%–42% of cases after late exploration, and they also noted poor results clinically after late repair.^[6]

Series with late exploration have revealed nerve laceration or entrapment to be present in 6%–25% of cases.^[6,8,23,24] Subsequently, advocates for early exploration of an RNP with a simple closed humeral shaft fracture would argue that after consideration of the plethora of available series, including a number of series that have documented the risk of a nerve laceration or incarceration with a closed humeral shaft fracture to be as high as 25%, that expectant or delayed nerve exploration can compromise ultimate recovery. Prolonged observation of cases with a lacerated or incarcerated radial nerve will result in no nerve recovery, potential atrophy and motor endplate loss, compromised nerve recovery on late exploration and repair, and significant interval loss of patient function and livelihood.^[25] In contrast, early exploration and repair performed earlier can facilitate better characterization of the nerve injury, quicker nerve recovery on repair with less distal endplate loss, less muscular atrophy, quicker return to function, and emotional relaxation. Moreover, after fracture fixation and stabilization is achieved, a neurolyzed or repaired nerve will potentially benefit from a better environment for recovery with less tension, motion, or callus formation to impede nerve healing.^[24,26]

Recovery from RNP may be affected by several factors including the cause and extent of nerve injury and the location and type of fracture. Unfortunately, due to insufficient number of patients in the current study, we were unable to perform meaningful subgroup analyses to determine whether the outcome of initial management is affected by these factors.

Depending on several mechanisms and different fracture personalities, the possibility of radial nerve injury changes. Therefore, we suggest that considering injury pattern, radial nerve palsy should be approached individually rather than in a uniform manner in closed humeral shaft fractures.

Conclusion

For radial nerve palsy accompanied by unstable humeral shaft fractures, primary exploration of the radial nerve and open reduction and plate fixation of the fracture should be considered as a treatment of choice. High-energy trauma, middle-distal humeral shaft fracture, and simple transverse fracture or comminuted fracture with butterfly fragment seem to be the risk factors for radial nerve transection. However, high-quality, randomized case control studies are needed to clarify the risk factors and treatment efficacy.

Conflict of interest: None declared.

REFERENCES

1. Shao YC, Harwood P, Grotz MR, Limb D, and Giannoudis PV. Radial nerve palsy associated with fractures of the shaft of the humerus: a systematic review. *J Bone Joint Surg Br* 2005;87:1647–52. [CrossRef]
2. Korompilias AV, Lykissas MG, Kostas-Agnantis IP, Vekris MD, Soucacos PN, Beris AE. Approach to radial nerve palsy caused by humerus shaft fracture: Is primary exploration necessary? *Injury* 2013;44:323–6.
3. Ring D, Chin K, and Jupiter JB. Radial nerve palsy associated with high-energy humeral shaft fractures. *J Hand Surg Am* 2004;29:144–7.
4. Larsen LB and Barfred T. Radial nerve palsy after simple fracture of the humerus. *Scand J Plast Reconstr Surg Hand Surg* 2000;34:363–6.
5. Amillo S, Barrios RH, Martinez-Peric R, Losada JI. Surgical treatment of the radial nerve lesions associated with fractures of the humerus. *J Orthop Trauma* 1993;7:211–5. [CrossRef]
6. Pollock FH, Drake D, Bovill EG, Day L, Trafton PG. Treatment of radial neuropathy associated with fractures of the humerus. *J Bone Joint Surg Am* 1981;63:239–43. [CrossRef]
7. Shaw JL, Sakellarides H. Radial-nerve paralysis associated with fractures of the humerus. A review of forty-five cases. *J Bone Joint Surg Am* 1967;49:899–902. [CrossRef]
8. Kettelkamp DB, Alexander H. Clinical review of radial nerve injury. *J Trauma* 1967;7:424–32. [CrossRef]
9. Sonneveld GJ, Patka P, van Mourik JC, Broere G. Treatment of fractures of the shaft of the humerus accompanied by paralysis of the radial nerve. *Injury* 1987;18:404–6. [CrossRef]
10. Samardzic M, Grujicic D, Milinkovic ZB. Radial nerve lesions associated with fractures of the humeral shaft. *Injury* 1990;21:220–2. [CrossRef]
11. Gosler MW, Testroote M, Morrenhof J, Janzing H. Surgical versus non-surgical interventions for treating humeral shaft fractures in adults. *Cochrane Database Syst Rev* 2012;1. [CrossRef]
12. Beaty J. Humeral shaft fractures. orthopaedic knowledge update. Rosemont Ill. *Am Acad Orthop Surg* 1999:278–86.
13. Huttunen TT, Kannus P, Lepola V, Pihlajamäki H, Mattila VM, Surgical treatment of humeral-shaft fractures: a register-based study in Finland between 1987 and 2009. *Injury* 2012;43:1704–8. [CrossRef]
14. Seddon H. Peripheral nerve injuries. Medical Research Council Special Report Series No. 282. London: Her Majesty's Stationary Office 1954:1–7.
15. Walker M, Palumbo B, Badman B, Brooks J, Van Gelderen J, Mighell M. Humeral shaft fractures: a review. *J Shoulder Elbow Surg* 2011;20:833–44. [CrossRef]
16. DeFranco MJ, Lawton JN. Radial nerve injuries associated with humeral fractures. *J Hand Surg Am* 2006;31:655–63. [CrossRef]
17. Shah A, Jebson PJ. Current treatment of radial nerve palsy following fracture of the humeral shaft. *J Hand Surg Am* 2008;33:1433–4. [CrossRef]
18. Elton SG, Rizzo M. Management of radial nerve injury associated with humeral shaft fractures: an evidence-based approach. *J Reconstr Microsurg* 2008;24:569–73. [CrossRef]
19. Ekholm R, Ponzer S, Tornkvist H, Adami J, Tidermark J. Primary radial nerve palsy in patients with acute humeral shaft fractures. *J Orthop Trauma* 2008;22:408–14. [CrossRef]
20. Kim DH, Kam AC, Chandika P, Tiel RL, Kline DG. Surgical management and outcome in patients with radial nerve lesions. *J Neurosurg* 2001;95:573–83. [CrossRef]
21. Lowe JB, 3rd, Sen SK, Mackinnon SE. Current approach to radial nerve paralysis. *Plast Reconstr Surg* 2002;110:1099–113. [CrossRef]
22. Modabber MR, Jupiter JB. Operative management of diaphyseal fractures of the humerus. Plate versus nail. *Clin Orthop Relat Res* 1998:93–104.
23. Klenerman L. Fractures of the shaft of the humerus. *J Bone Joint Surg Br* 1966;48:105–11.
24. Packer JW, Foster RR, Garcia A, Grantham SA. The humeral fracture with radial nerve palsy: is exploration warranted? *Clin Orthop Relat Res* 1972;88:34–8. [CrossRef]
25. Niver GE, Ilyas AM. Management of radial nerve palsy following fractures of the humerus. *Orthop Clin North Am* 2013;44:419–24. [CrossRef]
26. Garcia A, Maeck BH. Radial nerve injuries in fractures of the shaft of the humerus. *Am J Surg* 1960;99:625–7. [CrossRef]

ORIJİNAL ÇALIŞMA - ÖZET

Kararlı olmayan kapalı humerus cismi kırığı ile ilişkili radyal sinir felcinin primer eksplorasyonu

Dr. Soo-Hong Han, Dr. In Tae Hong, Dr. Ho Jae Lee, Dr. Sang June Lee, Dr. Uk Kim, Dr. Dong Won Kim

CHA Üniversitesi Tıp Fakültesi, Ortopedik Cerrahi Anabilim Dalı, CHA Bundang Tıp Merkezi, Seong-nam-Kore Cumhuriyeti

AMAÇ: Kapalı humerus cismi kırığının neden olduğu radyal sinir felcinin tedavisi tartışmalıdır. Bu çalışmanın amacı, kararlı olmayan kapalı humerus cismi kırıkları olan hastalarda radyal sinir felcinin erken evrede tedavisinin sonlanımını değerlendirmek ve bu tip yaralanması olan hastaların cerrahi yolla eksplere edilip edilmemesi gerektiğini belirlemektir.

GEREÇ VE YÖNTEM: Kararlı olmayan kapalı humerus cismi kırıklarının tedavisi için açık redüksiyon ve internal fiksasyon geçirmiş 15 ardışık hastanın tıbbi kayıtları gözden geçirildi. Yaralanma mekanizmaları, radyogramlar, zedelenmiş sinirin intraoperatif bulguları ve klinik iyileşmeler irdelendi. On beş hastanın ikisi basit düşme, ikisi beyzbol oynarken, biri kayak yaparken biri de iş sırasında makineye kaptırılmıştı. Kırıklar 6 hastada humerusun ortasında 8 hastada orta-distalinde ve bir hastada orta-proksimalinde bulunuyordu. Kırıklar 6 hastada transvers kırık, 4 hastada kelebek fragmanlı parçalı kırık, 3 hastada oblik segmentli kırık ve 2 hastada spiral kırık şeklindeydi.

BULGULAR: On bir hastada makroskopik olarak sinirler sağlamdı ve dördünde sinir tamamen enine kesilmişti. Total sinir kesisi olan dört hasta trafik kazası geçirmişti. Bu dört hastanın birinde humerus cisminin orta-distal kısmında kelebek fragmanlı parçalı kırık, diğer üçünde ise yine humerus cisminin orta-distalinde deplase transvers kırık mevcuttu. İki olguda enine kesili sinirler primer onarıldı. Diğer iki olguda sinir uçları ezilmiş olduğu için humerus boyu kısaltıldı ve sinir grefti kondu. Sağlam sinirli hastaların tümü son izlemde tamamen fonksiyonlarına kavuşmuştu.

TARTIŞMA: Kararlı olmayan humerus cismi kırığının eşlik ettiği radyal sinir felcinin tedavisi için terchen radyal sinirin primer eksplorasyonu, açık redüksiyon, kırığın plakayla tespiti düşünülmelidir. Yüksek enerjili travma, orta-distal humerusta lokalize kırık ve basit transvers kırık veya kelebek fragmanlı parçalı kırığın radyal sinir transeksiyonu için risk faktörleri olduğu görülmektedir.

Anahtar sözcükler: Humerus kırığı; primer eksplorasyon; radyal sinir felci.

Ulus Travma Acil Cerrahi Derg 2017;23(5):405–409 doi: 10.5505/tjtes.2017.26517