

The effect of Dermalix® on colon anastomosis leakage: experimental study

Şiyar Ersöz, M.D., Yasemin Konuk, M.D.

Department of General Surgery, Ankara University, Ankara-Türkiye

ABSTRACT

BACKGROUND: This study aimed to evaluate the effect of Dermalix® (Dx) on wound healing and anastomotic leakage in a rat model of end-to-end colon anastomosis.

METHODS: The study was carried out on 40 rats, as divided into three groups, including a negative control group (n=10, laparotomy only) control group (n=15, colon anastomosis), and the experimental group (n=15, colon anastomosis plus Dx applied to anastomosis site). The rats were sacrificed on the 3rd post-operative day, and resected colon segments were evaluated for bursting pressure (mmHg) using an infusion pump set-up and for pathological parameters of wound healing including neutrophil infiltration, epithelial regeneration, granulation tissue formation, local inflammatory response, neovascularization, and foreign body reaction.

RESULTS: Anastomotic leakage rate was significantly lower (1 rat vs. 6 rats, P=0.040). Moreover, mean bursting pressure was significantly (2.95 times) higher (mean 121 vs. 41 mmHg, respectively, P<0.05) in the Dx experimental group than in the control group. Dx was considered to significantly accelerate wound healing by increasing neovascularization (P<0.001). Control and experimental groups were similar in terms of other pathological parameters.

CONCLUSION: Based on significantly lower rate of anastomotic leakage and its positive effects especially on the bursting pressure and neovascularization, Dx seems to be considered as a promising technology in preventing anastomotic leakage.

Keywords: Anastomotic leakage; colon anastomosis; Dermalix®; rat model; wound healing.

INTRODUCTION

Anastomotic leakage is a frequent and serious complication of bowel surgery. Increased risk of surgical morbidity and mortality, longer duration of hospital stay, increase in local recurrence rates, decrease in quality of life, and poor prognosis are considered among the critical post-operative complications related to anastomotic leakage. Accordingly, several experimental and clinical studies have been conducted to address early diagnosis and prevention of anastomotic leakage after intestinal and colorectal surgeries.

Resveratrol (RSV), a natural compound with strong antioxidant properties, stimulates cellular proliferation by inducing fibroblast functions and collagen synthesis.^[1] Collagen, chitosan,

hyaluronic acid (HA), fibrin, and gelatin are natural components used as raw materials in the production of biomimetic agents, which are used for the repair and reconstruction of various tissues.^[2] Collagen, forming the main extracellular matrix protein of skin, tendon, and ligaments in particular, has been investigated in different phases of wound healing and is available on the market in several forms such as hydrogel/sponge.

In recent years, other extracellular matrix components such as glycosaminoglycans and fibrous proteins have also become included among the ingredients of products with wound-healing effects. These materials enable tissue repair by improving the new cell formation, cell migration, and intercellular adhesion.^[3]

Cite this article as: Ersöz Ş, Konuk Y. The effect of Dermalix® on colon anastomosis leakage: Experimental study. *Ulus Travma Acil Cerrahi Derg* 2023;29:1212-1217.

Address for correspondence: Şiyar Ersöz, M.D.

Department of General Surgery, Ankara University, Ankara, Türkiye

E-mail: drsiyar@hotmail.com

Ulus Travma Acil Cerrahi Derg 2023;29(11):1212-1217 DOI: 10.14744/tjtes.2023.20194 Submitted: 22.06.2023 Revised: 26.06.2023 Accepted: 20.10.2023
OPEN ACCESS This is an open access article under the CC BY-NC license (<http://creativecommons.org/licenses/by-nc/4.0/>).



Dermalix® (Dx), which is produced in the light of recent developments in the field of tissue repair, contains collagen as fibrous component, laminin as a cell adhesion protein, and HA as a glycosaminoglycan derivative, while lipid dipalmitoylphosphatidylcholine forms the microparticle structure of cell membrane. All of these components have synergistic effects on tissue repair.^[4]

Dx is designed to include such components that strengthen the effect of antioxidants and protect the delicate balance of wound environment. Its three-dimensional (3D) structure is formed by impregnating the porous texture of collagen-laminin with RSV-loaded HA/DCCP microparticles. While contains no preservatives or fragrance ingredients, it is a product subjected to gamma irradiation sterilization. It has a shelf life of 2 years at room temperature.

On the basis of the existing data, this study was designed to evaluate the effect of Dx product on wound healing, particularly on anastomotic site; in a rat model of end-to-end colon anastomosis.

MATERIALS AND METHODS

Animals

Before the clinical studies, the effect of the study product (Dx) on anastomotic leakage was planned to be investigated in a preclinical experimental study. *Rattus norvegicus* was the selected rat strain for the experiments, providing a phylogenetic basis and a highly convenient physiological model to mimic the condition in the human or animal body, as well as having a proper tissue, size, and anatomy suitable for the experimental study. The same strain was used in the previous studies which formed the basis of the present study.

The study protocol was approved by the Ankara University Animal Experiments Local Ethics Committee (Protocol no: 2022-6-57).

The study was conducted in September 2022 at the Animal Experiments Laboratory of Ankara University Faculty of Medicine. The power analysis performed before the study revealed that at least 70 rats are necessary in total for a two-group end-to-end anastomosis study to achieve a significance level of 0.05 and 95% power. However, given that the experimental model is to be studied for the 1st time with the use of a material that was never investigated before, it was decided to conduct preliminary experiments with a smaller sample due to the risk of inactivity or unforeseen adverse effects. Therefore, the number of animals to be used in the study was designated as 40. The study was carried out on 40 rats, as divided into three groups, including control group (n=15), experimental group (n=15), and a negative control group (n=10).

Surgical Procedure

All operations were carried out under appropriate anesthesia using sterile surgical techniques. During the operation, the sigmoid colon was divided 5 cm from the cecum and then

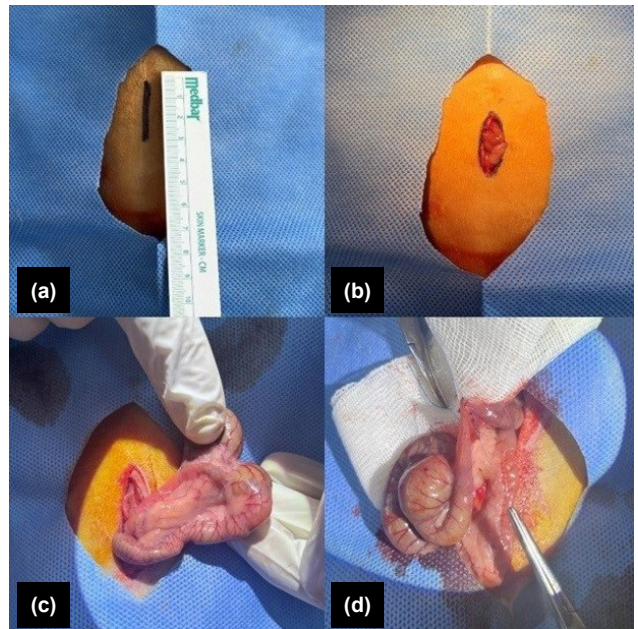


Figure 1. (a) Location of midline incision, (b) Shape of incision, (c) Preparation of colon for anastomosis, and (d) Anastomosis procedure.

end-to-end anastomosis was applied manually. A single-layer end-to-end anastomosis was created using 8–10 interrupted sutures (6–0 polypropylene) (Fig. 1).

In the negative control group, rats underwent laparotomy without any additional procedures and not exposed to experimental treatment. Negative control group was formed because the planned experiment was never done before and

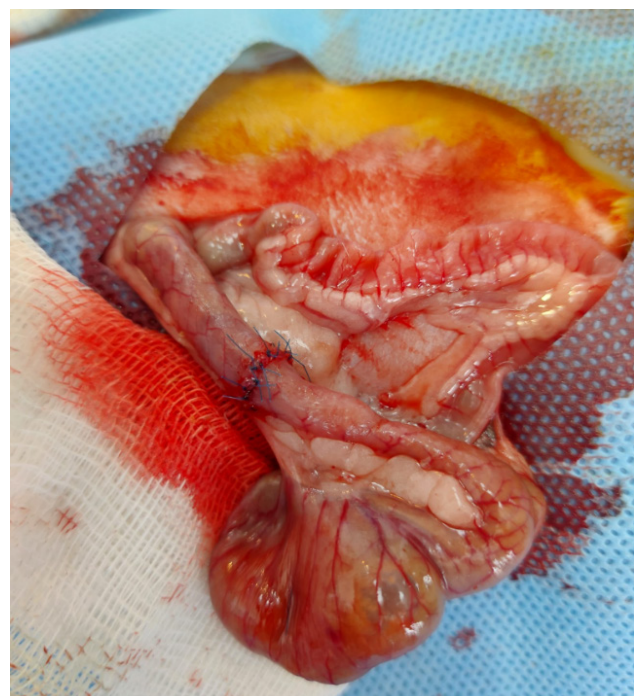


Figure 2. End-to-end colon anastomosis using simple interrupted suturing in the control group.

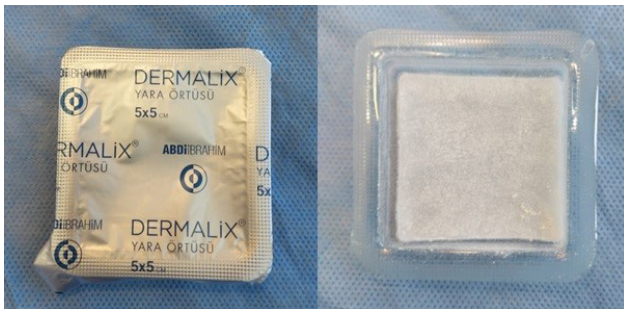

Figure 3. Dermalix®.

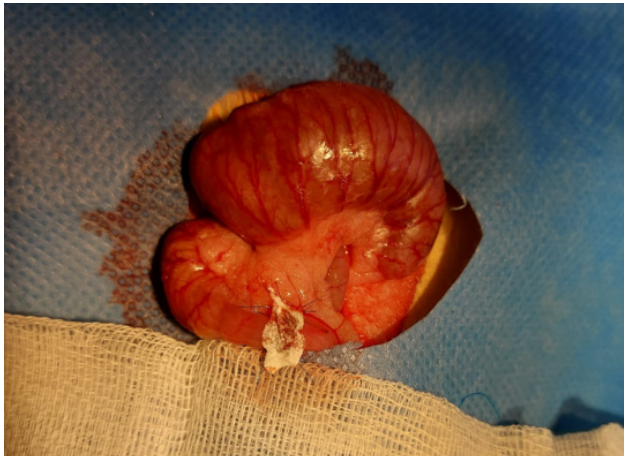

Figure 4. End-to-end colon anastomosis covered with Dermalix® in the experimental group.

aimed to evaluate the principles of the experimental model rather than the effect on treatment.

In the control group, anastomosis operation was followed by the primary closure in accordance with the anatomic position (Fig. 2).

In the experimental group, after anastomosis, a 1 × 1 cm Dx (Fig. 3) wound material was wrapped around the anastomosis, keeping the anastomosis line in the middle and the operation was finalized with primary closure in accordance with the anatomic position (Fig. 4).

Each group was kept separately in appropriate environmental conditions and checked daily. Three days after the operation, the rats were anesthetized and laparotomy was applied once again. The presence of intraabdominal fecal peritonitis and dehiscence of anastomosis line with or without accompanying abscess were considered to indicate anastomotic leakage (Fig. 5).

In the control and experimental groups, anastomosis segment, 3 cm in length, involving the anastomosis site was resected. Afterward, rats were sacrificed by thoracic aorta dissection.

The resected colon segment was cleaned with saline and the distal end was closed with 4/0 silk sutures (Fig. 6). An infu-

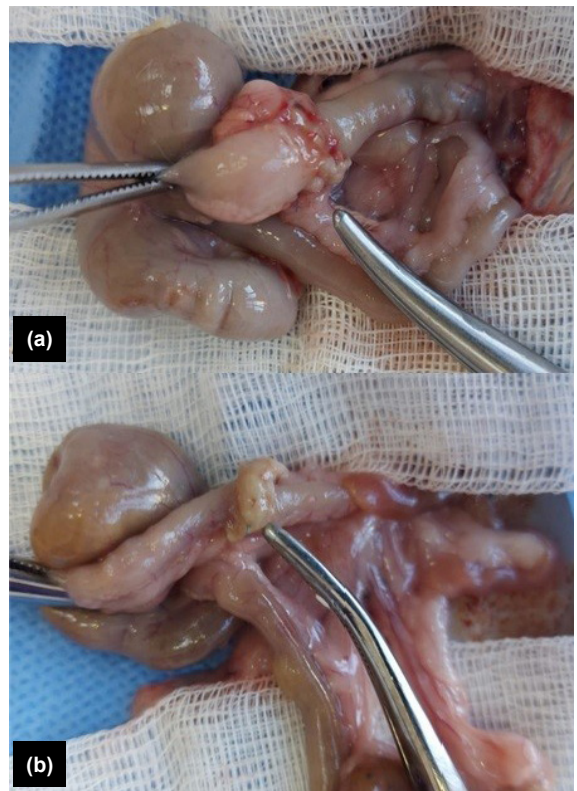

Figure 5. Laparotomy performed on the post-operative 3rd day. (a) Appearance of anastomosis in the control group and (b) Appearance of anastomosis in the experimental group (covered with Dermalix®).

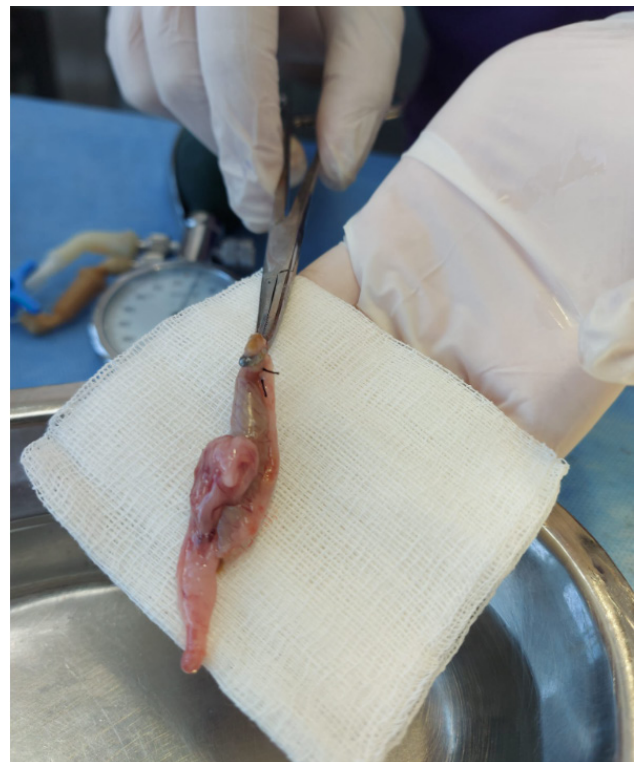

Figure 6. Resected colon segment.

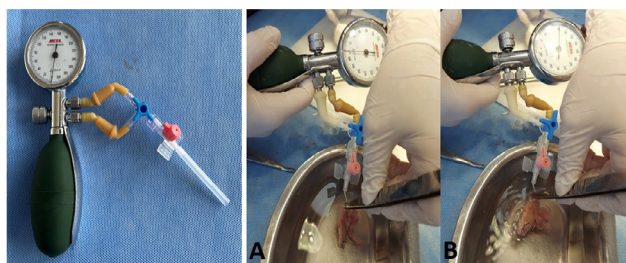


Figure 7. Infusion pump set-up and bursting pressure measurement. (a) Placement of colon segment to the end of infusion pump, (b) Measurement of bursting pressure with air-water test.

sion pump set-up equipped with a manometer that measures the pressure (mmHg) was prepared and a cannula was placed at the proximal end of the colon. After the preparation of the set-up, the colon segment was placed in a water-filled container and inflated using the infusion pump. Thus, a set-up that enables air-water test was formed, and by gradually increasing the pressure, the pressure that caused anastomotic leakage was recorded (Fig. 7).

After the bursting pressure measurement, a 1-cm segment that included the anastomosis line at the midline was removed. After washing with 0.9% sodium chloride solution, tissues were put into 10% formaldehyde solution for fixative. After 12 h of formaldehyde fixation, tissues were sampled including the anastomosis area, and paraffin blocking was performed. Histopathological evaluation was performed with H.E stain on 6 micron sections from paraffin blocks. In the pathological evaluation, parameters related to the steps of the wound healing process such as neutrophil infiltration, epithelial regeneration, granulation tissue formation, local inflammatory response, neovascularization, and foreign body reaction were evaluated. Neutrophil infiltration was evaluated as mild if 5–10, moderate if 11–50, and severe if >50 in 1 HPF area. Nuclear enlargement in the epithelium, chromatin coarsening, nucleolar prominence, and rare mitosis were considered regenerative changes and were accepted as positive (+) if observed and negative (-) if not. Fibrosis and edema development were evaluated for the granulation tissue and it was accepted as positive (+) if it was observed and negative (-) if it was not observed. Mononuclear inflammatory cells were evaluated for local inflammatory response and accepted as mild; if cells were between 5 and 10, as moderate between 11 and 50 and as severe >50 mononuclear cells detected in an HPF area. Foreign body type giant cells and granuloma-like structures composed of histiocytic cells were accepted as positive (+) and negative (-) for evaluating foreign body reaction. Finally, neovascularization was also scaled as mild if 1–5 capillaries, moderate if 6–10, and severe if >10 in one HPF.

Statistical analysis of the data obtained during assessments was performed and the results of the control group and experimental group were compared.

Statistical Analysis

All categorical data were presented as the number of cases and percentages, while continuous data were shown as either means \pm standard deviation (SD) or median with range. Categorical data were analyzed with the Pearson Chi-square test and continuous data by the Mann–Whitney U-test.

Statistical analysis was performed using SPSS 23.0 and Prism 8.0 software. $P < 0.05$ was considered statistically significant.

RESULTS

The study was carried out on 40 rats in three groups including the negative control group ($n=10$), the control group ($n=15$), and the experimental group ($n=15$).

Diagnostic laparotomy was applied to the rats in the negative control group and no pathology/complication was detected.

Anastomotic leakage occurred in six rats in the control group and in one rat in the experimental group. In seven rats with anastomotic leakage, temperature rise and congested appearance in the right lower quadrant of the peritoneum were observed, as considered to be suggestive of peritonitis. Abscess formation was not detected in any of the rats with anastomotic leakage. The rate of anastomotic leakage was significantly lower in the Dx experimental group than in the control group (Fisher's exact test, $P=0.040$) (Fig. 8).

In both control and experimental groups, completion of the normal wound healing process was not allowed, and the rats were sacrificed 3 days after the anastomosis, and the colon segment including the anastomosis line was resected to evaluate the contribution of Dx to anastomosis. The mean bursting pressure measured on resected colon segments was 41 mmHg (range, 32–100 mmHg) in the control group and was 121 mmHg (range, 60–220 mmHg) in the experimental group. Rats with anastomotic leakage were not included in the mean pressure measurements. The mean value of bursting pressure was 2.95 times higher in the experimental group than in the control group, and the difference was statistically significant (Table 1).

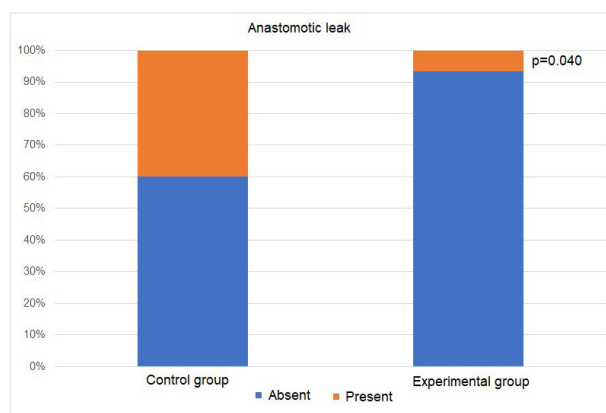


Figure 8. Anastomotic leakage ratio in experimental and control groups.

Table 1. Mean bursting pressure in experimental and control groups

	Experimental group (n=15)		Control group (n=15)		p value
	Mean	Standard Deviation	Mean	Standard Deviation	
Bursting pressure (mmHg)	121	57	41	39	p<0.05

Histopathological examination was performed on the resected colon segments. Assessment of neutrophil infiltration, which is an important marker for wound healing and inflammation, revealed that moderate and extensive infiltration was evident in 11 rats and four rats, respectively, in the control group, while in six rats and nine rats, respectively, in the experimental group. The difference between the two groups in terms of neutrophil infiltration was not found to be statistically significant on analysis with the Pearson Chi-square test ($P=0.070$).

Granulation tissue was observed in all rats after the anastomosis. Epithelial regeneration started in both groups, and 86.7% of rats in the control group and 80% of rats in the experimental group had mild regeneration. Extensive regeneration was observed in the remaining rats in each group. Local inflammation assessment revealed similar results in control and experimental groups, with detection of mild inflammation in two rats, moderate inflammation in six rats, and severe inflammation in seven rats, in each group.

Neovascularization, one of the processes that accelerate wound healing, was found to be at a mild level in 12 rats in the control group and to be at a moderate level in 11 rats in the experimental group. Therefore, Dx was considered to significantly accelerate wound healing by increasing neovascularization ($P<0.001$) (Fig. 9).

Foreign body reaction was predominantly mild in both experimental (in 12 rats) and control (in 13 rats) groups with no significant difference between groups ($P=0.500$).

DISCUSSION

Anastomotic leakage is a frequent complication of intestine and colon operations and is associated with serious conse-

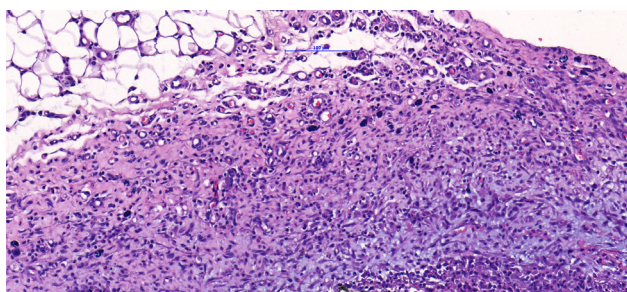


Figure 9. Histopathological view of neovascularization in the experimental group (H&E, $\times 200$).

quences. Leakage prevalence ranges between 1 and 39% and the rate of significant leakage varies between 3 and 6%.^[5] In our study, the rate of anastomotic leakage was found to be 23.3% as a limitation. Although all the anastomosis have done by the same surgeon with the same standardization, the reason of the high rate of anastomotic leakage does not known. However, it should be kept in mind that the data may have been so different because given counts were based on studies and compilations on humans. Since the colon wall thickness, lumen diameter, colonic microbiota phenotype, and even the diet in mice will be very different, such a comparison will not be a very realistic approach. However, it is aimed to apply an experimental model to anastomotic leaks and to investigate Dx efficiency on anastomosis. Several factors play a role in the occurrence of anastomotic leakages, such as recurrent abdominal surgery, intraoperative septic conditions, male gender, smoking/alcohol use, presence of comorbidities, and urgent/elective surgery in humans.^[5]

In our study, a significantly lower rate of leakage was detected in the Dx group (1/15) than in the control group (6/15). This may support the hypothesis of a previous study that it reduces leakage by accelerating wound healing.^[6]

In this study; no statistical difference was found between the groups in any of the parameters with histopathological findings of acute and chronic inflammations^[7-11] such as neutrophil infiltration, epithelial regeneration, granulation tissue formation, local inflammatory response, and foreign body reaction.

There is evidence demonstrating that Dx accelerates wound healing by supporting the growth of wound cells mechanically in a previous study.^[11] Our data on bursting pressure measurements are in line with the consideration of Dx to provide mechanical support. The finding of 3 times higher bursting pressure values in the Dx-applied experimental group of rats than in the control group of rats in the present study may be associated with mechanically supportive 3D structure of Dx.

The developed collagen matrix stimulates the angiogenesis and thus the granulation tissue starts to generate. In this study, although the granulation tissue formation was evident similarly in both control and experimental groups, neovascularization was more prominent in the Dx group and significantly different from the control group ($P<0.001$). Newly formed blood vessels carry more oxygen and nutrients to the wound site. This promotes wound healing by increasing the metabolic activities of cells. New blood vessels carry growth

factors and cellular components essential for the healing process. Vessels allow connective tissue cells to interact and come together. This contributes to the tightening of the wound area and wound contraction, which is one of the last stages of wound healing.^[7-9] We believe that the significantly higher neovascularization in the Dx group can be considered as an important factor in the contribution of this substance to wound healing.

CONCLUSION

As a result, data supporting the positive effect of Dx on wound healing were obtained in our study; however, large-scale animal experiments and/or clinical studies are needed to address the use of this product.

Ethics Committee Approval: This study was approved by the Ankara University Ethics Committee (Date: 16.03.2022, Decision No: 2022-6-57).

Peer-review: Externally peer-reviewed.

Authorship Contributions: Concept: Ş.E.; Design: Ş.E.; Supervision: Ş.E.; Resource: A.İ.; Materials: Ş.E., Y.K.; Data collection and/or processing: Ş.E., Y.K.; Analysis and/or interpretation: Y.K.; Literature search: Ş.E., Y.K.; Writing: Ş.E., Y.K.; Critical review: Ş.E., Y.K.

Conflict of Interest: None declared.

Financial Disclosure: The author declared that this study has received no financial support.

REFERENCES

1. Ndiaye M, Philippe C, Mukhtar H, Ahmad N. The grape antioxidant resveratrol for skin disorders: Promise, prospects, and challenges. Arch Biochem Biophys 2011;508:164–70. [CrossRef]
2. Loh QL, Choong C. Three-dimensional scaffolds for tissue engineering applications: Role of porosity and pore size. Tissue Eng Part B Rev 2013;19:485–502. [CrossRef]
3. Singh AV, Gemmati D, Kanase A, Pandey I, Misra V, Kishore V, et al. Nanobiomaterials for vascular biology and wound management: A review. Veins Lymphatics 2018;7:34–47. [CrossRef]
4. Cetinkalp S, Gokce EH, Simsir IY, Tanriverdi ST, Dogan F, Avci CB, et al. Comparative evaluation of clinical efficacy and safety of collagen laminin-based dermal matrix combined with resveratrol microparticles (dermalix) and standard wound care for diabetic foot ulcers. Int J Low Extrem Wounds 2021;20:217–26. [CrossRef]
5. Buchs NC, Gervaz P, Secic M, Bucher P, Mugnier-Konrad B, Morel P. Incidence, consequences, and risk factors for anastomotic dehiscence after colorectal surgery: A prospective monocentric study. Int J Colorectal Dis 2008;23:265–70. [CrossRef]
6. Bashmakov YK, Assaad-Khalil S, Petyaev IM. Resveratrol may be beneficial in treatment of diabetic foot syndrome. Med Hypotheses 2011;77:364–7. [CrossRef]
7. Wang PH, Huang BS, Horng HC, Yeh CC, Chen YJ. Wound healing. J Chin Med Assoc 2018;81:94–101. [CrossRef]
8. Ross R, Everett NB, Tyler R. Wound healing and collagen formation. VI. The origin of the wound fibroblast studied in parabiosis. J Cell Biol 1970;44:645–54. [CrossRef]
9. Mullen KM, Regier PJ, Ellison GW, Londoño L. A review of normal intestinal healing, intestinal anastomosis, and the pathophysiology and treatment of intestinal dehiscence in foreign body obstructions in dogs. Top Companion Anim Med 2020;41:100457. [CrossRef]
10. Anderson JM, Shive MS. Biodegradation and biocompatibility of PLA and PLGA microspheres. Adv Drug Deliv Rev 2012;64:72–82. [CrossRef]
11. Gokce EH, Tanriverdi ST, Eroglu I, Tsapis N, Gokce G, Tekmen I, et al. Wound healing effects of collagen-laminin dermal matrix impregnated with resveratrol loaded hyaluronic acid-DPPC microparticles in diabetic rats. Eur J Pharm Biopharm 2017;119:17–27. [CrossRef]

1. Ndiaye M, Philippe C, Mukhtar H, Ahmad N. The grape antioxidant

DENEYSSEL ÇALIŞMA - ÖZ

Dermalix®'in kolon anastomoz kaçakları üzerine etkisi: Deneysel çalışma

Dr. Şiyar Ersöz, Yasemin Konuk

Ankara Üniversitesi Tıp Fakültesi, Genel Cerrahi Anabilim Dalı, Ankara

AMAÇ: Çalışmada, Dermalix® (Dx)'in yara iyileşmesi ve anastomoz kaçağı üzerine olan etkisinin sıçan uç uca kolon anastomozu modelinde değerlendirilmesi amaçlanmıştır.

GEREÇ VE YÖNTEM: Çalışma; negatif kontrol grubu (n=10, sadece laparotomi), kontrol grubu (n=15, kolon anastomozu) ve deney grubu (n=15, kolon anastomozu ve anastomoz bölgesine uygulanan Dx) olmak üzere 3 gruba bölünmüş halde 40 sıçan üzerinde gerçekleştirilmiştir. Sıçanlar postoperatif 3. günde sakrifiye edilmiş ve rezeke edilen kolon segmentlerinde infüzyon pompası yardımı ile patlama basıncı (mmHg) ve nötrofil infiltrasyonu, epitel rejenerasyonu, granülasyon dokusu oluşumu, lokal inflamatuvar yanıt, neovaskülarizasyon ve yabancı cisim reaksiyonu dahil olmak üzere yara iyileşmesinin patolojik parametreleri değerlendirilmiştir.

BULGULAR: Anastomoz kaçağı oranı anlamlı derecede düşük (1 sıçan vs 6 sıçan, p=0.040) ve ortalama patlama basıncı Dx deney grubunda kontrol grubuna göre önemli ölçüde yüksek (2.95 kat, ortalama 121 mmHg vs 41 mmHg, p<0.05) bulunmuştur. Dx'in neovaskülarizasyonu artırarak yara iyileşmesini önemli ölçüde hızlandırdığı değerlendirilmiştir (p<0.001). Kontrol ve deney grubu diğer patolojik parametreler açısından benzer sonuçlar saptanmıştır.

SONUÇ: Anastomoz kaçağı oranının önemli ölçüde düşük olması, özellikle patlama basıncı ve neovaskülarizasyon üzerindeki olumlu etkileri göz önünde bulundurulduğunda Dx, anastomoz kaçağını önlemede umut vadeden bir teknoloji olarak görülmektedir.

Anahtar sözcükler: Anastomoz kaçağı; kolon anastomozu; sıçan modeli; yara iyileşmesi.

Ulus Travma Acil Cerrahi Derg 2023;29(11):1212-1217 DOI: 10.14744/tjtes.2023.20194