

Evaluation of agar films in the prevention of postoperative peritoneal adhesions in an animal model

Bir hayvan modelinde postoperatif periton yapışıklığının önlenmesinde agar filmlerinin değerlendirilmesi

Mohsen MAMOUDIEH,¹ Nooshin MIRKHESHTI,² Sayyed Ali ALAVI²

BACKGROUND

Peritoneal adhesions cause significant long-term postoperative morbidity. This study evaluates the efficacy of agar plates as the physical barrier in reducing adhesion formation after abdominal surgery in an animal model.

METHODS

Adhesions were induced, by cecum abrasion, in 20 C57/BL6 mice during a laparotomy procedure. Agar plates were used in 10 mice as the experimental group. At a second operation, 28 days later, the adhesions were graded, in two groups. Data were analyzed by using Student t test.

RESULTS

There was no significant difference in weight gain of the two groups during the study period. A comparison of the morphological appearances of the adhesions demonstrated that there was no evident difference between the two groups. There was also no significant difference in the incidence ratio of adhesions or postoperative adhesion scores between the two groups (p value >0.05).

CONCLUSION

Despite the hydrogel properties of agar, it was not successful in practice in the reduction of adhesion formation after peritoneal surgery. Since agar is a biological product, it may cause a hyperreactivity induced by the innate immune system in peritoneum. Therefore, agar does not appear to be useful in clinical practice for the reduction of adhesion formation after peritoneal surgery.

Key Words: Agar; surgical adhesion; abdominal surgery.

AMAÇ

Peritoneal yapışıklıkları uzun sürede önemli postoperatif morbidite nedenidir. Bu çalışma, bir hayvan modelinde karın cerrahisinden sonra yapışıklık oluşumunun azaltılmasında agar plakalarının etkinliğini değerlendirmektedir.

GEREÇ VE YÖNTEM

Yapışıklıklar bir laparotomi işlem sırasında 20 C57/BL6 farelerde, çekum abrazyonuyla oluşturuldu. Deneysel grup şeklinde 10 farede agar plakaları kullanıldı, 28 gün sonraki ikinci operasyonda, yapışıklıklar iki grupta derecelendirildi. Veriler, Student t testi kullanılarak analiz edildi.

BULGULAR

Çalışma süresince iki grubun kilosu açısından anlamlı bir fark yoktu. Yapışıklıkların morfolojik görünüm karşılaştırmasında, iki grup arasında belirgin bir fark yoktu. Aynı zamanda, iki grup arasında yapışıklıkların insidans oranı veya cerrahi işlem sonrası adezyon skorları bakımından da hiçbir anlamlı fark yoktu (p>0,05).

SONUÇ

Sahip olduğu hidrojel özelliklerine karşın, agar, uygulamada peritoneal cerrahiden sonraki yapışıklık oluşumunun azaltılmasında başarılı olmamıştır. Biyolojik bir ürün olması nedeniyle, agar, peritondaki doğal immün sistem tarafından uyarılan bir hiperreaktiviteye yol açabilir. Bu yüzden, agar, klinik uygulamada peritoneal cerrahiden sonra yapışıklık oluşumunun azaltılmasına yönelik olarak yararlı gibi görünmemektedir.

Anahtar Sözcükler: Agar; cerrahi yapışıklık; karın cerrahisi.

¹Department of Surgery, Isfahan University of Medical Sciences, Isfahan;

²East Sage Research Corporation, Isfahan, Iran.

¹Isfahan Üniversitesi Tıp Fakültesi, Cerrahi Bölümü, Isfahan;

²Doğu Sage Araştırma Şirketi, Isfahan, İran.

Dense peritoneal adhesions are usually well vascularized and innervated fibrous bands of tissue, which join together previously separated intra-abdominal organs. They commonly occur after surgical trauma, developing in more than 90% of patients undergoing laparotomy.^[1] Adhesions occur in 68-100% of patients undergoing one or more laparotomies.^[1-3]

A third of intestinal obstructions and nearly a quarter of female infertility cases are a consequence of adhesion formation.^[2] This widespread condition therefore represents a tremendous financial burden to health services, in terms of time a relaparotomy and the cost of treating adhesion complications.^[4] However, despite their clinical importance, information regarding the molecular and cellular events regulating adhesion formation is limited, and current prevention is based on careful surgery and the occasional use of physical barriers that are effective in only a proportion of patients.

Numerous products have been used to help minimize the formation of adhesions. However, none of the barriers has yet achieved sustained success.^[5,6] Current agents such as HA-CMC (sodium hyaluronate - carboxymethylcellulose) and icodextrin are widely used in clinical practice, but the results with respect to their antiadhesive efficacy and biocompatibility are conflicting.

Within 24 hours of HA-CMC application, the film becomes a hydrophilic gel that is absorbed by the body within 7 days and eliminated within 28 days. It has been shown to reduce the incidence of adhesions during gynecological and bowel surgery.^[7,8] However, these studies have been limited to laparotomy, and the stiff nature of HA-CMC complicates its use during laparoscopy. Moreover, several studies have shown conflicting results.^[9-11] Signs of severe inflammations and abscess formation are reported.^[10,11] Thus, research continues to find more suitable biophysical barriers for post-surgical adhesion prevention. One of the most significant criteria about such materials is that most of them can produce a hydrogel barrier on the target site. In this regard, an agent with the property of producing hydrogel under the condition that it does not react with the injured organ or stimulate the immune system can be considered as a proper antiadhesive barrier.

Agar is a polymer made up of subunits of the sugar galactose, and is a component of the cell walls of several species of red algae that are usually harvested in eastern Asia and California. Dissolved in boiling water and cooled, laboratory agar looks gelatinous. Agar, unlike gelatin, will not be degraded (eaten) by bacteria, so despite its protein component, it cannot be used as a nutrient by bacteria in the abdomen. In this study, we decided to use agar in the form of agar

plates for prevention of post-surgical adhesion in an animal model.

MATERIALS AND METHODS

Animals

Twenty C57BL adult female mice 10-12 weeks of age and weighing 25-30 g were used in the study groups and purchased from Pastor Ltd., Tehran, Iran. All mice were maintained under standard conditions of food and water ad libitum on a 12-hour day-night cycle. The animals were randomly divided into control and experiment groups.

Materials

A commercially available agar powder (Sigma Co. Ltd, USA) was used in this study. 0.75 mg of agar was dissolved in 100 ml normal saline and boiled. The solution was poured into a network plate with 1 x 1 cm nets, and autoclaved for 20 minutes (min). Then, the plate was kept at room temperature for 20 min till the agar plates changed into a gel form. The agar plates were kept in sterile normal saline before use in the abdomen of animals.

Procedure

All animal experiments were approved by the medical ethics committee of Isfahan University of Medical Sciences. Anesthesia was produced using an 80 mg/kg ketamine and 10 mg/kg xylazine intraperitoneal injection. The abdominal area of each animal was shaved with an electric clipper before operation.

All mice underwent a midline laparotomy, and the cecum was identified and scored using an abrasive pad until serosal bleeding was noted on the anterior surface. The laparotomy site was then closed in two layers after an agar film barrier (1 × 1 cm) was laid between the cecum and peritoneum. In the control group, there was no barrier between the layers. Twenty-eight days later, the mice were sacrificed under ether anesthesia and underwent a second laparotomy by a surgeon blinded to the group assignment in order to evaluate the extent of abdominal adhesions qualitatively and quantitatively under the following guidelines:^[12]

1. The general overall health of the test animals indicated by their weight gain after the initial surgery.
2. The incidence ratio of adhesions recorded as the number of animals with adhesions divided by the total number of animals in the group.
3. The quality of adhesions on the previously abraded cecal side with a numeric score of 0-3 (0 = no adhesion, 1 = thin and filmy, 2 = significant and filmy, and 3 = severe with fibrosis) (Method I).

Additionally, the adhesion scores were qualitatively measured using another 0-3 point scale for the fol-




Fig. 1. (a) Morphological appearance of the adhesions in the experimental (A) and control (B) groups. Adhesion bands are observed between the colon and peritoneal surface (arrows). (b) Morphological appearance of the adhesions in the experimental (A) and control (B) groups. Adhesion bands are observed between the colon and peritoneal surface (arrows).

lowing four states:^[13] no adhesion (0); slight adhesion (1+): adhesion of ~1 mm; moderate adhesion (2+): adhesion of ~2 mm; and severe adhesion (3+): adhesion of >3 mm (Method II).

Statistical Analysis

Statistical evaluation was performed using SPSS 13.0 for Windows. All quantitative data were reported as mean \pm SD. Student t test was performed for comparison of the results between the two groups. A p value less than 0.05 was considered significant.

RESULTS

Our surgical procedure was well tolerated by the animals. There was no mortality during or after surgery. All laparotomy sites were intact and none of the mice had dehiscence during the study period. Mean weight of mice was 28.1 ± 2.4 g and 27.1 ± 1.2 g (in control and experimental groups, respectively) before surgery, and there was no significant difference between the two groups. Mean weight of mice was 32.8 ± 0.2 g and 30.7 ± 0.8 g at the end of the study period (28 days) in the control and experimental groups, respectively. There was no significant difference in the weight gain of the two groups during this time. Figure 1 shows the morphological appearance of the adhesions in the two groups. In the experimental group, we found fibrosis, vascularization and inflammation in adhesion bands (Fig. 2). None of the mice in the control group showed complications, abscess formation, peritonitis, or any sign of febrile morbidity, while peritonitis was seen in 4 mice in the experimental group.

Since adhesions were identified in all mice in both groups, there was no significant difference between groups with regard to frequency of adhesion formation. The postoperative adhesion scores are shown in Table 1. The mice in the experimental group did not show a significant decrease in adhesion scores (by Methods I or II) compared with the control group ($p > 0.05$).

DISCUSSION

According to the results of this study, the animal group treated with agar plates did not show any differences in postoperative adhesion formation in comparison with the control group.

Barrier adjuvants are used to prevent adhesions by decreasing the contact between injured tissues that leads to adhesion formation. Over the past decades, many investigations have been conducted to find a treatment modality to prevent adhesions after intra-abdominal surgery. However, the success of the current methods in adhesion prevention has not been satisfactory.^[14,15]

The biocompatibility of the currently used antiadhesive products is not reliable. Several cases of postoperative acute aseptic peritonitis have been reported after using HA-CMC (Septrafilm) or 4% icodextrin (Adept). Although products are commonly used in clinical practice worldwide, their efficiency and biocompatibility have been increasingly questioned recently.^[16-24]

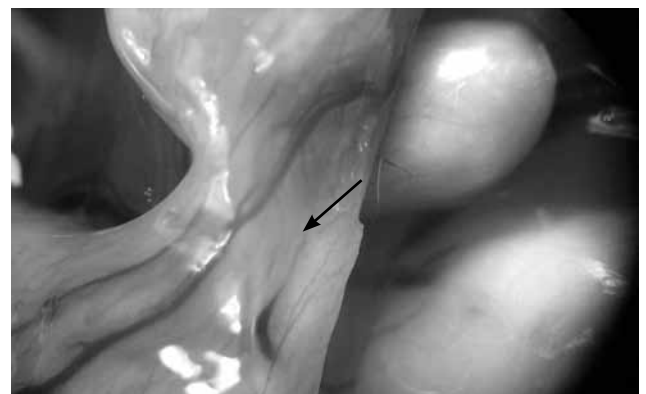


Fig. 2. Fibrosis, vascularization and inflammation in adhesion bands of the experimental group (observed in 4 of 10 mice).

Table 1. The postoperative adhesion scores in the two groups according to two measurement methods

	Groups		P value
	Experimental group (Mean \pm SD)	Control group (Mean \pm SD)	
Scale			
Adhesion score measured by method I	2.33 \pm 1.15	2.33 \pm 1.15	p>0.05
Adhesion score measured by method II	2.33 \pm 1.15	2 \pm 1	p>0.05

Other available products, such as Ringer's lactate or dextran, seem to reduce neither the incidence nor the severity of adhesions. Massive side effects of dextran such as pleural effusion, edema, abdominal complaints, and dyspnea have prohibited its use as an adhesion barrier.^[25] Another product, sodium hyaluronate (HA), was withdrawn from the market because of its side effects and its attribute of enhancing colorectal tumor cell adhesion to the peritoneum.^[26]

As mentioned before, agar is a polymer made up of subunits of the sugar galactose. Hence, regarding its carbohydrate structure, it seems that agar cannot stimulate the immune system like some protein components that are used as antiadhesive barriers. In addition, the property of producing hydrogel in the wet environment makes it a proper candidate as an antiadhesive barrier in abdominal surgery. However, according to the results of our study, agar is not a suitable barrier for post-surgical adhesion prevention, and this may be attributed to different reasons.

Although agar cannot be consumed directly by bacteria as a nutrient, it is a stable medium that can prevent macrophages from reaching the site of bacterial growth, and therefore agar can be considered as a suitable medium for bacterial growth and infection.

On the other hand, agar is a polymer made up of subunits of the sugar galactose, and is a component of the cell walls of several species of red algae. Although impurities, debris, minerals, and pigment are reduced to specified levels during manufacture, there are some impurities in this biological substance that can result in immune system stimulation and induction of inflammatory reactions at the site of surgery. This event can lead to a greater increase in adhesion formation.

The immune system is composed of two major subdivisions, the innate or nonspecific immune system and the adaptive or specific immune system. The innate immune system is a primary defense mechanism against invading organisms, while the adaptive immune system acts as a second line of defense. In spite of the adaptive immune system, the innate immune system includes defenses that, for the most part, are constitutively present and mobilized immediately upon infection. Additionally, the innate system is not antigen-specific and reacts similarly to a variety

of organisms. Innate immunity relies on genetically predetermined pattern recognition receptors (PRRs) that recognize carbohydrates, lipids and proteins that are not produced by the host. These macromolecular structures, usually found in the cell wall, are referred to as pathogen-associated molecular patterns.^[27] According to this information, it can be considered that agar may stimulate the innate immune system and induce inflammation at the site of surgery, which can lead to post-surgical adhesions. However, evaluating factors related to this kind of immunity can be helpful in proving this hypothesis.

In conclusion, according to the results of this study, agar is not a suitable physical barrier for preventing post-surgical adhesions in the case of abdominal surgery.

REFERENCES

1. Menzies D, Ellis H. Intestinal obstruction from adhesions--how big is the problem? *Ann R Coll Surg Engl* 1990;72:60-3.
2. Ellis H. The clinical significance of adhesions: focus on intestinal obstruction. *Eur J Surg Suppl* 1997;5-9.
3. Luijendijk RW, de Lange DC, Wauters CC, Hop WC, Duron JJ, Pailler JL, et al. Foreign material in postoperative adhesions. *Ann Surg* 1996;223:242-8.
4. Ray NF, Denton WG, Thamer M, Henderson SC, Perry S. Abdominal adhesiolysis: inpatient care and expenditures in the United States in 1994. *J Am Coll Surg* 1998;186:1-9.
5. Polymeneas G, Theodosopoulos T, Stamatiadis A, Kourias E. A comparative study of postoperative adhesion formation after laparoscopic vs open cholecystectomy. *Surg Endosc* 2001;15:41-3.
6. Tittel A, Treutner KH, Titkova S, Ottinger A, Schumpelick V. New adhesion formation after laparoscopic and conventional adhesiolysis: a comparative study in the rabbit. *Surg Endosc* 2001;15:44-6.
7. Becker JM, Dayton MT, Fazio VW, Beck DE, Stryker SJ, Wexner SD, et al. Prevention of postoperative abdominal adhesions by a sodium hyaluronate-based bioresorbable membrane: a prospective, randomized, double-blind multicenter study. *J Am Coll Surg* 1996;183:297-306.
8. Diamond MP. Reduction of adhesions after uterine myomectomy by Seprafilm membrane (HAL-F): a blinded, prospective, randomized, multicenter clinical study. *Seprafilm Adhesion Study Group. Fertil Steril* 1996;66:904-10.
9. Salum MR, Lam DT, Wexner SD, Pikarsky A, Baig MK, Weiss EG, et al. Does limited placement of bioresorbable membrane of modified sodium hyaluronate and carboxymethylcellulose (Seprafilm) have possible short-term beneficial impact? *Dis Colon Rectum* 2001;44:706-12.

10. Klingler PJ, Floch NR, Seelig MH, Branton SA, Wolfe JT, Metzger PP. Seprafilm-induced peritoneal inflammation: a previously unknown complication. Report of a case. *Dis Colon Rectum* 1999;42:1639-43.
11. Bowers D, Raybon RB, Wheelless CR Jr. Hyaluronic acid-carboxymethylcellulose film and perianastomotic adhesions in previously irradiated rats. *Am J Obstet Gynecol* 1999;181:1335-8.
12. Zong X, Li S, Chen E, Garlick B, Kim KS, Fang D, et al. Prevention of postsurgery-induced abdominal adhesions by electrospun bioabsorbable nanofibrous poly(lactide-co-glycolide)-based membranes. *Ann Surg* 2004;240:910-5.
13. Sawada T, Hasegawa K, Tsukada K, Kawakami S. Adhesion preventive effect of hyaluronic acid after intraperitoneal surgery in mice. *Hum Reprod* 1999;14:1470-2.
14. Polymeneas G, Theodosopoulos T, Stamatiadis A, Kourias E. A comparative study of postoperative adhesion formation after laparoscopic vs open cholecystectomy. *Surg Endosc* 2001;15:41-3.
15. Tittel A, Treutner KH, Titkova S, Ottinger A, Schumpelick V. New adhesion formation after laparoscopic and conventional adhesiolysis: a comparative study in the rabbit. *Surg Endosc* 2001;15:44-6.
16. Klingler PJ, Floch NR, Seelig MH, Branton SA, Wolfe JT, Metzger PP. Seprafilm-induced peritoneal inflammation: a previously unknown complication. Report of a case. *Dis Colon Rectum* 1999;42:1639-43.
17. Bowers D, Raybon RB, Wheelless CR Jr. Hyaluronic acid-carboxymethylcellulose film and perianastomotic adhesions in previously irradiated rats. *Am J Obstet Gynecol* 1999;181:1335-8.
18. Pinerolo MC, Porri MT, D'Amico G. Recurrent sterile peritonitis at onset of treatment with icodextrin solution. *Perit Dial Int* 1999;19:491-2.
19. Heering P, Brause M, Plum J, Grabensee B. Peritoneal reaction to icodextrin in a female patient on CAPD. *Perit Dial Int* 2001;21:321-2.
20. Del Rosso G, Di Liberato L, Perilli A, Cappelli P, Bonomini M. A new form of acute adverse reaction to icodextrin in a peritoneal dialysis patient. *Nephrol Dial Transplant* 2000;15:927-8.
21. Reichel W, Schulze B, Dietze J, Mende W. A case of sterile peritonitis associated with icodextrin solution. *Perit Dial Int* 2001;21:414-5.
22. Williams PF, Foggensteiner L. Sterile/allergic peritonitis with icodextrin in CAPD patients. *Perit Dial Int* 2002;22:89-90.
23. Goffin E, Scheiff JM. Transient sterile chemical peritonitis in a CAPD patient using icodextrin. *Perit Dial Int* 2002;22:90-1.
24. Goffin E, Tintillier M, Cosyns JP, Devuyst O. Sterile chemical peritonitis secondary to icodextrin: immunohistopathological description. *Perit Dial Int* 2002;22:723-6.
25. Gauwerky J, Heinrich D, Kubli F. Complications and side effects of artificial ascites for adhesion prevention. *Geburtshilfe Frauenheilkd* 1985;45:664-9. [Abstract]
26. Tan B, Wang JH, Wu QD, Kirwan WO, Redmond HP. Sodium hyaluronate enhances colorectal tumour cell metastatic potential in vitro and in vivo. *Br J Surg* 2001;88:246-50.
27. Rice PJ, Kelley JL, Kogan G, Ensley HE, Kalbfleisch JH, Browder IW, et al. Human monocyte scavenger receptors are pattern recognition receptors for (1->3)-beta-D-glucans. *J Leukoc Biol* 2002;72:140-6.