

Accidental late PEG dislodgment in 3 cases with a narrow stoma: Bougie dilatation rescue

İbrahim Hakkı Köker, M.D.,¹ Özlem Yenidünya, M.D.,² Nurten Akyürek Savaş, M.D.,¹
Şerife Değirmenciöglü Tosun, M.D.,³ Can Davutoğlu, M.D.³

¹Başkent University Medicine Faculty, Istanbul Hospital, Department of Gastroenterology, İstanbul-Türkiye

²Başkent University Medicine Faculty, Istanbul Hospital, Department of Anesthesiology, İstanbul-Türkiye

³Bezmailem Vakif University Medicine Faculty, Department of Gastroenterology, İstanbul-Türkiye

ABSTRACT

Percutaneous endoscopic gastrostomy (PEG) is a simple and effective method of enteral nutrition for many patients who cannot take oral food. The accidental dislodgment of the PEG tube after the maturation of the gastrocutaneous fistula (stoma) is called late dislodgment. If it is not detected early, the stoma lumen gets narrower and does not permit the passage of the replacement tube. In this case, the commonly followed method is to continue enteral nutrition by opening a new gastrocutaneous fistula after the complete closure of the original stoma. Here, we present a stoma-saving bougie dilatation method in 3 cases with severely narrowed stomas after late accidental dislodgment of the PEG tube.

Keywords: Bougie dilatation; Late PEG dislodgment; PEG stoma rescue.

INTRODUCTION

Percutaneous endoscopic gastrostomy (PEG) tube placement was first described in the 1980s.^[1] It is an endoscopic surgical method used for enteral nutrition in patients without oral intake and with a long-life expectancy.^[2] It has become the method of choice for patients with a functional gastrointestinal tract requiring long-term enteral nutrition.^[3]

Late accidental tube dislodgment is the dislodgment of the PEG tube after stoma maturation is completed. If this is detected late, the stomal narrowing has progressed to an extent that prevents the passage of the replacement tube. Therefore, according to current practice, a new gastrocutaneous fistula is created after the complete closure of the stoma.^[4] Herein, we report our experience in our bougie dilation rescue method in three late accidental PEG dislodgment cases with a narrow stoma.

CASE REPORT

We retrospectively reviewed three late accidental PEG dislodgment rescue cases with a severely narrowed stoma. The patients and their relatives obtained informed consent before the procedure.

We evaluated the first two cases (a 78-year-old female and an 83-year-old male) in the endoscopy unit. In both cases, the replacement tubes could not be placed due to the severe narrowing of the stoma. Although we initially considered placing a new PEG catheter endoscopically, as a standard method suggested in the literature,^[4] the cardiorespiratory conditions of these patients were at high risk for endoscopic sedation. Hence, we decided to perform bougie dilatation of the stenotic stoma with local anesthesia. A 0.035-mm guide wire (Boston Scientific, Alajuela, Costa Rica) passed through the stenosis in the stoma. Then, the stenotic stoma was dilated through Savary-Gilliard bougies (SGD-70-1, Cook Medical, Limerick, Ireland) at 5, 7, and 9 mm, respectively. Finally, a 20

Cite this article as: Köker İH, Yenidünya Ö, Akyürek Savaş N, Değirmenciöglü Tosun Ş, Davutoğlu C. Accidental late PEG dislodgment in 3 cases with a narrow stoma: Bougie dilatation rescue. *Ulus Travma Acil Cerrahi Derg* 2023;29:1382-1384.

Address for correspondence: İbrahim Hakkı Köker, M.D.

Department of Gastroenterology, Başkent University Medicine Faculty, Istanbul Hospital, İstanbul, Türkiye

E-mail: koker34@yahoo.com

Ulus Travma Acil Cerrahi Derg 2023;29(12):1382-1384 DOI: 10.14744/tjtes.2023.09130 Submitted: 07.04.2023 Revised: 30.08.2023 Accepted: 18.10.2023
OPEN ACCESS This is an open access article under the CC BY-NC license (<http://creativecommons.org/licenses/by-nc/4.0/>).



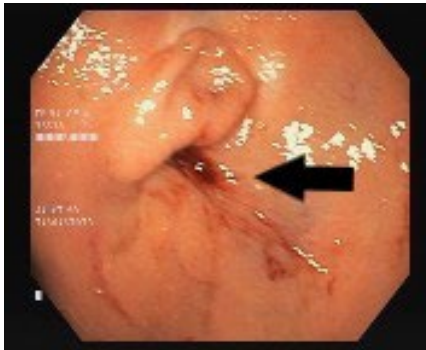


Figure 1. Percutaneous endoscopic gastrostomy stoma gastric orifice (black arrow)

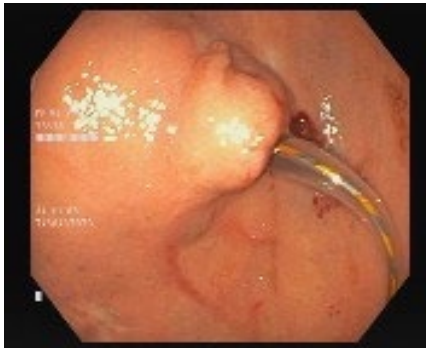

Figure 2. Bougie dilatation of the stoma through 9-mm Savary-Gilliard bougie

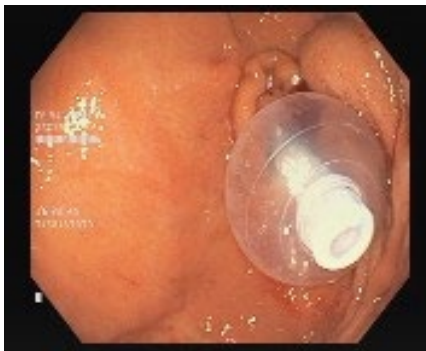

Figure 3. Inflated balloon of percutaneous endoscopic gastrostomy replacement tube

Fr diameter PEG replacement tube (Galena, Hangzhou Fushan Medical, Shenzhen, China) was passed through the stoma over the guide wire and inflated the balloon of the replacement tube. The follow-ups of the patients were uneventful.

The third patient, a 63-year-old male fed through a PEG tube for the past 6 years, was operated on recently for a subdural hematoma. In the post-operative follow-up, tube dislodgment was noticed in the intensive care unit. The replacement tube could not be reinserted through the narrow stoma. Therefore, a guide wire passed through the narrowed stoma and started bougie dilatation. However, the 9-mm bougie failed to pass due to significant resistance. Consequently, we decided to repeat bougie dilatation under endoscopic imaging. We used a standard gastroscope (Olympus type GIF-H170 2032181, Center Valley, PA, USA). We found the stoma orifice in the gastric corpus (Fig. 1). Then, a flexible, straight-tipped, 0.035-inch guide wire (Boston Scientific, Alajuela, Costa Rica) was advanced from the cutaneous orifice of the fistula on the abdomen toward the gastric corpus under endoscopic vision. Then, the 5 and 7-mm bougies passed through the stoma

without difficulty. Afterward, the 9-mm bougie through the stoma was advanced with twisting movements against the resistance (Fig. 2). Finally, the 20 Fr replacement tube (Galena, Hangzhou Fushan Medical, Shenzhen, China) was easily placed through the stoma, inflated the balloon, and completed the procedure. (Fig. 3). The mean operative time was 15 min. There were no complications related to the PEG rescue. The patient tolerated the procedure well and could resume using a replacement tube shortly after the intervention.

DISCUSSION

PEG is technically successful and practical, and it can be performed quickly compared to the open surgical gastrostomy method.^[5] The complication rate is low, including bleeding, aspiration, intra-abdominal organ damage, peristomal leakage, and accidental tube dislodgment.

Accidental PEG tube dislodgment, which can develop early or late after PEG tube placement, is an important factor in the patient's follow-up. Early dislodgment occurs in the first 4 weeks until the gastrocutaneous fistula tract's (stoma) mat-

uration is observed at a rate of 4%. Since the tract is not mature, early dislodgment carries the risk of peritonitis and sepsis due to intraperitoneal gastric leakage.^[6] In cases of late dislodgment seen after the first 4 weeks, the stoma narrows rapidly and closes if not detected early. Therefore, if detected early, a replacement tube or a Foley catheter is placed at the bedside; however, if the stoma is very narrow that the replacement tube cannot pass, then it is recommended to place a new pull-type PEG tube from a different point, according to the literature.^[4]

The bougie dilatation rescue method, described here in 3 cases, allows the insertion of the replacement tube by dilating the narrowed stoma with bougies under endoscopic vision. During the bougie dilatation phase, the initial bougie number is adjusted according to the existing narrowness. It gradually increased from the lowest caliber until it reached the width where the replacement tube could easily pass. In our practice, 5, 7, and 9-mm bougies were sufficient for this procedure. The advantage of this technique is that it allows the reuse of the existing stoma. To the best of our knowledge, the bougie dilatation rescue method is novel and has not been described in the literature before.

Regarding complications, the adverse event incident rate ranges from 4.8% to 26.2%, 30-day mortality is 1.8%–23.5%, and 1-year mortality was reported as 35%–55% after PEG placement.^[7,8] Conversely, the bougie dilatation technique has no obvious disadvantages due to its ease of application. Further studies are needed to identify the complications associated with this novel technique. However, as far as we can see from our limited number of patient experiences, we believe that no significant risk will be encountered in experienced hands. It is also a cost-effective method compared to placing a new PEG tube.

CONCLUSION

In conclusion, bougie dilatation rescue for a severely nar-

rowed PEG stoma allowed safer re-establishment of the gastrostomy tract while avoiding a new puncture and related risks.

Peer-review: Externally peer-reviewed.

Authorship Contributions: Concept: İ.H.K.; Design: İ.H.K., Ö.Y.; Supervision: İ.H.K., N.A.S.; Data collection and/or processing: Ş.D.T., C.D.; Analysis and/or interpretation: İ.H.K., Ö.Y.; Literature search: Ö.Y., N.A.S., Ş.D.T., C.D.; Writing: İ.H.K.; Critical review: Ö.Y., N.A.S., Ş.D.T., C.D.

Conflict of Interest: None declared.

Financial Disclosure: The author declared that this study has received no financial support.

REFERENCES

- Gauderer MW, Ponsky JL, Izant RJ Jr. Gastrostomy without laparotomy: A percutaneous endoscopic technique. *J Pediatr Surg* 1980;15:872–5.
- Rajan A, Wangrattanapranee P, Kessler J, Kidambi TD, Tabibian JH. Gastrostomy tubes: Fundamentals, periprocedural considerations, and best practices. *World J Gastrointest Surg* 2022;14:286–303. [CrossRef]
- Ponsky JL. Percutaneous endoscopic gastrostomy: After 40 years. *Gastrointest Endosc* 2021;93:1086–7. [CrossRef]
- Bream P Jr., Krohmer SJ, Pillai AK, Bones Md BL, Dickey KW. Percutaneous gastrostomy: How to recognize, avoid, or get out of trouble. *Tech Vasc Interv Radiol* 2018;21:255–60. [CrossRef]
- Bankhead RR, Fisher CA, Rolandelli RH. Gastrostomy tube placement outcomes: Comparison of surgical, endoscopic, and laparoscopic methods. *Nutr Clin Pract* 2005;20:607–12. [CrossRef]
- Rosenberger LH, Newhook T, Schirmer B, Sawyer RG. Late accidental dislodgement of a percutaneous endoscopic gastrostomy tube: An underestimated burden on patients and the health care system. *Surg Endosc* 2011;25:3307–11. [CrossRef]
- Anderloni A, Di Leo M, Barzaghi F, Semeraro R, Meucci G, Marino R, et al. Complications and early mortality in percutaneous endoscopic gastrostomy placement in Lombardy: A multicenter prospective cohort study. *Dig Liver Dis* 2019;51:1380–7. [CrossRef]
- Kara O, Kizilarslanoglu MC, Canbaz B, Arık G, Varan HD, Kuyumcu ME, et al. Survival after percutaneous endoscopic gastrostomy in older adults with neurologic disorders. *Nutr Clin Pract* 2016;31:799–804.

OLGU SUNUMU - ÖZ

PEG tüpünün geç dönemde yerinden çıkması sonucu belirgin stoma darlığı gelişmiş 3 olguda buji dilatasyonu ile stomanın kullanılabilir hale getirilmesi

Dr. İbrahim Hakkı Köker,¹ Dr. Özlem Yenidünya,² Dr. Nurten Akyürek Savaş,¹ Dr. Şerife Değirmencioğlu Tosun,³ Dr. Can Davutoğlu³

¹Başkent Üniversitesi Tıp Fakültesi, İstanbul Hastanesi, Gastroenteroloji Bilim Dalı, İstanbul, Türkiye

²Başkent Üniversitesi Tıp Fakültesi, İstanbul Hastanesi, Anestezi Anabilim Dalı, İstanbul, Türkiye

³Bezmialem Vakıf Üniversitesi Tıp Fakültesi, Gastroenteroloji Bilim Dalı, İstanbul, Türkiye

Perkütan endoskopik gastrostomi (PEG), oral gıda alamayan birçok hastada basit ve etkili bir enteral beslenme yöntemidir. Gastro-kütanöz fistül (stoma) olgunlaştıktan sonra PEG tüpünün yerinden çıkması geç dönem olarak adlandırılır. Erken tespit edilmezse, stoma lümeni daralır ve replasman tüpünün geçişine izin vermez. Bu durumda izlenen yöntem orijinal stomanın tamamen kapanmasından sonra yeni bir gastro-kütanöz fistül açılarak yeni bir PEG tüpü yerleştirilmesidir. Burada, PEG tüpünün geç dönemde yerinden çıkması sonrası ciddi şekilde daralmış stomalı 3 olguda stoma kurtarıcı buji dilatasyon yöntemini sunuyoruz.

Anahtar sözcükler: Buji dilatasyonu; geç PEG çıkması; PEG stoma kurtarılması.

Ulus Travma Acil Cerrahi Derg 2023;29(12):1382-1384 DOI: 10.14744/tjtes.2023.09130