

Combined diaphragmatic and urinary bladder rupture after minor motorcycle accident (Report of a case and literature review)

Hafif bir motosiklet kazası sonrası birlikte gelişen diyafragma ve mesane rüptürü (Olgu sunumu ve literatürün gözden geçirilmesi)

Stavros GOURGIOTIS,¹ Stefanie ROTHKEGEL,² Stylianos GERMANOS¹

Diaphragmatic and urinary bladder ruptures are rare entities after blunt abdominal trauma and they are usually the results of high energy injuries. They seldom occur in isolation. For the diaphragmatic rupture, the accurate diagnosis depends on high index of suspicion and careful scrutiny of the chest X-ray, while gross hematuria is the hallmark finding in patients with bladder rupture. Suprapubic pain, tenderness, and inability to void are the main symptoms and signs of bladder rupture. In this report, we describe our successful experience with a case of combined diaphragmatic and urinary bladder rupture occurred in isolation as a result of low energy trauma, with special emphasis on diagnosis and surgical treatment.

Key Words: Abdominal injuries/diagnosis/surgery; diaphragm; rupture; urinary bladder/injuries/surgery; wounds, nonpenetrating.

Diyaframla mesane rüptürleri künt abdominal travmadan sonra nadirdir ve genellikle yüksek enerjili travmalardan sonra gelişirler. Tek başlarına oluşmaları enderdir. Diyafram rüptürünün kesin tanısı, şüpheye ve göğüs radyografi filminin dikkatle incelenmesine dayanırken, mesane rüptürü olan hastalardaki temel bulgu makroskopik hematürüdür. Suprapubik ağrı, hassasiyet ve idrar yapamama, mesane rüptürü ile ilgili ana belirti ve semptomlardır. Bu yazıda, tanı ve cerrahi tedavi konularına özel vurgu yaparak, düşük enerjili bir travma sonucunda oluşan birlikte diyafram ve mesane rüptürlü bir olgudaki başarılı bir deneyimimizi sunuyoruz.

Anahtar Sözcükler: Diyafram; karın yaraları/tanı/cerrahi; mesane/yaralanma/cerrahi; yaralar, künt; yırtık.

Diaphragmatic (DR) and urinary bladder (BR) ruptures are rare entities after blunt trauma. They are often the result of high energy blunt injuries and hardly ever occur isolated.^(1,2)

This is a rare case of combined DR and BR occurred in isolation as a result of low energy blunt trauma. This is also a good illustration of the difficulty of diagnosis of combined DR and BR, especially in the failure of maintaining high index of suspicion and when the mechanism of injury is not suggestive for these injuries.

CASE REPORT

A 25-year-old man was referred on an emergency basis to our department after a motorcycle accident, with approximately 30 km/h. It was a frontal collision between his motorbike and a stationary car and the patient was thrown by the impact against the windshield. Initially, the interdisciplinary evaluation showed a hemodynamically stable patient with pulse rate 110 beats per minute, respiratory rate 18 breaths per minute, blood pres-

¹2nd Department of Surgery, 401 General Military Hospital of Athens, Athens, Greece; ²Department of Emergency Surgery, Justus-Liebig University, Giessen; Germany.

¹401. Genel Asker Hastanesi, 2. Genel Cerrahi Kliniği, Atina, Yunanistan;

²Justus-Liebig Üniversitesi, Acil Cerrahi Bölümü, Giessen, Almanya.

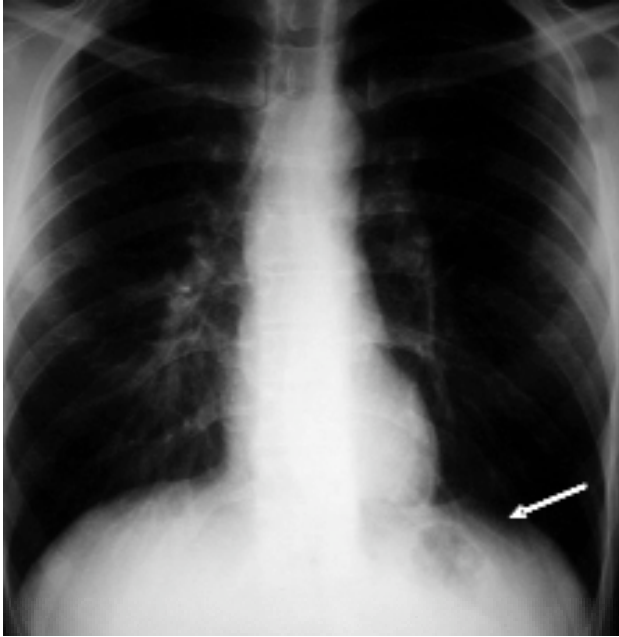


Fig. 1. Chest X-ray indicating loss of sequence of the left diaphragmatic border (arrow).

sure 130/80 mmHg, and multiple left forearm abrasions. On clinical examination, the patient was in suprapubic discomfort, and the lower abdomen was tender with rebound tenderness. No cerebral injury was detected. Because the patient was unable to void, he was catheterized and bloodstained urine was obtained.

Plain chest X-ray showed a loss of sequence of left diaphragmatic border (Fig. 1), while pelvic X-ray was normal; further evaluation with new series

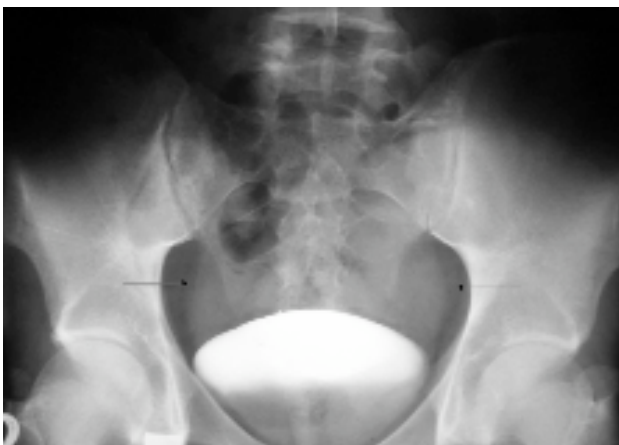

Fig. 2. Frontal retrograde cystogram; there is a suspicion of contrast medium extravasation on the right and left of the urinary bladder (arrows).

of chest X-rays was not obtained. The abdominal ultrasound (US) showed a small amount of fluid in the abdominal cavity and the contrast enhanced computed tomography (CT) showed free fluid into the peritoneal cavity without solid organ injuries and no pathological findings of the diaphragm and urinary bladder at that point. No additional injuries were observed. CT cystography was not performed at that point due to poor communication with the radiologist. Taking into consideration the absence of solid organ injury and the free fluid in the abdominal CT, in combination with the presence of macroscopic hematuria, we decided that the patient should have further investigation with a retrograde cystogram; the urinary bladder rupture was strongly suggested by the evidence. The cystogram demonstrated extravasation of contrast medium into the peritoneal cavity (Fig. 2, 3).

Because of the diagnosis of intra-peritoneal bladder rupture and equivocal signs of peritoneal irritation and since diaphragmatic rupture could not be excluded, an exploratory laparoscopy was per-

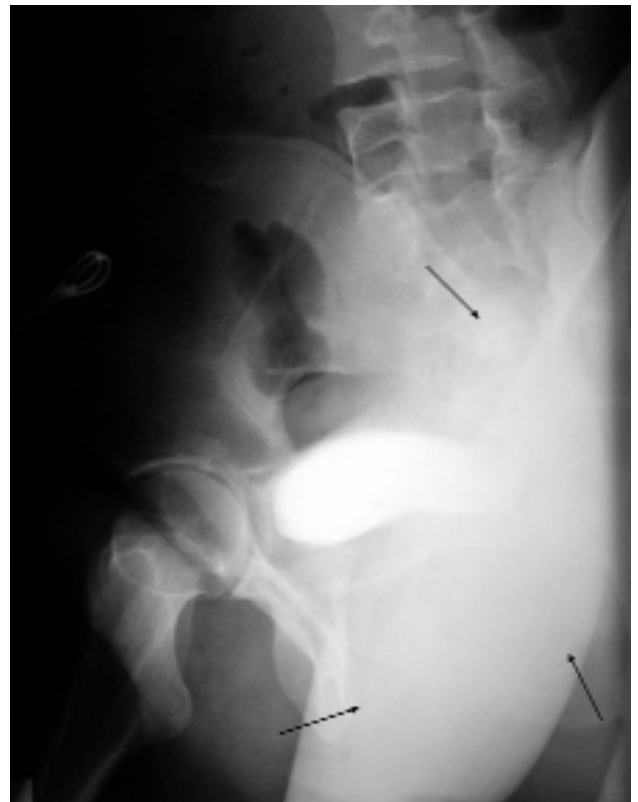

Fig. 3. Profile retrograde cystogram demonstrated extravasation of contrast medium (arrows).

formed. Three 5 mm ports and a 5 mm laparoscope were used. Laparoscopic examination of the abdomen revealed a 4 cm rupture at the dome of the bladder and 3 cm rupture at the left hemidiaphragm. Direct laparoscopic repair of diaphragmatic rupture with interrupted non absorbable sutures was feasible. We didn't manage to repair laparoscopically the rupture of the bladder so its surgical management was by Pfannenstiel incision, in two layers with interrupted absorbable sutures. No drainage was used. The postoperative course was uneventful. The urethral catheter was removed 10 days postoperatively; a repeated cystogram revealed no evidence of leak. The patient had no voiding or breathing complaints 4 weeks after the operation.

DISCUSSION

The reported incidence of blunt DR varies between 1% and 7%^[3] in hospitalized victims of motor vehicle crashes. It is associated with additional injuries such as fractures of the ribs, long bones fractures, pelvic fractures, intracranial hematoma, and injury of upper abdominal viscera.^[2] The right diaphragm appears to be partially protected by the liver and its ability to dissipate pressure over a large area, thereby decreasing the incidence of right-sided DR.^[4]

The striking problem with traumatic DR is the frequent difficulty in making the diagnosis in conservatively treated patients with traumas of the thoracoabdominal area. Although abnormal radiographs commonly reveal elevation of the hemidiaphragm, blunting of the costophrenic angle, absence of a sharp hemidiaphragm, or presence of a hemopneumothorax, only 25% to 50% of the initial chest roentgenograms are diagnostic for diaphragmatic rupture or injury.^[4] Initially, CT scanning appeared to be the ideal medium for visualizing DR. Subsequent experience with CT scanning, however, has revealed this diagnostic modality to be inconsistently reliable.^[5] Success rates from 42% to 84% have been reported.^[4,6] Magnetic resonance imaging (MRI) has been demonstrated to be relatively accurate in the diagnosis of blunt DR in conservatively treated patients with hemodynamic stability,^[7] but is of no value in the hemodynamically unstable patients with multiple injuries. Several authors reported high diagnostic accuracy of laparoscopy in patients with DR.^[8,9] Similar good

results in diagnostic accuracy have been reported with diagnostic thoracoscopy.^[10] In the present case, the suspicion of the left hemidiaphragm rupture was made by radiologic examination and the final diagnosis was made by laparoscopy.

BR is usually the result of blunt or penetrating trauma and its vulnerability varies with its degree of filling. Generally, an empty bladder is less vulnerable to be injured than a distended bladder. In the case of blunt trauma, BR may be the result of a blow to the lower abdomen or a fractured pelvis.^[11] An acantha from a bony fracture may tear the bladder and lead to extra-peritoneal leakage. A direct blow to the abdomen may lead to a sudden raise of intra-abdominal pressure ('blow out' injury) and if the organ is full of urine and distended it may be ruptured at its most vulnerable part which is the dome. BR occurs in 2% of abdominal trauma cases that require surgical repair.^[11] A range from 60% to 90% is associated with pelvic fractures.^[12] Intraperitoneal BR account for 38%-40% of all BR. The symptoms are suprapubic discomfort and an inability to void, and the signs are hematuria (gross in 95%; the hallmark of BR), suprapubic tenderness, signs of major trauma in the pelvic/perineal area, ileus, absent bowel sounds, abdominal distension (with intraperitoneal rupture, urinary ascites, signs of abdominal sepsis (in the setting of delayed diagnosis). Our patient exhibited suprapubic discomfort, lower abdominal distension and tenderness, hematuria, and inability to void. The physical examination and history are of limited value.

Gross hematuria with pelvic fracture and with no findings in contrast enhanced CT is an absolute indication for cystogram; while gross hematuria without pelvic fractures and microhematuria are relative indications for cystogram.^[13] Current evidence suggests that CT cystography is equivalent to conventional radiographic cystography and if CT is necessary for abdominal evaluation, CT cystography should be preferred.^[14] The reported sensitivity and specificity of CT cystography in determining the BR are 95% and 100% respectively.^[13] Conventional contrast enhanced CT with only passive filling of the bladder and catheter clamping has a high rate of false negative results and it should not be used to exclude bladder injury.^[11,15] Its accuracy is estimated to be of only 60.6% when compared with 95.9% of the retrograde cystogram.^[1] In this

case, the diagnosis of BR was suspected clinically but was confirmed by cystogram. There was an additional 2 hours delayed in diagnosis until the time of retrograde cystogram was obtained since we did not perform CT cystography during the initial CT. This might be a problem if the patient was hemodynamically unstable.

The initial approach for potential combined DR and BR after blunt trauma should always be exploratory laparotomy or laparoscopy with meticulous inspection, palpation and visualization of diaphragm and urinary bladder. Laparoscopy can be quickly and safely performed, offers a high rate of diagnostic success, and is minimally invasive. Because of the smallest openings the postoperative problems associated with laparotomy can be drastically diminished. In suitable case, like our report, closure of the primary defect can be performed at the same time as diagnosis. Unfortunately, we couldn't complete the laparoscopy repair of the bladder due to redundant and distended sigmoid colon and because we had no previous experience in laparoscopic urinary bladder repair.

In summary, the diagnosis of combined diaphragmatic and urinary bladder rupture due to blunt trauma requires a high index of suspicion; chest X-ray and cystogram are the screening tests of choice. Once diagnosed, operation is indicated through the abdomen. Laparoscopy is both a good diagnostic and, under certain conditions, therapeutic tool.

REFERENCES

1. Hsieh CH, Chen RJ, Fang JF, Lin BC, Hsu YP, Kao JL, et al. Diagnosis and management of bladder injury by trauma surgeons. *Am J Surg* 2002;184:143-7.
2. Mihos P, Potaris K, Gakidis J, Paraskevopoulos J, Varvatsoulis P, Gougoutas B, et al. Traumatic rupture of the diaphragm: experience with 65 patients. *Injury* 2003;34:169-72.
3. Reber PU, Schmied B, Seiler CA, Baer HU, Patel AG, Büchler MW. Missed diaphragmatic injuries and their long-term sequelae. *J Trauma* 1998;44:183-8.
4. Shapiro MJ, Heiberg E, Durham RM, Luchtefeld W, Mazuski JE. The unreliability of CT scans and initial chest radiographs in evaluating blunt trauma induced diaphragmatic rupture. *Clin Radiol* 1996;51:27-30.
5. Allen TL, Cummins BF, Bonk RT, Harker CP, Handrahan DL, Stevens MH. Computed tomography without oral contrast solution for blunt diaphragmatic injuries in abdominal trauma. *Am J Emerg Med* 2005;23:253-8.
6. Larici AR, Gotway MB, Litt HI, Reddy GP, Webb WR, Gotway CA, et al. Helical CT with sagittal and coronal reconstructions: accuracy for detection of diaphragmatic injury. *AJR Am J Roentgenol* 2002;179:451-7.
7. Shanmuganathan K, Mirvis SE, White CS, Pomerantz SM. MR imaging evaluation of hemidiaphragms in acute blunt trauma: experience with 16 patients. *AJR Am J Roentgenol* 1996;167:397-402.
8. Matthews BD, Bui H, Harold KL, Kercher KW, Adrales G, Park A, et al. Laparoscopic repair of traumatic diaphragmatic injuries. *Surg Endosc* 2003;17(2):254-8.
9. Smith CH, Novick TL, Jacobs DG, Thomason MH. Laparoscopic repair of a ruptured diaphragm secondary to blunt trauma. *Surg Endosc* 2000;14:501-2.
10. Reiff DA, McGwin G Jr, Metzger J, Windham ST, Doss M, Rue LW 3rd. Identifying injuries and motor vehicle collision characteristics that together are suggestive of diaphragmatic rupture. *J Trauma* 2002;53:1139-45.
11. Lynch TH, Martínez-Piñero L, Plas E, Serafatinides E, Türkeri L, Santucci RA, et al. EAU guidelines on urological trauma. *Eur Urol* 2005;47:1-15.
12. Deck AJ, Shaves S, Talner L, Porter JR. Computerized tomography cystography for the diagnosis of traumatic bladder rupture. *J Urol* 2000;164:43-6.
13. Gomez RG, Ceballos L, Coburn M, Corriere JN Jr, Dixon CM, Lobel B, et al. Consensus statement on bladder injuries. *BJU Int* 2004;94:27-32.
14. Wah TM, Spencer JA. CT of adult urinary tract trauma. *Imaging* 2005;17:53-68.
15. Deck AJ, Porter JR. Diagnostic peritoneal lavage as sole indicator of intraperitoneal bladder rupture: case report. *J Trauma* 2000;49:946-7.