

# Hypovolemic shock due to giant ovarian tumor rupture after minor trauma: A case report

Yılmaz Güler, M.D.,<sup>1</sup> Hasan Çalış, M.D.,<sup>1</sup> Serkan Şengül, M.D.,<sup>1</sup>  
Özkan Özen, M.D.,<sup>2</sup> Zülfikar Karabulut, M.D.<sup>1</sup>

<sup>1</sup>Department of General Surgery, Alanya Alaaddin Keykubat University Faculty of Medicine, Antalya-Turkey

<sup>2</sup>Department of Radiology, Alanya Alaaddin Keykubat University Faculty of Medicine, Antalya-Turkey

## ABSTRACT

Rupture of gynecologic tumors secondary to trauma rarely occurs. Rupture can lead to acute abdominal pain due to hemorrhage from the ruptured area and organs; rupture can also lead to peritonitis, depending on the size of the tumor. We describe the case of giant epithelial ovarian tumor rupture exhibiting due to minor trauma and the development of hypovolemic shock. A 69-year-old female patient was admitted to the emergency room with complaints of acute abdominal pain and subsequent clouding of consciousness after falling down while walking. Emergency abdominal computed tomography scan revealed widespread hemorrhagic free fluid in the abdominal cavity and a mass measuring 27.5 cm × 21 cm × 15 cm, extending from the right quadrant of the abdomen to the left. The patient underwent an emergency operation due to hypovolemic shock. During surgery, a totally ruptured mass lesion arising from the right ovary was seen; the mass contained cystic components and measured approximately 30 cm × 20 cm × 15 cm. Hemostasis was achieved in the bleeding areas, and the right ovarian mass was totally resected. The patient was discharged as cured on the 6<sup>th</sup> post-operative day. Gynecologic tumor rupture due to trauma is a rare event. However, it is a clinical condition that should be kept in mind regardless of the type of trauma. This is especially true in patients who experienced trauma and were radiologically found to have intra-abdominal hemorrhage with normal-appearing solid organs, such as liver and spleen, that frequently cause bleeding.

**Keywords:** Hypovolemic shock; ovarian neoplasm; rupture; trauma.

## INTRODUCTION

Rupture of gynecologic tumors may result in acute abdominal pain due to bleeding or peritonitis, depending on the size of the tumor and site of the rupture. There have been rare reports of spontaneous rupture of gynecologic tumors, especially teratomas, into the abdominal cavity or adjacent organs (small intestines, colon, and rectum).<sup>[1,2]</sup>

Ovarian epithelial tumors are the leading cause of death among gynecological cancers<sup>[3]</sup> and rank fifth in cancer deaths among women.<sup>[4]</sup> The two most important types of ovarian epithelial tumors are serous and mucinous cystadenocarcinomas. Rupture of epithelial tumors is much less common and

usually associated with manipulation during surgery.<sup>[5]</sup> In cases wherein spontaneous rupture of these tumors is reported in the literature, the cause usually involves pregnancy, due to anticoagulant use.<sup>[6,7]</sup>

Gynecological tumor rupture due to trauma is a very rare condition. In the literature, three ovarian germ cell tumors (two cases teratoma and one case yolk sac tumor) and one benign dermoid cyst rupture due to a blunt abdominal trauma has been reported.<sup>[8-11]</sup> According to our knowledge, this is the first case in the literature and we describe giant epithelial ovarian tumor rupture due to minor trauma accompanied by hypovolemic shock due to hemorrhage.

Cite this article as: Güler Y, Çalış H, Şengül S, Özen Ö, Karabulut Z. Hypovolemic shock due to giant ovarian tumor rupture after minor trauma: A case report. *Ulus Travma Acil Cerrahi Derg* 2021;27:486-489.

Address for correspondence: Yılmaz Güler, M.D.

Alanya Alaaddin Keykubat Üniversitesi Tıp Fakültesi, Genel Cerrahi Anabilim Dalı, Antalya, Turkey

Tel: +90 242 - 510 61 35 E-mail: yilmaz.guler@alanya.edu.tr

*Ulus Travma Acil Cerrahi Derg* 2021;27(4):486-489 DOI: 10.14744/tjtes.2020.07045 Submitted: 04.08.2019 Accepted: 20.03.2020

Copyright 2021 Turkish Association of Trauma and Emergency Surgery

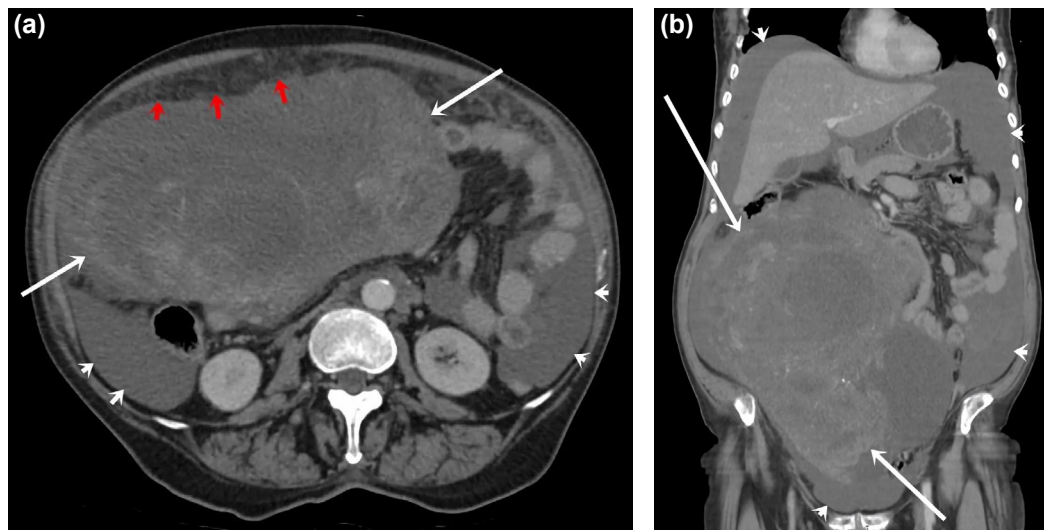


## CASE REPORT

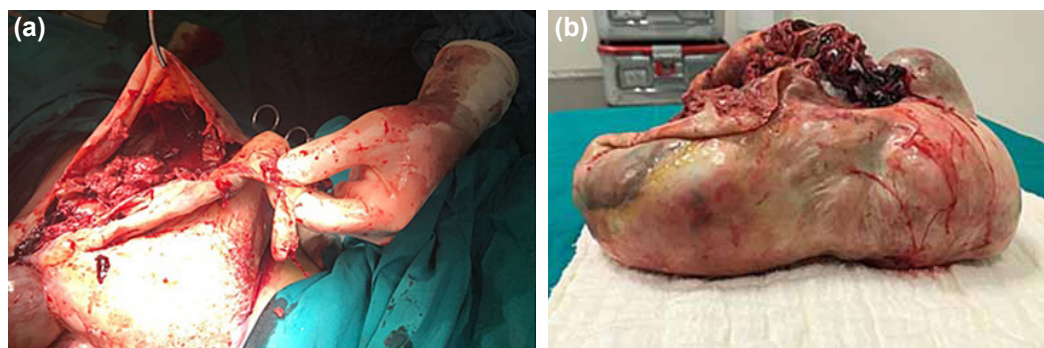
A 69-year-old female patient was admitted to the emergency room with complaints of acute abdominal pain and subsequent clouding of consciousness after falling down while walking. The patient had no any illness and drug use in medical and family history. It was learned that she had gynecologic examination at another hospital 3 years ago last time and the findings were normal. Physical examination of the patient revealed that the general condition was poor, the patient was confused and non-cooperative, arterial blood pressure was 40/20 mmHg, and pulse rate was 121 bpm. Abdominal physical examination could not be evaluated due to clouding of consciousness; however, a generalized abdominal distention was noted. In laboratory tests, leukocyte count (white blood cell) was  $10.28 \times 10^9$ , hemoglobin value was 10.77 g/dL (14–18 g/dL), hematocrit was 32.08 (40–53%), platelet count was  $74 \times 10^9$ , and biochemical parameters were found to be within normal limits. Emergency abdominal computed tomography performed following i.v. fluid resuscitation revealed intra-abdominal free fluid and a lesion filling the right quadrant with a maximum axial dimension of 15 cm  $\times$  21 cm and a maximum craniocaudal length of 27.5 cm; the lesion extended to

the left quadrant. The lesion had undefined borders (Fig. 1a and b). No pathology was found in other organs, thorax, and brain. Based on these findings, an emergency operation was performed.

During the operation, approximately 1800 ml of hemorrhagic fluid was found in the abdomen, and exploration revealed a right ovarian mass lesion containing cystic components and measuring approximately 30 cm  $\times$  20 cm  $\times$  15 cm. The anterior wall of the tumor was completely ruptured along the longitudinal axis, and hemorrhagic foci were seen in the ruptured areas. Hemostasis was achieved in the bleeding sites, and the right ovarian mass was totally resected (Fig. 2a and b). No other pathology was found in the uterus, left ovary, and other intra-abdominal organs. Hemoglobin value was 6.7 g/dL (14–18 g/dL) during the operation after fluid replacement with a total of five units of blood and two units of fresh frozen plasma being transfused in the pre-operative and post-operative periods. The patient was monitored in the intensive care unit for 2 days. She was transferred to the ward as vital signs and hemogram values became stable and bleeding was not detected. The patient was discharged on



**Figure 1.** (a, b) A tumor which completely filling the abdomen and intra-abdominal hemorrhagic fluid is seen in abdominal computed tomography.



**Figure 2.** (a) Perioperative view of the tumor, (b) tumor view after resection (dimensions of tumor 29.5 cm  $\times$  19 cm  $\times$  14.5 cm).

**Table 1.** Literature review for the ovarian tumor rupture due to trauma cases

Study	Year	Age	Country	Trauma type	Tumor diameter (cm)	Tumor Type
1 Chen et al. <sup>[8]</sup>	2012	8	Taiwan	Blunt	19x11x4.5	Yolk sac tumor
2 Levive et al. <sup>[9]</sup>	1992	26	USA	Traffic accident	8x8x7	Teratoma
3 Kimbrell et al. <sup>[10]</sup>	2007	18	USA	Traffic accident	15x8	Teratoma
4 Yohann et al. <sup>[11]</sup>	2017	15	USA	Traffic accident	3.8x2.6	Teratoma
5 Guler et al.	2019	69	Turkey	Fall down	29.5x19x14.5	Serous Cystadenocarcinoma

the 6th post-operative day as cured and referred gynecologic oncology department for staging surgery and further treatment. The resected tumor measured 29.5 cm × 19 cm × 14.5 cm and weighed 3.750 g. The histopathology report revealed an epithelial ovarian tumor identified as a low-grade serous cystadenocarcinoma. Hysterectomy, left oophorectomy, and lymph node dissection have been applied by gynecological oncology department. Stage of cancer was detected Stage 3 and adjuvant chemotherapy was applied.

## DISCUSSION

Trauma is one of the leading causes of deaths for people under the age of 45, and approximately 5 million people suffer traumas every year. Although variations occur depending on the type and severity of the trauma, hypovolemic shock due to blood loss is the most important cause of death associated with trauma. Even though varying rates are reported, 33–56% of patients with trauma-related hemorrhage die before reaching the hospital. Other than hemorrhage, deaths due to trauma usually involve secondary complications arising from organ injuries.<sup>[12]</sup>

Rupture of ovarian epithelial tumors is rare and usually associated with manipulation during surgery.<sup>[5]</sup> In cases wherein spontaneous rupture of these tumors is reported in the literature, the cause usually involves pregnancy.<sup>[6]</sup> Furthermore, rupture due to the use of anticoagulants has also been reported in the literature.<sup>[13]</sup> In our case, rupture developed due to minor trauma and there was no predisposing risk factor for rupture in patient's medical history. Gynecological tumor rupture due to minor trauma is a very rare condition. Rupture of an 19 cm × 11 cm × 4.5 cm ovarian yolk sac tumor due to an abdominal blunt trauma has been reported from Kaohsiung, Taiwan, at 2012.<sup>[8]</sup> Three benign ovarian benign cystic teratomas (dermoid cyst) rupture due to a blunt abdominal trauma has been reported in literature. One of them ruptures of an 8 cm × 8 cm × 7 cm dermoid cyst due to a traffic accident has been reported from Houston, USA, at 1992.<sup>[9]</sup> The 8 cm × 15 cm diameter ovarian dermoid cyst rupture due to a motorcycle accident has been reported from Los Angeles, USA, at 2007.<sup>[10]</sup> Other ovarian dermoid cyst

rupture has been reported from Gainesville, Florida, USA, at 2017 which was 3.8 cm × 2.6 cm diameter and due to traffic accident.<sup>[11]</sup> Although there are previously reported gynecologic tumor rupture examples due to trauma in the literature, the important specific characters of our case are giant tumor diameter, the first case of epithelial type ovarian tumor rupture due to minor trauma and subsequent development of hypovolemic shock due to the rupture. Our case is an important example of the gynecologic tumor ruptures which may cause development hypovolemic shock independently of the trauma type. The ovarian tumor rupture due to trauma cases has been demonstrated at Table 1 including our patient.

Gynecologic tumors can cause clinical complications such as hemorrhage, torsion, and rupture.<sup>[7]</sup> Tumor rupture manifests clinically and radiologically distinctive findings, depending on the type of rupture (intraperitoneal or involving adjacent organs such as small and large bowel, rectum, and bladder), and size of the tumor. Findings of peritonitis due to inflammation usually occur in ruptures and lead to perforations into the small and large intestines, while in ruptures that lead to bleeding into the peritoneal space, non-inflammatory acute abdominal symptoms and hemodynamic instability are seen. Laboratory findings may also vary depending on the rupture pattern.<sup>[2,6]</sup> In our patient, hemodynamic instability associated with rupture were prominent, and no positive findings were detected except for abdominal distension, as the abdominal examination could not be assessed clearly due to cloudy consciousness. The conventional treatment for hemorrhage and acute abdominal pain due to gynecologic tumor rupture is surgery. Excision of the tumor is the gold standard in surgical treatment. Additional surgical procedures are needed when there is a perforation of the small bowel, colon, rectum, or bladder.

As a result, cases with spontaneous rupture of gynecologic tumors into the abdominal cavity or adjacent organs have been reported in the literature. However, this clinical condition should be kept in mind in all patients who had acute abdomen or intra-abdominal bleeding findings with and without trauma history and regardless of the type of trauma. This is especially true in patients who experienced trauma and were radiologically found to have intra-abdominal hemorrhage with

normal-appearing solid organs, such as liver and spleen, that frequently cause bleeding.

## Acknowledgments

We thank to our patient for accepting to participating this case report study.

**Informed Consent:** Written informed consent was obtained from the patient for the publication of the case report and the accompanying images.

**Peer-review:** Internally peer-reviewed.

**Authorship Contributions:** Concept: Y.G.; Design: Y.G.; Supervision: Z.K.; Resource: H.Ç.; Materials: Y.G.; Data: Ö.O.; Analysis: S.Ş.; Literature search: H.Ç.; Writing: Y.G.; Critical revision: Z.K.

**Conflict of Interest:** None declared.

**Financial Disclosure:** The authors declared that this study has received no financial support.

## REFERENCES

1. Bats AS, Rockall AG, Singh N, Reznick RH, Jeyarajah A. Perforation of a malignant ovarian tumor into the rectosigmoid colon. *Acta Obstet Gynecol Scand* 2010;89:1362–3. [CrossRef]
2. Chang YT, Lin JY. Intraperitoneal rupture of mature cystic ovarian teratoma secondary to sit-ups. *J Formos Med Assoc* 2009;108:173–5. [CrossRef]
3. Lokadason R, James FV, Narayanan G, Prabhakaran PK. Targeted agents in epithelial ovarian cancer: review on emerging therapies and future developments. *Ecancermedicallscience* 2016;10:626. [CrossRef]
4. Ferlay J, Soerjomataram I, Dikshit R, Eser S, Mathers C, Rebelo M, et al. Cancer incidence and mortality worldwide: sources, methods and major patterns in GLOBOCAN 2012. *Int J Cancer* 2015;136:E359–86. [CrossRef]
5. Mizuno M, Kikkawa F, Shibata K, Kajiyama H, Suzuki T, Ino K, et al. Long-term prognosis of stage I ovarian carcinoma. Prognostic importance of intraoperative rupture. *Oncology* 2003;65:29–36. [CrossRef]
6. Salvadori PS, Bomfim LN, von Atzingen AC, D'Ippolito G. Spontaneous rupture of ovarian cystadenocarcinoma: pre- and post-rupture computed tomography evaluation. *Radiol Bras* 2015;48:330–2. [CrossRef]
7. Malhotra N, Sumana G, Singh A, Deka D, Mittal S. Rupture of a malignant ovarian tumor in pregnancy presenting as acute abdomen. *Arch Gynecol Obstet* 2010;281:959–61. [CrossRef]
8. Chen CF, Wong WY, Chuang CH, Yeh YS, Tsai KB, Wang JY. Ruptured ovarian yolk sac tumor combined with hemoperitoneum in a young girl with abdominal blunt injury. *Genomic Med Biomarkers and Health Scie* 2012;4:768. [CrossRef]
9. Levine RL, Pepe PE, Blackstone W, Danzinger J, Varon J. Occult traumatic avulsion of an ovarian dermoid cyst. *Am J Emerg Med* 1992;10:344–6.
10. Kimbrell BJ, Emami C, Petrone P, Asensio JA. Ruptured ovarian cystic teratoma secondary to blunt abdominal trauma: a very unusual case. *J Trauma* 2007;63:E27–9. [CrossRef]
11. Yohann A, Lee CW, Islam S. Traumatic rupture of an ovarian teratoma – Case report and review of the literature. *J Pediatric Surg Case Reports* 2017;23:34–6. [CrossRef]
12. Peden, M, Mcgee K.S, Sharma G. The Injury Chartbook: A Graphical Overview of the Global Burden of Injuries WHO: Geneva, Switzerland, 2002.
13. Casal Rodriguez AX, Sanchez Trigo S, Ferreira Gonzalez L, Brage Gomez S. Hemoperitoneum due to spontaneous rupture of ovarian adenocarcinoma. *Emerg Radiol* 2011;18:267–9. [CrossRef]

## OLGU SUNUMU - ÖZET

### Minör travma sonrası dev over tümörü rüptürüne bağlı gelişen hipovolemik şok: Olgu Sunumu

Dr. Yılmaz Güler,<sup>1</sup> Dr. Hasan Çalış,<sup>1</sup> Dr. Serkan Şengül,<sup>1</sup>  
Dr. Özkan Özen,<sup>2</sup> Dr. Zülfi Karabulut<sup>1</sup>

<sup>1</sup>Alanya Alaaddin Keykubat Üniversitesi Tıp Fakültesi, Genel Cerrahi Anabilim Dalı, Antalya

<sup>2</sup>Alanya Alaaddin Keykubat Üniversitesi Tıp Fakültesi, Radyoloji Anabilim Dalı, Antalya

Travmaya bağlı jinekolojik tümör rüptürleri oldukça nadir görülür. Rüptür, tümör çapına ve kanamaya bağlı olarak rüptüre olduğu alan ya da organda akut abdominal ağrıya yol açabildiği gibi, peritonite de sebep olabilmektedir. Bu çalışmamızda, minör travma sonrası gelişen rüptüre bağlı hipovolemik şok tablosuna neden olan dev epitelyal tip over tümör rüptürü olgusunu sunacağız. Altmış dokuz yaşında kadın hasta yürürken yere düşme sonrası gelişen karın ağrısı ve bilinç bulanıklığı şikayetleriyle hastanemize acil servisine başvurdu. Abdominal tomografide karın içi yaygın hemorajik sıvı ve 27.5x21x15 cm çapında karın sağ alt kadrandan sol kadrana doğru uzanan kitle lezyonu tespit edildi. Hasta hipovolemik şok tablosunda acil ameliyat edildi. Ameliyatta sağ over kaynaklı, ortasından tamamen rüptüre olmuş, kistik komponentler içeren ve yaklaşık 30x20x15 cm çapında kitle lezyonu saptandı. Kanama alanlarında hemostaz sağlanarak kitle total olarak çıkarıldı. Hasta ameliyat sonrası altıncı gün şifa ile taburcu edildi. Travmaya bağlı jinekolojik tümör rüptürleri nadir görülür. Ancak travmanın tipine bağlı olmaksızın mutlaka akılda tutulması gereken bir durumdur. Bu durum özellikle travma sonrası radyolojik olarak karıncı kanamanın saptandığı ancak sıklıkla yaralanan karaciğer ve dalak gibi organların radyolojik olarak normal olduğu durumlarda önemlidir.

**Anahtar sözcükler:** Hipovolemik şok; over tümörleri; rüptür; travma.

Ulus Travma Acil Cerrahi Derg 2021;27(4):486-489 doi: 10.14744/tjtes.2020.07045